



International Journal of Orthopaedics Sciences

ISSN: 2395-1958
IJOS 2018; 4(3): 22-26
© 2018 IJOS
www.orthopaper.com
Received: 05-05-2018
Accepted: 07-06-2018

Sunny Kumar Mallick
Senior Resident Doctor,
Orthopaedics, R.G.Kar Medical
College & Hospital, West Bengal,
India

Dipak Kumar Jha
Professor and head of the
department, Orthopaedics,
VIMS, West Bengal, India

Arindam Majumdar
Medical Officer, Orthopaedics,
Barasat district hospital, West
Bengal, India

Siddhartha Mahapatra
Post graduate trainee,
Orthopaedics, VIMS, West
Bengal, India

A comparative study between splinting versus corticosteroid injection in de-quervain's disease

**Sunny Kumar Mallick, Dipak Kumar Jha, Arindam Majumdar and
Siddhartha Mahapatra**

DOI: <https://doi.org/10.22271/ortho.2018.v4.i3a.05>

Abstract

Background: de Quervain's disease (DQ) is painful tenosynovitis of first dorsal compartment of hand. It is usually caused by overuse or repetitive activity. There are various modalities of treatment of DQ. Different studies have shown effectiveness of local corticosteroid injection, splinting or both in western population but to our knowledge, there is no effectiveness data available for Indian population.

This study was performed to compare the outcome of corticosteroid injection versus splinting for the treatment of de Quervain's tenosynovitis.

Methods: This randomized prospective study was conducted from July 2015 to December 2016 in Orthopaedics OPD of RKMSA. A total of 100 patients with de-Quervain's tenosynovitis were treated with either of these methods 1) corticosteroid injection in first dorsal compartment of wrist, 2) splinting, local ice or hot compression and topical Non-Steroidal Anti-Inflammatory (NSAIDs) gel.

Treatment effectiveness was measured by Wong-Baker FACES Pain Rating Scale, 0-10 Numeric Pain Rating Scale, size of nodule over radial styloid and grading of tenderness over 1st dorsal compartment.

Results: In the first group, a total of 50 patients were included (corticosteroid injection), and 50 patients in the second group (splinting, local ice or hot compression and topical Non-Steroidal Anti-Inflammatory (NSAIDs) gel). The mean age was 32.6 years (21 – 61 years) in all patients. There were 90 women and 10 men. Overall success rate was 90% in the first and 60% in the second groups, with a significant difference for both groups with respect to pain score and cure rate ($P < 0.05$). Temporary pain was the most common adverse reaction at the site of injection and was noted in 40% of patients.

Conclusion: Though steroid injection has excellent outcome, splinting can be an alternative viable treatment option for dQ especially in patients with low grade disease or reluctant to injection because of fear of probable adverse reactions.

Keywords: Keyword 1 de-Quervain's disease, Keyword 2 tenosynovitis, Keyword 3 corticosteroid injection, Keyword 4 splinting

Introduction

Fritz de Quervain first described De Quervain's tenosynovitis in 1895^[1]. It occurs typically in adults 30 to 50 years old, and women are affected six to ten times more frequently than men^[2]. De Quervain's disease is described as painful stenosing tenosynovitis of the first dorsal compartment of the hand. It is usually caused by overuse or an increase in repetitive activity, resulting in shear micro trauma from repetitive gliding of the first dorsal compartment tendons (Abductor Pollicis Longus (APL) and Extensor Pollicis Brevis (EPB) beneath the sheath of the first compartment over the styloid of the radius leading to thickening of the extensor retinaculum of the wrist. Predisposing movements include forceful grasping with ulnar deviation or repetitive use of the thumb^[3]. The cause is almost always related to overuse injury or is associated with rheumatoid arthritis.

Patients usually present with complaints of radial wrist pain with thumb movements and tenderness over the first dorsal compartment^[1-3]. Diagnosis is usually established by a positive Finkelstein's test, as well as the presence of a tender nodule over the radial styloid^[2-4, 5]. Finkelstein's test was first described in 1930 and has recently been described as being performed in four stages: first with the application of gravity assisted gentle active ulnar deviation at the wrist, then the patient actively deviates the wrist in an ulnar direction, then further passive ulnar deviation by the examiner, and in the final stage, the examiner passively

Correspondence

Sunny Kumar Mallick
Senior Resident Doctor,
Orthopaedics, R.G. Kar Medical
College & Hospital, West Bengal,
India

flexes the thumb into the palm [5, 6].

Conservative treatment, including rest with a splint and injection of steroid have most widely been used⁷. Because some patients have fear of steroid side effect and each of these treatment modalities has its advantages and disadvantages, we carried out this study to compare the outcome of these two treatment methods.

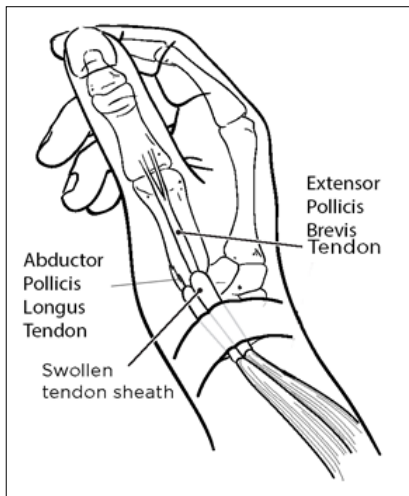


Fig 1: Pathology of de Quervain Tenosynovitis

Aims and Objectives

General objective

1. To treat De Quervain's disease patients actively.
2. To compare between the effectiveness of different treatment modalities.

Specific objective

To find the best treatment option for De Quervain's disease.

Materials and methods

This prospective randomized clinical study was carried out from July 2015 to December 2016 (18 months) at Out Patient Department of Ramakrishna Mission Seva Pratishthan (VIMS), Kolkata. Diagnosis of disease was based on these three clinical findings: 1) pain at the radial side of wrist with restricted abduction or extension of thumb, 2) tenderness over radial styloid process and 3) a positive Finkelstein's test. Patients with a previous history of acute trauma, wrist fracture, steroid injection, pregnancy, uncontrolled diabetes or rheumatoid arthritis were excluded from the study.

All patients were given explanations of the nature of the disease and plan of treatment. Written informed consent were given by all patients. Patients were randomly assigned by simple random sampling and consequently treated in two groups:

Group 1 patients were given 40 mg of methylprednisolone acetate injection along with 2ml of 1% lignocaine injection with a 5ml/1inch/25 or 27 gauge needle at about 2cm above the radial styloid process into the 1st extensor compartment [8, 9, 10]. If needed a 2nd injection was given after 3 weeks. If no improvement occurred even after 2nd dose, then it was considered as resistance to local steroid injection procedure.

Group 2 patients were advised readymade Thumb Spica splint and were asked to use the splint during their activities as much as possible and to use it even during rest.¹¹ Local ice compression was advised, but if worsened then switched over to local hot compression thrice a day. Topical NSAIDs gel was advised for local use thrice a day.

The patients were similar in both groups with respect to age, sex, duration of symptoms and criteria of diagnosis.

Follow up was done at 3 weeks interval till remission of symptoms and thereafter if symptoms recurred. At each visit, the following three physical signs were recorded for both groups:

- a) Finkelstein's test, its response in Wong-Baker FACES Pain Rating Scale (No Hurt, Hurts Little Bit, Hurts Little More, Hurts Even More, Hurts Whole Lot, Hurts Worst) and in 0–10 Numeric Pain Rating Scale [12, 13].
- b) Nodule over radial styloid process (size in mm).
- c) Tenderness over 1st dorsal compartment (soft tissue tenderness Grading scheme) (0-No tenderness, I-Tenderness to palpation WITHOUT grimace or flinch, II-Tenderness WITH grimace &/or flinch to palpation, III-Tenderness with WITHDRAWAL + "Jump Sign", IV-Withdrawal + "Jump Sign" to non-noxious stimuli) [14].

Treatment was considered successful if all three findings resolved and the patient had at least 90% improvement in the pain score. Relapse was considered if reappearance of the symptoms occurred after 3 months of remission of symptoms.

Categorical variables were expressed as Number of patients and percentage of patients and compared across the 2 groups using Pearson's Chi Square test. Continuous variables were expressed as Mean \pm Standard Deviation and compared across the 2 groups using unpaired T test if the data followed normal distribution and Mann-Whitney U test if the data did not follow normal distribution. Statistical analysis was performed using SPSS ver 23 software. A P value less than 0.05 was considered significant.

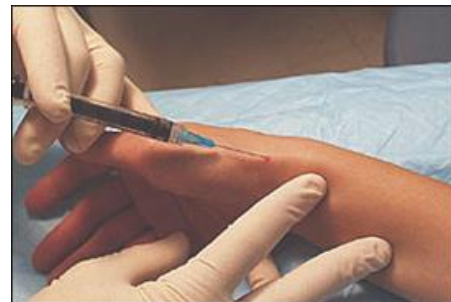

Fig 2: de Quervain injection technique

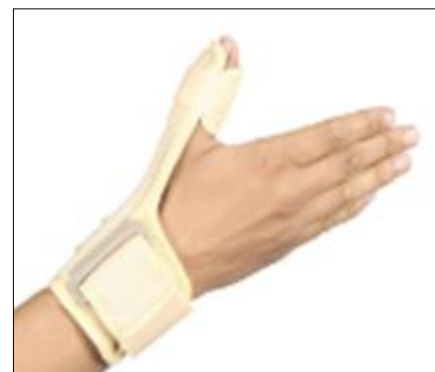

Fig 3: Thumb spica splint

Results

A total of 100 patients entered the study. In group 1, 50 patients were treated with corticosteroid injection and 50 patients in group 2 were treated with splinting, cold compress and topical NSAIDs.

The mean age of all patients was 35 years (range 21-62 years). There were 90 women and 10 men.

Table 1: Patient profiles

variable	Group 1: corticosteroid	Group 2: splinting
No of patients	50(100%)	50(100%)
Female	45(85%)	45(85%)
Male	5(15%)	5(15%)
Age(year), mean±SD, range	34.5±7(21-60)	36.1±8.1(22-62)
Right wrist	38	43
Left wrist	12	7
Duration of disease, weeks, mean±SD, range	6±4(2-10)	6.7±5(1-9)

Table 2: Outcome of treatment

variable	Group 1(n=50)		Group 2(n=50)	
	n	%	n	%
success	45	90	30	60
failure	5	10	20	40
Post injection pain	20	40	-	-

The overall success rate was 90% in injection group and 60% in splinting group. Pain was experienced by 20 patients which lasted less than one day post-injection. Skin discoloration at

injection site was seen in 3 cases. There was significant difference between both groups (P<0.05) in terms of pain scores. There was no adverse effect in splinting group.

Table 3: outcome with respect to Pain score

Variable: average pain score(0-9)	Group 1	Group 2	95 % CI		P-Value
	mean±SD	Mean ±SD	lower	upper	
Before treatment	4.8±1.2	4.6±1.7	-0.57	1.13	0.08
After treatment					
Success	1.5±1	2±0.7	-2.46	0.58	<0.05
failure	2±1.3	4±0.9	-2.76	-0.31	0.04
Skin hypo-pigmentation	3(6%)				
Sensory radial nerve impairment	0				

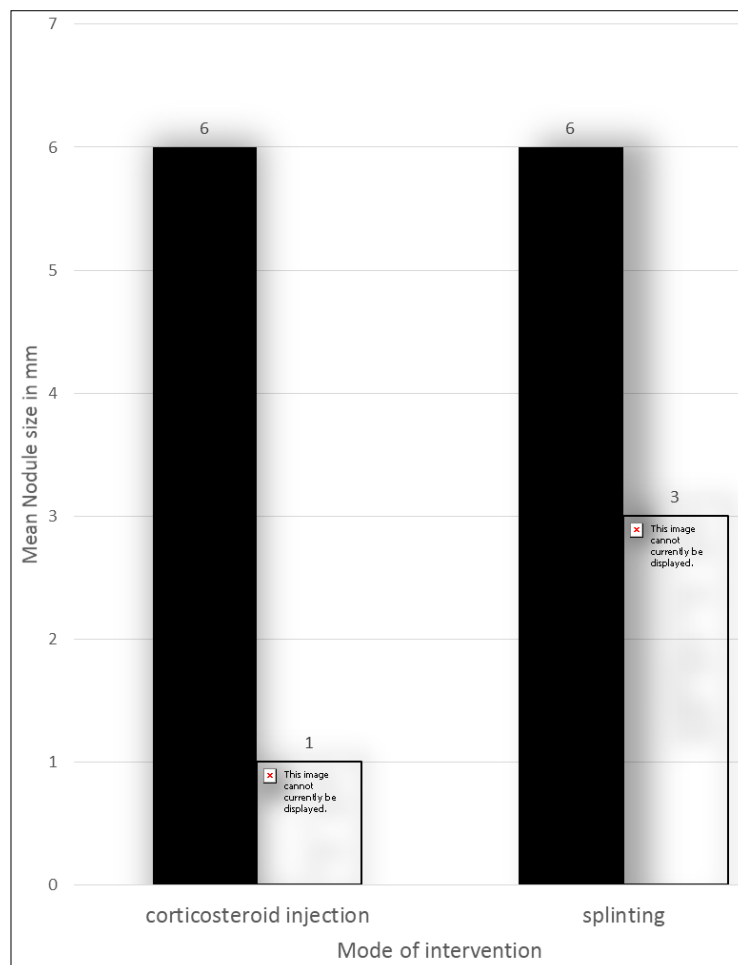


Fig 4: Effect of Corticosteroid injection vs splinting on Nodule size

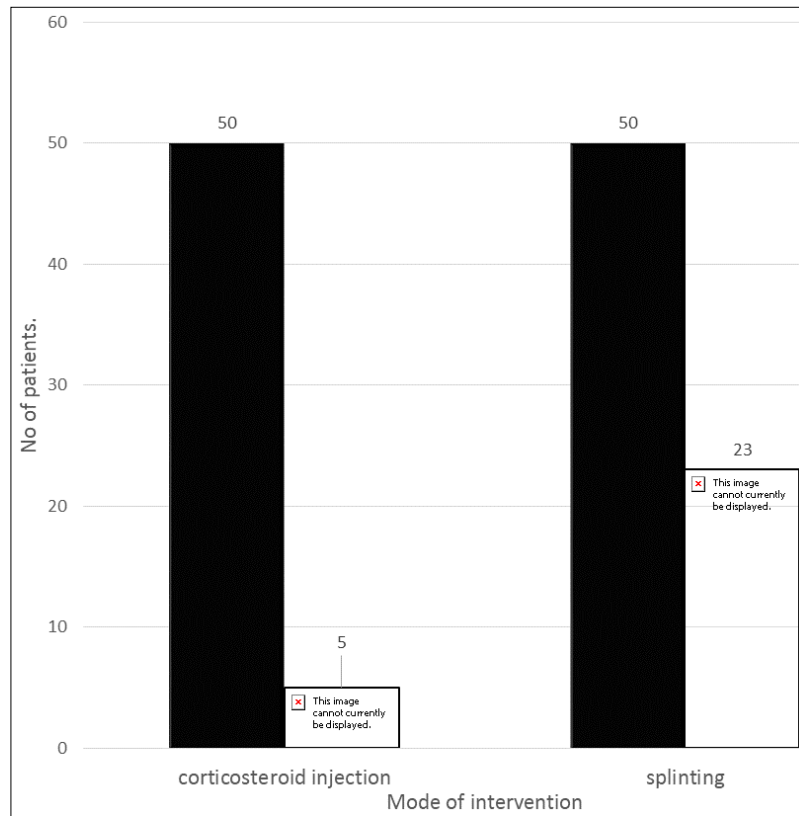


Fig 5: no of patients having pain score >3 at 0 and 52 weeks

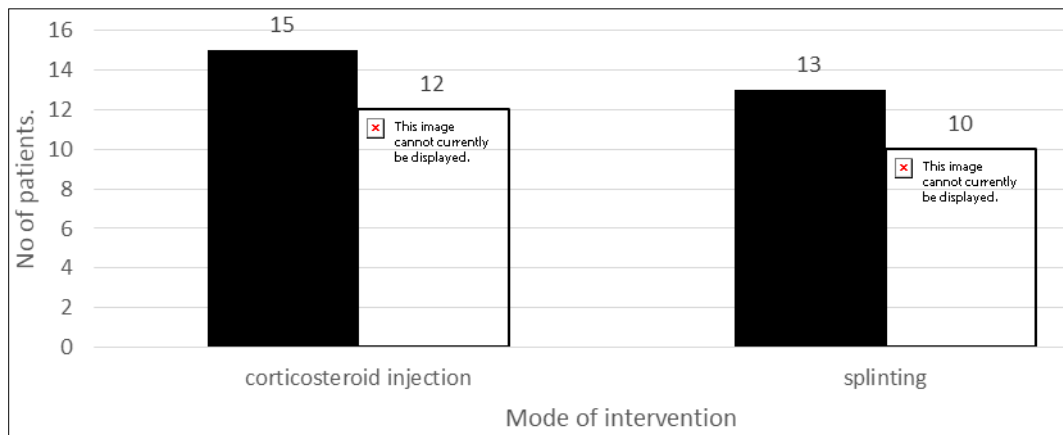


Fig 6: patients with initial grade II tenderness having no tenderness after intervention

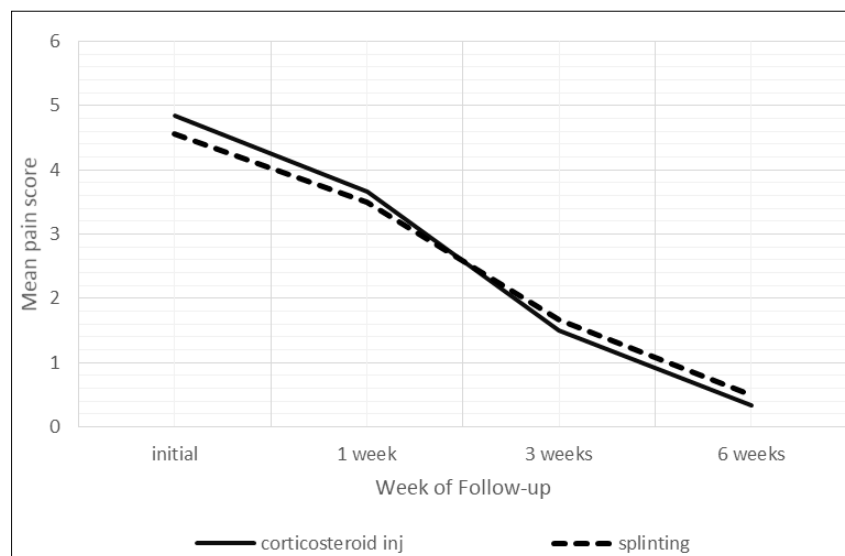


Fig 7: Reduction of pain score in the two groups

Discussion

Patients who received corticosteroid injection for the treatment of DQST were statistically significantly more likely to have full resolution of their symptoms during the follow-up period. The corticosteroid group also had statistically significantly less pain and activity limitation at first follow-up post than their counterparts who received thumb spica splint.

At 52 weeks of follow up 90% of patients had significant pain relief in injection group and 60% of patients in splinting group. In patients with grade II tenderness at initial presentation 100% had no tenderness after corticosteroid injection compared to 92% in splinting group with the difference being non-significant ($p>0.05$).

In cases of patient refusal for local corticosteroid injection splints can be used as an alternative mode of treatment.

There is no chance of complications like, infection, tendon rupture, Hypopigmentation if we use splints.

1. Carlton A. Richie III, DO, and William W. Briner, Jr, MD showed that, there was an 83% cure rate with injection alone. This rate was much higher than any other therapeutic modality (61% for injection and splint, 14% for splint alone, 0% for rest or nonsteroidal anti-inflammatory drugs) ^[15].
2. Cyriac Peters-Veluthamaningal, Jan C Winters, Klaas H Groenier and Betty Meyboom-deJong showed that, One or two local injections of 1 ml triamcinolone acetonide 10 mg/ml is an effective method of treatment provided by general practitioners for de Quervain's tenosynovitis with respect to short term outcomes when compared to placebo injection. The short-term effects were maintained for most of the outcome measures during the follow-up period of 12 months, but this was based on outcomes of the cohort of steroid responders and thus long term effectiveness is less clear ^[16].
3. Alfred F. Tallia, M.D., M.P.H., and Dennis A. Cardone, D.O., C.A.Q.S.M. University of Medicine and Dentistry of New Jersey–Robert Wood Johnson Medical School, New Brunswick, New Jersey, showed that, Pain associated with de Quervain's tenosynovitis is treated effectively by therapeutic injection ^[17].

Conclusion

Although the success rate was higher with corticosteroid injection, splinting can be considered as an alternative option for treatment of De Quervain's tenosynovitis especially in patients with low grade disease.

Also, splinting can be used as an effective mode of treatment in uncontrolled diabetes etc where invasive methods like injection can better be avoided.

References

1. De Quervain F. Ueber eine form von chronischer tendovaginitis. *Cor-Br F. Schweiz aerzte*. 1895; 4:899-903.
2. Wright PE II. Carpal tunnel, ulnar tunnel, and stenosing tenosynovitis. In: Campbell WC, Canale ST, Beaty JH, eds. *Campbell's Operative Orthopaedics*. 11th ed. Philadelphia, PA: Mosby/Elsevier, 2008, 4299-4230.
3. Retig AC. Athletic injuries of the wrist and hand. Part II: overuse injuries of the wrist and traumatic injuries to the hand. *Am J Sports Med*. 2004; 32(1):262-273.
4. Finkelstein H. Stenosing tendovaginitis at the radial styloid process. *J Bone Joint Surg*. 1930; 12:509-540.
5. Malanga GA, Nadler S. Musculoskeletal physical examination: an evidence-based approach. Philadelphia,

PA: Elsevier Mosby. 2006, 171-173.

6. Dawson C, Mudgal CS. Staged description of the Finkelstein test. *J Hand Surg*. 2010; 35A(9):1513-1515.
7. Weiss AP, Akelman E, Tabatabai M. Treatment of de Quervain's disease. *J Hand Surg Am*. 1994; 19(4):595-598.
8. Alfred Tallia F, Dennis Cardone A. Diagnostic and Therapeutic Injection of the Wrist and Hand Region. *D.O. Am Fam Physician*. 2003; 67(4):745-750.
9. Shivanna D, Manjunath D, Holagundi LM, Kumar HV. Outcome of Intra-Sheath Steroid Injection for De Quervain's Tenosynovitis. *The Internet Journal of Hand Surgery*. 2014; 6(1):1-5.
10. Bruce Carl Anderson, Richard Manthey, Matthew C. Brouns. Treatment of de Quervain's tenosynovitis with corticosteroids. A prospective study of the response to local injection. *Arthritis Rheum*. 1991; 34(7):793-798.
11. Johan Witt, Gary Pess, Richar Gelberman H. Treatment of de Quervain's tenosynovitis, a prospective study of the results of injection of steroids and immobilization in a splint. *The journal of bone and joint surgery*. 1991, 219-222.
12. Wong Donna Baker L, Connie M. Smiling face as anchor for pain intensity scales. *Pain*. 2001; 89(2-3):295-297.
13. John Farrara T, James Young Jr Pb, Linda LaMoreauxb, John Werthb L, Michael Pool R. Clinical importance of changes in chronic pain intensity measured on an 11-point numerical pain rating scale. *Pain*. 2001; 94(2):149-158.
14. Hubbard DR, & Berkoff GM. Myofascial trigger points show spontaneous needle EMG activity. *Spine*. 1993; 18:1803-1807.
15. Carlton Richie III ADO, William Briner W, Jr MD. Corticosteroid Injection for Treatment of de Quervain's Tenosynovitis: A Pooled Quantitative Literature Evaluation. *J Am Board Fam Med*. 2003; 16(2):102-106.
16. Cyriac Peters-Veluthamaningal, Jan Winters C, Klaas Groenier H, Betty Meyboom-de Jong. Randomised controlled trial of local corticosteroid injections for de Quervain's tenosynovitis in general practice. *BMC Musculoskeletal Disorders*. 2009; 10:131.
17. Alfred Tallia f, Dennis Cardone a. Diagnostic and Therapeutic Injection of the Wrist and Hand Region. *D.O. Am Fam Physician*. 2003; 67(4):745-750.