



International Journal of Orthopaedics Sciences

ISSN: 2395-1958
IJOS 2018; 4(3): 01-05
© 2018 IJOS
www.orthopaper.com
Received: 01-05-2018
Accepted: 02-06-2018

Dr. Vivian D' Almeida
Assistant Professor, Department
of Orthopaedics, Father Muller
Medical College, Mangalore,
Karnataka, India

Dr. Vinayak
PG Resident, Department of
Orthopaedics, Father Muller
Medical College, Mangalore,
Karnataka, India

Dr. Ashwin Kamath
Assistant Professor, Department
of Orthopaedics, Father Muller
Medical College, Mangalore,
Karnataka, India

Dr. Jubin Abraham Raju
Senior Resident, Department of
Orthopaedics, Father Muller
Medical College, Mangalore,
Karnataka, India

Dr. K Raghuvver Adiga
Professor and HOD, Department
of Orthopaedics, Father Muller
Medical College, Mangalore,
Karnataka, India

Correspondence

Dr. Vivian D' Almeida
Assistant Professor, Department
of Orthopaedics, Father Muller
Medical College, Mangalore,
Karnataka, India

Efficacy of epidural steroid injection in lumbar disc disease

**Dr. Vivian D' Almeida, Dr. Vinayak, Dr. Ashwin Kamath, Dr. Jubin
Abraham Raju and Dr. K Raghuvver Adiga**

DOI: <https://doi.org/10.22271/ortho.2018.v4.i3a.01>

Abstract

Purpose: Lumbar epidural steroid injection is a reasonable non-surgical option available in lumbar disc disease. We have a number of studies that have compared epidural steroid injections with discectomy for the treatment of lumbar disc herniation. There are only a few studies which throw light on conservative management of lumbar disc herniation. We intended to study and compare the effect and outcome of conservative (non-invasive) and epidural steroid injection (invasive but conservative).

Methods: In the year 2017 to 2018, a total of 100 cases of lumbar disc disease were randomly grouped into 2 groups of 50 each and one group treated with conservative measures and the other group with epidural steroid injection.

Results: The patients were followed up for a period of 1 year and were evaluated according to ODI and VAS scores taken preprocedure and on follow up visits. Thirty six percent of patients had either protrusion or extrusion of the lumbar disc. Irrespective of the magnitude of disc herniation, the cohort which was treated with epidural steroid injection showed significant improvement in symptoms. Beyond doubt steroid definitely helps control the chemical inflammation causing nerve root irritation which is believed to play a critical role in the genesis of radicular pain with and without the presence of mechanical compression of the nerve roots or cord.

Conclusion: Epidural steroid injection probably accelerates pain relief in patients who eventually have natural resolution of radicular pain in a gradual delayed fashion. Epidural steroid could allow faster return to function during the natural history of sciatica.

Keywords: epidural steroid, efficacy, lumbar disc disease

Introduction

It is a well-recognized fact that back pain in a disc disease is not only because of compression on neural elements, but may also be due to chemical inflammation. Surgery aims at decompressing the pressure on neural elements and conservative treatment aims to combat the chemical radiculitis^[1]. With the wide availability of MRI, clinical diagnosis and confirmation by MRI scan has been made easy. Many a times a disc lesion in MRI may influence the surgeon to operate and remove the offending disc. However, many such patients may not actually need surgery and can be treated non-operatively. It is also a well-known fact that the ten years of study by Weber *et al.*,^[1] states that the results of conservative treatment is comparable to surgical treatment on a long term. This study aims at analyzing the effectiveness of conservative treatment and to compare the outcome of the two broad categories which are invasive (epidural steroid) and non-invasive treatment of conservative care in a diagnosed and confirmed case of lumbar disc herniation^[2]. Back pain radiating to lower limbs is still, one of the unrewarding problems to deal with in clinical medicine. Among the various factors of low back pain, only those syndromes associated with neurological compression of the cauda equina of nerve roots, have reasonably well understood clinical presentation. Among the galaxy of causative factors, both spinal and extraspinal, the most common cause of low back ache seems to be the lumbar disc disease. The condition is increasing in number in our society and is associated with considerable morbidity and significant disability. The disc gives the spine the mobility and acts as a shock absorber^[3]. The diagnosis of the level and degree of protrusion or prolonged disc based upon clinical findings was confirmed by magnetic resonance imaging

which has a high sensitivity and specificity. The mode of conservative management are bed rest, skin traction, physiotherapy, exercise therapy, drug therapy and epidural steroid infiltration. Operative intervention indicated in patients with herniated disc with progressive neurological deficits but it has its own disadvantages of persistent pain and recurrence of symptoms.

Materials and Methods

Materials

The study was a hospital based prospective study. One hundred patients with lumbar disc herniation's in the age group of 25-70 years who were available for follow up were selected. Period of study was one year from April 2017 to May 2018. Patients who were presented to the Department of Orthopaedics at Father Muller Medical College hospital, Mangalore were drawn into the study. The cases which fulfilled the inclusion criteria mentioned here were taken up for the study.

Inclusion criteria

1. The patients above 18 years of age treated by only nonoperative methods.
2. Symptomatic patients with disc herniations with positive MRI findings.
3. Patients who would be available for follow up for minimum of 12months.

Exclusion criteria

1. Patients below 18 years.
2. Patients with progressive neurological deficits.
3. Patients with associated listhesis, instability of the spine.
4. Patients with cauda equina lesions.
5. Patients with history of previous spine surgery
6. Patients associated with infection or discitis
7. Any condition that comes in the way of early mobilization of the patient.

Methods

All patients who presented with low back ache with radiation to one or both gluteal regions and posterior aspect of the thighs in combination with exacerbation while coughing and sneezing were evaluated initially in the outpatient department. The diagnosis was confirmed with radiographic imaging. Lateral and anteroposterior plain radiographs of lumbar spine were taken to evaluate osseous anatomy and alignment. Later magnetic resonance imaging was done to confirm the disc herniation, to grade the disc herniation and also to rule out other possible causes of back pain such as infection in spine, tumours of spine and intra-abdominal visceral causes which will have major bearing with respect to treatment and inclusion into the study. Haematological (viz., Hb, TC, DC, ESR, Platelet counts), biochemical (blood sugar, blood urea, serum creatinine), serological (HIV, HBsAg) investigation were done as one of the groups in our cohort had later invasive procedure. All the patients were later admitted for the treatment.

Conservative management

Patients who were planned for conservative treatment were treated with Non-steroidal anti-inflammatory drugs, a muscle

relaxant and bed rest for a period of two to three days. Later physiotherapy (IFT, TENS, MH) was initiated. Physiotherapy included stretching, core muscle strengthening and trunk stabilization exercises. Patient education was a part of treatment in both the groups.

Epidural steroid injections

Patients who were planned (lumbar disc herniation-bulge, protrusion or extrusion) for epidural steroid injections were briefed about the pain management and goals and only after a written consent, invasive procedure was carried out. Platelet inhibitors like Clopidogrel, Aspirin were stopped a week prior to procedure, systemic infections were ruled out before injecting epidural steroid. Epidural steroid injection was performed by the anaesthetist on call. Our study comprised of administering only one dose of epidural steroid, without fluoroscopy guidance.

Technique

Epidural steroid injection was carried out in the operation theatre. Patient was positioned in lateral position. Injection containing Triamcinolone 40mg mixed with 3 to 4 ml of 2% lignocaine was injected to the epidural space without fluoroscopic guidance by interlaminar approach. All these injections were performed at one level cephalad to the disc herniation.

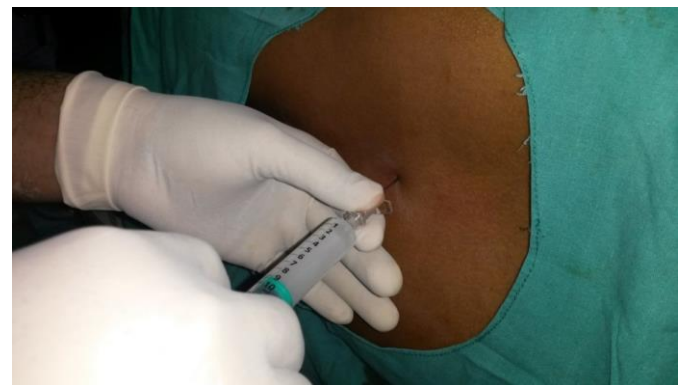

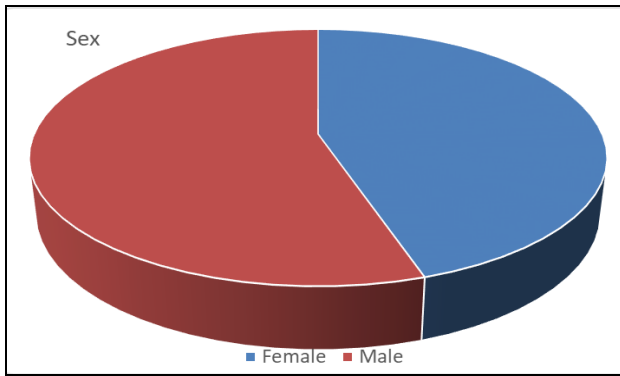
Fig 1: Administering epidural steroid

All patients in both the groups were prospectively assessed with clinical examination and questionnaires. The self-assessment questionnaire included a Visual analogue scale of 0 to 10 for assessment of current back and radicular pain. Pain drawing was used to indicate the magnitude of pain and an Oswestry disability index was used to quantitate the level of dysfunction (on a 0 to 100 point scale, in which higher score represents greater disability). The questionnaire and clinical examination was completed at presentation and at every follow up clinical visit. Follow up was carried out at one, six and twelve months interval after treatment. Core muscle strengthening exercises was a part of the treatment for both the cohorts.

Results

Age and sex distribution

Age group of our patients was between 25 to 70 years. Majority of our patients were in the age group of above 45 years. 45% were females and 55% were males.



Graph 1: Age vs Sex distribution

We had twenty female patients treated with epidural steroid injection and twenty five were treated with conservative management. Thirty male patients were treated with epidural steroid and twenty five were treated with conservative management. Our results showed that in both genders, epidural steroid injection yielded better results than conservative treatment. It was noticed that the female patients recovered early compared to the male patients as their Oswestry disability index (ODI) got better at 6 months follow up.

Table 1: Males vs Females

		Treatment	N	Mean	Std. deviation	T Score	df	P VALUE
Female	ODI 1 Month	ESI	20	52.55	6.468	-0.059	43	0.953
		Conservative	25	52.68	7.883			
	ODI 6 Months	ESI	20	38.9	7.137	-2.832	43	0.007
		Conservative	25	45.28	7.792			
Male	ODI 1 Month	ESI	30	51.17	8.824	-0.631	53	0.531
		Conservative	25	52.52	6.653			
	ODI 6 Months	ESI	30	38.4	9.412	-1.844	53	0.071
		Conservative	25	42.96	8.782			
ODI 1 Year	ESI	30	28.17	9.101	-2.781	53	0.007	
	Conservative	25	36	11.786				

Comparison of epidural steroid with conservative management:

Table 2: Results * Treatment Cross tabulation

		Treatment			Total
		ESI	Conservative		
Results	Excellent	Count	13	4	17
		% within Results	76.5%	23.5%	100.0%
		% within Treatment	26.0%	8.0%	17.0%
	Good	Count	32	25	57
		% within Results	56.1%	43.9%	100.0%
		% within Treatment	64.0%	50.0%	57.0%
	Fair	Count	5	17	22
		% within Results	22.7%	77.3%	100.0%
		% within Treatment	10.0%	34.0%	22.0%
	Poor	Count	0	4	4
		% within Results	0.0%	100.0%	100.0%
		% within Treatment	0.0%	8.0%	4.0%
Total	Count	50	50	100	
	% within Results	50.0%	50.0%	100.0%	
	% within Treatment	100.0%	100.0%	100.0%	

Table 3

	Value	Exact Sig. (2-sided)
Fisher's Exact Test	15.889	.001
N of Valid Cases	100	

The two comparing groups were distributed with equal number of patients. The results prove that epidural steroid injection gives significant relief of pain as compared to other conservative approach. We did not notice any complications in both the groups, especially in patients treated with epidural steroid injection viz., headache, facial flushing, increased back pain, nerve deficits and injury, intravascular injection, epidural haematoma, etc.

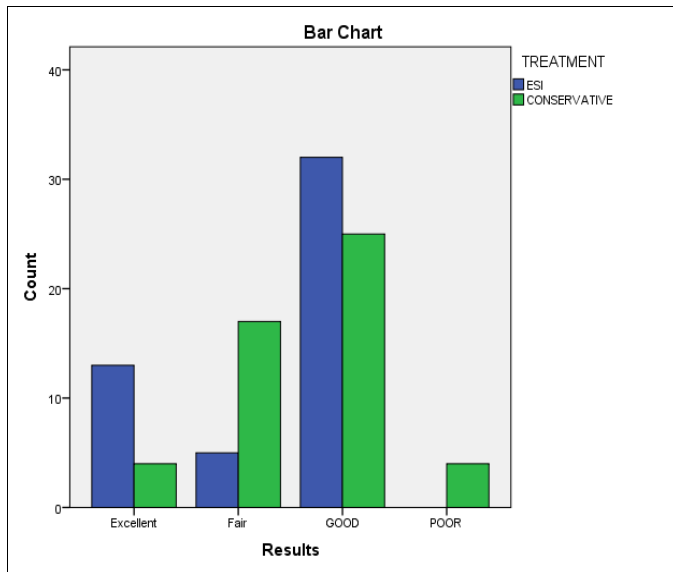
Observations and Discussion

Sciatica due to lumbar intervertebral disc herniation is one of the most common cause of radicular pain in an adult working population [4]. A plethora of treatment modalities exist for this common problem, many patients have a tendency to avoid surgery considering its associated risk factors and cost. Lumbar epidural steroid injection is a reasonable non-surgical option available in such situation. We have a number of studies that have compared epidural steroid injections with discectomy for the treatment of lumbar disc herniation⁵. There are only a few studies which throw light on conservative management of lumbar disc herniation. We intended to study and compare the effect and outcome of conservative (non-

invasive) and epidural steroid injection (invasive but conservative).

Strengths in our study was that it was a prospective study with a reasonably good patient size making it likely that results are generalizable. Treatment with epidural steroid injection or non-invasive management was randomly assigned.

There are few drawbacks in our study that needs to be quoted. The non-invasive management comprising of TENS, bed rest, Non-steroidal anti-inflammatory drugs and exercise regimens were done by different physiotherapists for different patients. Irrespective of whether the patients recovered or not, follow-up magnetic resonance imaging (MRI) was not done in our patients. There were few patients who crossed over from conservative management and opted for epidural steroid as they were not willing to complete the conservative treatment.



Graph 2: ESI vs Conservative

Thirty six percent of patients had either protrusion or extrusion of the lumbar disc. Irrespective of the magnitude of disc herniation, the cohort which was treated with epidural steroid injection showed significant improvement in symptoms. Beyond doubt steroid definitely helps control the chemical inflammation causing nerve root irritation which is believed to play a critical role in the genesis of radicular pain with and without the presence of mechanical compression of the nerve roots or cord. We cannot be certain that the difference between the two cohorts were exclusively due to epidural steroid, rather than unmeasured confounders. Notable difference at baseline in the demographic variations, past history with respect to back related disability and objective findings existed among those patients treated with epidural steroid injections or conservative management. However, the final effect of epidural steroid treatment on the predominant symptom and satisfaction were similar after adjusting for other predictors of outcome. Thus, our results are partly comparable to those of Weber's randomized trial.

We observed the fact that after a dose of epidural steroid injections the ODI got better and better with time. Though patient had a good relief from the radicular pain immediately following the injection we noticed that the sense of satisfaction of well being was only after few months. So considering this observation we can say that the full (complete) response of epidural steroid often was delayed. The quick relief can probably attributed to the local anaesthetic that is injected along with the steroid. Swerdlow.

M. *et al* in his study of intradiscal medications in the relief of lumbosciatic syndrome states that methylprednisolone injected in the epidural space can remain inside for upto 2 weeks^[2]. Probably this could be a reasonable explanation for a delayed action of epidural steroid that we observed in our study.

A general consensus is that a patient will be subjected to discectomy if he fails to recover after a 6 weeks conservative trial of bed rest, Non-steroidal anti-inflammatory drugs (NSAIDs) and electrotherapy^[9]. In our study we had few patients who were not relieved of symptoms even after 6 weeks of conservative treatment. The patients who were not willing to continue conservative treatment any further were given epidural steroid following which they did have relief from their early symptoms. Therefore, here we can learn that failure of NSAID's and electrotherapy in relieving sciatica does not imply that steroids will be ineffective. Epidural steroid can be considered as a viable option before the decision of discectomy is made.

While injecting the steroid, we used the posterior interlaminar approach without fluoroscopic guidance. Hence, there is a possibility of the steroid not having adequately spread to the anterior epidural compartment due to inaccurate needle placement in the posterior soft tissue of the back. We are not sure if this could be a reason for few failures in the epidural steroid injected group of patients in our study.

Though our results support the relative benefit of epidural steroid for properly selected patients, this does not mean that conservative management should be no longer recommended as initial treatment. Conservative management for at least 4 to 6 weeks can be recommended for patients with an intervertebral disc herniation without significant disability. After one month, our results should not be interpreted as requiring epidural steroid or surgical intervention in those without improvement since many of the conservatively treated patients in our study had good outcomes. For those with very bothersome symptoms, epidural steroid would hasten the recovery and may result in better outcomes. It is not clear in our study whether there is a time window beyond which the relative benefit of epidural steroid diminishes and thus when conservative treatment must be deemed to have failed.

Conclusion

- Epidural steroid injection probably accelerates pain relief in patients who eventually have natural resolution of radicular pain in a gradual delayed fashion.
- Epidural steroid could allow faster return to function during the natural history of sciatica.
- Patient education with respect to injury avoidance and home therapeutic exercise programme. Thus empowering the patient for self-care is definitely an effective means in treating the symptoms of lumbar disc diseases.

Summary

- This study was done to evaluate the effectiveness and also to compare epidural steroid and other non-invasive methods of conservative management for lumbar disc herniation.
- 100 patients were randomly divided into two groups of 50 each and were treated either with epidural steroid and other modes of non-invasive conservative management.
- We had patients between 25-70 years and majority were males.
- All the ODI and VAS scores obtained before and after the

treatment were tabulated and statistically analyzed.

- Patients treated with epidural steroid recovered earlier than the patients treated by other modes of conservative treatment.

References

1. Rozenberg S, Duborg G, Khalifa P, *et al.* Efficacy of epidural steroids in low back pain and sciatica: A critical appraisal by a French task force of randomized trials. *Rev Rhum.* 1999; 66:79-85.
2. Cluff R, *et al.* The technical aspects of epidural steroid injections: a national survey. *Anesth Analg.* 2002; 95(2):403-8.
3. Walker BF. The prevalence of low back pain: a systematic review of the literature from 1966 to 1998. *J Spinal Disord.* 2000; 13(3):205-17.
4. Rothoerl RD, Woertgen C. When should conservative treatment for lumbar disc herniation be ceased and surgery considered? *Neurosurgery review.* 2002; 25:162-165.
5. Wang Jeffrey C, Lin Eric, Brodke Darrel S. Epidural Injections for the Treatment of Symptomatic Lumbar Herniated Discs, 2002 *Journal of Spinal disorders and techniques.* 2002; 15(4):269-272.
6. Carragee EJ, Alamin TF, Miller JL, Carragee JM. Discographic, MRI and psychosocial determinants of low back pain disability and remission: a prospective study in subjects with benign persistent back pain.
7. Manchikanti L, Pampati V, Fellows B, Rivera J, Beyerr CD, Damron KS. Role of one day epidural adhesiolysis in management of chronic low back pain: a randomized clinical trial. *Pain physician.* 2004; 7:177-186. ISSN. 1553-3159.
8. Glen R Buttermann. Treatment of lumbar disc herniation. Epidural steroid injection compared with disectomy, *JB & JS.* 2004; 86:670-679.
9. Abdi S, Datta S, Trescot AM, Schultz DM, Adlaka R. Epidural steroids in the management of chronic spinal pain-a systematic review.
10. Stout A. Epidural steroid injections for low back pain. *Phys. Med Rehabil Clin Am.* 2010; 21(4):825-834.
11. Ibrahim Burak, Atci Albayanak, Serdal A. *Journal of Neurology Research.* 2013; 3(6):173.
12. Manchikanti L, Mallya Y, Wango BW, Pampati V, Fellows B. A prospective evaluation of complications of 10,000 fluoroscopically directed epidural injection.-*Pain Physician.* 2012; 15(2):131-140.
13. Benyamin RM, Manchikanti L, Parr AT, Diwan S, Singh V. The effectiveness of lumbar interlaminar epidural injections in managing chronic low back and lower extremity pain.
14. Manchikanti L, Buenaventura RM, Manchikanti KN, Ruan X. Effectiveness of therapeutic transforaminal epidural steroid injection in managing lumbar spinal pain. *Pain Physician.* 2012; 15(3):199-245.
15. Vad Vijay, Bhat BM, *et al.* Transforaminal Epidural Steroid Injections in Lumbosacral Radiculopathy: A Prospective Randomized Study: *Spine.* 2002; 27:11-15.