



ISSN: 2395-1958
IJOS 2018; 4(3): 16-21
© 2018 IJOS
www.orthopaper.com
Received: 04-05-2018
Accepted: 06-06-2018

Dr. Arshad Azeez
Junior Resident, Department of
Orthopaedics, Sree Balaji
Medical College and Hospital,
Chennai, Tamil Nadu, India

Dr. Srinivasan N
Asst. Professor, Department of
Orthopaedics, Sree Balaji
Medical College and Hospital,
Chennai, Tamil Nadu, India

Dr. Vijay Narasimman Reddy
Professor & Hod, Department of
Orthopaedics, Sree Balaji
Medical College And Hospital,
Chennai, Tamil Nadu, India

Management of Fracture Neck of Talus and Clinical Evaluation

Dr. Arshad Azeez, Dr. Srinivasan N and Dr. Vijay Narasimman Reddy

DOI: <https://doi.org/10.22271/ortho.2018.v4.i3a.04>

Abstract

Ankle injuries and Talar neck fractures are almost always the result of a high-energy trauma. It always remains a topic of debate whether talar neck fractures require emergent reduction. Most orthopaedic surgeons recommend the use of dual surgical approaches, anterolateral and anteromedial, to allow accurate visualization of the fracture and also for anatomic reduction. It is most important to cautiously preserve any remaining blood supply of the talus. Obtaining acceptable reduction and clinical results, while avoiding complications, presents a unique challenge in the treatment of the same. Common complications associated with talar neck fractures are, posttraumatic arthritis, osteonecrosis, and malunion, nonunion.

Keywords: Ankle injuries, Talar neck fractures, high-energy trauma

Introduction

The Talus has a complex anatomy and a unique blood supply. That predisposes to its uncommon but often serious injuries and complications thereafter. 60% of its surface is covered by articulate cartilage and it has 7 articular surfaces. The inferior articular facets with calcaneus forms the subtalar joint. The antero-medial surface and central trochlear surface, with lateral process form the talar portion of the ankle joint. The talus is held in the ankle by bony constraints, the medial and lateral malleolus, and constraining ligaments. Talus does not have any muscular attachments to it. Talar fractures are rare and uncommon, constituting less than 1% of all reported fractures, and only 4% to 6% of all fractures associated with ankle and foot. 1 Most talar fractures are as a result of high-energy trauma and have a high rate of associated injuries. Just about 50% of all talar fractures takes place through the talar neck, which is a part of the talus that has the smallest cross-sectional area and is covered with a relatively weak cortex and thus it is more prone for fractures. High-energy trauma that produces displaced talar neck fractures hinder the blood supply to the body of talus with produces varying degrees of articular cartilage damage. Establishing an acceptable and satisfactory clinical result, while preventing complications is demanding in the treatment of fracture neck of talus.

Mechanism of Injury

Talar neck fractures are almost always due to result of high-energy trauma, because the thick subchondral bone prevent it from getting fractured in a trivial trauma. The proposed mechanism of fracture neck of talus is hyper dorsiflexion force. 2 With dorsiflexion, there is initial breach in the posterior ligament complex of the subtalar joint, and the neck of the talus impacts against the leading anterior edge of the distal tibia. A fracture line develops at this point and enters the nonarticular portion of the subtalar joint between the middle and posterior facets. With the continuation of force, the calcaneus and the rest of the foot, including the head of the talus, sublux anteriorly. If there is an associated inversion component to the force, the foot might sublux or dislocate medially. Likewise, if there is any eversion force, the foot may go for lateral dislocation. If the force ceases at this moment, the foot recoils, and causes the body of the talus tips into equines, and the fracture surface of the neck comes to ride on the upper surface of the calcaneus. However, if the dorsiflexion force carry through, there will

Correspondence

Dr. Arshad Azeez
Junior Resident, Department of
Orthopaedics, Sree Balaji
Medical College and Hospital,
Chennai, Tamil Nadu, India

be further rupture of the posterior ankle capsular ligamentous complex, the tuff posterior talofibular ligament, and the superficial and posterior aspects of the deltoid ligaments takes place. The talar body is then wedged posteriorly and medially out of the ankle mortise and rotates in planes of horizontal and transverse axis so that the fracture ends faces upwards and laterally [3].

Fracture Classification

The most commonly established classification system for the fractures neck of talus is that by Hawkins4 (Figure 1), which relies mainly on displacement and dislocation, and therefore, suspected damage to the blood supply of the talus depending on its pattern of fracture displacement. In a long run this classification was further established and modified by Canale and Kelly, [5] who added the type IV category. A Hawkins type I fracture is an undisplaced fracture, without any associated subluxation or dislocation component to it. A Hawkins type II fracture is a displaced vertical talar neck fracture with a subluxation or dislocation of the subtalar/talocalcaneal joint. A Hawkins type III fracture is a displaced fracture spanning through the talar neck with dislocation at both the talocalcaneal and tibiotalar joints. The degree or the amount of displacement and dislocation is thought to be the primary assessing criteria of the interruption of its vascular status. and therefore, the risk for the development of osteonecrosis as one of its dreaded complication. A type IV fracture is associated with a dislocation of the tibiotalar and subtalar joint, also with an additional dislocation or subluxation of the head of the talus at the talonavicular joint. Several authors [5, 6] have found and satisfied that the above described classification system correlates with the final outcome and the incidence of avascular necrosis of talus. However, there has been many controversial results comparing other studies with that of Hawkins classification and avascular necrosis [7]. Despite all those flaws and these concerns, the Hawkins classification remains the standard and most widely accepted system for talar neck fractures.

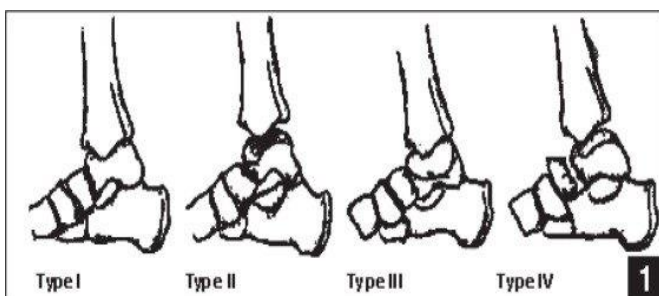


Fig 1: Modified Hawkins classification of talar neck fractures

Clinical and Radiologic Evaluation

Talar neck fractures are usually due to high-energy trauma. The most proposed mechanism of injury is either a high-velocity road traffic accident or fall from height. Talar neck fractures may be only part of the total spectrum of the patient's injuries, and a general trauma survey, other joint, long bones and spine examination should be included in each patient's evaluation and examination before diagnosing. Particular attention should also be directed to the thoracolumbar spine, because spine injuries have been found in frequent association with talar neck and body fractures.8 conscious patients will report severe foot and ankle pain.

Physical examination will reveal gross swelling and tenderness over the hind foot and mid foot. Significant deformity may be present depending on the displacement of the fracture and any associated subluxation or dislocation of the talocalcaneal or ankle joint. Because of potential damage to the neurovascular structures, it is important to perform a thorough assessment and examination of the affected foot.

Routine x-rays of the ankle, consisting of anteroposterior, mortise, and lateral plain radiographs, are used to identify suspecting fractures and displacement of the talar neck. The special oblique view of the talar neck described by Canale and Kelly [5] provides the best view of talar neck angulation and shortening, which is not easily elicited on routine radiographs. This radiograph is made by placing the ankle into maximum equinus and pronating the foot 15° while the x-ray tube is angled 75° from the horizontal plane (Figure 2). If plain radiographs do not clearly identify a fracture in a patient with a high suspicion for a non-displaced talar neck fracture, computed tomography (CT) may be recommended to avoid the possibility of a missed talar neck fracture.9 Preoperatively, CT scans are useful for assessing comminution and displacement of the fractures, as well as providing accurate images of the ankle, subtalar, and transverse tarsal joints.

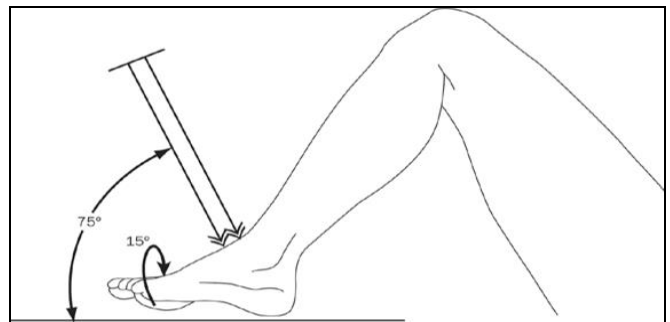


Fig 2: Canale view to evaluate the talar neck

Emergency Treatment

Fractures of the talar neck which are found undisplaced on a CT scan can be treated in a short leg non-weight-bearing cast in neutral position. The patient should be carefully followed with series of radiographs to ensure that the fracture does not go in for displacement during treatment course. As a treating orthopaedicians it should be in mind that failure to address subsequent fracture deformities leads to articular incongruence. Therefore, some authors recommend internal fixation for even undisplaced talar neck fractures. 10 An additional benefit of internal fixation is that it permits early motion.

Because of the high-energy mechanism and limited soft tissue envelope, 21% of talar neck fractures are open fractures, 4 requiring emergent operative debridement and irrigation to reduce the risk of infection. If primary anatomic reduction and fixation is not possible, (e.g. seriously ill multiply injured patients or patients with complex foot trauma) provisional fixation may be performed by either K-wires or a spanning external fixator.10 Some authors have advocated the use of an external fixator that provides distraction to the ankle joint to unload the talus, with hopes of reducing the morbidity of avascular necrosis [11, 12]. However, Besch *et al.* [13] concluded that the external fixation has no effect in the prevention of avascular necrosis following talar neck fractures.

It remains questionable whether talar neck fractures require emergent treatment. The time of definitive fixation always

depends on multiple factors, including fracture comminution, soft tissue conditions, available resources, surgeon experience and comfort level, and medical status of the patient [14]. In several clinical studies, the timing of internal fixation did not have a significant effect on the rate of avascular necrosis or the functional outcome [15, 16]. Hence, the investigation done by Patel *et al.* [17] indicates that most expert orthopedic trauma surgeons do not believe that immediate operative treatment is necessary for displaced talar neck fractures. Most reported that the operation can wait more than 8 hours, with a significant proportion reporting that treatment in more than 24 hours is acceptable.

Although delayed fixation may be suitable for talar neck fractures, a provisional closed reduction under local anesthesia to relieve the increased skin and neurovascular bundle tension caused by displaced fracture fragments should be considered. Once reduced, the dislocated joint typically stabilizes because of the shape and fit of the articular surfaces and surrounding structures. Repeated forceful reduction attempts should be avoided. Surgical intervention is indicated for type II, III, and IV fractures if an acceptable closed reduction cannot be obtained. Adelaar [18] recommended open reduction and internal fixation of any fracture with more than

3 to 5 mm dorsal displacement or any rotational deformity. Most authors have stressed that type II, III, and IV fractures should be treated by open anatomic reduction and stable internal fixation to restore articular congruity and permit early motion.

Operative Treatment

Most surgeons recommend the use of dual surgical approaches, anteromedial and anterolateral, to allow accurate visualization and anatomic reduction of talar neck fractures. [16, 19, 20] The anteromedial approach begins at the anterior border of the medial malleolus and extends toward the navicular tuberosity, just between the anterior tibial and posterior tibial tendons. Laterally, the incision begins at the Chaput tubercle on the tibia and extends toward the bases of the third and fourth metatarsals. [21] However, the Ollier approach, oblique from the tip of the lateral malleolus to the neck of the talus, is also effective, and allows better control of the lateral process and the anterior part of the posterior subtalar joint. If the fracture progresses posteriorly into the body of the talus, a medial malleolar osteotomy is recommended, although this is more frequently suggested for talar body fractures.

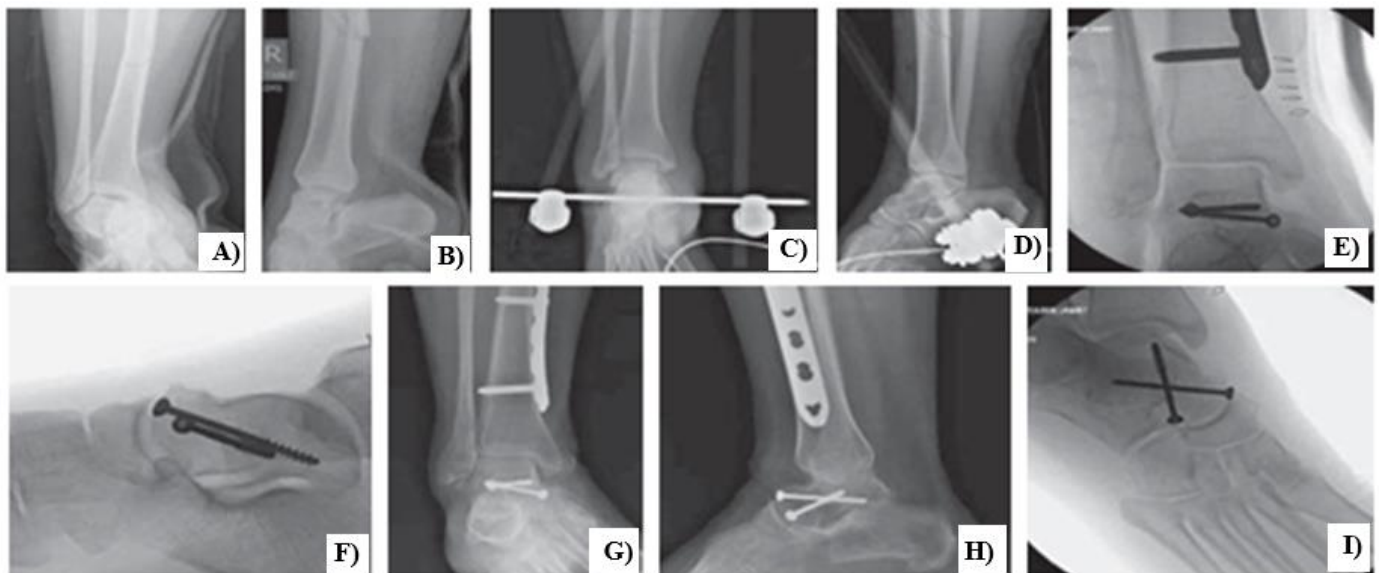


Fig 3: A 37-year-old woman sustained multiple injuries in an automobile vs train accident, including a displaced talar neck fracture with subtalar joint dislocation (A) and subluxation of the tibiotalar joint (B). Due to her multiple associated injuries, her talus fracture was initially treated by closed reduction (C) and application of a spanning external fixator (D). When her condition improved, she underwent open reduction and internal fixation using dual surgical approaches and 2 anterior to posterior lag screws (E-G). The patient has a good clinical and radiographic result 18 months after reconstruction (H, I).

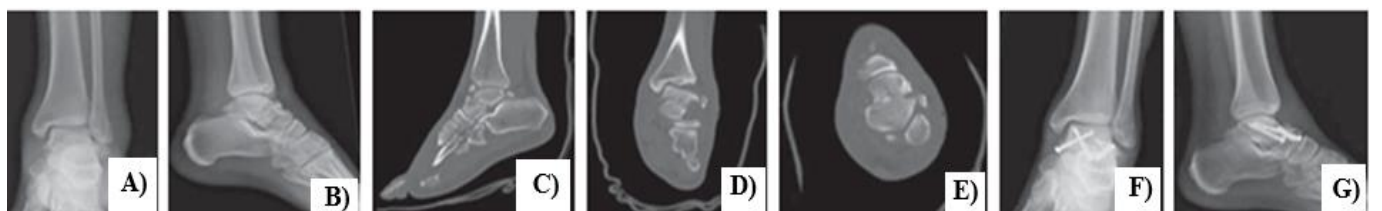


Fig 4: A 24-year-old man sustained a Hawkins type II talar neck fracture while riding his bicycle with a fixed cleat pedal (A, B). CT scans show the comminuted fracture of the talus, which extends through the neck to the middle articular facet (C,D,E). Radiographs 7 months after open reduction and internal fixation. Dual approaches were used, and that fracture fixed with 2 AP screws and a 2-mm lateral plate to maintain the talar neck length (F, G).

The above mentioned case illustrations are the reference case studies which was operated and treated in Sree Balaji medical college hospital Chennai during the year 2016.

The objective of surgical management of talar neck fracture is anatomic reduction of both the talar neck and subtalar joint,

because even minimal residual displacement or joint incongruity can adversely affect subtalar joint mechanics [8]. It is important to avoid reducing the talar neck fragment in supination, pronation, or axial malalignment. Because rotational alignment is very difficult to judge, dual approaches

are usually enforced. Provisional K-wires may be placed in the talar body and talar head fragment to serve as a joystick to correct the impending displacement and deformity. This technique avoids the use of a pointed reduction clamp that may require a larger exposure and cause more vascular derangement.

To achieve stable internal fixation and decrease the rate of malunion, at minimum of ^[2] screws are mandatory. Numerous types of screws have been described for talar neck fracture fixation, but titanium screws have the superiority when it comes to MRI compatibility, allowing early detection of osteonecrosis. Bioabsorbable screws have some theoretical advantages, in that they can be placed through the articular surface which get resorbed over time.

Most authors ^[10], advocate to place screws from anterior to posterior because the fracture site is routinely encountered from an anterior approach. However, Swanson *et al.* compared the biomechanical strengths of various fixation methods in a transverse, non-comminuted talar neck fracture model, and concluded that posterior-to-anterior screw fixation was stronger. Posterior-to-anterior screw fixation has potential disadvantages, including requiring an additional posterior approach with potential injury to the peroneal artery and its branches and screw head prominence that can limit ankle plantar flexion. Furthermore, if a posteroanterior screw is situated in the lower half of the head, the shaft of the screw protrudes into the roof of the sinus or canal tarsi, and can injure the canal tarsi artery. Attiah *et al.* studied different screw configurations in a comminuted talar neck fracture model. They compared ^[3] anteroposterior screws, ^[2] cannulated posteroanterior screws, ^[1] screw from anterior to posterior, and a medially applied blade plate. They concluded that the anteroposterior screws had approximately 20% lower yield point and stiffness compared to the posteroanterior screws or blade plate techniques, but this difference was not statistically significant.

Lag screws are typically used to compress talar neck fractures to withstand early motion which, is beneficial for ankle and subtalar joint function. However, when there is comminution of the talar neck, especially the medial column, the use of a lag screw may be contraindicated, as it will cause deformity and malunion. Transfixation screws are used to avoid compression and maintain the correct length of the talus.⁸ Bone grafting is occasionally needed to replace areas of impaction defects to restore the neck length.

For comminuted talar neck fractures, many authors have advocated plate fixation with or without neutralization screw fixation (Figure 4). ^[10, 19, 20, 3] By providing a solid buttress as a bridging strut, plates can be placed on the most comminuted column of the talus either medial, lateral, or bilateral columns. Plate sizes used range from 2 to 2.7 mm. Plates not only provide longitudinal structural support, but also prevent supination or pronation of the distal fragment.

After Treatment

Patients treated conservatively in a below-the-knee cast are kept non weight bearing for at least 6 weeks. Partial weight bearing is generally allowed after 6 to 8 weeks, and total weight bearing is permitted when there is convincing evidence of healing.

Open reduction and internal fixation aims at stable fixation, which permits early mobilization, decreasing the likelihood of stiffness. Once the wounds are healed, early postoperative active motion begins, depending on the degree of stable fixation and fracture comminution. Motion of the joints

improves cartilage healing ^[22]. Partial weight bearing is generally restricted for 6 to 12 weeks, and full weight bearing is delayed until radiographs show the fracture healing.

Avascular Necrosis

Avascular necrosis of the talar body, resulting from interruption of the precarious vascular supply to the talus, is the most dreaded late complication after talar neck fractures. The risk of developing avascular necrosis in a Hawkins type I fracture is only 0% to 15%, since only the blood supply entering through the neck is disrupted. Hawkins type II fractures have a 20% to 50% risk of avascular necrosis, with the artery of the tarsal canal and the dorsal blood supply from the neck being disrupted Type III and IV fractures have a 69% to 100% risk of avascular necrosis, with all ^[3] main sources of blood supply damaged ^[4, 5, 7]. More the degree of displacement, comminution, and compound injuries could increase the chances of developing avascular necrosis. Avascular necrosis of the body weakens the talar trochlea, resulting in its collapse if full weight bearing is permitted in the presence of avascular necrosis.1 depending on the collapse of the talar dome being it partial or full, the subsequent degenerative transition lead to pain and disability in both the tibiotalar and subtalar joints, along with shortening of the affected leg ^[4, 5]

The Hawkins sign, which is characterized as a prognostic indicator of revascularization of the talar body, appears within 6 to 8 weeks after the talar neck fracture, and can be radiographically envisage on the anteroposterior or the mortise view. The preserved blood supply resorbs the subchondral bone of the talar dome, developing a disuse osteopenia, which appears as a radiolucency of the talar dome which indicates preserved vascularity of the talus.⁴ In clinical practice, the Hawkins sign is strongly predictive of the absence of avascular necrosis. However, the sign is highly sensitive but less specific, such that its absence does not universally predict avascular necrosis.⁵ Magnetic resonance imaging will be of great use in its evaluation to assess the percentage of avascular necrosis involvement and helps in planning of appropriate treatment.

Although the contingent of developing avascular necrosis is determined at the time of injury, surgical management techniques, including prompt and accurate reduction of the dislocation, may decrease this complication. A thorough understanding of the anatomy of the fracture and meticulous surgical dissection and reduction techniques are essential to prevent further insult to the tarrying vessels. Tang *et al.* ^[12] reported that the use of a vascularized cuboid pedicle bone graft, combined with internal and external fixation, and showed that this method could effectively prevent avascular necrosis in their preliminary study.

Before the collapse of articular surface, the patient may be asymptomatic and function satisfactorily without discomfort. The talus often revascularize itself spontaneously if given ample amount of time. It takes place from medial to lateral through creeping substitution and it may taken even years together for the said outcome ^[4]. Once the diagnosis of avascular necrosis has been made, non-weight bearing, or partial weight bearing, should be recommended to prevent collapse of talar dome. Canale and Kelley⁵ found that those who were kept non-weight bearing on crutches for an average of 8 months had fair-to-excellent results, and those who were partial weight bearing in a patellar tendon brace or short leg brace with limited ankle motion had poor-to-good results. However, those receiving no treatment, defined as non-weight

bearing for <3 months, had mostly poor results. No consensus exists on either the duration or degree of restricted weight bearing, or on the utility of bracing or immobilization in minimizing the sequelae of osteonecrosis. Other authors believe that non-weight bearing is of questionable value in preventing collapse if avascular necrosis develops [3, 4].

When nonsurgical management fails to prevent avascular necrosis and collapse of the talar dome, surgical interventions should be considered. Secondary or salvage treatments include talectomy, bone grafting, tibiocalcaneal fusion, Blair fusion, and pantalar fusion. Talectomies yield poor outcomes, resulting in frequent pain, a short limb, and significant loss of ankle and subtalar motion [4, 5]. Arthrodesis has been suggested for use during primary treatment of severe talar neck fractures, with the aim of eliminating pain and the limitations of subtalar arthritis. However, we generally reserve arthrodesis as a salvage treatment following failure of internal fixation. A stainless steel talar body prosthesis introduced by Hamroongroj may be useful in treating avascular necrosis or severe crush injuries of the talus.

Malunion and Nonunion

Talar neck fractures very often evolves into malunion and nonunion, leading to limited range of movements at the subtalar and ankle joint depends on the type and site of involvement. The prevalence of malunion has been documented from studies that it accounts for approximately 30%, [5], and that of nonunion is approximately 2.5%. [8, 16] Typical clinical and radiographic findings of malunion are varus malalignment of the talar neck and deformity of the medial column. It is difficult to correctly evaluate residual step offs and alignment on plain radiographs. Chan *et al.* compared the ability of plain radiographs, computed tomography (CT), and radiostereometric analysis to detect changes in talus fracture fragment position and alignment using an *in vitro* model. The most accepted and authentic imaging method to measure malunion was CT scan. The 3D CT scan reconstructions allow the clinician to have better visual appearance of the anatomy of talar neck malunion.

Arthrodesis will be a vital salvage procedure for a well-established talar neck malunion or nonunion, but which does not restore the normal functioning of the joint. [5], Some authors have advocated surgical restoration of the anatomical shape of the talus for the treatment of malunions. Secondary reconstruction depends on the status of the soft tissues, the joint cartilage, and the signs of upcoming or established osseous necrosis. This salvage procedure corrects the foot malposition by an osteotomy through the malunited fracture or removal of the pseudarthrosis, and restoring the medial neck length using additional bone grafting if necessary. If talar neck malunion or nonunion occurs in the presence of complete avascular necrosis or septic necrosis of the talus, excision of all necrotic and infected bone materials augmented with bone grafting or shortening and arthrodesis of the affected joints are recommended

Posttraumatic Arthritis

Long-term follow-up studies have shown high rates of posttraumatic arthritis as a sequela of talar neck fractures. Causes of posttraumatic arthritis is a complex entity, which may include wear away of the articular cartilage at the time of injury, advancement in the process of cartilage degeneration from fracture malunion, nonunion causing malalignment and incongruence, or avascular necrosis. The incidence of posttraumatic arthritis is the most common sequelae following

talus fracture which is sometimes more commonly seen than that of avascular necrosis. The arthritis initially involves the subtalar joint, but may also affect the ankle and talonavicular joints at a later on stage. The subtalar joint is spring for arthritis because the calcaneus slides past the talus during dislocation, causing compressive and shearing forces that may result in damage to the cartilage. Not always all cases of posttraumatic arthritis become symptomatic. The development of severe arthritis causing chronic pain and stiffness may necessitate the need for arthrodesis if conservative treatment shows unsatisfactory outcome.

Conclusion

Fracture talus and talar neck have been found to have in association with a high incidence of complications, including avascular necrosis, infection, skin necrosis, malunion, nonunion, and posttraumatic arthritis as a late complication. The high-velocity nature of the trauma required to produce a displacement in relation with talar neck fracture can impend severe soft tissue damage, including compromising its unique blood supply. Absolute reduction and internal fixation of displaced fracture neck to reestablish and to maintain alignment has a major role in minimizing the complication rate to a higher instance. However, the posttraumatic sequel and complications may be inevitable, even without avascular necrosis being the most dreaded complication, following anatomic fracture reduction and fixation, patients frequently ails with chronic pain, discomfort and joint stiffness due to post traumatic arthritis as a late complication.

References

1. Adelaar RS. The treatment of complex fractures of the talus. *Orthop Clin North Am.* 1989; 20(4):691-707.
2. Heckman JD. Fractures of the talus. In: Rockwood and Green's Fractures in Adults. 5th ed. Philadelphia, PA: Lippincott, Williams & Wilkins, 2001.
3. Penny JN, Davis LA. Fractures and fracture-dislocations of the neck of the talus. *J Trauma.* 1980; 20(12):1029-1037.
4. Hawkins LG. Fractures of the neck of the talus. *J Bone Joint Surg Am.* 1970; 52(5):991-1002.
5. Canale ST, Kelly FB Jr. Fractures of the neck of the talus. Long-term evaluation of seventy one cases. *J Bone Joint Surg Am.* 1978; 60(2):143-156.
6. Inokuchi S, Ogawa K, Usami N, Hashimoto T. Long-term follow up of talus fractures. *Orthopedics.* 1996; 19(5):477-481.
7. Metzger MJ, Levin JS, Clancy JT. Talar neck fractures and rates of avascular necrosis. *J Foot Ankle Surg.* 1999; 38(2):154-162.
8. Fortin PT, Balazsy JE. Talus fractures: evaluation and treatment. *J Am Acad Orthop Surg.* 2001; 9(2):114-127.
9. Rodop O, Mahiroğullari M, Akyüz M, Sönmez G, Turgut H, Kuşkucu M. Missed talar neck fractures in ankle distortions. *Acta Orthop Traumatol Turc.* 2010; 44(5):392-396.
10. Rammelt S, Zwipp H. Talar neck and body fractures [published online ahead of print April 24, 2008]. *Injury.* 2009; 40(2):120-135.
11. Milenkovic S, Radenkovic M, Mitkovic M. Open subtalar dislocation treated by distraction external fixation. *J Orthop Trauma.* 2004; 18(9):638-640.
12. Tang H, Han K, Li M. Treatment of Hawkins type II fractures of talar neck by a vascularized cuboid pedicle bone graft and combined internal and external fixation: a

- preliminary report on nine cases. *J Trauma*. 2010; 69(4):E1-E5.
13. Besch L, Drost J, Egbers HJ. Treatment of rare talus dislocation fractures. An analysis of 23 injuries [in German]. *Unfallchirurg*. 2002; 105(7):595-601.
 14. Lawrence SJ, Singhal M. Open Hindfoot Injuries. *J Am Acad Orthop Surg*. 2007; 15(6):367-376.
 15. Comfort TH, Behrens F, Gaither DW, Denis F, Sigmond M. Long-term results of displaced talar neck fractures. *Clin Orthop Relat Res*. 1985; (199):81-87.
 16. Vallier HA, Nork SE, Barei DP, Benirschke SK, Sangeorzan BJ. Talar neck fractures: results and outcomes. *J Bone Joint Surg Am*. 2004; 86(8):1616-1624.
 17. Patel R, Van Bergeyk A, Pinney S. Are displaced talar neck fractures surgical emergencies? A survey of orthopaedic trauma experts. *Foot Ankle Int*. 2005; 26(5):378-381.
 18. Adelaar RS. Fractures of the talus. *Instr Course Lect*. 1990; 39:147-156.
 19. Sanders DW, Busam M, Hattwick E, Edwards JR, McAndrew MP, Johnson KD. Functional outcomes following displaced talar neck fractures. *J Orthop Trauma*. 2004; 18(5):265-270.
 20. Herscovici D Jr, Anglen JO, Archdeacon M, Cannada L, Scaduto JM. Avoiding complications in the treatment of pronation-external rotation ankle fractures, syndesmotic injuries, and talar neck fractures. *J Bone Joint Surg Am*. 2008; 90(4):898-908.
 21. Herscovici D Jr, Sanders RW, Infante A, DiPasquale T. Bohler incision: an extensile anterolateral approach to the foot and ankle. *J Orthop Trauma*. 2000; 14(6):429-432.
 22. Cronier P, Talha A, Massin P. Central talar fractures therapeutic considerations. *Injury*. 2004; 35(suppl 2):SB10-SB22.