

ISSN: 2395-1958
IJOS 2018; 4(2): 672-676
© 2018 IJOS
www.orthopaper.com
Received: 08-02-2018
Accepted: 09-03-2018

Dr. Avinash Kumar
Resident doctor, Department of orthopaedics, J. L. N. Medical College, Ajmer, Rajasthan, India.

Dr. BS Rao
Assistant professor, Department of orthopaedics, J. L. N. Medical College, Ajmer, Rajasthan, India

Dr. SK Bhaskar
Sr. Professor and Head, Department of orthopaedics, J.L. N. Medical College, Ajmer, Rajasthan, India

Long term functional outcome of intertrochanteric femur fractures treated with dynamic hip screw v/s proximal femoral nail: Retrospective study

Dr. Avinash Kumar, Dr. BS Rao and Dr. SK Bhaskar

DOI: <https://doi.org/10.22271/ortho.2018.v4.i2j.98>

Abstract

Background: Trochanteric fractures are devastating injuries that most commonly affect the elderly and also in young, have a tremendous impact on both the health care system and society in general. The mainstay of treatment of intertrochanteric fracture is fixation with a screw slide plate device or intramedullary device. The purpose of this retrospective study to review the long term functional outcome of Intertrochanteric femoral fractures treated with dynamic hip screw (DHS) v/s proximal femoral nail (PFN).

Methods: This study was conducted on 1000 patients of both sexes with intertrochanteric femoral fractures above 16 years of age group which were operated for intertrochanteric femoral fracture by DHS (500patients) and PFN (500patients) from January 2009 to December 2012. Functional results were assessed by Harris hip scoring system.

Results: In our study Mean age-62.66±16.99. The ratio of males to female was 1.23:1. 85.2% of patients were found with domestic fall and both sides were equally involved. In our study 5.2% cases of infection notated in the PFN group and 9.4% in the D.H.S group. Peri-Implant fracture occurred in 8 cases (1.6%) in PFN group and 19 cases (3.8%) in DHS group. Mechanical complications like (Breakage of PFN/ DHS screw and PFN/ DHS plate) occurred in 24 cases (4.8%) in PFN group and in DHS group were found in 16 cases (3.2%). Deformity (varus deformity and external rotation) occurred in 11 cases (2.2%) in PFN group and 44 cases (8.8%) in DHS group. Mean HHS of PFN was 92.064 and of DHS was 91.753(p=0.425).

Conclusions: We conclude that long term functional outcome measured by HHS of Intertrochanteric femoral fractures treated with dynamic hip screw v/s proximal femoral nail have no significant difference but complication like peri-implant fracture, Shortening, Screw cut-out, varus deformity were more in patient operated by DHS.

Keywords: Proximal femoral nail (PFN), dynamic hip screw (DHS), Intertrochanteric femur fractures, Harris hip score (HHS)

Introduction

Trochanteric fractures are devastating injuries that most commonly affect the elderly and also in young, have a tremendous impact on both the health care system and society in general. They are three to four times more common in women who are osteoporotic; trivial fall being the most common mechanism of injury^[1].

The incidence of intertrochanteric fractures varies from country to country. Gulberg *et al.*^[2] has predicted that the total no of hip fractures will reach 2.6million by 2025 and 4.5 million by 2050. In 1990 26% of all hip fractures occurred in Asia whereas this figure could rise to 37% in 2025 and 45% in 2050^[3].

In Denmark the incidence of hip fractures has declined about 20% from 1997 to 2006. Hagino *et al.* reported a lifetime risk of hip fracture for individuals at 50 yrs of age of 5.6% for men and 20.0% for women^[4].

For many, this fracture is often a terminal event resulting in death due to cardiac, pulmonary or renal complications. Approximately 10 to 30% of patients die within one year of an intertrochanteric fracture^[5].

Correspondence

Dr. Avinash Kumar
Resident doctor, Department of orthopaedics, J. L. N. Medical College, Ajmer, Rajasthan, India.

The goal of treatment of an intertrochanteric fracture is the restoration of the patient to his or her pre-injury status as early as possible.

Operative treatment for hip fractures was introduced in the 1950s with the expectation of improved functional outcome and a reduction of the complications associated with immobilization and prolonged bed rest [6, 7].

The purpose of this retrospective study to review the long term functional outcome of Intertrochanteric femoral fractures treated with dynamic hip screw v/s proximal femoral nail.

Material and Method

This retrospective study was conducted on 1000 patients admitted in the Department of Orthopedics JLN Hospital and Medical College, Ajmer which were operated for intertrochanteric femoral fracture by dynamic hip screw (500 patients) and proximal femoral nail (500 patients) from January 2009 to December 2012.

Patients of both sexes with intertrochanteric femoral fractures above 16 years of age group who underwent dynamic hip

screw v/s proximal femoral nail were included in this study while patients who had pathological fracture, ipsilateral shaft femur fracture, open fractures and patients with peri-prosthetic fracture were excluded from this study. Functional Results were assessed by Harris hip scoring system [8, 9].

Results

This study involved 1000 cases of intertrochanteric femur fracture of either sex from January 2009 to December 2012. 500 were treated by proximal femoral nail and 500 were treated by dynamic hip screw.

In our study maximum age was 97 years and minimum was 17years (Mean age-62.66±16.99 with male to female ratio of 1.23:1 and mode of injury domestic fall in majority (85.2%). both side were equally involved.

Infection, Shortening (>1 cm), Peri-Implant fracture and Mechanical complications found more in DHS group then PFN group and have significant difference.

Most of patients (95.0%) have good to excellent outcome in PFN group compare to (90.0%) in DHS.

Table 1: Common complications in pfn and dhs

Complications	PFN(n-500)		DHS(n-500)		P value	
	No.	Percentage (%)	No.	Percentage (%)		
Infection	26	5.2%	47	9.4%	0.015	
Screw cut-out	-	-	23	4.6%	-	
Anterior thigh pain	17	3.4%	29	5.8%	0.097	
Shortening	(< 1cm)	13	2.6%	21	4.2%	0.222
	(> 1cm)	18	3.6%	42	8.4%	0.002
Breakage of PFN screw	9	1.8%	-	-	0.007	
Breakage of DHS screw	-	-	9	1.8%	0.007	
Breakage of implant	15	3.0%	7	1.4%	0.131	
Z effect	16	3.2%	-	-	-	
Reverse Z effect	6	1.2%	-	-	-	
Peri-implant Fracture	8	1.6%	19	3.8%	0.051	
External rotation	0	0	1	0.2%	<0.001	
Internal rotation	0	0	0	0	-	
Varus deformity	11	2.2%	43	8.6%	<0.001	
Valgus deformity	0	0	0	0	-	

Table 2: Comparative Harris Hip Score

Harris Hip Score	PFN		DHS	
	No.	Percentage (%)	No.	Percentage (%)
Excellent	374	74.8%	326	65.2%
Good	101	20.2%	124	24.8%
Fair	25	5.00%	50	10.00%
Poor	0	0	0	0
Total	500	100	500	100

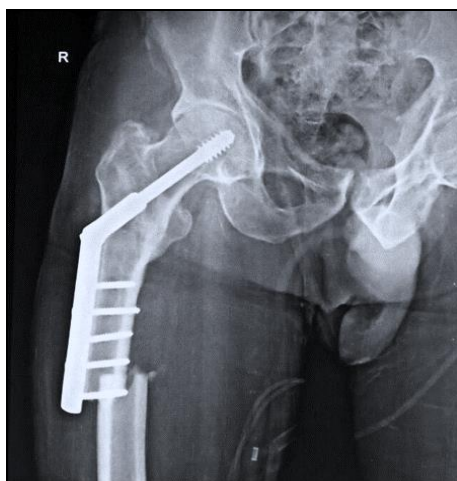

Fig 1: DHS with peri-implant fracture

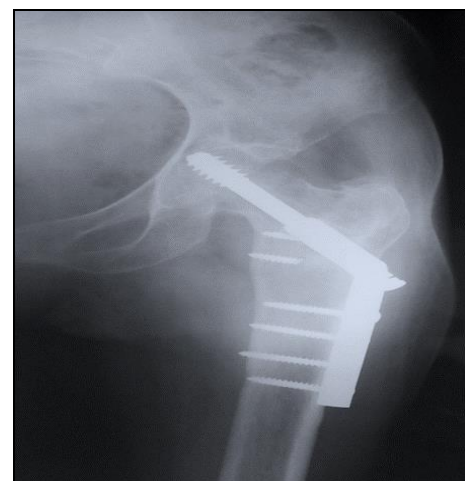

Fig 2: DHS with screw cut out

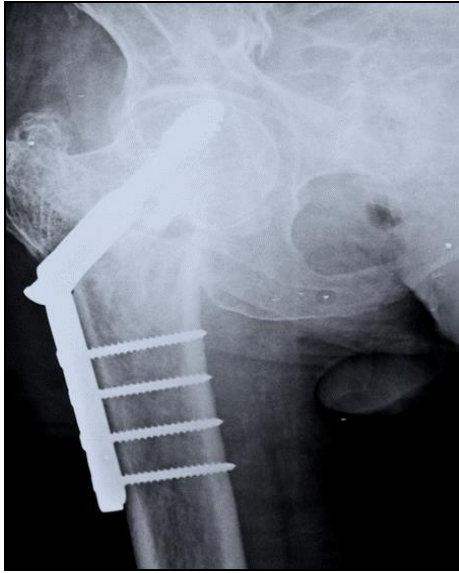


Fig 3: DHS with screw cut out and varus collapse

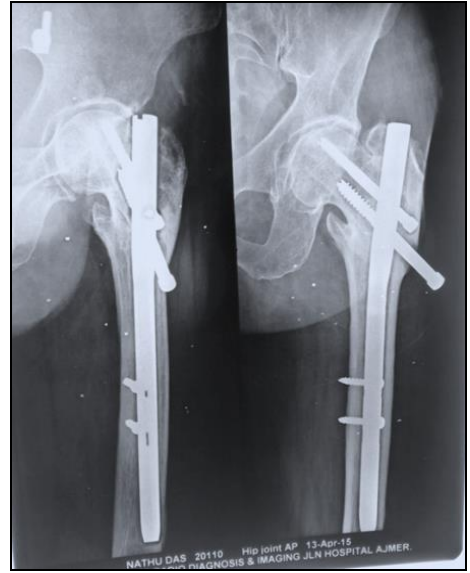

Fig 6: PFN with Reverse Z effect

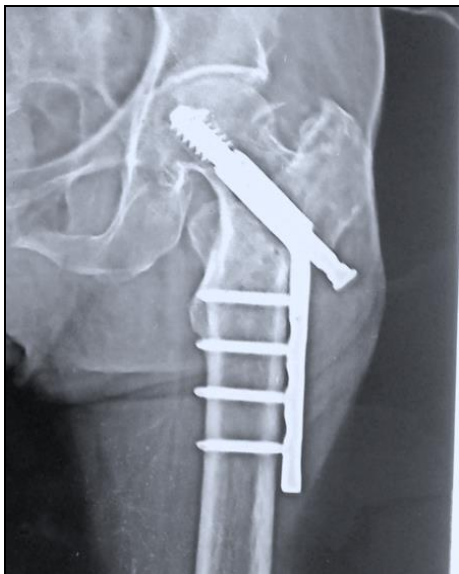

Fig 4: DHS with screw back out

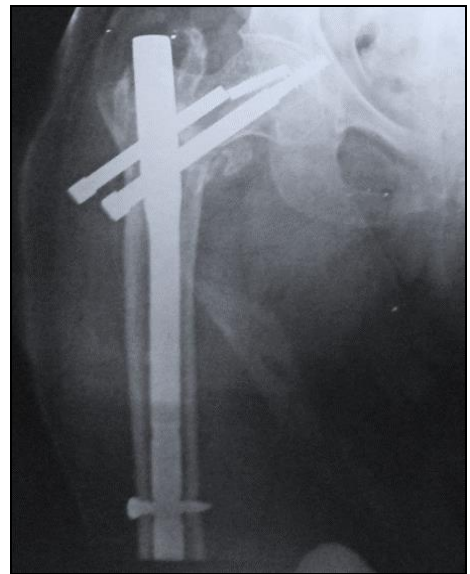

Fig 7: PFN with broken screw and screw cut out

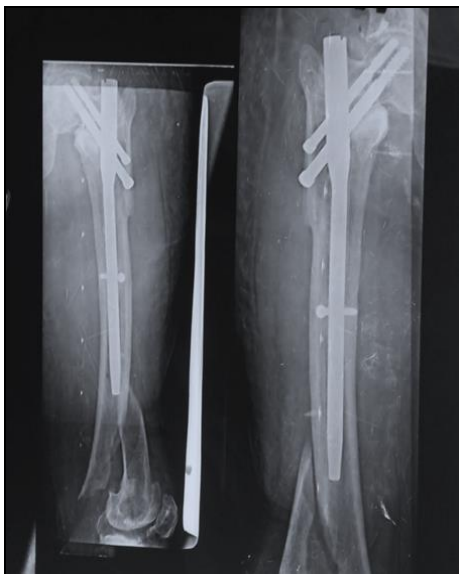

Fig 5: PFN with shortening, varus collapse and peri-implant fracture

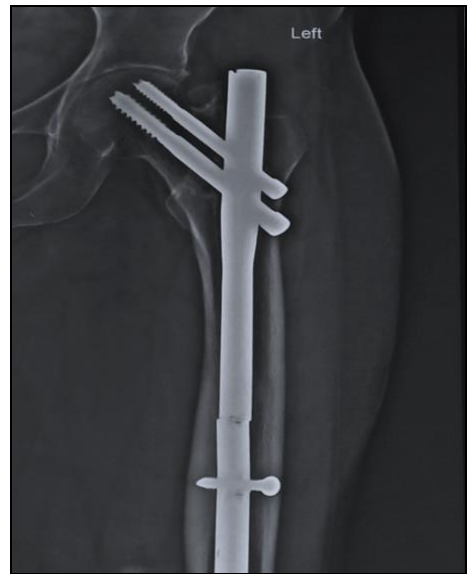

Fig 8: PFN with Breakage of implant

Discussion

In the last few decades treatment of intertrochanteric fractures has evolved significantly. The aim of management accordingly has drifted to achieving early mobilization, rapid rehabilitation and quick return of individuals to pre-morbid home and work environment as a functionally and psychologically independent unit.

Operative treatment in the form of internal fixation permits early rehabilitation and offers the best chance of functional recovery, and hence has become the treatment of choice for virtually all fractures in the trochanteric region.

The purpose of this retrospective study was to review the long term functional outcome of Intertrochanteric femoral fractures treated with dynamic hip screw v/s proximal femoral nail.

The study was conducted on 1000 treated patients of intertrochanteric femur fracture (500 patients by PFN and 500 patients by DHS) in Department of Orthopedics, JLN Hospital and Medical College, Ajmer from January 2009 to December 2012.

In our study average age was 62.66 years (range: 17-97 years). This is comparable with other studies done by Jonnes C *et al.* (2016) ^[10], Endigeri P *et al.* (2017) ^[11], Yadav A *et al.* (2014) ^[13] they observed the mean age of patients was near about 60 years in their studies.

Korkmaz *et al.* (2014) ^[14] and Shivanna *et al.* (2014) ^[15] observed the mean age of the patients were higher than our and other workers. In our study both side was equally involved (p=0.658).

The ratio of males to female was 1.23:1 for both the groups (p=0.849). This is comparable with other studies done by Jonnes C *et al.* (2016) ^[10], Shivanna *et al.* (2014) ^[15]. Korkmaz *et al.* (2014) ^[14] observed in their study male: female was 1:2.12.

This variation is probably because our study measured the male female ratio amongst operated fractures that reported for follow up and not the actual sex incidence for all trochanteric fractures.

The fracture due to domestic fall occurred in 85.2% patients while 13.2% patients met road traffic accident and in 10.1% patients fracture occur due to fall from height and fracture occur due to Assault in 0.6% patients.

Korkmaz *et al.* (2014) ^[14], Shivanna *et al.* (2014) ^[15] observed that more than 80% of hip fractures in the elderly result from a simple fall. Hip fractures in young adults were observed to result most often with high energy trauma such as motor vehicular accidents or a fall from height.

There were 26 cases (5.2%) of infection notated in the PFN group and 47 cases (9.4%) in the D.H.S group (P=0.015). They were seen within few days of surgery and treated by local debridement and antibiotic.

Sheoran *et al.* (2016) ^[16] and Sarukte *et al.* (2016) ^[17] also observed similar result.

Anterior thigh pain occurred in 17 cases (3.4%) in PFN group and 29 cases (5.8%) in DHS group (p=0.097). The plate and screw device weaken the bone mechanically. Yeganesh *et al.* (2016) ^[18] also found high Anterior thigh pain in DHS treated patients.

Shortening (<1 cm) occurred in 13 cases (2.6%) in PFN group and 21 cases (4.2%) in DHS group (p=0.222 NS).

Shortening (>1 cm) occurred in 18 cases (3.6%) in PFN group and 42 cases (8.4%) in DHS group (p=0.002 S). Even though there was more shortening in the D.H.S group it was not significant enough to cause any gait or functional impairment. Shortening might have resulted due to comminution of variable degree at fracture site & concentric collapse at

fracture site.

Similar observation by Sarukte *et al.* (2016) ^[17], Faisal *et al.* (2016) ^[19], and Mulay *et al.* (2015) ^[20].

Peri-Implant fracture occurred in 8 cases (1.6%) in PFN group and 19 cases (3.8%) in DHS group (p=0.051).

Smaller diameter and fluting tip helped to reduce the stress forces below the tip of the nail and thereby reducing the incidence of low energy fractures at nail tip. Stress rising of the construct also can be reduced by increasing length, small valgus angle and higher location of this angle at nail tip.

Jonnes C *et al.* (2016) ^[10] also found Peri-Implant fracture rate higher in DHS patients.

Mechanical complications like (Breakage of PFN screw and PFN) occurred in 24 cases (4.8%) in PFN group and Mechanical complications (Breakage of Plate and Richard screw) in DHS group were found in 16 cases (3.2%).

Screw cut out occurred in 23 cases (4.6%) in DHS group.

Z and reverse Z effect were found in 22 cases (4.4%) in PFN group. length of hip pin is larger than the lag screw then hip pin will become loose and result in Z effect this might force the pin to slide into the joint and lag screw slide laterally.

Deformity (varus deformity and external rotation) occurred in 11 cases (2.2%) in PFN group and 44 cases (8.8%) in DHS group (p<0.001). Due to the pull of the muscle the distal shaft fragment has the tendency to migrate upwards thus resulting in varus deformity.

Jonnes C *et al.* (2016) ^[10], Sheoran *et al.* (2016) ^[16] Sarukte *et al.* (2016) ^[17] were observed higher deformity with DHS treatment.

Our study shows Mean HHS of PFN was 92.064 and of DHS was 91.753 (p=0.425). Average harris hip score in both groups have no statically significant difference.

Jonnes C *et al.* (2016) ^[10] (<0.31), Bhakat *et al.* (2013) ^[21] (<0.467) and Chaitanya *et al.* (2015) ^[22] were found no statically significant difference in both groups.

Conclusion

In this study we conclude that long term functional outcome measured by HHS of Intertrochanteric femoral fractures treated with dynamic hip screw v/s proximal femoral nail have no significant difference but more excellent results found in patients which treated by PFN. Complication like Peri-implant Fracture, Shortening, Screw cut-out, Varus deformity were more in patient operated by DHS. We conclude that intertrochanteric fractures can be better and more effectively treated with Proximal Femoral Nail and had better functional outcome less complications.

Declaration

Funding: None

Conflict of interest: None declared

Ethical approval: Taken

Reference

1. Dimon JH, Hughston JC. Unstable intertrochanteric fractures of the hip. *J Bone Joint Surg Am.* 1967; 49(3):440-50.
2. Gulberg B, Johnell O, Kanis JA. World-wide projection for hip fractures. *Osteoporos Int.* 1997; 7(5):407-13.3.
3. Melton LJ 3rd, Kearns AE, Atkinson EJ, Bolander ME, Achenbach SJ, Huddleston JM, *et al.* Secular trends in hip fracture incidence and recurrence. *Osteoporos Int.* 2009; 20(5):687-94.
4. Hagino H, Furukawa K, Fujiwara S. Recent trends in incidents and lifetime risk of hip fracture in Tottori,

- Japan Osteoporosis Int. 2009; 20(4):543-548
5. Kyle RF, Cabanela ME, Russell TA. Fractures of the proximal part of the femur. Instr Course Lect 1995; 44:227-253.
 6. Massive WK. Fracture of hip bone joint surgery. 1964; 46a:658.
 7. Hugh WL. A self-adjusting nail plate for fracture about hip Joint, J bone joint surgery. 1955; 37A:1085-1093.
 8. Harris WH. Traumatic arthritis of the hip after dislocation and acetabular fractures: treatment by mold arthroplasty. An end-result study using a new method of result evaluation. J Bone Joint Surg Am. 1969; 51(4):737-55.
 9. Marchetti P, Binazzi R, Vaccari V, Girolami M, Morici F, Impallomeni C *et al.* Long-term results with cementless Fitek (or Fitmore) cups. J Arthroplasty. 2005; 20(6):730-7.
 10. Jonnes C, Shishir SM, Najimudeen S. Type II intertrochanteric fractures: proximal femoral nailing (PFN) versus dynamic hip screw (DHS). Archives of Bone and Joint Surgery. 2016; 4(1):23.
 11. Endigeri P, Pattanashetty OB, Banapatti DB, Pillai A, Ullas T. Outcome of intertrochanteric fractures treated with proximal femoral nail: A prospective study. J Orthop Traumatol Rehabil. 2015; 8:25-9.
 12. Yadav A, Anand V, Sidhu V, Singh TP, Sharma R. A Comparative Study of Proximal Femoral Nailing Versus Dynamic Hip Screw Device in the Surgical Management of Intertrochanteric Fractures (Extra capsular). The Internet Journal of Orthopedic Surgery, 2014, 23(1).
 13. Korkmaz MF, Erdem MN, Disli Z, Selcuk EB, Karakaplan M, Gogus A. Outcomes of trochanteric femoral fractures treated with proximal femoral nail: an analysis of 100 consecutive cases. Clinical interventions in aging. 2014; 9:569.
 14. Korkmaz MF, Erdem MN, Disli Z, Selcuk EB, Karakaplan M, Gogus A. Outcomes of trochanteric femoral fractures treated with proximal femoral nail: an analysis of 100 consecutive cases. Clinical interventions in aging. 2014; 9:569.
 15. Umesh Shivanna M, Girish Rudrappa H. A Comparative Study of Functional Outcome between Dynamic Hip Screw and Proximal Femoral Nail in Surgical Management of Per-Trochanteric Fractures. Journal of Evolution of Medical and Dental Sciences. 2015; 4(43):7489-7498.
 16. Dr. Ajay Sheoran. Comparative Analysis between Dynamic Hip Screw and Proximal Femoral Nail in Management of Peritrochanteric Femoral Fractures. Indian Journal of Research, 2016, 5(6).
 17. Vijay sarukte. Comparative Study of Surgical and Functional Outcomes of Intertrochanteric Fractures Treated With Dhs (Dynamic Hip Screw) And PFN (Proximal Femoral Nail). International Journal of Recent Scientific Research. 2016; 7(12):14769-14773.
 18. Yeganeh A, Taghavi R, Moghtadaei M. Comparing the intramedullary nailing method versus dynamic hip screw in treatment of unstable intertrochanteric fractures. Medical archives. 2016; 70(1):53.
 19. Faisal M, Nistane P. Proximal Femoral Nailing vs. Dynamic Hip Screw in unstable Intertrochanteric Fracture of Femur—A comparative analysis. Int J Biomed Advan Res. 2016; 7(10):489-92.
 20. Mulay S, Gouri F, Mahajan U. Treatment of Intertrochanteric Fracture by PFN or DHS. International J. of Healthcare and Biomedical Research. 2015; 3(03):209-15.
 21. Bhakat U, Bandyopadhyay R. Comparative Study between Proximal Femoral Nailing and Dynamic Hip Screw in Intertrochanteric Fracture of Femur. Open Journal of Orthopedics. 2013; 3(07):291.
 22. Chaitanya M. Comparison of Dynamic Hip Screw and Plate with Proximal Femoral Nail in Trochanteric Fractures of Femur. IOSR Journal of Dental and Medical Sciences (IOSR-JDMS). 2015; 14(4):73-82.