

ISSN: 2395-1958
IJOS 2018; 4(2): 640-648

www.orthopaper.com
Received: 03-02-2018
Accepted: 04-03-2018

Dr. Varun Manek
M.S Ortho, Department of Orthopaedics, Sree Balaji Medical College and Hospital, Biher, New Colony, Chromepet, Chennai, Tamil Nadu, India

Dr. K Venkatachalam
Professor, Department of Orthopaedics, Sree Balaji Medical College and Hospital, Biher, New Colony, Chromepet, Chennai, Tamil Nadu, India

Dr. Vijaynarasimman Reddy
Professor and Head, Department of Orthopaedics, Sree Balaji Medical College and Hospital, Biher, New Colony, Chromepet, Chennai, Tamil Nadu, India

Correspondence
Dr. K Venkatachalam
Professor, Department of Orthopaedics, Sree Balaji Medical College and Hospital, Biher, New Colony, Chromepet, Chennai, Tamil Nadu, India

Proximal humeral internal locking osteosynthesis for surgical fixation for displaced two part to four part fractures: A prospective study

Dr. Varun Manek, Dr. K Venkatachalam and Dr. Vijaynarasimman Reddy

DOI: https://doi.org/10.22271/ortho.2018.v4.i2j.93

Abstract
Secure fixation of displaced proximal fractures of the humerus is a challenging problem. Proximal humeral fractures constitute about 5 percent of all upper extremity fractures. They are often considerably displaced and communited in the elderly. About 66 percent of these fractures occur in patient above the age of 60 years. The female to male ratio is about 3:1 and the incidence of this fracture increases with age. It is in these older patients, that the mechanism of injury is usually a low energy trauma. As majority of these fractures occur in the osteoporotic bone, the operative treatment with locking compression plate has of late become the gold standard. The aim of the present study is to analyse prospectively, 45 cases of proximal humeral peri-articular fractures, occurring in the osteoporotic bone of the elderly, in the age group of 50 to 69 years treated surgically with PHILOS plating. It is to study their radiological and functional outcome score so the clinical outcomes and then to compare it with published literature. Also, comparison shall be made as to the time elapsed from injury to surgery, the surgery duration, the loss of blood during surgery, post-op complications and the time required for radiological bony union. In our series, the clinical outcome assessed as per the Constant Shoulder Score, achieved 44.45% fair, 40% good and 11.11% excellent results. We had 4.44% of poor outcomes. Our study conclusively shows that LCP should be considered as a gold standard in treating displaced peri-articular proximal humeral fractures especially in the elderly with osteoporotic bone. These implants provide greater angular stability, better biomechanical properties and enhanced anchorage in these complex injuries. The goal of the treatment is primarily to restore a painless shoulder with reasonably satisfactory function.

Keywords: Proximal humerus fractures, PHILOS plating, locking compression plate

Introduction
Proximal humeral peri-articular fractures in the elderly osteoporotic bone are categorized as fragility fractures [1]. These fractures occur in bone wherein the bone mass index is significantly reduced and are extremely prevalent in the elderly and more so in the women. Fragility fractures are caused as a result of low energy trauma that occur from fall from standing height or less. The most common locations are vertebrae, hip, wrist and the proximal humerus [2]. The management of these types of fragility fractures have undergone a paradigm shift over the past 10 years. Minimally invasive approaches combined with biologically friendly internal fixation have become accepted methods of treatment of these complex fractures [3]. The biomechanical properties of locking plates have distinguished and defined their clinical efficacy compared to conventional plates. Locking plates function as 'internal fixators' with multiple anchor points [4]. The available literature has proven beyond reasonable doubt the low rates of non-union and overall fewer complication rates with the use of PHILOS plates in the osteoporotic proximal humeral periarticular fractures [5]. Poor bone quality encountered in older adults, increases the technical difficulty and complications of operative treatment of fragility fractures. The goal of these surgeries is to optimize bone-joint alignment, preserve blood supply to help heal and to provide adequate stability in order to permit early mobilization. With these locking plates screws become "one" with the plate, thereby reducing the possibility of hardware failure. Stability and "pullout" strength are determined by the sum of all locked screws, instead of a single screw [6].

The plate-screw in a LCP assembly assures uniform distribution of the stresses along the entire length of the plate, thereby making locking plates best suited for osteoporotic bone fractures. The use of the PHILOS plate via anterolateral deltoid splitting approach has in the literature shown good outcomes and the very same technique has been followed in our operative series also. While using this approach have several advantages [7, 8], including minimal soft tissue disruption, preservation of natural biology and minimal blood loss, there has been described an increased risk for axillary nerve damage. In our series, we have demonstrated that with strict adherence to the proximal humeral clinical anatomy, the theoretical risk of damage to the axillary nerve can be avoided. In our series of PHILOS plate fixation of proximal humerus, we have adhered strictly to the principles of biological fixations as pioneered by AO group.

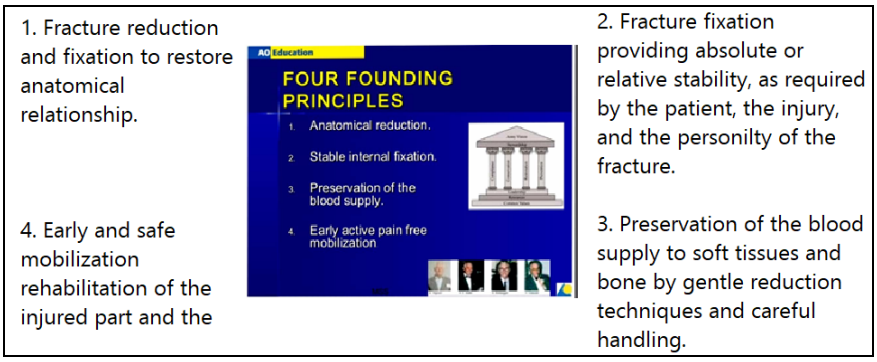

Fig 1: AO four pillar principles for internal fixation of fractures.

Materials and methods

This prospective study was done at Sree Balaji Medical College and Hospital, BIHER, Chromepet, Chennai from March 2015 to December 2017. In this 34 months of study duration, the recruitment of fresh case was stopped in February 2017, so that there would be a minimum follow up period of 10 months.

Inclusion criteria

- Both male and female patients in the age group 50-69 years were included in the study.
- NEER fracture Type two part to four parts alone were included in the study.

Exclusion criteria

- Type one part fractures were excluded from the study.
- Severely comminuted with head split fracture four parts were excluded from the study, as they would qualify primarily for arthroplasty.
- Polytrauma patients were excluded from the study.
- Fractures older than10 days from the time of injury were excluded from the study.

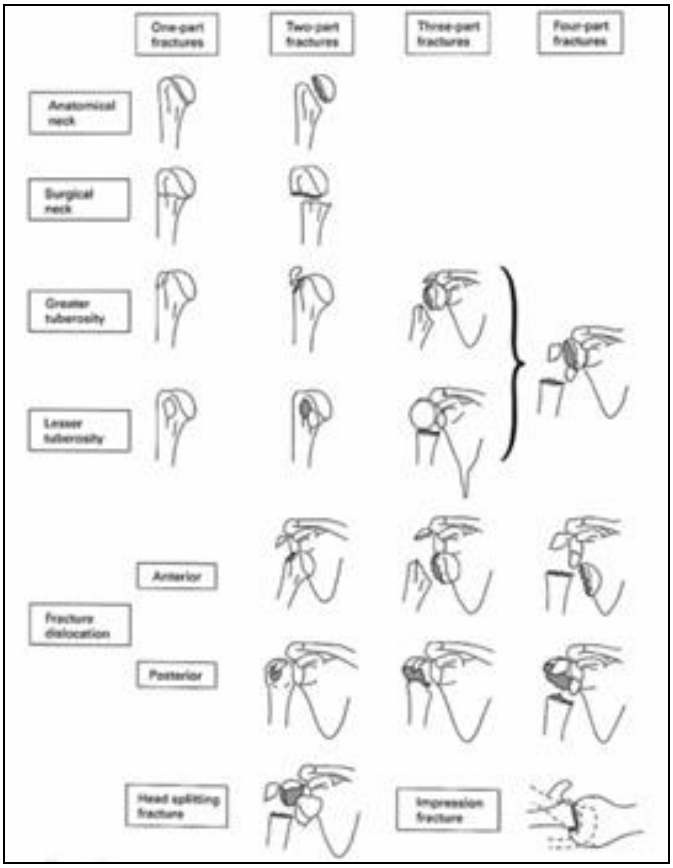

Fig 2: Neer classification for proximal humerus fractures [7].

After obtaining necessary medical, cardiac and anesthetic fitness, cases were taken up for surgery. All patients were operated upon by the same surgical team and through a deltoid splitting approach was used, locking compression plate (PHILOS – Proximal Humeral Interlocking Osteosysnthesis) was the implant for all cases. In cases requiring bone grafting, it was obtained from the ipsilateral iliac crest. Prophylactic and post-operative IV antibiotics (ceftriaxone with sulbactum 1.5 gm BD) were given for a period of 3 days. Post – operatively patients were given an arm sling and for relief of pain, injectible NSAID or Opioid derivative were given. DT removal was done on POD 2. Pendular exercises were initiated by the bedside by POD 3. Suture or staple removal was done on POD 12 to POD 14.

Active shoulder mobilization exercises were initiated from the third week onwards or earlier if pain was well tolerated by the patients. Fracture union was assessed clinically and radiologically at the end of 6 weeks, 12 weeks and 18 weeks or till radiological evidence of union. Constant shoulder score was assessed at the end of 10 months and the results tabulated.

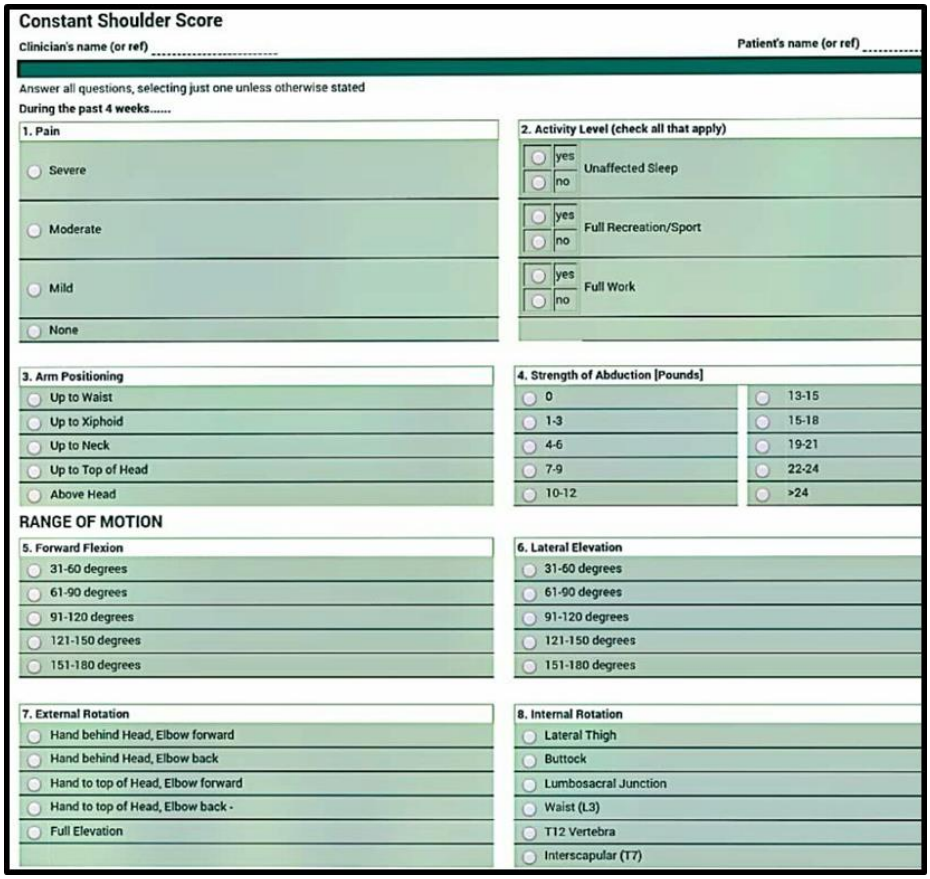

Fig 3: Constant shoulder scoring system [10].

Surgical hardware

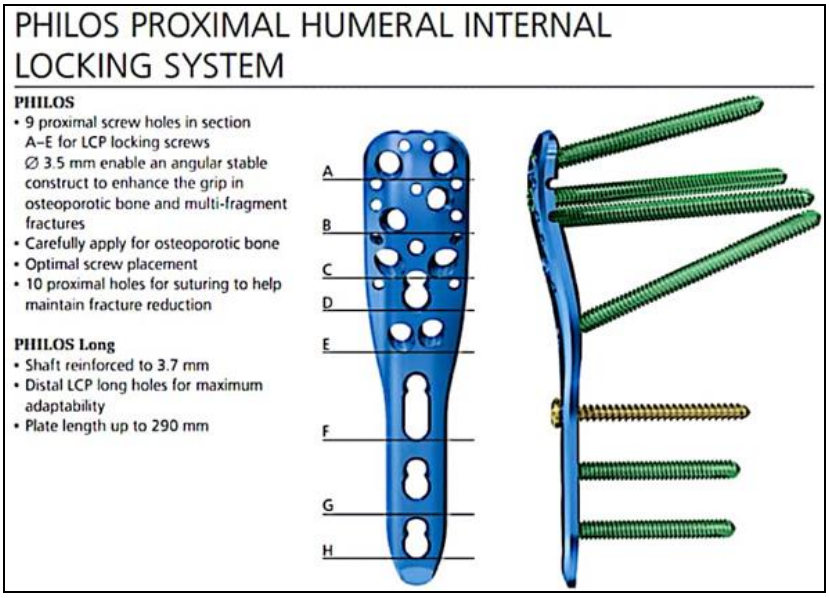

Fig 5: PHILOS plate construct.



Screws used with PHILOS	
X12.102–X12.124	Locking Screw Stardrive ∅ 3.5 mm, length 12–60 mm, self-tapping
X13.012–X13.060	Locking Screw ∅ 3.5 mm, length 12–60 mm, self-tapping
*X04.812–X04.860	Cortex Screw ∅ 3.5 mm, length 12–60 mm, self-tapping
0X.200.012–0X.200.060	Cortex Screw Stardrive ∅ 3.5 mm, self-tapping, length 12–60 mm

Fig 6: Screw types used in PHILOS plate.

Fig 7: C-arm image pre-op.

Fig 8: Pre-operative skin marking to avoid injury to axillary nerve. The area in between the dotted line is the danger zone. The axillary nerve lies at a distance between 5 to 7 cm from the tip of the acromion.

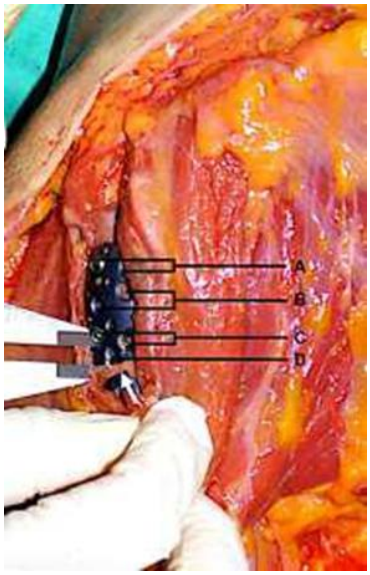

Fig 9: The proximal holes of PHILOS plate are marked as A-D while the arrows indicates the axillary nerve which just passes across the plate elbow hole. This is the safe zone for screwing above the D line. The plate has been slid under the axillary nerve.

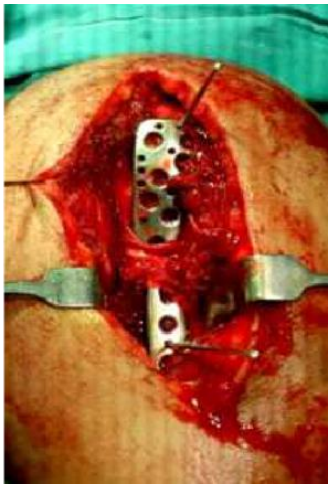

Fig 10: Intra-operative picture showing the axillary nerve and the PHILOS plate being slid underneath it.

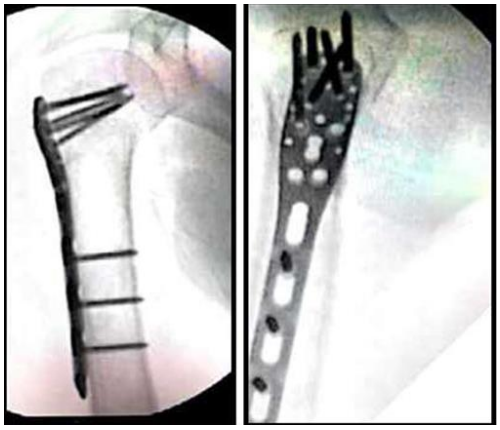

Fig 11: Immediate post-op c-arm image AP and lateral.

Fig 12: Minimal surgical incision length.

Surgical procedure adopted for proximal humeral fracture fixation in our case series

Previous studies have shown that the traditional delto-pectoral approach to the proximal humerus provides very limited access to the postero-lateral aspect, of the shoulder and that visualisation and reduction of a large retracted greater tuberosity poses a technical difficulty. Further the delto-pectoral approach requires extensive soft tissue dissection and muscle retraction in order to gain adequate exposure to the lateral aspect of the proximal humerus. This extensive approach can cause further devascularisation during surgical dissection and plating thereby leading to disruption of an already critical blood supply to the humeral head and other displaced fracture fragments leading eventually to avascular necrosis of the humeral head. Thus, it is vital to understand the intricate vascular supply of the proximal humerus.

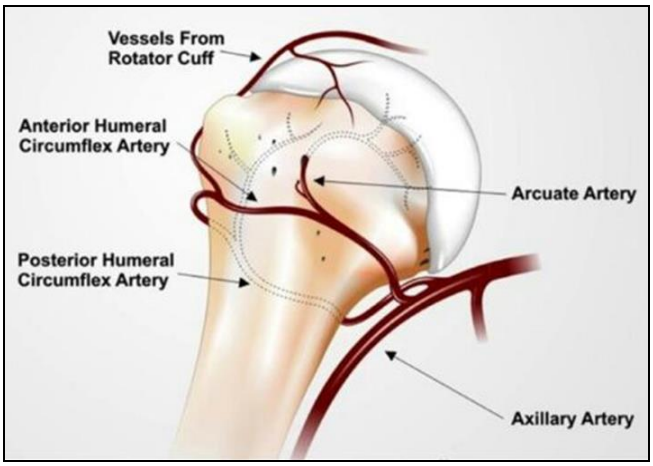

Fig 13: This figure illustrates the course of the anterior humeral circumflex artery supplying the humeral head via the anterolateral ascending branch and terminal arcuate artery.

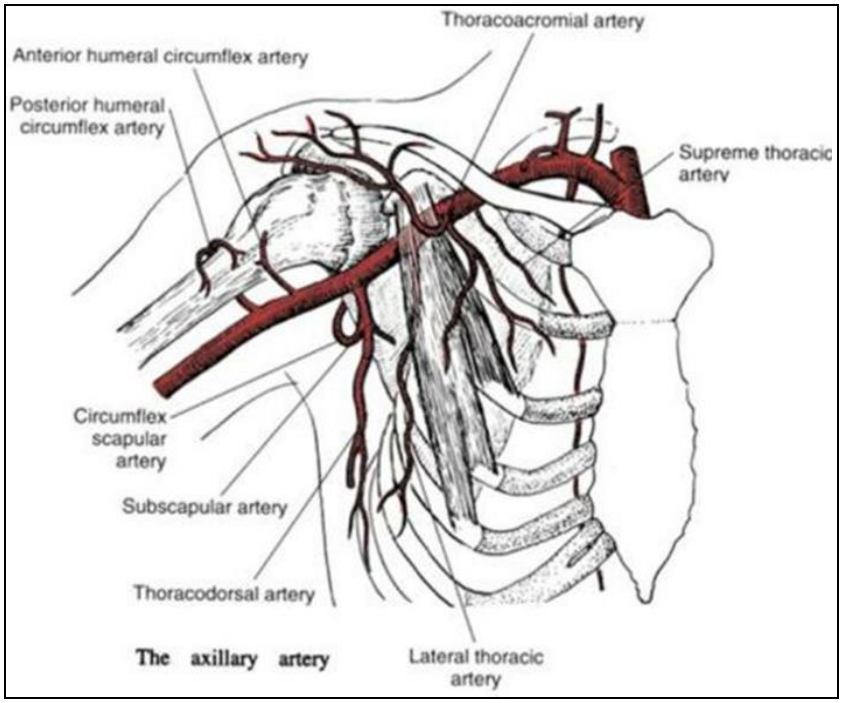

Fig 14: This illustration depicts the branches of the axillary artery including the anterior and posterior humeral circumflex arteries supplying the humeral head.

The deltoid splitting approach, provides for superior visualization of the postero-lateral aspect of the proximal humerus with minimal soft tissue dissection and gentle retraction, however theoritcally there has been described an increased risk of injury to the axillary nerve. We have adopted the MIPPO technique, via the antero-lateral deltoid splitting approach which involves making mini skin incisions for our series of proximal humeral fracture fixations. This approach has been advocated by many in the recent studies [11-14]. This technique leads to minimal soft tissue injury, reduced postoperative pain and improved functional outcomes. MIPPO allows for the visualization of the axillary nerve and the plate can be safely slid under it, to prevent the nerves impailment.

Results

Table 1: Age and sex distribution of proximal humerus fractures.

Age (in years)	'n'	Percentage	Male	Female
50-54	5	11.11	2	3
55-59	9	20.00	3	6
60-64	19	42.22	6	13
65-69	12	26.67	4	8
Total	45	100	15 (33.33%)	30(66.67%)

Table 2: Mechanism of injury.

Mode of injury	'n'	Percentage	Male	Female
Slip and fall	36	80%	14	22
RTA	9	20%	1	8
Total	45	100%	15	30

Table 3: Fracture type distribution according to NEER classification of proximal humerus fractures.

Neer Fracture type	Two part	Three part	Four part
N	8	27	10
Sex	M4, F4	M6, F21	M5, F5
Percentage	17.78%	60.00%	22.22%

Table 4: Time elapsed between surgery and surgical intervention.

Time elapsed in days	Male 'n'	Female 'n'	Total 'n'
Day 0-1	2	6	9
Day 2-3	3	2	5
Day 4-5	2	4	6
Day 5-6	1	5	6
Day 7-8	1	6	7
Day 9-10	5	7	12
Total	15	30	45

Table 5: Cases for which autologous bone graft was done.

Male n (%age)	Female n (%age)	Total n (%age)
4 (8.88%)	5 (11.12%)	9 (20%)

Table 6: Time taken for radiological evidence of bone consolidation.

Time taken in weeks	Male 'n'	Female 'n'	Total 'n'	Percentage
10-11	3	5	8	17.77%
12-13	9	19	28	62.22%
14-15	2	4	6	13.34%
16-17	1	2	3	6.67%
Total	15	30	45	100%

Table 7: Constant Murley Shoulder Score.

Sex	Score >30 Poor	Score 21-30 Fair	Score 11-20 Good	Score <11 Excellent	Total 'n'
Male 'n'	1	7	6	1	15
Female 'n'	1	13	12	4	30
Total	2	20	18	5	45
Percentage	4.44%	44.45%	40%	11.11%	100%

Table 8: Complications.

Complications	'n'	Percentage
Humeral head collapse	1	2.22%
Hardware penetration	1	2.22%
Impingement	2	4.45%
Varus collapse	1	2.22%
AVN	1	2.22%
Total	6	13.33%

A total of 45 patients qualified for the study in strict adherence to our inclusion criteria. According to the age and sex distribution, in our series 42.22% (n=19) of patients were in the age group 60-64 and this was followed by 26.67% (n=12) in the age group 65-69. 33.33%(n=15) of patients in our series were male and remaining 66.67% (n=30) of the patients were female. With regard to the mechanism of injury 80% (n=36) of patients were injured by simple slip and fall from standing height and 20% (n=9) were injured by RTA. 60% (n=27) of fractures were of NEER type three part followed by 22.22% (n=10) which were of NEER type four part. The average time elapsed between injury and surgery was 4.2 days (range: 1-10 days). 20% (n=9) of patients required autologous grafting from ipsilateral iliac crest. All of these cases were of type NEER four part (male-4, female-5). The average duration of surgery was 85 minutes (range: 75-110 minutes) and the average blood loss was 90ml (range: 75-110 ml). The average period for radiological bone healing was 12.67 weeks (range: 10-17 weeks). As per the Constant Murley Shoulder Score, 11.11% (n=5) had excellent, 40% (n=18) had good and 44.45% (n=20) had fair outcomes. There was 4.44% (n=2) of poor outcome in our series. We had 13.33% (n=6) of complication of which 4.45% (n=2) were probably avoidable iatrogenic because of proximal implant fixation, causing impingement and 2.22% (n=1) case had varus collapse. We also had 2.22% (n=1) each of humeral head collapse, hardware penetration and AVN as complications. It is these 2 patients with varus collapse and another with AVN, who had a poor outcome in the Constant Murley Shoulder Score. The average follow-up period was 15.8 months (range: 10 to 27 months).

Discussion

Proximal humerus fractures in the elderly is a steadily growing problem. It is most common type of fragility fracture accounting for nearly 6% of all adult fractures [15]. With the increase of life span and a growing gediatric population, their instances are on the rise. Surgical fixation with the locking compression plate is the gold standard for displaced proximal humerus fractures [16]. Locking compression plating system are best suited for fractures of osteoporotic bone [17].

To achieve fracture stability, the axial, tortional and three point bending forces have to be neutralized. The ability of the conventional plates to achieve this kind of stability is limited by the screw torque. Osteoporosis, cancellous bone, comminution and/ or pathological bone can prevent adequate thread purchase to allow for achieving adequate torque (1.5N) in order to achieve stability. This is exactly the case with the fragility fractures of the proximal humerus. Further with conventional plates, the excessive soft-tissue stripping which is required to improve the friction coefficient between the bone and plate, severely compromises on the vascular supply to the osseous fragment and the soft tissue. Locked plates have become an attractive alternative to conventional plates as they act as 'bridge plates' and significantly help preserve the already compromised blood supply to the fracture fragments.

Percutaneous fracture fixation is based on three basic principles namely percutaneous reduction, extra-periosteal plate placement and bridging fixation. In our series of 45 cases, 66.67% of patients were females and 33.33% were males. In other series, sex distribution was as follows:

Table 9: Sex distribution.

Study									
Sex	**Geiger *et al.*, [18]**	**Parmarksizoglu *et al.*, [19]**	**Kumar GN *et al.*, [20]**	**Korkmaz *et al.*, [21]**	**Kilic *et al.*, [22]**	**Chowdary *et al.*, [23]**	**Aksu *et al.*, [24]**	**Hitesh *et al.*, [27]**	**Our Study**
Male	8	10	35	16	13	54	33	7	15
Female	20	22	16	25	9	16	70	23	30

Thus, in our study two thirds of the patients were females, which presents the ratio of 2:1 similar to those studies reported by Parmaksizoglu *et al*., Aksu *et al*., Hitesh *et al*. and Geiger *et al*. This confirms our earlier comment that this pattern of fracture occurring in the elderly are more commonly seen in the elderly women, more so about the age of 60 years.

In the age distribution factor, since our inclusion criteria allowed us only to include patients in the age range 50-69 years, we had a preponderance of patients in the age group of 60-64 years (42.22%) followed by the age group 65-69 years (26.67%). This compares well with study of Geiger *et al*., [18] whose age mean was 60.7+/- 12.9 years and the study by Konard *et al*., [26] 62.9 +/- 15.7 years. The study by Aksu *et al*., [24] also had a mean age of 62 years. This establishes the fact that proximal humeral fractures are common in the age above 60 years.

The most common mode of injury was fall from standing height (80%) followed by RTA (20%). This compares well with the study of Geiger *et al*., [18] who reported similar mechanism in 75% of the cases in his series. In our series three part fractures dominated at 46.67% (n=14) of cases. Our study compares well with the study done by Geiger *et al*., [18] Hitesh *et al*. [27] and Chowdary *et al*. [23]

Table 10: The NEER fracture type distribution in other studies.

NEER Fracture Pattern	Two Part	Three Part	Four Part
Our study	8	27	10
Geiger *et al*., [18]	8	12	4
Erasmo *et al*., [25]	7	40	35
Parmaksizoglu *et al*., [19]	-	12	20
Kumar *et al*., [20]	8	15	23
Chowdary *et al*., [23]	22	38	10
Hitesh *et al*., [27]	10	14	6

Our average time lag between injury and surgery was 4.2 days (range: 0-10 days). The average duration of surgery was 85 minutes (range: 75-110 minutes) and the average blood loss was 90 ml (range: 75-110 ml). 20% (n=9) patients in our series, all having four part fracture, required autologous iliac crest bone grafting. This again highlights the fact that, when biological fixation with locking compression plate is opted for, the need for bone grafting decreases and the average blood loss is also minimised.

Thus, our duration 12.67 weeks of radiological healing was in tandem with other studies. Our outcome closely matches the findings of Hitesh *et al*., [27] and Kilic *et al*. [22]

Table 11: Time duration for radiological evidence of bony union in other studies.

Study	Average duration in weeks	Range in weeks
Our study	12.67 weeks	10-17
Kilic *et al*., [22]	13.6 weeks	10-20
Kumar *et al*., [20]	12 weeks	8-20
Chowdary *et al*., [23]	11.4 weeks	6-12
Hitesh *et al*., [27]	12.8 weeks	10-16

Table 12: The constant Murley score as reflected in various studies.

Study	Constant score outcomes			
	Poor	**Fair**	**Good**	**Excellent**
Our study	4.44%	44.45%	40%	11.11%
Kumar *et al*., [20]	9.80%	11.76%	25.49%	49.02%
Chowdary *et al*., [23]	8.57%	31.42%	40%	20%
Geiger *et al*., [18]	39.3%	3.6%	37.1%	20%
Erasmo *et al*., [25]	6.10%	20.73%	63.41%	9.7%
Hitesh *et al*., [27]	3.33%	40%	40%	16.67%
Parmaksizoglu *et al*., [19]	6.3%	25%	28.1%	40.6%

Table 13: Complications as encountered in various studies

Complication	Hitesh *et al.* [27]	Geiger *et al.*, [18]	Erasmo *et al.*, [25]	Parmaksizoglu *et al.*, [19]	Kumar *et al.*, [20]	Korkmaz *et al.*, [21]	Kilic *et al.*, [22]	Chowdary *et al.*, [23]	Aksu *et al.*, [24]	Our study
Humeral Head collapse	-	-	-	-	-	-	-	-	-	2.22
Hardware Penetration	-	-	-	-	1.96	2.4	-	8.57	-	2.22
Subacromial Impingmet	13.33%	21.4%	3.6	-	1.96	-	4.54	8.57	4.85	4.45
Varus Collapse	3.33%	-	4.8	-	7.84	7.3	9.09	-	8.73	2.22
AVN	-	7.2	12%	6.2%	-	-	9.09	-	-	2.22
Adhesive Capsulitis	-	-	-	-	-	-	9.09	1.42	-	-
Superficial Infection	-	-	1.2	-	-	-	-	2.86	-	-
Deep infection	-	-	-	-	1.96	-	-	-	0.97	-
Haematoma	-	-	-	-	-	-	-	2.86	-	-
Decreased radial Nerve sensation	-	7.2	-	-	-	-	-	-	-	-
Reoperation	-	28.57	-	-	-	-	-	-	-	-
Loosening of Locking head	-	3.6	-	-	-	-	-	-	-	-
Screw										
Non union	-	-	2.4	-	-	-	-	-	-	-
Displacement of Greater Tuberosity	-	-	-	-	-	2.4	-	-	-	
Reflex symp Dystrophic	-	-	-	-	-	-	9.09	-	-	-
Implant fracture	-	-	-	-	-	-	-	-	0.97	-
Total	16.66%	67.97%	24%	6.2%	13.72%	12.1%	40.9%	24.28%	15.52%	13.33%

Due to strict adherence to AO principles and methodological surgical approach, we have been able to keep our complication rates relatively low at 13.33% (n=6) Our complication rates were comparable to the study by Kumar *et al*., [20], Korkmaz *et al*., [21], Hitesh *et al*. [27] and that of Aksu *et al*., [24].

Conclusion

The points for consideration from this prospective study with regard to the major complications in this procedure are as follows:

Subacromial impingement: We need to ensure that the plate does not sit too proximally.

Varus collapse: We need to ensure that the medial column or the hinge is intact. We also ought to consider the use of cancellous allograft, suture augmentation and some plate contouring. Also, consideration must be given for infero-medial support screws.

Screw penetration: Careful C-arm image assessment in two perpendicular planes will ensure that primary intraarticular screw penetration does not occur. However, placement of screws that are too short of the subchondral bone are not advisable.

Proximal humeral fracture is a common periarticular fracture seen in the elderly. It is by far the commonest fracture of the shoulder. It is the second most common site of fracture in the upper limb after distal radius in the elderly. In the aged group with poor bone mineral density management of these osteoporotic fractures poses a surgical challenge to the operating surgeon. We concur with the study done by Hitesh *et al*. [27] that ORIF with PHILOS plate for proximal humerus fragility fractures in the aged has the advantages of accurate reduction, early mobilization and better fixation. It also helps reconstruct the comminuted irreducible fracture fragment. It is imperative to mention here that the deltoid splitting approach if done with adequate safety precaution, give good access to the proximal humeral posterior fragment, minimizes blood loss and gives impressive cosmetic scar healing. The present study concludes that the PHILOS plate provides for an excellent stable construct even in two to four part fractures. We also concur with Fazal *et al*., [28], whose study conclusively proved the efficacy of PHILOS plating for proximal humerus fragility fractures.

References

1. Cummings SR, Melton LJ. Epidemiology and outcomes of osteoporotic fractures. Lancet. 2002; 18;359(9319):1761-1767.
2. Mirco Pietri, Silvia Lucarini. The orthopaedic treatment of fragility fractures Clin Cases Miner Bone Metab. 2007; 4(2):108-116.
3. Jan-Magnus Björkenheim, Jarkko Pajarinen, Vesa Savolainen. Internal fixation of proximal humeral fractures with a locking compression plate A retrospective evaluation of 72 patients followed for a minimum of 1 year, Acta Orthopaedica Scandinavica. 2009; 75(6):741-745.
4. Klinik für Traumaand Sportmedizin, Wilhelminspital Wien, Austria. General principles for the clinical use of the LCP. Injury. 2003; 34(2):B31-42.
5. Geiger EV, Maier M, Kelm A, Wutzler S, Seebach C, Marzi I. Functional outcome and complications following PHILOS plate fixation in proximal humeral fractures.Acta Orthop Traumatol Turc. 2010; 44(1):1-6.
6. Cronier P, Piétu G, Dujardin C, Bigorre N, Ducellier F, Gérard Le concept de plaque verrouillée R. Revue de Chirurgie Orthopédique et Traumatologique, Supplement. 2010, 96(4):S90-S110.
7. Benjamin Buecking MD, Juliane Mohr MD, Benjamin Bockmann, Ralph Zettl MD, Steffen Ruchholtz MD. Deltoid-split or Deltopectoral Approaches for the Treatment of Displaced Proximal Humeral Fractures? Clin Orthop Relat Res. 2014; 472(5):1576-1585.
8. Dr. Rukesh Patel R, Dr. Nimish Patel P, Dr. Amit Nakum N, Dr. Shabbir Sabuwala K. Proximal humerus fractures

treated using the Deltoid-Splitting Approach gujarat medical journal. 2015; 70:1
9. Murray IR, Amin AK, White TO, Robinson CM. Proximal humeral fractures Current Concepts In Classification, Treatment And Outcomes. J Bone Joint Surg[Br]. 2011; 93B:1-11.
10. Constant Shoulder Scoring System. http://www.orthopedicscore.com/scorepages/constant_shoulder_score.html
11. Liu K, Liu PC, Liu R, Wu X. Advantage of minimally invasive lateral approach relative to conventional deltopectoral approach for treatment of proximal humerus fractures. Med Sci Monit. 2015; 21:496-504.
12. Isiklar Z, Kormaz F, Gogus A, Kara A. Comparision of deltopectoral versus lateral deltoid split approach in operative treatment of proximal humeral fractures. J Bone Joint Surg Br. 2010; 92:352.
13. Gardner MJ, Griffith MH, Dines JS, Briggs SM, Weil AJ, Lorich DG. The extended anterolateral acromial approach allows minimally invasive access to the proximal humerus. Clin Orthop Relat Res. 2005; (434):123-9.
14. Robinson CM, Khan L, Akhtar A, Whittaker R. The extended deltoid-splitting approach to the proximal humerus. J Orthop Trauma. 2007; 21:657-62.
15. Charles Court-Brown M, Ashima Garg, Margaret McQueen M. The epidemiology of proximal humeral fractures. Acta Orthopaedica Scandinavica. 2001; 72(4):365-371.
16. Handoll HH, Brorson S. Interventions for treating proximal humeral fractures in adults. Cochrane Database Syst Rev. 2015; 11;(11):CD000434. doi: 10.1002/14651858.CD000434.pub4.
17. Egol Kenneth AMD, Ong Crispin CBA, Walsh Michael PhD, Jazrawi Laith MMD, Tejwani Nirmal CMD, Zuckerman Joseph DMD. Early Complications in Proximal Humerus Fractures (OTA Types 11) Treated With Locked Plates Journal of Orthopaedic Trauma. 2008; 22(3):159-164. doi: 10.1097/BOT.0b013e318169ef2a
18. Geiger EV, Maier M, Kelm A, Wutzler S, Seebach C, Marzi I. Functional outcome and complications following PHILOS plate fixation in proximal humeral fractures. Acta Orthop Traumatol Turc. 2010; 44(1):1-6.
19. Parmaksizoğlu AS, Sökücü S, Ozkaya U, Kabukçuoğlu Y, Gül M. Locking plate fixation of three- and four-part proximal humeral fractures. Acta Orthop Traumatol Turc. 2010; 44(2):97-104.
20. Kumar GN, Sharma G, Sharma V, Jain V, Farooque K, Morey V. Surgical treatment of proximal humerus fractures using PHILOS plate. Chin J Traumatol. 2014; 17(5):279-84.
21. Korkmaz MF, Aksu N, Göğüş A, Debre M, Kara AN, Işiklar ZU. [The results of internal fixation of proximal humeral fractures with the PHILOS locking plate]. Acta Orthop Traumatol Turc. 2008; 42(2):97-105.
22. Kiliç B, Uysal M, Cinar BM, Ozkoç G, Demirörs H, Akpinar S. [Early results of treatment of proximal humerus fractures with the PHILOS locking plate]. Acta Orthop Traumatol Turc. 2008; 42(3):149-53.
23. Chowdary U, Prasad H, Subramanyam PK. Outcome of locking compression plating for proximal humeral fractures: a prospective study. J Orthop Surg (Hong Kong). 2014; 22(1):4-8.
24. Aksu N, Göğüş A, Kara AN, Işiklar ZU. Complications encountered in proximal humerus fractures treated with locking plate fixation. Acta Orthop Traumatol Turc. 2010; 44(2):89-96. doi: 10.3944/AOTT.2010.2313.
25. Erasmo R, Guerra G, Guerra L. Fractures and fracture-dislocations of the proximal humerus: A retrospective analysis of 82 cases treated with the Philos(®) locking plate. Injury. 2014; 45(6):S43-8.
26. Konrad G, Bayer J, Hepp P, Voigt C, Oestern H, Kääb M *et al*. Open reduction and internal fixation of proximal humeral fractures with use of the locking proximal humerus plate. Surgical technique. J Bone Joint Surg Am. 2010; 92(1)1:85-95**.**
27. PHILOS Plate Fixation for Displaced Two part to Four Part Fractures: A Prospective Study Dr. Hitesh Bhandari, Prof. Dr. Venkatachalam K Scholars Academic Journal of Biosciences. 2018; 61B):90-100.
28. Fazal. PHILOS plate fixation for displaced proximal humeral fractures. J Orthop Surg. 2009; 17(1):15-18.