



## International Journal of Orthopaedics Sciences

ISSN: 2395-1958  
IJOS 2018; 4(2): 300-307  
© 2018 IJOS  
www.orthopaper.com  
Received: 13-02-2018  
Accepted: 17-03-2018

**Ashraf Abd-Eldayem**  
Lecturer of Orthopedic Surgery  
Faculty of Medicine, Zagazig  
University, Egypt

**Hossam Fekry**  
Lecturer of Orthopedic Surgery  
Faculty of Medicine, Zagazig  
University, Egypt

**Nagy Fouda**  
Lecturer of Orthopedic Surgery  
Faculty of Medicine, Zagazig  
University, Egypt

### Surgical treatment of hallux valgus using chevron technique

**Ashraf Abd-Eldayem, Hossam Fekry and Nagy Fouda**

DOI: <https://doi.org/10.22271/ortho.2018.v4.i2e.44>

#### Abstract

**Background:** The great toe is affected by many congenital and acquired conditions including hallux valgus. Hallux valgus was first reported in 1856. Most patients with hallux valgus are young females. High heel shoes are extrinsic factors which are important in the development of hallux valgus. More than 130 procedures have been described in the treatment of hallux valgus. The chevron osteotomy is one of the most widely used distal metatarsal osteotomies for the treatment of this deformity in adults. The idea of the Chevron osteotomy is that, it is a V shaped horizontally oriented with lateral displacement of the head of the first metatarsal accompanied with release and balancing of the soft tissue structure on both sides of the joint.

**Patients and Methods:** Study include 36 patients, all were females. The mean age was 35 years. All patients have symptomatic bilateral hallux valgus deformity. Pain was the primary reason for surgery. Study designed for comparison of results of Chevron's osteotomy with fixation by 2 k-wires versus no fixation. Fifty percent of cases subjected for fixation and 50 percent with no fixation. No specific selection was performed.

**Results:** Evaluation of the results includes radiological and clinical observations. Assessment using the American Orthopaedic Foot and Ankle Society's hallux-metatarsophalangeal-interphalangeal scale was also done. Inter-metatarsal angle averaged 18° pre-operatively and 10° post-operatively, the corresponding values for hallux angle was 25° and 16° respectively. No complications of thrombophlebitis, non-union or avascular necrosis were recorded. Overall results show 94% as excellent or good results.

**Conclusion:** The Chevron osteotomy disclosed excellent relief of pain, good cosmetic correction and overall patient satisfaction. Stability and the technical ease make this procedure preferable for correction of moderate hallux valgus deformity.

**Keywords:** Surgical treatment, hallux valgus, chevron technique

#### Introduction

The treatment of hallux valgus deformity requires special consideration to obtain successful outcome. The distal metatarsal articular angle is of critical importance in this deformity. The goal of correction is to achieve a realigned first ray and preserve the congruent first metatarsophalangeal articulation. In patients with an increased distal metatarsal articular angle and congruent joint, the use of double and triple first ray osteotomies must be used to achieve satisfactory correction.

The great toe is affected by many congenital and acquired conditions including hallux valgus [45]. According to Mann and Coughlin [34] hallux valgus was first reported in 1856, giving more emphasis to medial exostosis genesis than to the complex deformity itself. Most patients with hallux valgus are young females who abhor an inelegant shoe [13]. Young patients with hallux valgus require pain relief and surgical methods that are capable of obtaining satisfying functional and cosmetic long-term results [56].

The wearing of constricting and high heel shoes are extrinsic factors which are important in the development of hallux valgus [20, 29]. Changing social footwear habits requires an awareness of the dangers of and damage done by ill fitting, tight shoes and that proper shoe fit is critical for good foot health [50]. Heredity is likely to be a major predisposing factor in some patients, with up to 68% of patients showing a familial tendency [9].

More than 130 procedures have been described in the treatment of hallux valgus [21].

**Correspondence**  
**Ashraf Abd-Eldayem**  
Lecturer of Orthopedic Surgery  
Faculty of Medicine, Zagazig  
University, Egypt

These procedures ranging from resection arthroplasty [23] to distal first metatarsal [22] or basal first metatarsal osteotomy [30]. There is no agreement about the best surgical technique to use to correct hallux valgus deformity [1]. Ideally, the most useful osteotomies correct the inter-metatarsal angle with minimal shortening and provide adequate stability of the osteotomy site [35].

Most metatarsal osteotomies are carried out either distally or proximally, although the degree of correction that can be obtained with a distal osteotomy is not as great as with a proximal osteotomy. As a rule, the distal osteotomy is used for the mild to moderate deformity, and the proximal osteotomy is used for the more severe deformity [35]. Recently it is reported that Chevron osteotomy is indicated for the treatment of moderate to severe hallux valgus deformities [46]. The preservation of dorsi-flexion in the first metatarso-phalangeal joint is important in women, as any reduction will affect their ability to wear high-heeled shoes [15].

Distal Chevron osteotomy was first performed by Austin in 1962, and first reported by Austin and Leventen in 1981 [2]. Their aim was to redirect the first metatarsal head to create a uniform contact at the first metatarso-phalangeal joint. The chevron osteotomy is one of the most widely used distal metatarsal osteotomies for the treatment of hallux valgus in adults [19].

The idea of the Chevron osteotomy is that, it is a V shaped horizontally oriented with lateral displacement of the head of the first metatarsal accompanied with release and balancing of the soft tissue structure on both sides of the joint.

### Patients and Methods

Study include 36 patients, 72 feet, all patients were females. The mean age was 35 years (range 18-54 years). All patients have mild to moderate symptomatic bilateral hallux valgus deformity. No other forefoot procedures were performed earlier. The hallux valgus angle was at least 25°, and that of the inter-metatarsal was at least 12°. All patients had painful hallux valgus that did not respond to conservative treatment within a minimum of 6 months. Non-operative management, including modification of shoe wear, non-steroidal anti-inflammatory medications, orthotic devices, or a combination of these methods, had failed in all patients. All patients had pain (ranging from moderate to severe) related to the hallux valgus deformity.

Any patient shows degenerative arthritis of the first metatarso-phalangeal joint, prior involvement of the hallux by surgery, rheumatoid arthritis, trauma, neurologic diseases affecting the lower extremities and additional simultaneous surgery were excluded. All patients were active in their jobs or managing their household's activities. No patient had disease causing immobility or functional impairment or disabilities.

Under general anesthesia, all patients underwent for Chevron's osteotomy and chelectomy were done for both sides in same sitting. Release for the conjoined tendons inserted onto the base of the lateral aspect of the proximal phalanx of the great toe were also done for all patient to gain re-alignment of the metatarso-phalangeal joint. Pain was the primary reason for surgery, although shoe fit and cosmetic were also considered. Contraindication for the procedure was arthritis, luxation or incongruent metatarso-phalangeal joint and poor mobility of the metatarso-phalangeal joint.

Study designed for comparison of results of Chevron's osteotomy with fixation by 2 k-wires versus no fixation. Fifty

percent of cases subjected for fixation and 50 percent with no fixation. No specific selection was performed rather than patients were arranged consecutively and to be one case from each group sequentially.

### Surgical Procedure

Slightly curved longitudinal skin incision between the medial exostosis and the extensor hallucis longus tendon. Care is taken to protect the sensory branch of the superficial peroneal nerve in this area. The nerve with its vascular bundle and extensor hallucis longus tendon is retracted. The capsule is exposed and a U shaped flap is created with its base attached to the proximal phalanx. The head of the first metatarsal is further exposed and the salcus on the articular surface is identified. An osteotomy is done starting from the salcus using an oscillating power saw with 5 mm wide blade, and excising the medial prominence and overgrowth is removed flush to the shaft of the first metatarsal bone in a vertical orientation.

Tenotomy of the conjoint tendon on the medial aspect of the metatarsal head is performed through the same incision. The apex of the V shaped osteotomy is marked in the head in a mid point that is not much near to the articular surface. The two arm of the V shaped osteotomy is done in a horizontal orientation using an oscillation power saw starting from the decided starting point and at angle of 60°. Horizontal direction allows stability of the osteotomy and also that broad cancellous contact surface allows fast healing. The osteotomy cut must be through both cortices, so that allows for lateral displacement of the metatarsal head. Translation of the metatarsal head laterally is done using thumb pressure. About one fourth of the width of the metatarsal is used as displacement of the metatarsal head to lateral direction to alignment of the big toe. Impaction on the osteotomy is performed manually and the protruding part of the proximal metatarsal shaft is sawed off with the oscillating power saw.

The U shaped capsular flap brought back to its bed and sutured back to bone under sufficient tension to overcorrect the valgus deformity slightly. The correction is maintained over the big toe until capsule is sutured back and closure for the subcutaneous tissue and skin is closed with a subcuticular absorbable suture. In the group where k-wires were used to fix the osteotomy, the k-wires 1.6 mm were used to fix the osteotomy before capsule closure. A non-adherent sterile dressing is placed. Dressing applied between the first and the second toe allowing a degree of over correction. Moreover, dressing applied between the lesser toes too. No cast is applied.

Post-operative care was performed same for all patients. Ambulation is started on second post-operative day with help of cane, bearing weight on the heel and lateral side of the foot. Most patients walk comfortably by the fifth post-operative day, and mobilization of the metatarso-phalangeal joint is begun. Dressing is done for the surgical wound after one week and re-done on the same fashion as post-operative way. All dressing was removed by the third week. Heel walking was allowed for the first 3 weeks in cast shoe for both feet, followed by full weight bearing in cast shoe for both feet for the next 3 weeks. Regarding the group who had fixed with k-wires, wires were removed at 3 weeks interval post-operatively at out-patient clinic.

Radiological examination was done routinely for all patients as pre-operative evaluation on standing position. Antero-posterior and lateral weight-bearing radiographs were made

preoperatively. The hallux valgus angle and the first intermetatarsal angle were measured. Measurement for the hallux valgus angle and the inter-metatarsal angle were carried out. Decision was taken to operate upon when the hallux valgus angle equal to 25° or more. Post-operative radiological follow up was done for all patients on second post-operative day, on 6 and 12 weeks. Moreover, final radiological examination was performed at one and two year post operative period.

The criteria for evaluation of the results include radiological

and clinical observations. All patients were asked for pain, cosmetic satisfaction, and shoe wear difficulties and recorded. Assessment using the American Orthopaedic Foot and Ankle Society's hallux-metatarsophalangeal-interphalangeal scale [25] was also done. This 100-point scale is based on a questionnaire combining subjective and objective data, including the clinical parameters of pain (40 points); function (45 points); and alignment (15 points). Table [1] shows this score system in details.

**Table 1:** The American Orthopedic Foot and Ankle Society Hallux Metatarsophalangeal-Interphalangeal Scale (Kitaoka *et al.* [25]).

<b>Points</b>	
<b>Pain:</b>	
None	40
Mild, occasional	30
Moderate, daily	20
Sever, almost always present	0
<b>Function:</b>	
<b>Activity limitations:</b>	
No limitations	10
No limitations on daily activities such as employment responsibilities but with limitation of recreational activities such as sports	7
Limited daily and recreational activities	4
Sever limitation of daily and recreational activities	0
<b>Footwear limitations:</b>	
Able to wear fashionable shoes, no insert required	10
Must wear comfortable shoes only, with or without insert	5
Must wear modified shoe and or brace	0
<b>MTP joint motion:</b>	
Normal or mild restriction (75° arc of motion)	10
Moderate restriction (30°-74° arc of motion)	5
Sever restriction (<30° arc of motion)	0
<b>IP joint planter flexion:</b>	
No restriction	10
Sever restriction, less than 10° planter flexion	0
<b>MTP-IP stability:</b>	
Stable in all directions	5
Unstable	0
<b>Callus related to MTP-IP:</b>	
No callus or asymptomatic callus	5
Symptomatic callus	0
<b>Alignment:</b>	
Good, hallux well aligned	15
Fair, some hallux malalignment, asymptomatic	8
Poor, obvious symptomatic malalignment	0
<b>Total</b>	<b>100</b>

Rating: excellent 100-90 points, good 89-80 points, fair 79-70 points, and poor <70 points

## Results

The angle between first and second metatarsals, inter-metatarsal angle, averaged 18° (range 14°-28°) pre-operatively and 10° (range 7°-18°) post-operatively, the corresponding values for hallux angle 25° (range 23°-32°) and 16° (range 12°-28°) respectively. In all patients the post-operative measured angled is decreased for both the inter-metatarsal and hallux angles. Figures 1-4 shows radiological results for 4 cases, 2 cases from each group.

No complications of thrombophlebitis, non-union of the osteotomy or avascular necrosis of the metatarsal head were recorded. Superficial and transient infection recorded in 3 feet in the group fixed with k-wires, which resolved after k-wire removal.

At 6 weeks post-operatively, all patients showed clinical and radiological union at osteotomy site. No significant shortening was recorded.

Ninety five percent of patients return to full activity in six to eight weeks. Patients had no restriction of footwear and were able to wear any kind of shoes at 12 weeks follow up. No patient needed custom-made shoes. The range of flexion-extension at the metatarso-phalangeal joint averaged 75°.

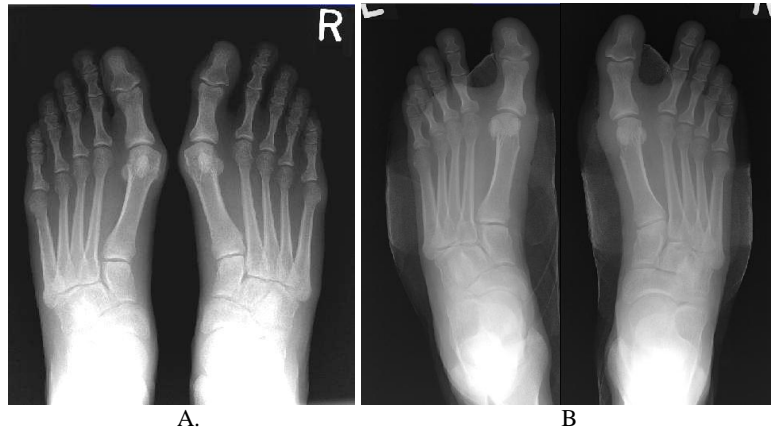Subjective patient's evaluation was done and in generally overall result was great satisfaction by most of the patients. Subjectively, the satisfaction rate in terms of symptom improvement, cosmetic appearance and function was over 90%. Table [2] shows the results of subjective evaluation for pain, cosmetic satisfaction and shoe wear difficulties.

**Table 2:** shows the subjective patient's (Nr. 36) evaluation for post-operative at 1 year period

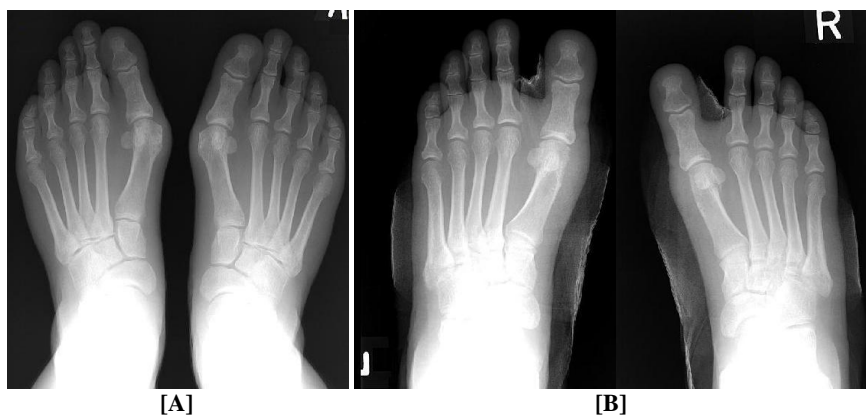
	Pain		Cosmetic satisfaction		Shoe wear difficulties	
	Pre-op	Post-op	Pre-op	Post-op	Pre-op	Post-op
None	0	32	0	30	0	28
Mild	10	4	3	6	7	6
Moderate	23	0	25	0	23	2
Sever	3	0	8	0	6	0

Assessment by the American Orthopaedic Foot and Ankle Society's hallux-metatarsophalangeal-interphalangeal scale shows that 24 patients (66.5%) points between 90-100 i.e.

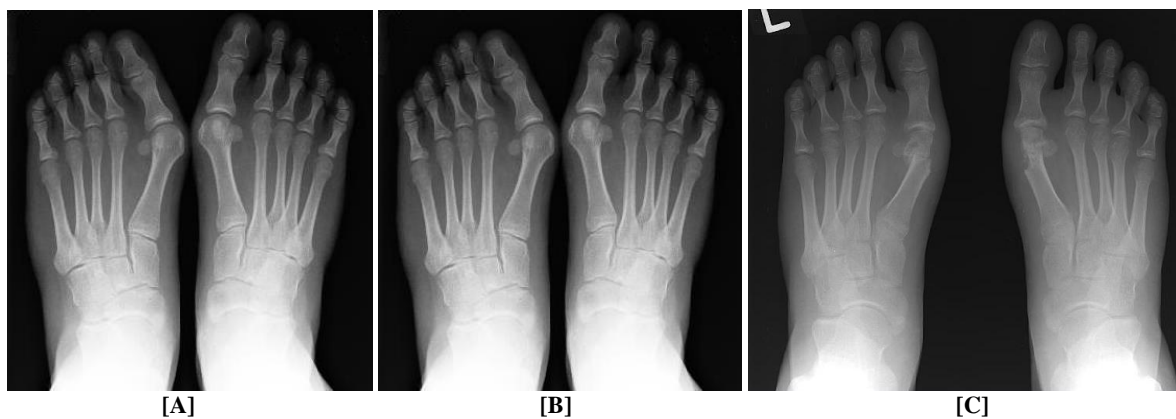
excellent rating, 10 patients (27.5%) points between 80-89 i.e. good rating, and 2 patients (6%) points between 70-79 i.e. fair rating. Overall results show 94% as excellent or good rating.



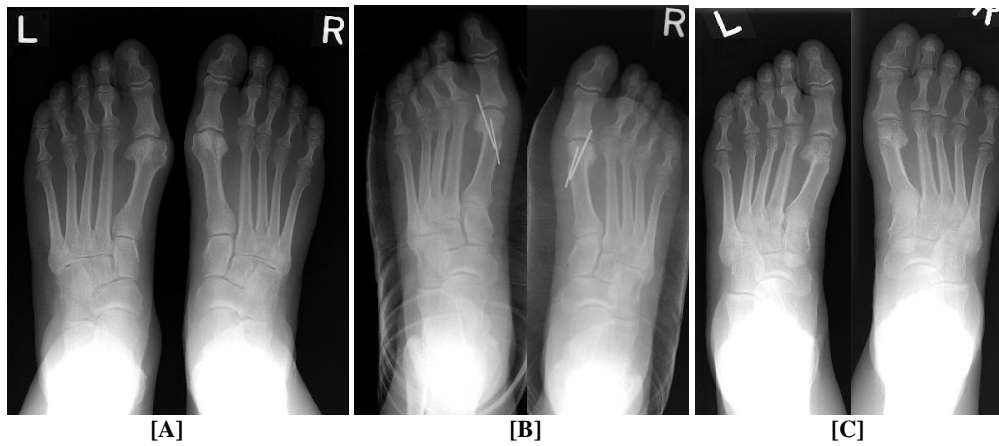
**Fig 1:** Shows 39 years old female patient, no k-wires fixation used, [A] per-operative AP view shows hallux angle of 27° and inter-metatarsal angle of 13° [B] post-operative measures as 12° and 10° respectively



**Fig 2:** Shows 33 years old female patient, no k-wires fixation used, [A] per-operative AP view shows hallux angle of 29° and inter-metatarsal angle of 14° [B] post-operative measures as 14° and 11° respectively



**Fig 3:** Shows 20 years old female patient, with k-wires fixation, [A] per-operative AP view shows hallux angle of 35° and inter-metatarsal angle of 18° [B] post-operative measures as 14° and 12° respectively, and [C] one year follow up measures 18° and 11° respectively



**Fig 4:** Shows 48 years old female patient, with k-wires fixation, [A] per-operative AP view shows hallux angle of 25° and inter-metatarsal angle of 13° [B] post-operative measures as 18° and 9° respectively, and [C] one year follow up measures 16° and 8° respectively.

## Discussion

Idea of Chevron osteotomy is to have adequate stability to allow for early ambulation without cast [2]. This was in mind as a target throughout this study. McBride [37] was first to mention the important role of the contracted muscles for the conjoined tendons inserted onto the base of the lateral aspect of the proximal phalanx of the great toe. He also recommends releasing these tendons which will allow restoration of the normal alignment of the metatarso-phalangeal joint. All patients in this study were subjected for this release in which re-alignment wererestored and maintained. It has been recognized that metatarsal osteotomy alone is insufficient to correct the entire deformity. A distal soft-tissue procedure must be added, including release of the lateral soft-tissue contracture. This release involves the adductor hallucis from the proximal phalanx [35]. Johnson *et al.* [17] in a comparison study for results of Chevron and modified McBride bunionectomy reported that Chevron osteotomy resulted in a statistically significant greater correction of the intermetatarsal angle than did the McBride bunionectomy. Kura *et al.* [28] studied on ten normal fresh frozen cadaveric foot specimens the role of the medial capsule and the transverse metatarsal ligament in hallux valgus deformity. They show the importance of the medial capsule in hallux valgus deformity and that the transverse ligament did not contribute substantially to cause the deformity. Tightening of the medial capsule was a part of the procedure in this series.

No casting is necessary as reported by Austin and Leventen [2], this was same procedure done in this series. Previously described basal and distal metatarsal osteotomies may be technically difficult and have inherent disadvantages, including shortening of the first metatarsal, stiffness of the first metatarso-phalangeal joint, and non-union at site of the osteotomy [15]. Chevron osteotomy, when done correctly, does not result in recurrence of the deformity and that significant complication is rare [2]. The surgical technique is straightforward, but careful attention to detail is necessary to obtain consistent and satisfactory results [15].

Mitchell osteotomy was reported in 1945 and was popularized for long period [12, 38]. This osteotomy is technically complex with many potential problems regarding displacement and instability [18]. Johnson *et al.* [18] concluded that Mitchell osteotomy is a good but technically difficult operation, whereas the Chevron osteotomy is a good but technically easy procedure. As the osteotomy site in case of Chevron osteotomy is located in a cancellous bone it solidifies more quickly than in Mitchell osteotomy [18]. Kinnard and Gordon [24] in a comparison study between Chevron and Mitchell

osteotomies for correction of hallux valgus deformity observed a better correction of the angle between the first and second metatarsals by the Mitchell osteotomy and a tendency to loose the correction in the immediate postoperative period for the Chevron osteotomy. However, no clinical superiority could be demonstrated, nor did patient satisfaction differ in the two techniques. They conclude that these two procedures give essentially equivalent results. Lewis and Feffer [31] reported that post-operative pain is less after Chevron osteotomy than after a conventional Mitchell procedure, and that the patients are quite comfortable by the second post-operative day and usually begin walking. Patients in this series were comfortable as first day post-operative and they start walking also.

Wilson osteotomy was first reported in 1963 [55]. Schemitsch and Horne [47] describe it as a technically straightforward, effective, and predictable method of treatment of hallux valgus. Holstein and Lewis [14] reported second metatarsalgia in 17 of their 98 cases operated with Wilson osteotomy due to shortening of the first metatarsal, Chevron osteotomy do not carry that risk as it is considered as displacement osteotomy is transverse plane. Gill [8] reported that shortening is less likely to occur with Chevron osteotomy compared with some other distal osteotomies.

Klosok *et al.* [26] in a study comparing Chevron and Wilson metatarsal osteotomy reported that the patients in the chevron group returned to work earlier and mobilized faster. In this study patients return to daily activities within a week and to work in 6 weeks interval. In study carried out by Calder *et al.* [4] they compare fixation by screw versus suture fixation for Mitchell's osteotomy as a surgical options for correction of hallux valgus deformity in 30 patients. They concluded that the mean time for return to social activities after fixation by a screw was 2.9 weeks and to work 4.9 weeks, which was significantly earlier than those who had stabilization by a suture, 5.7 and 8.7 weeks, respectively. In this series there was no difference in return to social activities, 2 weeks, and back to work or normal daily activities, 6 weeks. Rather those with suture fixation patients were even more comfortable.

Johnson *et al.* [16] used double osteotomy for the first metatarsal to correct the hallux valgus deformity. They had reported stiffness of the first metatarso-phalangeal joint as the main disadvantage of this procedure. No joint stiffness recorded in this study. Trnka *et al.* [52] reported dorsi-flexion of the first metatarsal as a complication after proximal metatarsal osteotomies. This complication was not recorded in this series. Horne *et al.* [15] perform 90° as an angle between the two arms of the V shaped osteotomy as they had found

that if a 60° angle is used, performance of the osteotomy through the dorsal cortex of the metatarsal is difficult. In this study 60° was used with no difficulties encountered.

Pelet [39] reported that poor results are due to failure to observe the proper indications, or to failure in performing the operative technique properly. In this study the utmost care was taken in selection in the cases indicated for Chevron osteotomy and care was undertaken during all steps of the operative procedure.

Avascular necrosis of the first metatarsal head is a recognized complication of the distal first metatarsal osteotomies [36]. Horne *et al.* [15] reported in nine out of 76 feet (12%) as evidence of avascular necrosis of the first metatarsal head but this did not affect the clinical results. No evidence of avascular of the metatarsal head was recorded in this series. Other studies did not report that also after Chevron osteotomy [8, 11, 18, 27, 40, 43, 54]. Some studies reported that patients underwent for corrective surgery for hallux valgus are at a low risk for venous thrombosis following the surgical procedure [42]. The prevalence of avascular necrosis can be minimized by limiting soft-tissue stripping [35]. Kuhn *et al.* [27] reported that no risk of avascular necrosis and that adductor tenotomy and lateral release could be done safely. Mann and Donatto [33] reported in four feet out of 23 feet, exhibited postoperative radiographic changes that could be construed as avascular changes, but there was no collapse noted, nor were there clinical symptoms of avascular necrosis. Green *et al.* [10] believe that avascular necrosis of the first metatarsal head is an infrequent complication following distal Chevron osteotomy. Jones *et al.* [19] studied the vascular supply to the first metatarsal head and found that vascular networks were preserved when the osteotomy was done properly. Also, an extensive plantar and plantar lateral network of vessels provided circulation to the head. These findings explain reason of no avascular necrosis recorded in this study and also in other studies [8, 11, 18, 27, 40, 43, 54].

Radl *et al.* [42] use fixation by k-wires and they removed it after 4 weeks post-operatively. Fifty percent of patients in this series were also fixed with k-wires but removed at 3 weeks interval. No recorded infection whether with or without use of k-wire fixation in this study. Other studies used bioabsorbable pin for better holding the osteotomy [5, 41]. Although, there was no need for removal, but a giant cell granuloma developed in 5% of their cases, which necessitates debridement. Mancuso *et al.* [32] reviews 500 cases operated by different distal metaphyseal osteotomies and they reported up to 11% of their patients experienced pin irritation, 1.4% of cases reported as pin site infection and which half of them required incision and drainage. Gill *et al.* [7] also used bioabsorbable pins to fix the osteotomy site for Chevron osteotomy in a comparison to the traditional k-wires in 144 feet, 74 feet with bioabsorbable pins and 70 with k-wires. Osteolysis, which is frequently found in association with bioabsorbable implants and was observed in 8% of this group. However, the osteolysis was a radiographic observation only, it was not associated with clinical complications, and it was no more frequent than that seen with traditional K-wires. No difference between both groups with regard to the prevalence of complications or the stability of fixation. The group fixed by k-wires in this study report no complication, rather than irritation from the projecting end of the k-wire through the skin, which is disappears by the third week post-operatively where k-wires were removed. No such complaint reported by the other group upon suture was used instead of the k-wires.

Chevron osteotomy located in a metaphyseal region with high

chance of union. Other diaphyseal osteotomy requires stabilization with a lag screw, because it is unstable and because bony union of an osteotomy of the diaphysis is not as favorable as that of the metaphysis [39].

In 50% of cases in this series no fixation is used at the osteotomy site and results were excellent radiological and clinical union. The capsule-periosteal flap attached to the metatarsal shaft and this gives stability. This also reported in earlier studies and same conclusion was reported [49, 53].

Crosby and Bozarth [6] in a comparison study of temporary K-wire fixation, Herbert Whipple screw fixation, versus no osteotomy fixation was performed on distal chevron osteotomies for hallux valgus deformities. The overall results show no significant difference for different ways of fixation versus no fixation. Same conclusion was draw up in this study.

For long follow up period, Schneider *et al.* [48] reviewed 112 feet with a minimum follow-up of ten years following Chevron osteotomy. They reported excellent clinical results following Chevron osteotomy not only proved to be consistent, but showed further improvement over a longer follow-up period.

The chevron procedure resulted in an overall satisfactory improvement of symptoms, function, and cosmesis [33], this was concluded also in this study. Tranka *et al.* [51] reported their results at two and five years of follow up post Chevron osteotomy. At these two follow-up periods, the chevron osteotomy was found to be a reliable procedure for the correction of mild and moderate hallux valgus deformity, and outcome did not differ on the basis of age. In this study follow up was up to two years and have same conclusions.

The forefoot is probably the part of the body which is exposed to the heaviest mechanical stresses [3] and Chevron osteotomy is one of the most osteotomy that carries great mechanical stability. Chevron osteotomy technically is easier and intrinsically more stable to dorsiflexion than other osteotomies [44].

Radiographic assessment of the correction of hallux valgus may bear no relation to clinical results [15]. Most studies assessment based on clinical outcome. Evaluation of the results in this study based on the American Orthopaedic Foot and Ankle Society's hallux-metatarsophalangeal-interphalangeal scale [25]. Also, on subjective questionnaire regarding pain, cosmetic satisfaction and shoe wear difficulties.

The main indication for surgical option in this series was pain. This was also reported in several other studies [2, 13, 16, 18].

## Conclusions

The Chevron osteotomy disclosed excellent relief of pain, good cosmetic correction and overall patient satisfaction. The stability of the osteotomy, the technical ease makes this procedure preferable when osteotomy of the distal portion of the first metatarsal bone is used for correction of moderate hallux valgus deformity. This procedure is used to treat a mild to moderate deformity, i.e. hallux valgus angle of less than 30 degrees.

Results suggest that a capsuloperiosteal flap without using any internal fixation material is effective. Using the American Orthopaedic Foot and Ankle Society's hallux metatarsophalangeal-interphalangeal scale is useful and practical way for evaluation of the results.

## References

1. Maki G, Goran V, Ivan B. Surgical Treatment of

- Moderate Hallux Valgus: A Comparison of Distal Chevron Metatarsal Osteotomy With and Without Lateral Soft-Tissue Release; *Foot Ankle Spec*; 2017; 10(6):524-530.
2. Austin DW, Leventen EO. A new osteotomy for hallux valgus: A horizontally V displacement osteotomy of the metatarsal head for hallux valgus and primus varus. *Clin Orthop*. 1981; 157:25-30.
  3. Lee HJ, Chung JW, Chu IT, Kim YC. Comparison of distal chevron osteotomy with and without lateral soft tissue release for the treatment of hallux valgus. *Foot Ankle Int*. 2010; 31(4):291-5.
  4. Calder JD, Hollingdale JP, Pearse MF. Screw versus suture fixation of Mitchell's osteotomy: A prospective randomized study. *J Bone Joint Surg*. 1999; 81[B]:621-4.
  5. Caminear DS, Pavlovich R Jr, Pietrzak WS. Fixation of the chevron osteotomy with an absorbable copolymer pin for treatment of hallux valgus deformity. *J Foot Ankle Surg*. 2005; 44:203-10.
  6. Park HW, Lee KB, Chung JY, Kim MS. Comparison of outcomes between proximal and distal chevron osteotomy, both with supplementary lateral soft-tissue release, for severe hallux valgus deformity *Bone Joint J* 2013; 95-B:510-16.
  7. Neumann JA, Reay KD, Bradley KE, Parekh SG. Staple fixation for Akin proximal phalangeal osteotomy in the treatment of hallux valgus interphalangeus. *Foot Ankle Int*. 2015; 36:457-64.
  8. Gill LH. Distal osteotomy for bunionectomy and hallux valgus correction. *Foot Ankle Clin*. 2001; 6:433-53.
  9. Glynn MK, Dunlop JB, Fitzpatrick D. The Mitchell distal metatarsal osteotomy for hallux valgus. *J Bone Joint Surg*. 1980; 62[B]:188-91.
  10. Green MA, Dorris MF, Baessler TP, Mandel LM, Nachlas MJ. Avascular necrosis following distal Chevron osteotomy of the first metatarsal. *J Foot Ankle Surg*. 1993; 32:617-22.
  11. Hattrup SJ, Johnson KA. Chevron osteotomy: analysis of factors in patients' dissatisfaction. *Foot Ankle*. 1985; 5:327-32.
  12. Helal B. Surgery for adolescent hallux valgus. *Clin Orthop*. 1981; 157:50-63.
  13. Hawkins FB, Mitchell CL, Hedrick DW. Correction of hallux valgus by metatarsal osteotomy. *J Bone Joint Surg*. 1945; 27:387.
  14. Holstein A, Lewis C, Experience with Wilson's oblique osteotomy for hallux valgus. In Bateman, JE (ed.): *Foot Science*. Philadelphia, W.B. Saunders, 1976, 179.
  15. Horne G, Tanzer T, Ford M. Chevron osteotomy for the treatment of hallux valgus. *Clin Orthop*. 1984; 183:32-6.
  16. Johnson A, Georgopoulos G, Erikson M, Eilert R. Treatment of adolescent hallux valgus with the first metatarsal double osteotomy, The Denver experience. *J Pediatr Orthop*. 2004; 4:358-62.
  17. Johnson JE, Clanton TO, Baxter DE, Gottlieb MS. Comparison of Chevron osteotomy and modified McBride bunionectomy for correction of mild to moderate hallux valgus deformity. *Foot Ankle*. 1991; 12:61-8.
  18. Johnson KA, Cofield RH, Morrey BF. Chevron osteotomy for hallux valgus. *Clin Orthop*. 1979; 142:44-7.
  19. Jones KJ, Feiwell LA, Freedman EL, Cracchiolo A. 3<sup>rd</sup>: The effect of chevron osteotomy with lateral capsular release on the blood supply to the first metatarsal head. *J Bone Joint Surg*. 1995; 77[A]:197-204.
  20. Kato T, Watanabe S. The etiology of hallux valgus in Japan. *Clin Orthop*. 1981; 157:78-81.
  21. Kelikian H. *Hallux valgus, allied deformities of the forefoot and metatarsalgia*. Philadelphia and London, W. B. Saunders Co. 1965, p241.
  22. Keller JW. Distal first metatarsal displacement osteotomy. *J Bone Joint Surg*. 1974; 56[A]:923.
  23. Keller WL. The surgical treatment of bunions and hallux valgus. *N. Y. State J Med*. 1904; 80:741.
  24. Kinnard P, Gordon D. A comparison between Chevron and Mitchell osteotomies for hallux valgus. *Foot Ankle*. 1984; 4:241-3.
  25. Kitaoka HB, Alexander IJ, Adelaar RS, Nunley JA, Myerson MS, Sanders M. Clinical rating systems for the ankle-hindfoot, midfoot, hallux, and lesser toes. *Foot Ankle Int*. 1994; 15:349-53.
  26. Klosok JK, Pring DJ, Jessop JH, Maffulli N. Chevron or Wilson metatarsal osteotomy for hallux valgus. A prospective randomised trial. *J Bone Joint Surg*. 1993; 75[B]:825-9.
  27. Kuhn MA, Lippert FG, Phipps MJ, Williams C. Blood flow to the metatarsal head after chevron bunionectomy. *Foot Ankle Int*. 2005; 26:526-9.
  28. Kura H, Luo Z, Kitaoka H, An K. Role of medial capsule and transverse metatarsal ligament in hallux valgus deformity. *Clin Orthop*. 1998; 354:235-40.
  29. Lam SL, Hodgson AR. A comparison of foot forms among the non-shoe and shoe-wearing in Chinese population. *J Bone Joint Surg*. 1958; 40[A]:1058-62.
  30. Lapidus PW. Operative correction of the metatarsus primus in hallux valgus. *Surg. Gynecol. Obstet*. 1934; 58:183.
  31. Lewis R, Feffer H. Modified Chevron osteotomy of the first metatarsal. *Clin Orthop*. 1981; 157:105-9.
  32. Mancuso JE, Abramow SP, Bloom WB, Carioscia MP, Landsman MJ. Smooth Kirschner (K) wire fixation of distal metaphyseal osteotomy bunionectomies: a 10-year retrospective survey. *J Foot Surg*. 1992; 31:276-84.
  33. Mann RA, Donatto KC. The chevron osteotomy: a clinical and radiographic analysis. *Foot Ankle Int*. 1997; 18:255-61.
  34. Mann RA, Coughlin MJ. Adult hallux valgus. In: Mann RA, Coughlin MJ. *Surgery of the foot and ankle*. 7<sup>th</sup> ed. St. Louis: Mosby. 1999, 151-267.
  35. Mann RA. Disorders of the first metatarsophalangeal joint. *J Am Acad Orthop Surg*. 1995; 3:34-43.
  36. Mann RA. Editorial. *Foot Ankle*. 1982; 3:125.
  37. McBride ED. A conservative operation for bunions. *J Bone Joint Surg*. 1928; 10:735-739.
  38. Mitchell CL, Fleming JL, Allen R, Glenney C, Sanford GA. Osteotomy-bunionectomy for hallux valgus. *J Bone Joint Surg*. 1958; 40[A]:41.
  39. Pelet D. Osteotomy and fixation for hallux valgus. *Clin Orthop*. 1981; 157:42-6.
  40. Pochatko DJ, Schlehr FJ, Murphey MD, Hamilton JJ. Distal chevron osteotomy with lateral release for treatment of hallux valgus deformity. *Foot Ankle Int*. 1994; 15:457-61.
  41. Porter MD, Anderson MG. Results of bioabsorbable fixation of metatarsal osteotomies. *Am J Orthop*. 2004; 33(12):609-11.
  42. Radl R, Kastner N, Aigner C, Portugaller H, Schreyer H, Windhager R. Venous thrombosis after hallux valgus surgery. *J Bone Joint Surg*. 2003; 85[A]:1204-8.

43. Resch S, Stenstrom A, Gustafson T. Circulatory disturbance of the first metatarsal head after Chevron osteotomy as shown by bone scintigraphy. *Foot Ankle*. 1992; 13:137-42.
44. Robinson AH, Limbers JP. Modern concepts in the treatment of hallux valgus: Aspects of current management. *J Bone Joint Surg*. 2005; 87[B]:1038-45.
45. Sammarco J, Idusuyi O. Complications after surgery of the hallux. *Clin Orthop*. 2001; 391:59-71.
46. Sanhudo JA. Correction of moderate to severe hallux valgus deformity by a modified chevron shaft osteotomy. *Foot Ankle Int*. 2006; 27:581-5.
47. Schemitsch E, Horne G. Wilson's osteotomy for the treatment of hallux valgus. *Clin Orthop*. 1989; 240:221-25.
48. Schneider W, Aigner N, Pinggera O, Knahr K. Chevron osteotomy in hallux valgus. Ten-year results of 112 cases. *J Bone Joint Surg*. 2004; 86[B]:1016-20.
49. Singh SK, Jayasekera N, Nazir S, Sharif K, Kashif. Use of a simple suture to stabilize the chevron osteotomy: a prospective study. *J Foot Ankle Surg*. 2004; 43:307-11.
50. Thompson FM, Coughlin MJ. The High Price of High-Fashion Footwear. Instructional Course Lectures, The American Academy of Orthopaedic Surgeons. *J Bone Joint Surg*. 1994; 76[A]:1586-93.
51. Trnka H, Zembsch A, Easley M, Salzer M, Ritschl P, Myerson M. The Chevron Osteotomy for Correction of Hallux Valgus: Comparison of Findings After Two and Five Years of Follow-up. *J Bone Joint Surg*. 2000; 82[A]:1373-8.
52. Trnka H, Parks B, Ivanic G, Chu I, Easley M, Schon L *et al.*. Six first metatarsal shaft osteotomies, mechanical and immobilization comparisons. *Clin Orthop*. 2000; 381:256-65.
53. Us K, Yilmaz C, Ozdemir M, Ogun T. Stabilization of the Chevron procedure for hallux valgus deformity with a capsuloperiosteal flap. *J Foot Ankle Surg*. 1999; 38:2-7.
54. Williams WW, Barrett DS, Copeland SA. Avascular necrosis following chevron distal metatarsal osteotomy: a significant risk? *J Foot Surg*. 1989; 28:414-6.
55. Wilson JN. Oblique displacement osteotomy for hallux valgus. *J Bone Joint Surg*. 1963; 45[B]:552.
56. Zembsch A, Trnka H, Ritschl P. Correction of hallux valgus, metatarsal osteotomy versus excision arthroplasty. *Clin Orthop*. 2000; 376:183-94.