



ISSN: 2395-1958  
IJOS 2018; 4(2): 295-299  
© 2018 IJOS  
www.orthopaper.com  
Received: 10-02-2018  
Accepted: 14-03-2018

**Dr. Siddaram N Patil**  
Associate Professor, Department  
of Orthopaedics, Sri Devraj Urs  
Medical College, Tamaka, Kolar,  
Karnataka, India

**Dr. Prabhuling Reddy Patil**  
Assistant Professor, Department  
of Orthopaedics, Sri Devraj Urs  
Medical College, Tamaka, Kolar,  
Karnataka, India

## Prospective study of functional and radiological outcome of diaphysial fracture of femur in children, in age group of 5-15 years treated with, titanium elastic nail

**Dr. Siddaram N Patil and Dr. Prabhuling Reddy Patil**

**DOI:** <https://doi.org/10.22271/ortho.2018.v4.i2e.43>

### Abstract

To achieve the effectiveness of intramedullary fixation of displaced long bones shaft fractures in skeletally immature children using the TENS intramedullary nails.

**Patients and Methods:** The case records of 30 children in the age group of 5-15 years, who underwent fixation with titanium intramedullary nails because of long bones fractures were reviewed. The average age of the patients was 11.7 years, and mean follow-up was 41.3 months. Subjective satisfaction was assessed according to Flynn et al's criteria.

**Results:** All patients achieved complete healing at a mean of 7.5 weeks. Complications. Were recorded in 2(6.3%) patients and included, six entry site skin irritations, and two skin infections at the entry site. In a subjective measure of outcome at follow-up, 89% of patients were very satisfied and 11% satisfied; no patients reported their outcome as not satisfied. The implants were removed at a median time of six months.

**Conclusion:** Elastic Stable Intra-medullary Nailing, TENS is the method of choice for the paediatrics patients, because it is minimally invasive and shows very good functional and cosmetic results. It allows an early functional and cast-free follow-up with a quick pain reduction.

**Keywords:** Titanium Elastic Nail (TEN), femur, shaft of femur

### Introduction

Elastic nailing for children was first performed on a child with Vitamin D resistant rickets in Nancy, France in 1977. The technique spread fairly rapidly for the stabilization of long bones, mostly in multiple trauma. The idea of using relatively low diameter intramedullary rods to stabilize long bone fractures, in particular those of the femoral shaft, was of course not new, German school had been using condylocephalic nailing of intertrochanteric fractures since 1950, Rush pins were being used for over three decades then [41]. In 1970, Ender described the nailing of trochanteric fractures using three pins that were smaller and more flexible than the previously described devices inserted through the medial femoral condyle and spread out in the femoral neck [40]. Prevot, the professor in Nancy at the time of the development of elastic nailing, wrote that several factors had proven important in the development of the technique [15, 41].

1. Dissatisfaction of children with the prolonged conservative management of femoral shaft fractures.
2. Difficulties with schooling and psychological problems with prolonged immobilization
3. Prevot's personal conviction that open reduction and plate fixation was an unsuitable and unphysiological method for fracture fixation in a growing bone.
4. The new vision and drive to create a fracture stabilization system particular to children.
5. Technological advances to permit such development mainly (a) materials with a suitable tensile strength and modulus of elasticity and (b) modern image intensification with low pulse dosage and a memory.

### Biological Property

One of the principles of ESIN which led to its success is the respect that it has for the growing bone and the nature of children's fractures.

### Correspondence

**Dr. Prabhuling Reddy Patil**  
Assistant Professor, Department  
of Orthopaedics, Sri Devraj Urs  
Medical College, Tamaka, Kolar,  
Karnataka, India

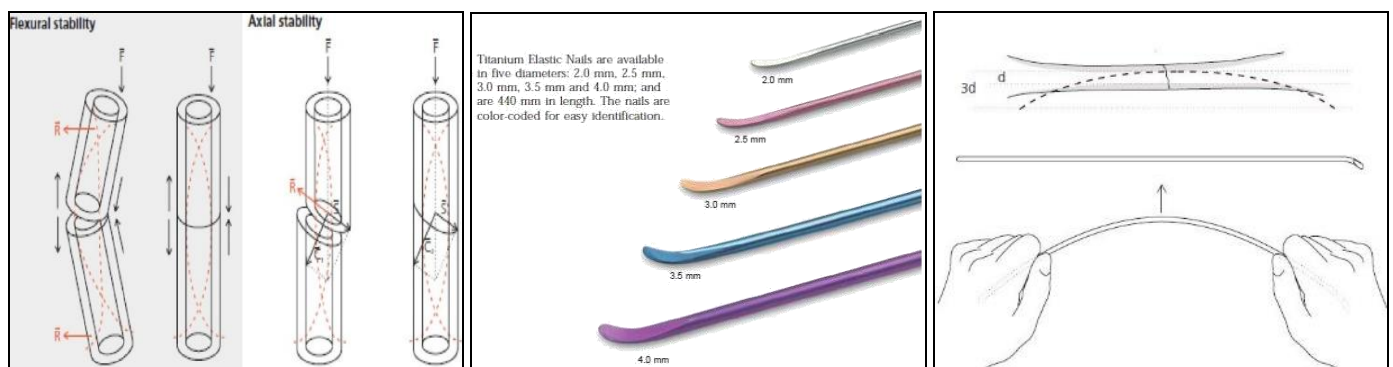
The periosteum of a child is a much thicker and the periosteal circulation is an important source of cortical blood supply. Cutting the periosteum, or stripping it, has a deleterious effect on healing in terms of speed of healing, callus formation and bone length. In ESIN minimal periosteal stripping is achieved by a minimally invasive approach and in most cases a closed reduction. The elasticity of the construct allows for the ideal of micro-motion for rapid fracture healing<sup>42</sup>. Elastic nailing reduces diaphyseal and metaphyseal fractures satisfactorily in terms of length, rotation and alignment and any inaccuracy of reduction, particularly displacement are corrected as children's fractures remodel after healing.

**Biomechanics**

ESIN is a successful method for treating children's fractures because they heal rapidly in less than half the time of an equivalent adult fracture [43]. The elastic nails whether constructed of titanium alloy or of stainless steel, are adequately strong to maintain the reduction for the length of

time required. In the insertion of elastic nails, each nail is inserted to achieve a 3-point fixation of the bone. The nails are pre-curved to achieve this and in general the pre-curve that should be put on a nail should be approximately three times the diameter of a long bone at its isthmus. Two nails are used, identically pre-curved and inserted opposite each other to produce a perfectly balanced construct that maintains alignment.

**Double-frame model:** It illustrates the principle of the ESIN technique. The inner frame consists of the medullary canal containing the elastic flexible nails and the bone, Where-as the muscles on the anterior/posterior, medial/lateral sides form the outer frame. Both frames have to be functional in order to provide sufficient stability for reducing and maintaining fracture reduction. In the tibia, the application of the principle of ESIN is more demanding because of the missing outer frame, and muscle coverage on the medial and lateral sides.



**Fig 1:** Stability of Tens  
F-force acting, R-restoring force of the nail, S-shear force, C-compressive force

**Material and Methods**

A study of 30 cases of Titanium Elastic Nailing System (TENS) for long bone fractures where, conducted, taking the prospective cases from July 2016 to Feb 2018. The study was done at RLJ hospital attached to Sri Devaraj Urs Medical College, Kolar, Karnaka.

**The inclusion criteria**

1. All long bone fractures treated with Titanium Elastic Nailing System (TENS).
2. Follow up of minimum six months.
3. With or without Polytrauma/multiple injuries.

**The exclusion criteria**

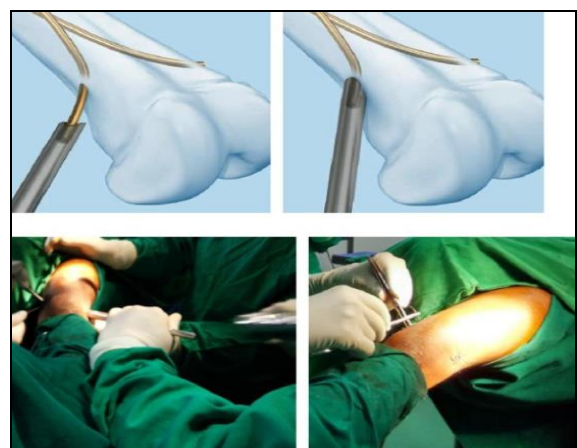
1. Pathological fractures eg: osteogenesis imperfecta
2. Fractures at proximal and distal ends of the long bones.
3. Unstable fractures like long spiral and comminuted fractures.
4. Severe Grade III Gustilo open fractures.

**Patients were screened to find their eligibility for our study, and Indications for TENS are**

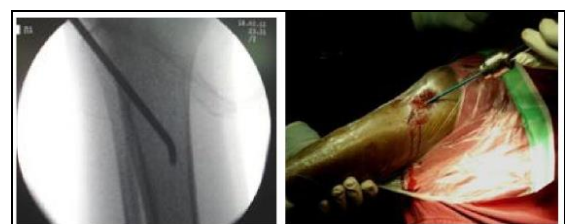1. All long bones fractures in children aged between 5 and 16 years.
2. Fracture clavicle, forearm in adults.
3. All long bone fractures in Polytrauma / Multiple injuries.
4. Fractures with head injury and fractures in paralysed limbs.
5. Long bone fractures where TENS gives acceptable stability.

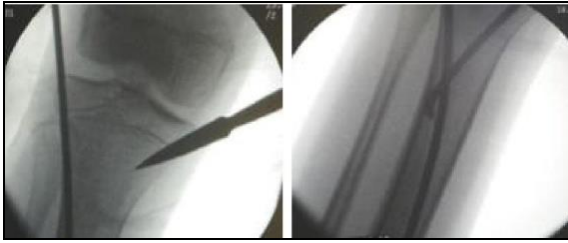
**Preoperative Planning: Nail size**

Nail Width: The diameter of the nail is selected as per,  
A) Flynn et al's formula: Diameter of nail= Width of the narrowest point of the medullary canal on AP Nail occupies at least 1/3<sup>rd</sup> or 40% of the Medullary canal.



**Femoral Entry Point**





**Tibial Entry point**

**Post-operative care**

- Patients were kept nil orally 4 to 6 hours post operatively
- IV fluids/blood transfusions were given as needed
- Analgesics were given according to the needs of the patient
- The limb was kept elevated over a pillow or BB splint as required.
- IV antibiotics were continued for 7 days and switched over to oral antibiotics on the 7th day and continued till the 14th day.
- Post operatively after 24 hours-Wound Inspection, Check X-ray to assess reduction and active static exercises/passive exercises/active neighbouring joint movement at the earliest
- Sutures were removed on the 14<sup>th</sup> postoperative day and patients were discharged.
- Patient was called for periodic follow up at 6 weeks, 8 weeks, 12 weeks, 6 months for clinical and radiological assessment.

**Follow Up**

Assessment done at 6, 12 and 24 weeks, at each follow up

patients are assessed clinically, radiologically and the complications are noted

**Clinical Assesment**

**1) Pain**

- a. present
- b. absent

**2) Range of movements**

**3) Measurement of limb length**—noted for shortening/lengthening

**4) Time of weight bearing**

- a. Partial weight bearing (in weeks)
- b. Complete weight bearing (in weeks)

**Radiological Assessment**

X-ray thigh full length with hip and knee joints-AP and lateral views

X-ray leg full length with knee and ankle- AP and lateral

Alignment: 1. sagittal/coronal angulation (in degrees-<10 or >10)

1. Minor angulation (< 10<sup>0</sup>-sagittal/coronal; <10<sup>0</sup> rotational malalignment) at final follow-up (24 weeks)
2. Minor leg length discrepancy(<2cm-shortening/lengthening) at final follow-up (24 weeks)
3. Inflammatory reaction to nails
4. Superficial infection at site of nail insertion
5. Delayed union

The final outcome based on the above observations is done as per Flynn’s criteria.

**Table 1:** Outcome according to Flynn's Criteria

Results Variable at 16 weeks	Excellent	Satisfactory	Poor
Limb-Length inequality	<1.0cm	<2.0cm	>2.0cm
Malalignment	5 degrees	10 degrees	>10 degrees
Unresolved pain	Absent	Absent	Absent
Other complications	None	Minor & resolved	Major & lasting

**Table 2:** Additional outcome variable in study

Variable	Excellent	Satisfactory	Poor
Range of Movement	Full Range	Mild Restriction	Moderate-Severe Restriction
Time of Union	8-12 weeks	13-18 weeks	>18 weeks
Unsupported weight bearing	8-12 weeks	13-18 weeks	>18 weeks

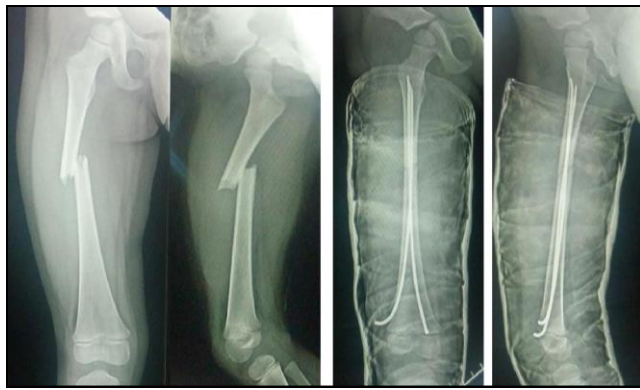**Statistical Analysis:** Descriptive statistics like numbers, percentages, average, standard deviations, were used. Data was presented in the form of tables and graphs wherever necessary. Inferential statistical tests like Chi-square and

Fisher’s exact probability test were applied to know the association between incidence of complications and clinical variables.

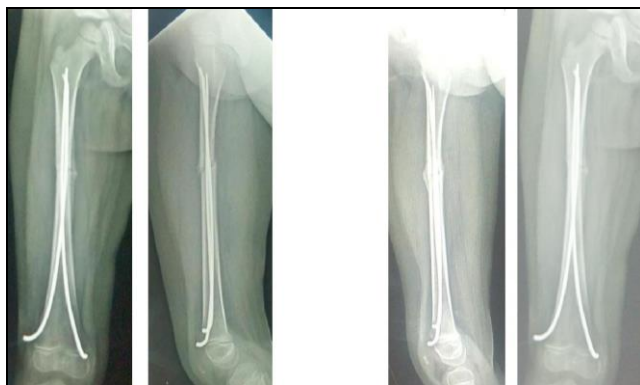**Table 3**

Insufficient reduction	Greater than 10° alignment defect in the coronal, sagittal or horizontal plane before onset of malunion.
Joint stiffness	Greater than 5° knee extension defect or greater than 20° hip or ankle range of motion
Malalignment	Greater than 10° angulation in any plane after bone consolidation.
Recurrent fracture	New fracture during follow-up at the same level as the primary
Surgical Revision	Any fracture-related surgical procedure following TENS, other than those to remove material
Delayed union	Failure to demonstrate complete union on X-rays taken after a specified time period following the fracture: 15 week for femur and tibia

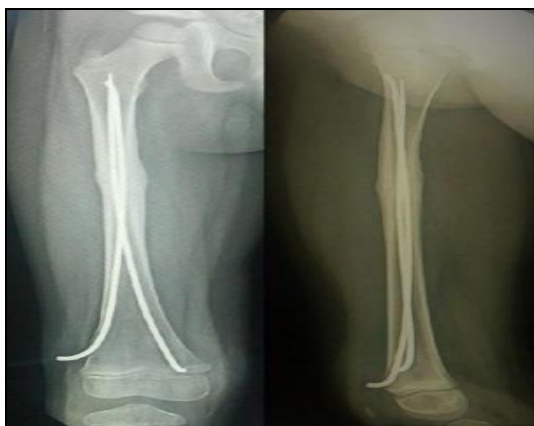**Functional outcome after TENS intramedullary nailing in Femur Fractures**



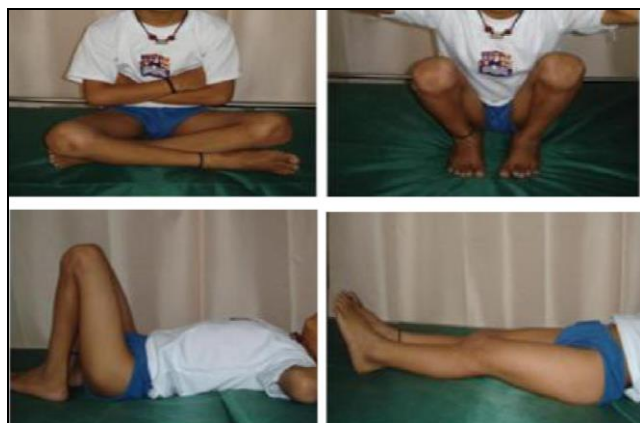Pre op Post op



6week follow up 12 weeks follow up



24 week follow up



Clinical pictures

Fig 1: Femur

**Results**

Study design: A prospective study on about 30 consecutive patients with diaphyseal fracture of femur meeting the inclusion and the exclusion criteria, admitted to RLJ hospital attached to Sri Devaraj Urs Medical College, Kolar, Karnataka

**Table 4: Age Distribution**

Age in years	Number of patients	Percentage %
5-8 years	4	2
9-12 years	16	30
13-15 years	10	28
Total	30	100

**Table 5: Gender Distribution**

Gender	Number of patient	Percentage %
Male	23	76
Female	7	40
Total	30	100

**Table 6: Mechanism of Injury**

Mode of injury	Number of patient	Percentage %
RTA	11	36
Self	13	44
Fall from Height	6	20
Total	30	100

**Table 7: Level of fracture**

Diaphysis of femur	Number of patients	Percentage %
Upper 1/3	6	20
Middle 1/3	16	30
Lower 1/3	8	30

**Table 8: Side effected**

Side effected	Number of patient	Percentage %
Right	21	70
Left	9	30
Total	30	100

**Table 9: Range Of Movement (Degrees)**

Range of movement	Number of patient	Percentage %
Full	27	90
Mild restriction	3	10
Medium restriction	0	0
Sever restriction	0	0
Total	30	100

**Table 10: Complication**

Comication	Number of patient	Percentage %
Nil	17	56
Mainor	13	44
Major	0	0
Total	30	100

**Discussion**

This prospective study was started with the objectives to study the functional and radiological outcome following surgical management of diaphyseal fractures of femur in children aged between 5-15 years by using Titanium Elastic Nailing System at Department of Orthopedic, of R L Jalappa Hospital and Research Center, Kolar, Karnataka.

Thirty consecutive cases which strictly followed inclusion criteria were included in the study after consent of the patient and legal guardian, preferably parents. Out of the total 30

cases, 23(76.6%) were boys and 7(23.3%) were girls with a mean age of 9.2 years. Most common mode of injury was self-fall/sports injury, accounting for 44% of cases, closely followed by RTA (36%) and least common was fall from height (20% of cases). All the cases were closely examined and x-rays were done and findings noted. Femur was effected in 13 cases (44%) and tibia in 17(56%) of cases. The most common pattern of fracture observed was transverse (46%), followed by oblique (34%), spiral and communitated patterns were seen 10% cases each. Majority of fracture were on right side (70%) and in the middle one-third on the bone (83%). All the cases were operated within 48 hours of trauma with an average time interval between trauma and surgery of 29.1 hours. The average operative time was 49.83 minutes with minimum time 30 minutes and maximum time of 60 minutes. The minimum nail size used in our study was 2.5mm and maximum size was 3.5mm. Post-op immobilization was done in 18 cases due to unstable fracture fixation with an average period of 2.23 weeks, non-weight bearing ambulation was started on post-op 2<sup>nd</sup> - 3<sup>rd</sup> day. Weight bearing as tolerated ambulation was started at the earliest. Average duration of stay in hospital was 2 weeks, after which patients were followed up at 6weeks, 12 weeks and 24 weeks clinically and with x-rays imaging. The average time till full weight bearing ambulation was 10 weeks.

Two cases, mid shaft fracture, had complete bone remodeling seen at 24 weeks, hence implant was removed at 24 weeks. Time for union for 22 cases (73.33%) was under 12 weeks and the maximum time taken for union was 15 weeks for a communitated femur midshaft fracture case, the mean time for union was 10 weeks. With an exception of 3 cases which had mild restriction of movement in knee joint, all the cases had active, full and pain-free range of movement of the adjacent joints.

Minor complications were observed in 6(43.33%) cases, none of the cases had major complications. Most commonly nail entry site pain/irritation was seen, in 2(33.33%) cases. Superficial infections were seen in 3 cases which were treated with antibiotic course. One case of limb length discrepancy was noted with <2 cm lengthening in femur and 2 cases of coronal plane angular deformity were observed with <10 degree of deformity. None of the cases reported sagittal plane deformity, rotational deformity, nail back out, sinking of nail in medullary cavity, any iatrogenic injuries and any major complications. The final outcome was evaluated as per Flynn's criteria, 23(76.66%) cases had an excellent outcome, 7(23.33 %) had satisfactory and none of the patient had a poor outcome.

At the end of our study it was concluded that Titanium Elastic Nailing for diaphyseal fracture of femur in age group 5 years to 15 years old children, is a safe, cost effective, physiological procedure with a relatively easy learning curve resulting in very few short term complications with mostly excellent outcomes irrespective of fracture location and pattern provided that the important biomechanical principles of TENS are followed.

### Conclusion

Based on the experience and results of our study, we conclude that Titanium Elastic Nail System surgical technique is a safe, simple, reliable and effective method for management of paediatric femoral diaphyseal fractures between the ages of 5 to 15 years. Titanium Elastic Nails gives elastic mobility promoting rapid union at fractures site and stability which is ideal for early mobilization as well as its physal protective

technique and design causes minimal disturbance of bone growth, hence TENS may be considered to be a protective and physiological method of treatment. TENS has definite advantages in terms of short duration of hospital stay, and early return to activity, acceptable bone healing time, good functional outcome and less incidence of complications. The surgical technique itself is easy to learn and implement with moderate need of equipment and surgical skills. Minimally invasive approach, shorter operative time, less blood loss, lesser radiation exposure resonates with idea of an ideal surgical technique. Overall experience in our study shows that Titanium Elastic Nailing for paediatric femur, diaphyseal fracture is a safe, cost effective, physiological procedure with a relatively easy learning curve resulting in very few short term complications with mostly excellent outcomes irrespective of fracture location and pattern provided that the important biomechanical principles of TENS are followed.

### References

1. Ligier JN, Metaizeau JP, Prevot J, Lascombes P. Elastic Stable Intramedullary Nailing of Nailing of Femoral Shaft Fractures in Children. *J Bone Joint Surg Br.* 1988; 70-B:74-7.
2. Barry M, Paterson JMH. Flexible intramedullary nails for fractures in children. *J Bone Joint Surg [Br].* 2004; 86-B:947-53.
3. Siddaram patil. Prospective Study in treatment of long bone fracture in children by Titanium Elastic Nailing stabilization. *Int J Biol Med Res.* 2014; 5(4):4479-4490.
4. Susanta Khuntia<sup>1</sup>, Sanjaya Behera, Bijaya Sadangi, Anil sahu, Prakash Mall, Diptish Sahoo *et al.* Elastic bone fractures- scope of elastic nails. *JEMDS*, 2016.
5. Aamer Nisar, Abhijit Bhosale. Complications of Elastic Stable Intramedullary Nailing for treating paediatric long bone fractures. *Journal of orthopaedics.* 2013; 10:17-24.
6. Lascombes P, Prevot J, Ligier JN, Metaizeau JP, Poncelet T. Elastic stable intramedullary nailing in forearm shaft fractures in children: 85 cases. *J Pediatr Orthop.* 1990; 10:167-171.
7. Lascombes P, Haumont T, Journeau P. Use and abuse of flexible intramedullary nailing in children and adolescents. *J Pediatr Orthop.* 2006; 26:827-834.
8. Metaizeau JP. Stable elastic intramedullary nailing for fractures of the femur in children. *J Bone Joint Surg Br.* 2004; 86:954-7.
9. Furlan D, Pogoreliæ Z, Bioèiæ M, Juriæ I, Budimir D, Todorijæ J *et al.* Elastic stable intramedullary nailing for pediatric long bone fractures: experience with 175 fractures. *Scand J Surg.* 2011; 100:208-15.
10. Flynn JM, Hresko T, Reynolds RA, Blasler RD, Davidson R, Kasser J. Titanium elastic nails for pediatric femur fractures e a multicentre study of early results and analysis of complications. *J Pediatr Orthop.* 2001; 21:4-8.
11. Lewallen RP, Peterson HA. Non-Union of long bone fractures in children, a review of 30 cases. *J Pediatr Orthop.* 1985; 5:135-142.
12. Mehlmam CT, Wall EJ. Injuries to shafts of the radius and ulna. In: Beaty JH, Kasser JR, eds. *Fractures in Children.* 6th ed. Philadelphia: Lippincott Williams & Wilkins, 2006.
13. Moroz LA, Launay F, Kocher MS. Titanium elastic nailing of fractures of the femur in children- Predictors of complications and poor outcome. *J Bone Joint Surg Br.* 2006; 88-B(10):1361-6.