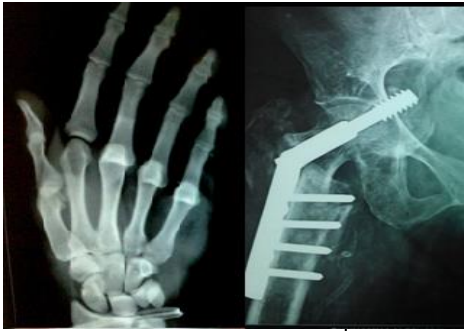

International Journal of Orthopaedics Sciences

ISSN: 2395-1958
IJOS 2018; 4(2): 328-333
© 2018 IJOS
www.orthopaper.com
Received: 21-02-2018
Accepted: 24-03-2018

Dr. Siddaram N Patil
Associate Professor, Department
Of Orthopaedics, Sri Devraj Urs
Medical College, Tamaka. Kolar,
Karnataka, India

Dr. Prabhuling Reddy Patil
Sr. Resident, Department Of
Orthopaedics, Sri Devraj Urs
Medical College, Tamaka. Kolar,
Karnataka, India

A study of 30 cases of titanium elastic nailing system (TENS) for long bones, and its clinical outcome

Dr. Siddaram N Patil and Dr. Prabhuling Reddy Patil

DOI: <https://doi.org/10.22271/ortho.2018.v4.i2e.49>

Abstract

Elastic stable intramedullary nails (ESIN) was popularized in 1980s in Nancy, France. Titanium is twice as elastic as steel and hence it resists permanent deformation of the nail which occurs during nail insertion. The versatility of the principle has widened the indications with time and experience. Conservative treatment had disadvantages like longer period of immobility, longer hospital stays, delayed rehabilitation, more malunions etc. Aggressive surgery in the form of plating and rigid nailing were not essential in children. Elastic nails have become the preferred treatment in children between five to sixteen years. ESIN can also be used in adults for clavicle fractures, forearm fractures. ESIN is also preferred in Polytrauma/Multiple injuries as they are minimally invasive and have shorter surgical time. In Damage control orthopaedics, the principle of minimally invasive surgery is followed. Other advantages of ESIN are it is postop cast immobilization may not be required, shorter hospital stay, early return to daily activity, biological union, no growth plate injury, easy and safer implant removal. This technique should be part of the armamentarium of any orthopaedic surgeon. TENS is now being used for all long bones. Hence we decided to do a study of Titanium Elastic Nailing System (TENS) for long bone fractures.

Keywords: 30 cases of titanium, nailing system, long bones clinical outcome

Introduction

Elastic stable intramedullary nails (ESIN) was popularized in 1980s in Nancy, France.^{1,2} Titanium is twice as elastic as steel and hence it resists permanent deformation of the nail which occurs during nail insertion^[1, 3]. The versatility of the principle has widened the indications with time and experience^[2, 4]. Conservative treatment had disadvantages like longer period of immobility, longer hospital stays, delayed rehabilitation, more malunions etc. Aggressive surgery in the form of plating and rigid nailing were not essential in children. Elastic nails have become the preferred treatment in children between five to sixteen years. ESIN can also be used in adults for clavicle fractures, forearm fractures. ESIN is also preferred in Polytrauma/Multiple injuries as they are minimally invasive and have shorter surgical time. In Damage control orthopaedics, the principle of minimally invasive surgery is followed. Other advantages of ESIN are it is postop cast immobilization may not be required, shorter hospital stay, early return to daily activity, biological union, no growth plate injury, easy and safer implant removal^[1, 3, 5-9]. This technique should be part of the armamentarium of any orthopaedic surgeon. TENS is now being used for all long bones. Hence we decided to do a study of Titanium Elastic Nailing System (TENS) for long bone fractures.

Materials and Methods

A study of 30 cases of Titanium Elastic Nailing System (TENS) for long bone fractures where, conducted, taking the prospective cases from July 2016 to Feb 2018. The study was done at RLJ hospital attached to Sri Devaraj Urs Medical College. Kolar, Karnaka.

The inclusion criteria

1. All long bone fractures treated with Titanium Elastic Nailing System (TENS).
2. Follow up of minimum six months.
3. With or without Polytrauma/multiple injuries.

Correspondence

Dr. Prabhuling Reddy Patil
Sr. Resident, Department Of
Orthopaedics, Sri Devraj Urs
Medical College, Tamaka. Kolar,
Karnataka, India

The exclusion criteria

1. Pathological fractures eg: osteogenesis imperfecta
2. Fractures at proximal and distal ends of the long bones.
3. Unstable fractures like long spiral and comminuted fractures.
4. Severe Grade III Gustilo open fractures.

Patients were screened to find their eligibility for our study, and Indications for TENS are

1. All long bones fractures in children aged between 5 and 16 years.
2. Fracture clavicle, forearm in adults.
3. All long bone fractures in Polytrauma/Multiple injuries.
4. Fractures with head injury and fractures in paralysed limbs.
4. Long bone fractures where TENS gives acceptable stability.

The following principles like

1. The diameter of the individual nail was selected as per Flynn *et al.* formula. (Flynn 2001) [10]
2. Flynn *et al.* formula: Diameter of nail= width of the narrowest point of the medullary canal on AP and lateral view X 0.4 mm. In case of single nail usage its diameter should be more than 60% of the narrowest diameter of the medullary canal.
3. Nails was contoured with long bend such that apex of the convexity will be at the level of fracture to provide optimal three-point fixation.
4. Both the nails should be bent symmetrically to same extent, in case Femur and Tibia Fracture
5. The nails are pre-bent so that the height of the curve is three times greater than the diameter of the medullary canal.
6. Always using same diameter nails to prevent loss of reduction towards the side of stronger nail.
7. The entry point of both nails was at the same level.
8. When inserted, nails have maximum cortical contact at the fracture site in the opposite directions.
9. The nail tip should be pointing to the concave side of the bowed nail, even in clavicle
10. If closed reduction fails, open reduction will be undertaken using a small incision at fracture site.

Post-operatively, the patients were immobilized with long leg cast with a pelvic band for femur fracture or with above knee POP cast for tibia fracture, and for clavicle immobilised in fore-arm pouch, such immobilization will be continued based on radiological assessment. The period of immobilization was followed by active hip and knee/knee and ankle mobilization with non-weight bearing crutch walking for lower limb fractures, in case of clavicle fracture shoulder exercise Active shoulder and elbow/elbow and wrist mobilization for clavicle fractures. Full weight bearing was started by 8-12 weeks depending on the fracture configuration and callus response. Mobilization out of bed without restriction was permitted for patients with isolated injuries. Patients with lower extremity fractures will be permitted to bear weight as tolerated. Assessment was done at 4, 6, 8, 10, 12, 16 and 24 weeks. At each follow up patients were assessed clinically, radiologically and the complications where noted. All the patients were followed up till nails were removed after union. Union is defined as the presence of bridging callus at 3 out of 4 cortices on anteroposterior and lateral xrays. Delayed union is defined as slower than normal

progression to union on xrays after a specified time period following the fracture [5, 11, 12].

Clinical data that was collected was by age, gender, mechanism of injury, bone involved, type of fracture, associated injuries, closed or open reduction, post op immobilization with cast or orthoses, duration of hospital stay. It was also included range of motion, angular and rotational malalignment of the limb, limb length, time to partial and full weight bearing, time to return to school in case of children, time of union, time of nail removal, intra and postoperative complications and its treatment like signs of irritation or local infection from the tip of the nail, and signs of deep infection, etc. Anteroposterior and lateral xrays were carried out at regular intervals. Post-operative radiological evaluation where included and an assessment of the position of the nail, frontal and sagittal alignment, loss of reduction, callus formation, disturbance of trochanteric growth, osteonecrosis of the femoral head and femoral length. Varus and valgus angulation will be measured from the anatomical axis. Flexion and extension were measured directly with the understanding that the normal bow of the femur contributes to anterior angulation of fractures of the midshaft by a few degrees. Circumferential callus formation, the visibility of the fracture line, and leg length discrepancy and malalignment were recorded at each post-operative visit in order to monitor remodeling and detect delayed union or deformity [13].

Complications**Minor**

Pain at the site of nail insertion

Minor angulation (<10°-sagittal/coronal; <10° rotational malalignment) at final follow-up
Minor leg-length discrepancy (<2cm-shortening/lengthening) at final follow-up
Inflammatory reaction due to nails

Superficial infection at site of nail insertion

Delayed union (no sign of any callus after six wks or no circumferential callus after six mths)

Loss of knee movement (worse than 10° to 110°) more than two months after removal

Major

Angulation exceeding the guidelines at the final follow-up (>10°-sagittal/coronal; or >10° rotational malalignment)

Loss of reduction (between fixation and removal) requiring new reduction or surgery

Surgery to revise nail placement (e.g. nail trimming)

Leg-length discrepancy exceeding guidelines at final follow-up (>2cm-shortening/lengthening)

Deep infection

Compartment syndrome requiring surgery.

Haematoma requiring surgery

Neurological damage after nailing

Delayed or nonunion leading to revision

Radiological Assessment

X-ray thigh full length with hip and knee joints-AP and lateral views

X-ray leg full length with knee and ankle- AP and lateral

Alignment: 1. sagittal/coronal angulation (in degrees-<10 or >10)

1. Minor angulation (<10° -sagittal/coronal; <10° rotational malalignment) at final follow-up (24 weeks)

2. Minor leg length discrepancy (<2cm-shortening/lengthening) at final follow-up (24 weeks)

3. Inflammatory reaction to nails
4. Superficial infection at site of nail insertion
5. Delayed union

The final outcome based on the above observations is done as per Flynn’s criteria.

Outcome according to Flynn’s Criteria

Results Variable at 16 weeks	Excellent	Satisfactory	Poor
Limb-Length inequality	<1.0cm	<2.0cm	>2.0cm
Malalignment	5 degrees	10 degrees	>10 degrees
Unresolved pain	Absent	Absent	Absent
Other complications	None	Minor & resolved	Major & lasting

Additional outcome variable in study

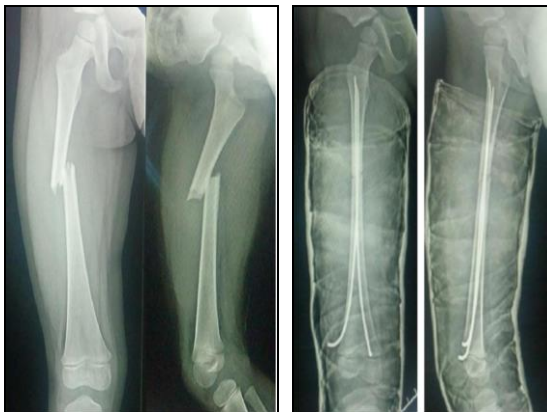Variable	Excellent	Satisfactory	Poor
Range of Movement	Full Range	Mild Restriction	Moderate-Severe Restriction
Time of Union	8-12 weeks	13-18 weeks	>18 weeks
Unsupported weight bearing	8-12 weeks	13-18 weeks	>18 weeks

Statistical Analysis: Descriptive statistics like numbers, percentages, average, standard deviations, were used. Data was presented in the form of tables and graphs wherever necessary. Inferential statistical tests like Chi-square and

Fisher’s exact probability test were applied to know the association between incidence of complications and clinical variables.

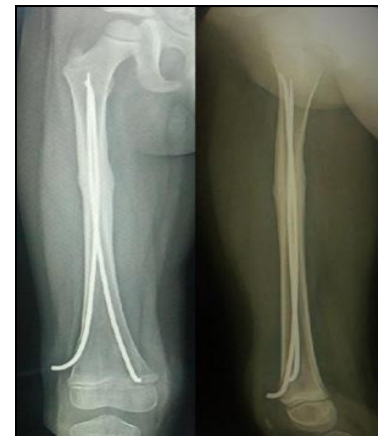Insufficient reduction	Greater than 10° alignment defect in the coronal, sagittal or horizontal plane before onset of malunion.
Joint stiffness	Greater than 5° knee extension defect or greater than 20° hip or ankle range of motion
Malalignment	Greater than 10° angulation in any plane after bone consolidation.
Recurrent fracture	New fracture during follow-up at the same level as the primary
Surgical Revision	Any fracture-related surgical procedure following TENS, other than those to remove material
Delayed union	Failure to demonstrate complete union on X-rays taken after a specified time period following the fracture: 15 week for femur and tibia

Functional outcome after TENS intramedullary nailing in Femur and Tibia Fractures

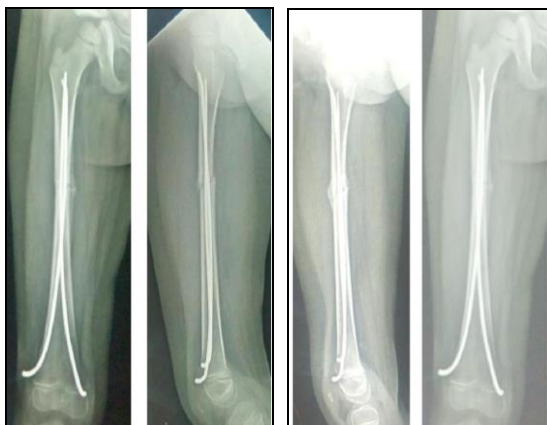

Pre op

Post op

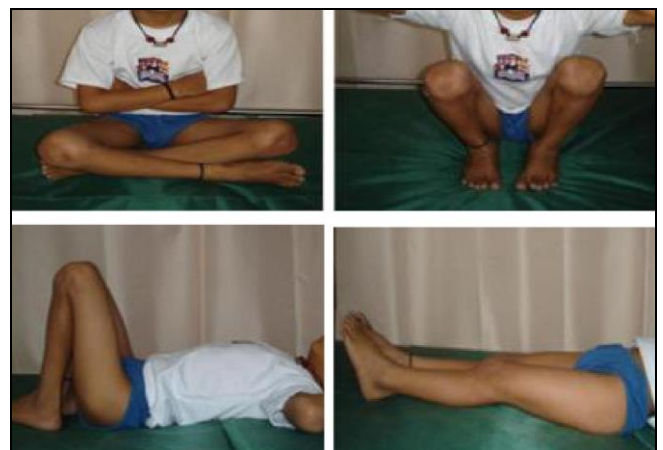

24 week follow up



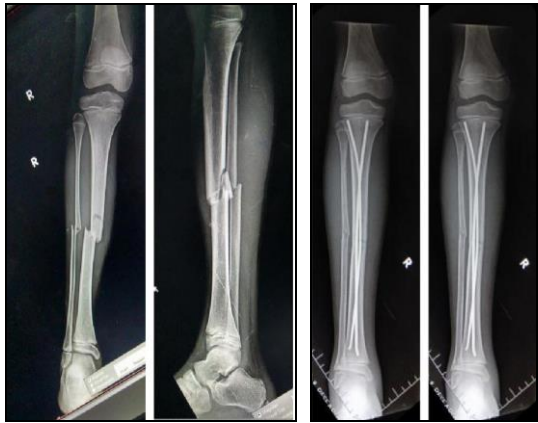6 week follow up

12 weeks follow up



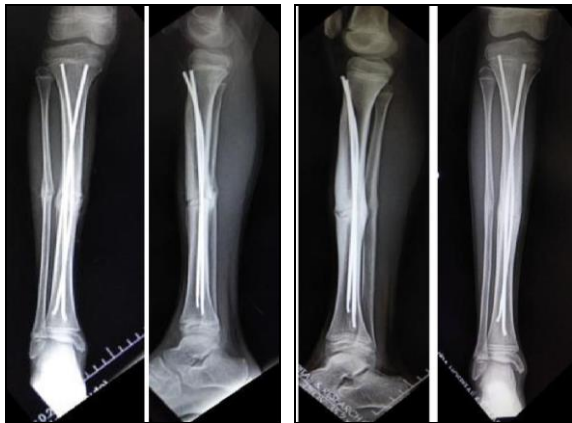Clinical pictures

Fig 1: Femur



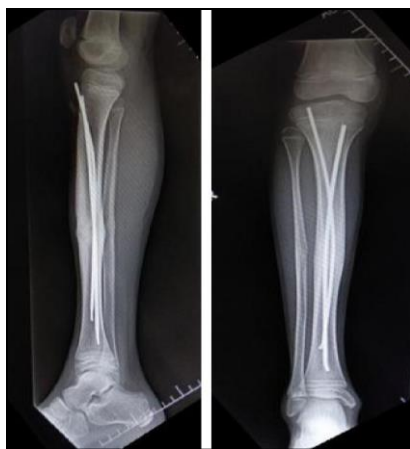Pre-OP

Post-OP

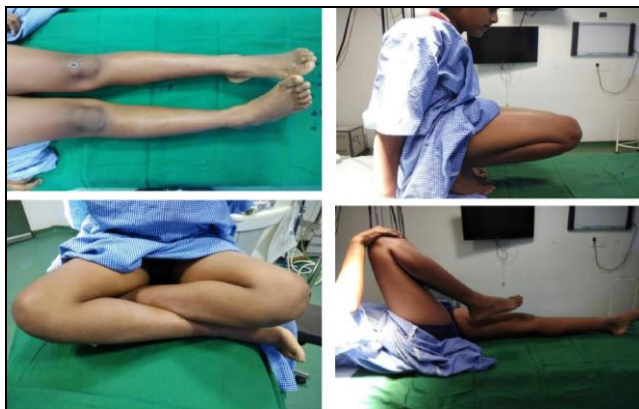


6 weeks follow up

12 weeks follow-up



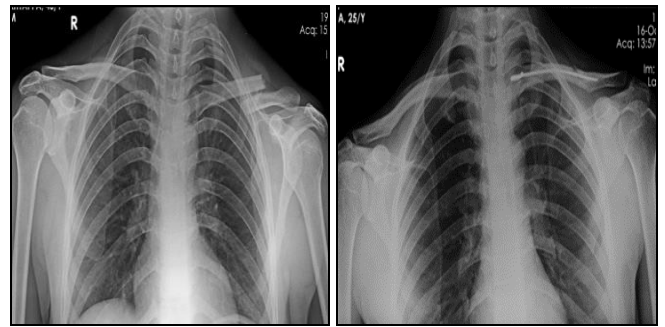
24 weeks follow-up



Clinical pictures

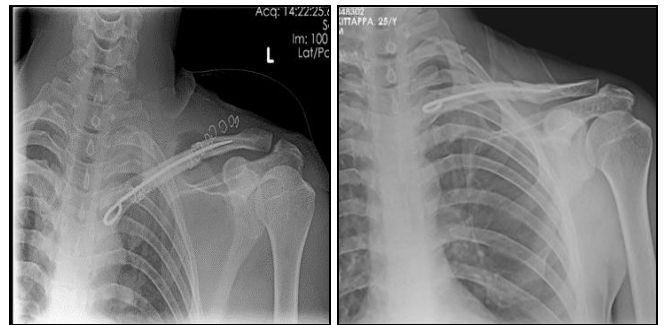
Fig 2: Tibia

Functional outcome after TENS intramedullary nailing in clavicle Fracture



Pre-OP

Post-OP



6 weeks

12 weeks

Fig 3: Clavicle

In displaced mid shaft fracture clavicle were taken. In this study 7 males (68%) and 3 females (32%) patients of age group 25years to 65 years were taken [mean age of 41.2 years.] Study showed that displaced mid shaft clavicle # were most common in age group of 31-50 years consisting of 9 cases (72%).

Right sided # 3 cases (60%) were more than left side (40%). There were 6 cases (68%) due to road side accidents followed by 2 cases (20%) due to fall.

7 cases (76%) showed union at 6 weeks of follow up. 2 cases (16%) showed union at 10 weeks and rest 2 (8%) at 14 weeks of follow up.

Table 3

Age group in years	Total	Males	Females	%
21-40	8	6	04	72
41-60	2	04	02	12

Table 4

Period of Union	No of cases	%
Within 6 weeks	7	76
6-10 weeks	01	16
10-14 weeks	01	08

Patients (60%) had full range of movement in flexion and abduction at shoulder and 4 patients, (40%) had deficient movement at shoulder.

Table 5

Range of shoulder movement	No of cases	%
(Flexion and abduction)		
More than 165 °	6	60
150-165 °	4	40
Less than 150 °	Nil	0

Operative complications such as infection, incision numbness, scar hyperplasia, irritation of nail end, withdrawal and breakage of nails were not found.

Results

Study Design: A prospective study on about 30 consecutive patients with diaphyseal fracture of femur, tibia and Clavicle meeting the inclusion and the exclusion criteria, admitted to RLJ hospital attached to Sri Devaraj Urs Medical College. Kolar. Karnataka

Table 1: Age Distribution

Age in years	Number of patients	Percentage%
5-8 years	4	2
9-12 years	9	30
13-15 years	8	28
25-65 years	9	30
Total	30	100

Table2: Gender Distribution

Gender	Number of patient	Percentage %
Male	23	76
Female	7	40
Total	30	100

Table 3: Mechanism of Injury

Mode of injury	Number of patient	Percentage %
RTA	11	36
Self	13	44
Fall from Height	6	20
Total	30	100

Table 4: Bones effected

Bone effected	Number of patient	Percentage %
Femur	8	28
Tibia	13	42
Clavicle	9	30
Total	30	100

Table 5: Side effected

Side effected	Number of patient	Percentage %
right	21	70
left	9	30
Total	30	100

Table 6: Range Of Movement (Degrees)

Range of movement	Number of patient	Percentage %
Full	27	90
Mild restriction	3	10
Medium restriction	0	0
Sever restriction	0	0
Total	30	100

Table 7: Complication

Comication	Number of patient	Percentage %
Nil	17	56
Mainor	13	44
Major	0	0
Total	30	100

Conclusion

Based on the experience and results of our study, we conclude that TITANIUM ELASTIC NAIL SYSTEM surgical technique is a safe, simple, reliable and effective method for

management of paediatric femoral and tibial diaphyseal fractures between the age of 5 to 15 years and adults clavicle Fractures, age from 25-65years.

Titanium Elastis Nails gives elastic mobility promoting rapid union at fractures site and stability which is ideal for early mobilization as well as its physéal protective technique and design causes minimal disturbance of bone growth, hence Tens may be considered to be a protective and physiological method of treatment.

Tens has definite advantages in terms of short duration of hospital stay, and early return to activity, acceptable bone healing time, good functional outcome and less incidence of complications.

The surgical technique itself is easy to learn and implement with moderate need of equipment and surgical skills. Minimally invasive approach, shorter operative time, less blood loss, lesser radiation exposure resonates with idea of an ideal surgical technique.

Overall experience in our study shows that Titanium Elastic Nailing for paediatric femur, tibia diaphyseal fracture and adults clavicle fractures is a safe, cost effective, physiological procedure with a relatively easy learning curve resulting in very few short term complications with mostly excellent outcomes irrespective of fracture location and pattern provided that the important biomechanical principles of TENS are followed.

Most clavicle fractures heal uneventfully without serious consequences with non-operative treatment. With changing trends in treatment of displaced mid shaft clavicle fracture (DMCF), plating remains the standard procedure for fixation. An attractive alternate method of fixation is Titanium Elastic Nailing (TEN).

References

- Ligier JN, Metaizeau JP, Prevot J, Lascombes P. Elastic Stable Intramedullary Nailing of Nailing of Femoral Shaft Fractures in Children. *J Bone Joint Surg Br.* 1988; 70-B:74-7.
- Barry M, Paterson JMH. Flexible intramedullary nails for fractures in children. *J Bone Joint Surg [Br].* 2004; 86-B:947-53.
- Siddaram patil. Prospective Study in treatment of long bone fracture in children by Titanium Elastic Nailing stabilization. *Int J Biol Med Res.* 2014; 5(4):4479-4490.
- Susanta Khuntia, Sanjaya Behera, Bijaya Sadangi, Anil sahu, Prakash Mall, Diptish Sahoo *et al.* Elastic bone fractures-scope of elastic nails. *JEMDS,* 2016.
- Aamer Nisar, Abhijit Bhosale. Complications of Elastic Stable Intramedullary Nailing for treating paediatric long bone fractures. *Journal of orthopaedics.* 2013; 10:17-24.
- Lascombes P, Prevot J, Ligier JN, Metaizeau JP, Poncelet T. Elastic stable intramedullary nailing in forearm shaft fractures in children: 85 cases. *J Pediatr Orthop.* 1990; 10:167-171.
- Lascombes P, Haumont T, Journeau P. Use and abuse of flexible intramedullary nailing in children and adolescents. *J Pediatr Orthop.* 2006; 26:827-834.
- Metaizeau JP. Stable elastic intramedullary nailing for fractures of the femur in children. *J Bone Joint Surg Br.* 2004; 86:954-7.
- Furlan D, Pogoreliæ Z, Bioeieæ M, Jurieæ I, Budimir D, Todorieæ J *et al.* Elastic stable intramedullary nailing for pediatric long bone fractures: experience with 175 fractures. *Scand J Surg.* 2011; 100:208-15.
- Flynn JM, Hresko T, Reynolds RA, Blasler RD,

- Davidson R, Kasser J. Titanium elastic nails for pediatric femur fractures: a multicentre study of early results and analysis of complications. *J Pediatr Orthop.* 2001; 21:4-8.
11. Lewallen RP, Peterson HA. Non-Union of long bone fractures in children, a review of 30 cases. *J Pediatr Orthop.* 1985; 5:135-142.
 12. Mehlman CT, Wall EJ. Injuries to shafts of the radius and ulna. In: Beaty JH, Kasser JR, eds. *Fractures in Children.* 6th ed. Philadelphia: Lippincott Williams & Wilkins, 2006.
 13. Moroz LA, Launay F, Kocher MS. Titanium elastic nailing of fractures of the femur in children- Predictors of complications and poor outcome. *J Bone Joint Surg Br.* 2006; 88(10):1361-6.