



International Journal of Orthopaedics Sciences

ISSN: 2395-1958
IJOS 2018; 4(2): 155-157
© 2018 IJOS
www.orthopaper.com
Received: 08-02-2018
Accepted: 12-03-2018

Dr. Srinivas Y
Associate Professor, of
Orthopaedics, Kamineni
Institute of Medical Sciences,
Sreepuram, Narketpally,
Nalgonda, Telangana, India

Dr. Srikanth G
Senior Resident of Orthopaedics,
Kamineni Institute of Medical
Sciences, Sreepuram,
Narketpally, Nalgonda,
Telangana, India

Dr. Anudeep
Junior resident of Orthopaedics,
Kamineni Institute of Medical
Sciences, Sreepuram,
Narketpally, Nalgonda,
Telangana, India

Dr. ME Luther
Professor and HOD, Department
of Orthopaedics, Kamineni
Institute of Medical Sciences,
Sreepuram, Narketpally,
Nalgonda, Telangana, India

Correspondence
Dr Srikanth G
Senior Resident of
Orthopaedics, Kamineni Institute
of Medical Sciences, Sreepuram,
Narketpally, Nalgonda,
Telangana, India

Proximal humerus fracture treated with proximal humerus locking plates. (Philos): A functional outcome

Dr. Srinivas Y, Dr. Srikanth G, Dr. Anudeep and Dr. ME Luther

DOI: <https://doi.org/10.22271/ortho.2018.v4.i2c.23>

Abstract

It has always been an enigma for the management of such fractures because of numerous muscles attachment and paucity of space for fixing implant in fracture of proximal humerus. The object of the osteosynthesis is to reduce the displacement (usually rotation) of each fragment and hold it in place with an implant and allowing early mobilization.

Objective: To evaluate the functional outcome of proximal humerus fractures treated with proximal humerus locking plates (PHILOS).

Material and Methods: Using Neer's classification twelve patients of proximal humerus fractures were treated by open reduction and internal fixation with PHILOS plate through deltopectoral approach and were evaluated by Neers criteria at the end of follow up.

Results: All the fractures of proximal humerus who met the inclusion criteria were treated with (PHILOS) plate. Proximal humerus fracture is common in age group of 31 to 40 years (41%). 8 out of 12(58%) patients were male. In the present study 8(67%) cases had 2 part fracture; 3(25%) cases had 3 part fracture and one case (8%) had 4 part fracture. In our study we had 4 Excellent (34%) and 7 satisfactory (58%) results and 1 had unsatisfactory (8%) according to Neer's criteria. Out of 12 patients, 2(17%) had complication. 1 patient (8.5%) had superficial infection and 1 patient (8.5%) had stiffness of the shoulder

Conclusion: From our study it can be safely recommended that for proximal humerus fractures, PHILOS plating is a good choice of surgical treatment.

Keywords: Proximal humerus, Neer's criteria, PHILOS plate

Introduction

Proximal humerus fractures are one of the commonest fractures occurring in the human body. They account for approximately 4 – 5% of the all fractures^[1]. Incidence of fractures is more common in the elderly because of decreased bone density and in younger age group following high velocity trauma^[1]. It has been always been an enigma for the management of such fractures because of numerous muscles attachment. A review of published result suggests that there is no universally accepted form of treatment. Conservative management may be associated with non-union, malunion resulting in painful dysfunction^[2]. The surgery should be carried out as soon as the patient's general condition permit. A delay of several days makes reduction more difficult and a significant delay results in absorption of bone, making secure internal fixation impossible. The object of the osteosynthesis is to reduce the displacement (usually rotation) of each fragment and hold it in place with an implant. Three & four part fractures represent 13 to 16 % of proximal humeral fractures. Treatment options for these displaced fractures include open reduction and fixation. Neer recommended open reduction and internal fixation for displaced two and three parts fractures^[3]. Most of the poor results following open reduction and internal fixation of three part fracture are due to imperfect technique. In a three or four part fracture dislocation when the head of the humerus is entirely devoid of any blood supply it can be replaced by a humeral prosthesis. However the goal of Proximal Humerus fracture fixation should be stable reduction allowing early mobilization. This study is conducted to analyze fractures of the proximal humerus that were treated with the locking compression plate and documents their clinical and functional outcome^[4].

Material and Methods

All patients fulfilling the inclusion criteria were admitted to Kamineni Institute of Medical Sciences during the study period from October 2013 to September 2015. It was a Prospective type of study. The study purpose was to include patients with proximal humerus fractures admitted and examined according to protocol and associated injuries were noted. Clinical and Radiological evaluation was done. Fractures classified using Neer’s classification. Blood investigations were carried out to get fitness for surgery. Consent of the patient and fitness for surgery along with ethical committee clearance was taken. Patients underwent Open reduction internal fixation with PHILOS plate for the fracture under general anaesthesia / block. Post-operative physiotherapy followed according to protocol, to evaluate the functional outcome. Inclusion criteria: Two part, three part, four part proximal humeral fractures, Acute fractures, Age above 18, Patient fit for surgery, Exclusion criteria was below 18yrs of age, Associated humerus shaft fracture, Associated neurovascular injury, Pathological fractures, Old fractures and compound fracture.

Results

Proximal humerus fracture is common in age group of 31 to 40 years (41%). 8 out 12(58%) patients were male. The commonest mode of injury was Road traffic accident (67%). In the present study 8(67%) cases had 2 part fracture; 3(25%) cases had 3 part fracture and one case (8%) had 4 part fracture. In our study we had 4 Excellent(34%) and 7 satisfactory(58%) results and 1 had unsatisfactory(8%) according to Neer’s criteria. Out of 12 patients, 2(17%) had complication. 1 patient (8.5%) had superficial infection and 1 patient (8.5%) had stiffness of the shoulder. The final results were evaluated using Neer Scoring system.

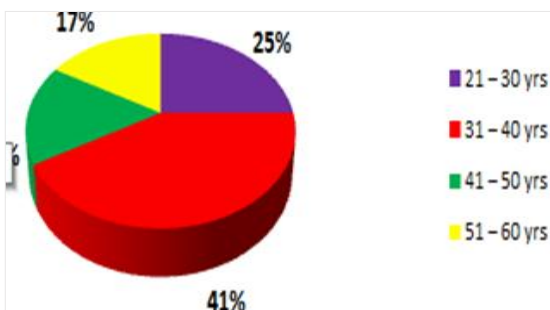


Chart 1: Age

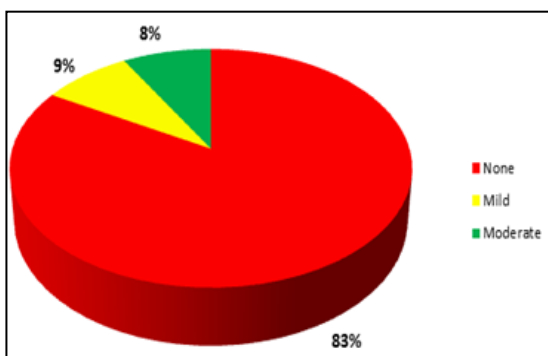


Chart 2: Anatomy

10 Patients (83%) have no anatomical disturbance and 1 patient had mild anatomical disturbance 1 patient had moderate involvement at the end of 9 month

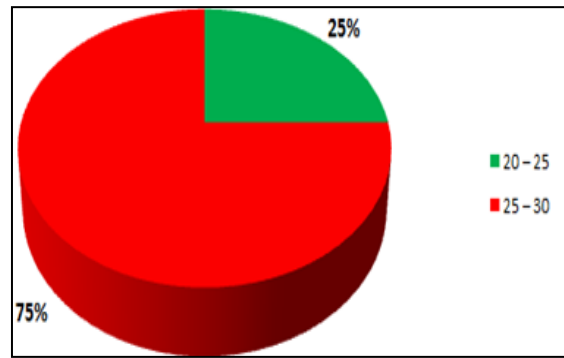


Fig 3: Results

9 Patients (75%) had functional score between 25 – 30 And 3 patients (25%) had score between 20-25 at the end Of 9 months

Discussion

The incidence of proximal humerus fractures has increased in last few years. The management in these injuries is still uncertain. However, with the aim of getting anatomically accurate reductions and early restoration of function, open reduction and internal fixation, is preferred. The best results are obtained if the fracture is well reduced and planned rehabilitation program followed. Proximal humerus fractures occur more commonly in elderly age group. Numerous age related studies point towards this and our study shows an average incidence of 39.9yrs to 58.1 yrs as noted by Sameer Aggarwal, Kamal Bali⁵. Further our study showed a higher incidence of fractures in men than in women. The gender ratio was 1.4:1. Major cause of fracture in our study was road traffic accidents in 8 (66.4%) cases and in 4 cases (33.6%) the mode of injury was fall from standing height due to slipping. MA Fazal, FS Haddad⁶ in their study have reported 21 cases(77.8%) of fall and 6 cases(22.2%) of RTA. Sameer Aggarwal, Kamal Bali⁵ in their study of 47 patients of proximal humerus fracture, fall accounted for 55% of fracture, road side accident 42.5% and 1 fracture(2.5%) was caused by seizure. C. Gerber⁷ reported, in their series of 34 fractures 16 were on left side and 18 were on right side. When compared with other studies, in the present study two part fractures were more in our series and were treated with (PHILOS). As the number of cases in this study are small, no conclusion can be drawn. Ramachander Siwach *et al.*⁸ treated 12 two part and 13 three part fracture using LCP. MA Fazal *et al.*⁶ treated 27 of their cases (13 two part and 12 three part) using PHILOS plating. When compared with other studies present study shows less complications. One patient had stiffness and one patient had superficial infection. However, Felix Brunner⁹ showed 13.9% of his cases had screw penetration as a complication.

The final results are graded according to Neer scoring criteria. We had satisfactory to excellent results in 11(91.7%) of patients treated in our institution. All patients with excellent results and satisfactory results had normal muscle function and functional range of motion according to Neer’s Criteria. We had unsatisfactory results in 1 (8.3%) patient. 1 patient had stiffness with restriction of movements and with persistent mild to moderate pain which considered as unsatisfactory. This patients had poor follow up and compliance to physiotherapy was poor. Ramachander Siwach *et al.*⁸ recorded a similar outcome with 92% of their cases having excellent to satisfactory results.

Table 1: Post-Operative function Assessment as per NEER's criteria at the end of 9 months follow up. (n=12)

| Function (30 Points) | No of Patients | Percentage |
|------------------------|----------------|------------|
| 15 - 20 | Nil | Nil |
| 20 - 25 | 3 | 25 % |
| 25 - 30 | 9 | 75 % |
| Total | 12 | 100 % |

Table 2: Result assessment as per NEER's criteria at the end of 9 Months follow up. (n=12)

| Result | No of Patients | Percentage % |
|----------------------------|----------------|--------------|
| Excellent (>89) | 4 | 34 % |
| Satisfactory (80- 88) | 7 | 58 % |
| Unsatisfactory (70 – 79) | 1 | 8 % |
| Failure (< 69) | Nil | Nil |
| Total | 12 | 100 % |

The Neer's scoring system of severity of pain, function, range of movements and anatomy was done to determine the end results.

Conclusion

The present study was done to evaluate functional outcome and complication following surgical management of proximal humerus fractures treated with proximal humerus by locking compression plate. (PHILOS) Locking compression plate is mechanically and biologically an advantageous implant in proximal humeral fractures particularly in comminuted fractures and in osteoporotic bones in elderly patients, thus allowing early mobilization and fracture union. From our study it can be safely recommended that for proximal humerus fractures, PHILOS plating is a good choice of surgical treatment.

References

1. Neer II, Charles S. Displaced Proximal Humerus Fractures. The Journal Of Bone And Joint Surgery. 1970; 52:1090-1103.
2. Hauschild O, Konrad G, AudigeL, De Boer P, Lambert SM, Hertel R. versus non-operative treatment for two-part surgical neck fractures of the proximal humerus. Arch Orthop Trauma Surg. 2013; 133:1385-1393.
3. Neer CS. Dispalced proximal humeral fracture. Part 1: Classification and evaluation. J Bone Joint Surg. 1970; 52:1077-1089.
4. Wijnman AJ, Roolker W, Patt TW. Open reduction and internal fixation of three and four-part fractures of the proximal part of the humerus. J Bone Joint Surg Am. 2002; 84:1919-1925.
5. Sameer A. Displaced proximal humeral fractures: an Indian experience with locking plate. Journal of Orthopaedic Surgery and Research. 2010; 5:60-65.
6. Fazal MA, Haddad FS. PHILOS plate fixation for displaced proximal humeral fractures. Journal of Orthopaedic Surgery. 2009; 17:15-18.
7. Gerber C, Werner CM, Vienne P. Internal fixation of complex fractures of the proximal humerus. J Bone Joint Surg. 2004; 86:848-855.
8. Ramchander S, Roop S, Rajesh Kumar R. Internal fixation of proximal humerus fracture by locking proximal humerus plate in elderly osteoporotic. J Orthopaed Traumatol. 2008; 9:149-153
9. Felix B, Christoph S, Christian B. Open Reduction and Internal Fixation of Proximal Humerus Fractures Using a Proximal Humeral Locked Plate. A Prospective Multicenter Analysis. J Orthop Trauma. 2009; 23:163172.