



ISSN: 2395-1958  
IJOS 2018; 4(2): 11-15  
© 2018 IJOS  
www.orthopaper.com  
Received: 03-02-2018  
Accepted: 04-03-2018

**Rajat Tak**  
Government Medical College and  
Hospital, Kota, Rajasthan, India

**Dr. Vikas Gupta**  
Government Medical College and  
Hospital, Kota, Rajasthan, India

**Rajesh Goel**  
Prof. Government Medical  
College and Hospital, Kota,  
Rajasthan, India

## Clinical outcomes of treatment of benign cystic lesions of proximal femur with non-vascularized autologous fibular strut graft and supplementary fixation with cannulated cancellous screw

**Rajat Tak, Dr. Vikas Gupta and Rajesh Goel**

**DOI:** <https://doi.org/10.22271/ortho.2018.v4.i2a.03>

### Abstract

The aim of the study was to evaluate results of benign cystic lesions of proximal femur treated by non vascularized autologous fibular strut graft and supplementary fixation using cannulated cancellous screw. Non vascularized autologous fibular strut graft which act as mechanical as well as biological graft. The hypothesis behind this study to add fixation to fibular strut graft which helps in immediate structural support, early consolidation of defect and remodeling.

**Methods and Materials:** We prospectively and retrospectively evaluated clinical outcomes of surgically treated 8 patients with benign lytic lesions of proximal femur. Out of these 6 were males and 2 females with mean age of presentation was 17 years. Average follow up time was 36 months. Histological diagnosis included simple bone cyst, aneurysmal bone cyst, fibrous dysplasia.

**Results:** 8 patients with benign cystic lesions of proximal femur were treated with curettage and autologous fibular strut grafting. The average operation time was 148 minutes. All patients were allowed unprotected full weight bearing by a mean of 13.2 weeks after surgery. All patients had regained normal unrestricted activity without pain by 12 months of follow up. None of the patients sustained pathological fracture of femur following the surgery. All patients achieved partial or complete consolidation of the lesion within 8 months. None of the patients had local recurrence of tumor in their long follow up. None of the patients were suffered from postoperative wound infection, deep vein thrombosis, chronic hip pain.

**Conclusion:** We conclude that non vascularized autologous fibular strut graft with internal fixation using cannulated cancellous screws is a safe and effective method of treatment for benign cystic lesions of proximal femur.

**Keywords:** Benign cystic lesions, proximal femur, Non vascularized fibular strut graft, fixation.

### Introduction

Proximal femur is one of the common site for cystic lesions including benign tumors and tumor like conditions. These are simple bone cysts, aneurysmal bone cysts, fibrous dysplasia. Surgical treatment usually requires as these lesions are prone for pathological fractures. Many surgical treatment options are described including curettage, bone grafting (autologous fibular strut/tricortical/cancellous/synthetic), biodegradable bone cement with or without fixation device. Fixation device can be cannulated cancellous screws, Dynamic hip screws. This study describes the clinical outcomes of treatment of benign cystic lesions of proximal femur with non vascularized autologous fibular strut graft and fixation with cannulated cancellous screw. The advantage of this procedure is that it provides immediate structural support, early consolidation of defect and remodeling.

### Methods and Materials

The study was conducted at Govt Medical college and Hospital, kota after getting clearance from the ethical committee. All study participants given written informed consent for participation in this study. The study was conducted from 2010 to 2017 on patients admitted from OPD of orthopaedics department of the hospital.

We evaluated 8 patients (6 males and 2 females) both retrospectively and prospectively who met the inclusion criteria.

**Correspondence**  
**Rajat Tak**  
Government Medical College and  
Hospital, Kota, Rajasthan, India

**Inclusion Criteria:** Primary benign tumors or tumor like conditions of proximal femur including femoral neck, head, trochanter

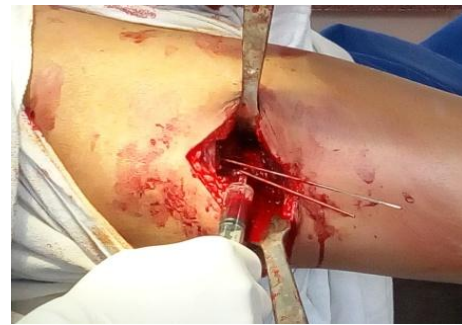1. With impending pathological fractures
2. Tumors causing pain and limp
3. Tumors with expansile natural course.

8 patients were treated with curettage and autologous non vascularized fibular strut graft followed by supplementary cannulated cancellous screws fixation .The average age at the time of presentation was 17 years and the average follow up period was 36 months. Pathological diagnosis included simple bone cyst, aneurysmal bone cyst, fibrous dysplasia. Patients were assessed preoperatively using x rays, CT scan and MRI .Those patients with typical findings of benign cystic lesions didn't undergo into preoperative biopsy. For doubtful cases core needle biopsy was done under fluoroscopic guidance .The tissue obtained during surgery was sent for histopathologic examination.

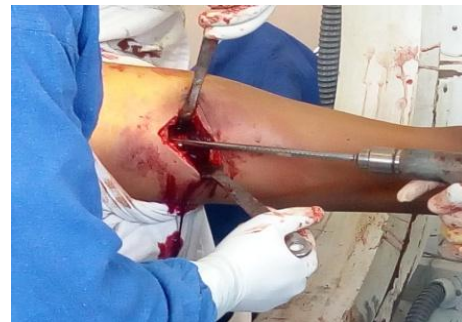**Operative procedure**

Under spinal anaesthesia patients were put on a radiolucent traction table. Painting with povidone iodine 10% of the affected limb and pelvic region followed by sterile drapping. First fibular strut graft is harvested from the same side 2-3 cm more than the approximated length of graft required .This prevents cross contamination of tumor into graft site . Fibular graft is taken subperiosteally through lateral skin incision over middle of shaft. Periosteum is left behind which helps in fibular reconstitution. The wound is sutured into layers and dressed.

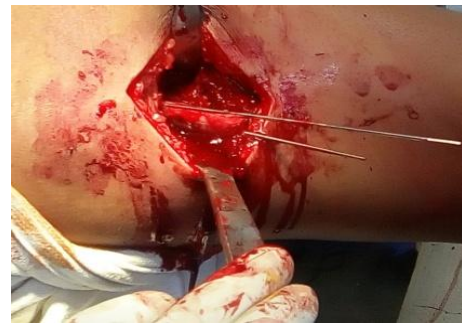Lateral incision is placed over mid of greater trochanter to extend distally. Soft tissue is dissected, vastus lateralis is elevated to expose lateral cortex of femur. A DHS guide wire is placed in centre of the neck in both AP and Lateral views under fluoroscopy. Cortical window is created with the help of drilling the cortex with 8 mm reamer over guidewire that opens into lesion and decompresses the cavity. Window created is large enough that allows complete curettage of the lesion .The material obtained from lesion examined grossly and send for histopathology. Curettage of lesion is done with a curettage spoon. The harvested fibula is then sized accordingly to get fit into the defect snugly. Fibular graft is gently hammered into the defect over centrally placed guidewire through the cortical window supplemented by two 6.5 mm cannulated cancellous screws without crossing capital physis.



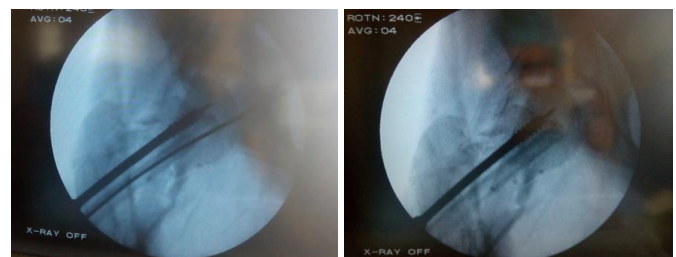
DHS guide wire placed



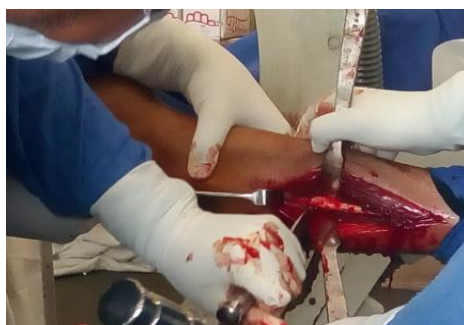Reaming with 8 mm reamer



Fibula was inserted over guide wire



Fibular placement under c arm



DFibular cortical graft

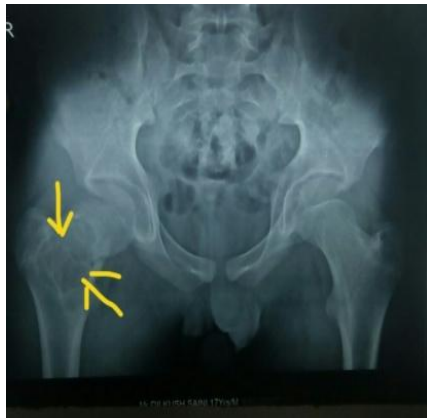Postoperative AP, Lateral radiographs are taken. Intravenous antibiotic cover given for 3-4 days. Patients were discharged after 5 days. Sutures were removed after 2 weeks .Weight bearing not allowed postoperatively .We followed the patients 6 weekly upto 3 months then 3 monthly thereafter with clinical as well as radiological recovery. Serial x rays are taken in every follow up visit and records are maintained. Toe touch weight bearing with help of walker or crutches allowed after 6 weeks and if patient is comfortable to complete weight bearing allowed around 3 months

**Patient characteristics**

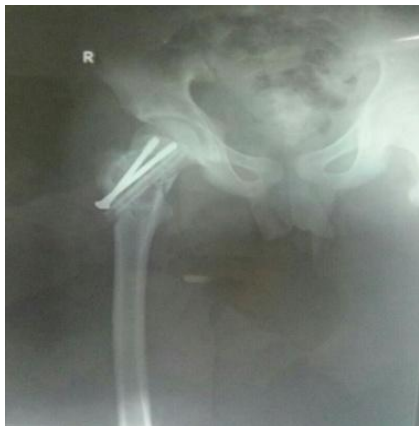Case No.	Age/ Gender	Diagnosis	Location of lesion	Follow up (months)	Operative time (minutes)	Complete consolidation (months)	Time- FWB (wks)
1	16/M	ABC	N+T	48	116	8	12
2	19/M	SBC	N	28	148	6	16
3	21/F	FD	N+T	32	150	9	12
4	13/M	ABC	N+T	40	165	10	14
5	20/M	FD	N	38	170	6	13
6	14/M	ABC	N+T	30	144	8	13
7	17/M	ABC	N+T	34	152	10	12
8	16/F	SBC	N+T	32	138	8	14

ABC : Aneurysmal bone cyst , SBC : Simple bone cyst , FD : Fibrous dysplasia , FWB: Full weight bearing , N: Neck , T : Trochanter.

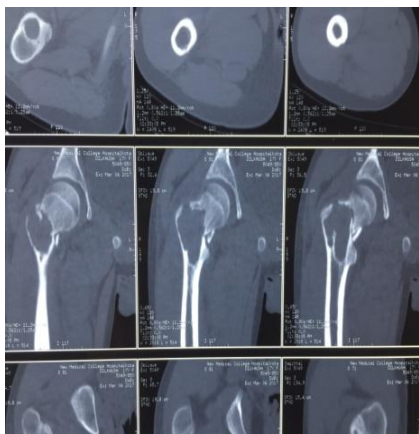Radiograph of a case of aneurysmal bone cyst (17/M) of right proximal femur treated with curettage and non vascularized autologous fibular strut graft and supplementary fixation with cannulated cancellous screws.



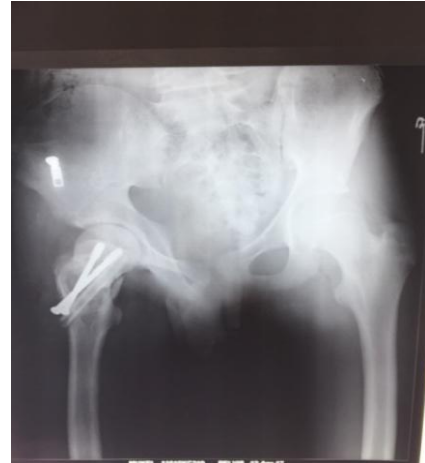pre-operative x ray



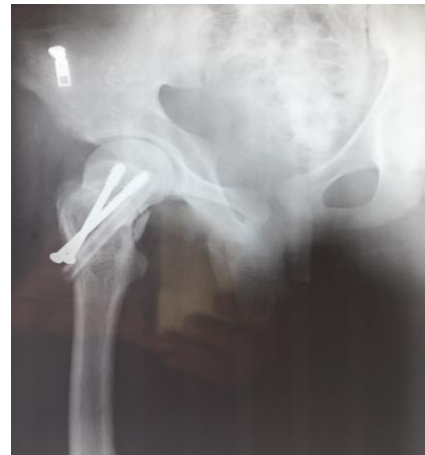Post-operative x ray



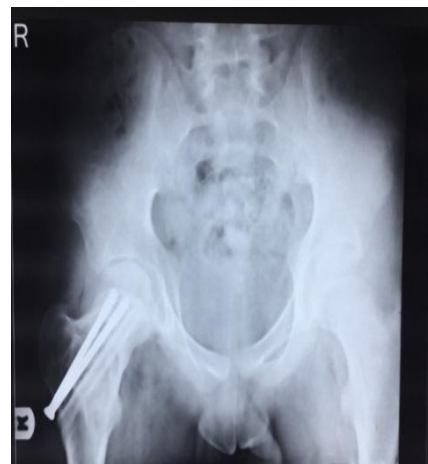ct scan



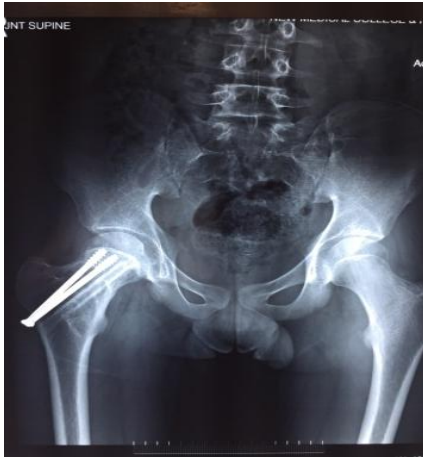6 Weeks follow up



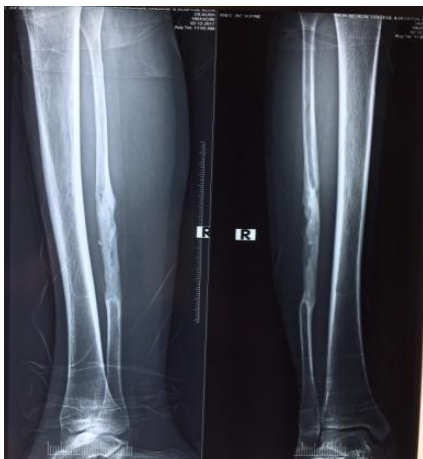3 months follow up



6 months follow up



9 months follow up



Fibular regeneration

## Results

8 patients with benign cystic lesions of proximal femur were treated with curettage and autologous fibular strut grafting. 6 patients were males and 2 were females. The mean age at the time of presentation was 17 years. The average operative time was 148 minutes. Average follow up period was 36 months. All patients achieved partial or complete consolidation by mean of 12.6 months. All patients were attained full unprotected weight bearing by mean of 13.2 weeks of follow up. Pathological diagnosis was simple bone cyst in 2 patients, aneurysmal bone cyst in 4 patients, fibrous dysplasia in 2 patient. None of the patient sustained pathological fracture following the procedure. None of the patients had recurrence of tumor in their follow up. None of the patients had any postoperative complications - infection, chronic hip pain, deep venous thrombosis. It was observed that partial to complete re growth of fibula at the donor site in 3 patients after a mean of 16 months post-surgery.

## Discussion

Proximal femur is one of the most common site for benign cystic tumor and tumor like conditions. There are several treatment options available including curettage and bone grafting with or without fixation. Bone grafts can be autologous/allogenic – cortical or cancellous. Bone substitutes like calcium hydroxyapatite or biodegradable bone cement – calcium phosphate cement can be used after curettage of these lesions. Cancellous grafts doesn't provides immediate structural support. Cortical fibular graft provides immediate structural support, graft incorporation, and remodeling. Surgical reinforcement of the proximal femur after resection

of bone tumor to prevent postoperative fracture when the tumor affects > 50% of diameter of the femoral neck. Internal fixation can be done using various implants - dynamic hip screws, cannulated cancellous screws. One study use dynamic hip screw with autologous non vascularized fibular graft in 13 patients, all patients achieved partial/complete radiographic consolidation of the lesion with tumor recurrence in 1 case. chronic hip pain was observed in 1 patient due to irritation of the tensor fascia lata muscle by tube plate [1]. In our study none of the patient had similar complaint in follow up.

George *et al.* [2] reported 17 patients with benign lesions of the proximal femur treated with non vascularised autologous fibular strut grafts without osteosynthesis with recurrence of tumor in 2 patients. Fixation devices have inherent disadvantages such as an increased risk of infection, tissue irritation, cut out, and in young patients a further operation to remove the device [3].

Ozaki *et al.* reported 17% recurrence rates in ABC with curettage and cement application [8, 10, 7, 13]. In the same study, the results were compared with cryotherapy and lower complication rates were found in the cement group. The advantages of this technique are that it is easy to perform and the cement provides structural support in the cavity. However, it has limitations, as neurovascular structures and the growth plate should be protected from the heat generated with this technique. Good results (between 82-96% success) have been reported with cryotherapy [6, 7]. However, progression of fractures, local infection, fusion or nerve damage with associated fractures and growth plate destruction are potential complications [6, 7]. Corticosteroid injections are ineffective in the treatment of aneurysmal bone cysts [6].

Autologous bone graft has been considered ideal, but its disadvantage includes its limited availability, tumor infestation at the donor site, infection. Calcium hydroxyapatite as bone substitutes can be used, it act as scaffold for new bone formation. Calcium phosphate cement has advantage that it is biodegradable. Vascular autologous cortical graft have superior quality than non vascularized autologous cortical graft [4, 5], but due to complexity of procedure and more operative time and demanding microsurgical technique is required in graft harvesting. So we use non vascularized autologous cortical graft.

Jaffe and Dunham [3] in their study uses cancellous graft along with cortical autograft and dynamic hip screw fixation. Allografts can be used but graft incorporation is slower and they are immunogenic. Advantage is plenty availability, no donor site morbidity. Some authors uses combined anterior and lateral approaches for bone tumors extending into neck and head. They reported that anterior approach allows good exposure of head for curettage than lateral approach, but there are high chances of vascular injury, contamination of femoral vessels if postoperative diagnosis was malignant bone tumor [15].

We conclude that non vascularized autologous fibular strut graft with supplementary fixation using cannulated cancellous screws is a safe and effective method of treatment for benign cystic lesions of proximal femur.

## Conflict of interest

There was no conflict of interest in this study.

## References

1. Nakamura T, Matsumine A, Asanuma K, Matsubara T & Sudo A. Treatment of the benign bone tumors including femoral neck lesion using compression hip screw and

- synthetic bone graft. SICOT J, 2015; 1:15.
2. George B, Abudu A, Grimer RJ, Carter SR, Tillman RM. The treatment of benign lesions of the proximal femur with non vascularised autologous fibular strut grafts J Bone Joint Surg (Br). 2008; 90(5):648-51.
  3. Jaffe KA, Dunham WK. Treatment of benign lesions of the femoral head and neck. Clin Orthop, 1990; 257:134–7. PubMed.
  4. Finkemeier CG. Bone grafting and bone graft substitutes. J Bone Joint Surg [Am] 2002; 84-A:454–64.
  5. Dell PC, Burchardt H, Glowczewski FP Jr. A roentgenographic, biomechanical, and histological evaluation of vascularized and non-vascularized segmental fibular canine autographs. J Bone Joint Surg [Am] 1985; 67-A:105–12.
  6. Web of ScienceGoogle Scholar Ohashi M, Ito T, Hirano T, Endo N. Percutaneous intralesional injection of calcitonin and methylprednisolone for treatment of an aneurysmal bone cyst at C-2. Division of Orthopaedic Surgery, Department of Regenerative and Transplant Medicine, Niigata University Graduate School of Medicine and Dental Sciences, Niigata, Japan. J Neurosurg Pediatr 2008; 2:365-9.
  7. Yildirim E, Ersözlü S, Kirbas I, Özgür AF, Akkaya T, Karadeli E. Treatment of pelvic aneurysmal bone cysts in two children: selective arterial embolization as an adjunct to curettage and bone grafting. Diagn Interv Radiol, 2007; 13:49-52.
  8. Beris AE, Lykissas MG, Payatakes A, Kontogeorgakos VA, Mavrodontidis A, Korompilias AV. Free vascularised fibular graft for treatment of pathological femoral neck fracture and osteonecrosis of the femoral head: A case report with a long-term follow-up. Microsurgery, 2009; 29:240-3. [CrossRef]
  9. Singh VP, Mir R, Kaul S. Aneurysmal bone cyst of sternum. Thorac Surg 2010; 89:e43-5. [CrossRef].
  10. George B, Abudu A, Grimer RJ, Carter SR, Tillman RM. The treatment of benign lesions of the proximal femur with non-vascularised autologous fibular strut grafts. J Bone Joint Surg Br., 2008; 90:648-51.
  11. Jaffe HL. Aneurysmal bone cyst. Bull Hosp Joint Dis 1950; 11:3-13.
  12. Chan G, Arkader A, Kleposki R, Dormans JP. Case report: primary aneurysmal bone cyst of the epiphysis. Clin Orthop Relat Res., 2010; 468:1168-72. [CrossRef]
  13. Ozaki T, Hillmann A, Lindner N, Winkelmann W. Cementation of primary aneurysmal bone cysts. Clin Orthop Relat Res 1997; 337: 240-8urettage through broad exposure in addition to grafting and rigid internal fixation.
  14. Enneking WF, Gearen PF. Fibrous dysplasia of the femoral neck: treatment by cortical bone grafting. J Bone Joint Surg [Am] 1986; 68-A:1415-22. PubMedWeb of ScienceGoogle Scholar.
  15. Hu YC, Lun DX, Zhao SK. Combined anterior and lateral approaches for bone tumors of the femoral neck and head. Orthopedics. 2012; 35: e628–634. [PubMed]