



International Journal of Orthopaedics Sciences

ISSN: 2395-1958
IJOS 2018; 4(1): 1018-1024
© 2018 IJOS
www.orthopaper.com
Received: 25-11-2017
Accepted: 26-12-2017

Dr. Rahul Gopikishan Jaju
Assistant Professor, Department
of Orthopaedics, Government
Medical College Aurangabad,
Maharashtra, India

Dr. Ansari Muqtadeer Abdul Aziz
Head of Unit and Associate
Professor, Department of
Orthopaedics, Government
Medical College Aurangabad,
Maharashtra, India

Dr. Girish Gadekar
Associate Professor,
MGM medical College,
N-6, CIDCO, Aurangabad,
Maharashtra, India

Functional evaluation of management modalities of three and four part proximal humeral fractures

Rahul Gopikishan Jaju, Ansari Muqtadeer Abdul Aziz and Girish Gadekar

DOI: <https://doi.org/10.22271/ortho.2018.v4.i1o.145>

Abstract

Introduction: Three and four –part fractures represent 13%-16% of proximal humeral fractures. They occur more frequently in older patients after the cancellous bone has become weakened by senility and osteopenia. Treatment options for these displaced fractures include closed reduction and k-wire fixation, open reduction and internal fixation and arthroplasty. The purpose of the present study was to evaluate the functional results in patient with three and four-part proximal humeral fractures treated by different modalities, over a period of 2 years.

Materials and Methods: We present a retrospective study of 40 three-part and four part proximal humeral fractures according to Neer's classification, treated by simple technique of Kirschner wire Osteosynthesis, open reduction and internal fixation with clover-leaf plate or proximal humeral locking plate system (PHILOS) and hemiarthroplasty of the proximal humerus. The criteria for inclusion were a diagnosis of undisplaced three-part fracture, displaced three and four part fractures confirmed by three independent observers.

Results: The study was conducted over a period of two years with an average follow up of 20.7 months (Range: 12 to 40 months). There were 14 undisplaced three-part fractures impacted in valgus, seven displaced three part fractures, two three-part fracture with dislocated head, four four-part fractures with dislocated head.

Conclusion: Three-and four-part proximal humeral fractures are difficult injuries to evaluate and treat. Nevertheless, an algorithm for treatment has been devised. Preoperative and intraoperative evaluation must address fracture pattern, bone quality, patient motivation, and expectations. A thorough knowledge of normal glenohumeral relationships is essential to achieve optimal surgical results.

Keywords: Proximal humerus, displaced, valgus, internal fixation, hemiarthroplasty

Introduction

The first proximal humerus fracture was documented by Hippocrates who described method of weight traction that aided in bone healing. Three and four-part fractures represent 13%-16% of proximal humeral fractures [1-4]. In younger patients, these fractures usually are caused by high-energy trauma and are usually fracture dislocations. In older patients with osteoporosis, trivial trauma can produce significant injury due to osteopenia. Einarsson in 1958 grouped his patients according to the number of fracture fragments, later the classification proposed by Neer-Svend Hansen in 1974 and Clifford in 1980 [2-4, 5, 6]. Einarsson states that 80% of 3 and 4-part fractures treated conservatively have good results. Treatment options for these displaced fractures include closed reduction and k-wire fixation, open reduction and internal fixation and arthroplasty [4, 5]. The preferred treatment varies depending on the patient's age and bone quality, the expertise of the surgical team, and patients expectations. Most fractures of the proximal humerus are minimally displaced two-part fractures and can be successfully treated non-operatively. These patients with three and four part fractures were treated with closed reduction and k-wire fixation, open reduction and internal fixation with a clover leaf buttress plate, proximal humeral locking plate system (PHILOS) or hemiarthroplasty of the shoulder depending upon the fracture configuration, geometry, patients age bone quality and physical demands [6]. In 1957 Knight-Mayne suggested prosthetic replacement of proximal fracture dislocations and severely comminuted fractures [7]. Neer recommended open reduction and internal fixation for displaced two and three part proximal humeral fractures and arthroplasty for four-part fractures [8, 9].

Correspondence:

Dr. Ansari Muqtadeer Abdul Aziz
Head of Unit and Associate
professor, Department of
Orthopaedics, Government
Medical College Aurangabad,
Maharashtra, India

The preferred method for 3-part fractures was open reduction (41.9% with excellent or satisfactory results) and that for 4-part was prosthetic replacement in the series of Bandi (1976) which was not sub grouped according to number of fracture fragments, results were good in 68% of the patients treated with open reduction^[10, 11]. Thus, if we analyse the evolution of treatment of proximal humeral fractures the trend has been towards open reduction and internal fixation due to the availability of newer implants and instrumentation provided by the AO group for the severely comminuted fractures^[10, 11]. The purpose of the present study was to evaluate the functional results in patients with three and four-part proximal humeral fractures treated by different modalities, over a period of 2 years.

Materials and Methods

Forty patients of three and four part undisplaced and displaced fractures of proximal humerus, admitted and treated at sancheti institute for orthopaedics and rehabilitation, pune. They were treated with closed reduction and k-wires, open reduction and internal fixation with plates, hemiarthroplasty of the shoulder joint depending on age, fracture geometry, comminution, quality of bone, functional requirements of the patient and general medical condition of the patient. We present a retrospective study of 40 three-part proximal humeral fractures according to Neer's classification, treated by simple technique of Kirschner wire Osteosynthesis, open reduction and internal fixation with clover-leaf plate or proximal humeral locking plate system (PHILOS) and hemiarthroplasty of the proximal humerus.

Inclusion criteria

1. Undisplaced three-part fracture,
2. Displaced three and four part fractures confirmed by three independent observers,
3. Good mental and physical health,
4. Adequate cooperation in rehabilitation and well documented follow-up of at least 12 months.

There were three compound comminuted fractures (7.5 %) of the proximal humerus which were initially treated with thorough debridement under general anaesthesia and intravenous antibiotics till wound was healing without signs of infection then definitive fixation depending on the geometry of the fracture. Out of these three compound cases there were two cases (5%) with associated brachial plexus injury which were treated with repair of the brachial plexus three months post fixation of the proximal humeral fracture. Associated injuries were present in four cases, one with compound fracture upper end tibia, one with closed fracture lower end radius and closed fracture upper end tibia, one with compound supracondylar fracture femur, and one case had head injury with intertrochanteric fracture femur. All patients were followed up for an average of three months to two years.

A. Inclusion criteria for closed reduction and k-wire fixation

1. Undisplaced three or four part fractures defined as < 45 degree of angulation of articular surface or less than 1 cm of displacement between major fragments^[12, 13].
2. Where fracture is undisplaced or displaced, but there is no comminution
3. Where fracture can be reduced close but is stable.
4. Maintenance of gleno humeral congruity.
5. Poor general or medical condition of the patient especially elderly where short procedure is required.

B. Inclusion criteria for open reduction and internal fixation

1. Young age
2. Absence of comminution of head (intact humeral head).
3. Good bone quality.
4. An angulation of the articular surface of more than 45 degree
5. Displacement between the major fragments of more than 1 cm 6 Fracture with valgus impaction^[14].

C. Inclusion criteria for shoulder hemiarthroplasty

1. Four-part fracture dislocation with severe comminution.^{15,16}
2. Fragmentation of articular surface of the humeral head.
3. Severe osteoporosis
4. When articular segment of humeral head is separated from tuberosities and humeral shaft^[15-17].

Statistical Analysis: Statistical analysis was carried out on SPSS 16.0 version (Chicago, Inc., USA). The results are presented in mean \pm SD and percentages. The anatomical and functional results were compared by using Wilcoxon rank sum test. The $p < 0.05$ was considered significant.

Operative Technique

The patients were operated within three days of injury. Position of the patient: beach chair

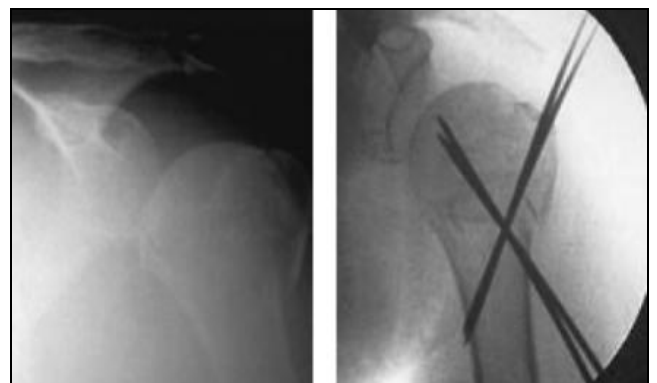
Operative technique of closed reduction and k-wire fixation

Reduction maneuver

Closed reduction is performed with the patient supine and the arm abducted 70-80 degree. The reduction maneuver is carried out with the shoulder abducted to 70-80 degrees progressive longitudinal traction is applied on the arm, and the humeral shaft is placed slightly lateral relative to the humeral head.

Pinning technique

With valgus impacted fractures, it is critical to pin the segment of the greater tuberosity in opposition to the segment of the humeral head as well as the humeral shaft. Two of the pins are passed through the humeral shaft just above the deltoid insertion and are directed superiorly from the lateral cortex. The third pin is passed from the anterior cortex into the humeral head. The pins are widely spaced in the fracture fragments. Proper placement of each pin in two planes, as far as the Subchondral bone, should be confirmed by image-intensification.



Operative technique of open reduction and internal fixation

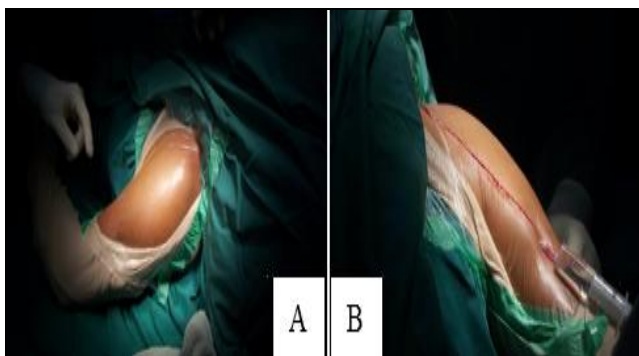
Approach

Standard deltopectoral approach in beach chair position under general anaesthesia with the surgical plane between deltoid and pectoralis major was used. In cases of fracture dislocation the joint capsule was opened to expose the distal articular surface. After achieving stable anatomic reduction the fracture was fixed with proximal humeral locking plate system (PHILOS) for humerus. Rotator cuff was sutured meticulously. Special care was taken to avoid damage to the soft tissue around the bicipital tuberosity to prevent damage to the nutrient artery to the head of the humerus [18, 19].

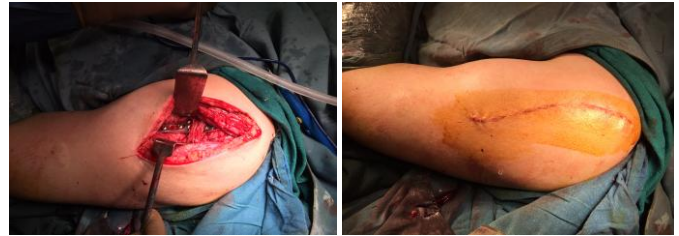Operative technique of shoulder hemiarthroplasty

Prosthetic replacement

At the time of endoprosthesis insertion it is important to take care of technical problems such as determination of the height of the prosthesis, the diameter of the head, version of the head, the fixation and height of the tuberosity, the type of fixation and the diameter of the stem. The height of the prosthesis is seen preoperatively by radiography of the contralateral side, allowing a preoperative plan to be made, or intraoperatively as judged by the position of the line of the fracture; there is usually a medial metaphyseal beak at the site of the fracture at the junction of the head and neck. The tension of the soft tissue when pulling the tuberosities around the head gives indication as to the appropriate height and size of the head. The diameter of the head of the prosthesis should be the same or very close to the measured diameter of the retrieved head, the exception being fracture-dislocations which are either anterior or posterior, in which added stability may be sought by using a head of slightly larger diameter. As a rule the version of the head should be determined with the arm at the side and the forearm on the abdomen; the centre of the head of the prosthesis should be facing the centre of the glenoid. Too much retroversion may stretch the rotator cuff and lead to pull-out of the tuberosity and too little may lead to loss of stability. In the case of posterior fracture-dislocations, less retroversion may ensure better stability, and inversely in the case of anterior fracture-dislocations more retroversion than usual may be necessary. The determination of retroversion should be tailored to each individual shoulder. The tuberosities should be fixed to the stem and the holes in the fins should be avoided. Sutures should pass circularly around the stem and when tightened should compress the fragments onto it. In all cases stems were fixed by cementing. To prevent stress shielding by a tight stem, adequate diameter of stem was used [20, 21].



A) Beach-chair position of patient (For Orif and P. S. R)
B) Deltopectoral Approach (For O. R. I. F and P. S. R)



C: Axillary Nerve Protected,

D: Final Closure.

Rehabilitation

In the immediate postoperative period with adequate analgesia, the arm is passively mobilised and elevated in the plane of the scapula as high as tolerated, two to three times a day. The patient is encouraged to exercise the hand, wrist and elbow. This is continued for six weeks after which active and passive movements are undertaken. Strengthening exercises are started at ten weeks depending on the fracture or consolidation of the tuberosity. All the patients were asked to follow up at 3 weeks, 6 weeks, 3 months and 6 months. The average stay of these patients in the hospital was 10 days after surgery.

At each follow up the following points were taken into consideration

1. Pain.
2. Function.
3. Range Of Motion.
4. Anatomy.

These criteria were proposed by Neer: The maximum points are 100 units [22, 23].

Pain: 35 Units

Function: 30 Units

Range of Movement: 25 Units and

Anatomy: 10 Units

On overall scores the patients were grouped into: Excellent: > 89 units Satisfactory: 80-89 units Unsatisfactory: 70-79 units and Failure: < 70 units.

Results

Forty patients of three and four part undisplaced and displaced fractures of proximal humerus were included in this study. The study extended from February 2004 to September 2006 with an average follow up of 20.7 months (range: 12 to 40 months). There were 14 undisplaced three-part fractures impacted in valgus, seven displaced three part fractures, two three-part fracture with dislocated head, four four-part fractures with dislocated head, ten displaced four part fractures, three compound displaced four part comminuted fractures. In 25 cases (62.5%) the injury affected the right shoulder and in 15 cases (37.5%) the left shoulder. The average age of the patients was 54.5 years (Range: 22 to 87 years) and 30 male (75%) patients and 10 (25%) of the patients were females. The causes of the fractures were accidental falls in 12 cases (30%), traffic accidents in 28 (70%) cases. Frequency of fracture occurrence according to Neer's classification is shown in Table 1

Table 1

Neer's type	No. Of cases	Percentage
Three part undisplaced	14	35%
Three part displaced	07	17.5%
Three part with dislocated head	02	5%
Four part displaced	10	25 %
Four part with dislocated head	04	10 %
Compound comminuted fractures	03	7.5 %

Following is table showing age wise distribution of patients and treatment given to them (Table 2)

Table 2: CRKW: closed reduction and k-wire fixation, ORIF: open reduction and internal fixation, PSR: partial shoulder replacement.

Age-Group	No. of patients	CRKW	ORIF	PSR
20-30	7 (17.5%)	3(7.5%)	4(10%)	0
31-40	2 (5%)	1(2.5%)	4(10%)	0
41-50	14 (35%)	2(5%)	8(20%)	1(2.5%)
51-60	07 (17.5%)	2(5%)	4(10%)	1(2.5%)
61-70	06 (15%)	2(5%)	3(7.5%)	1(2.5%)
71-80	02 (5%)	2(5%)	0	0
81-90	02 (5%)	1(2.5%)	0	1(2.5%)

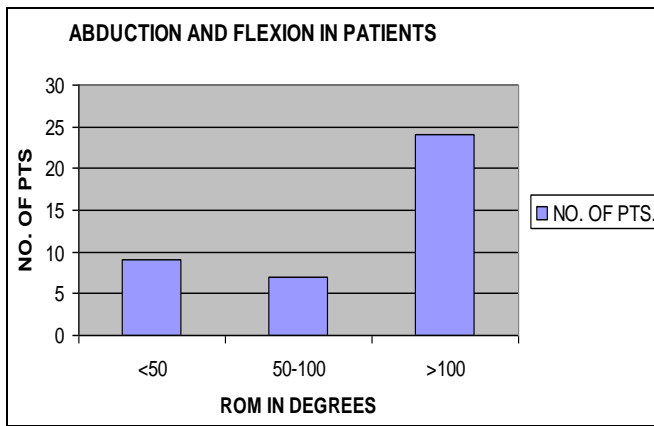


Chart 1

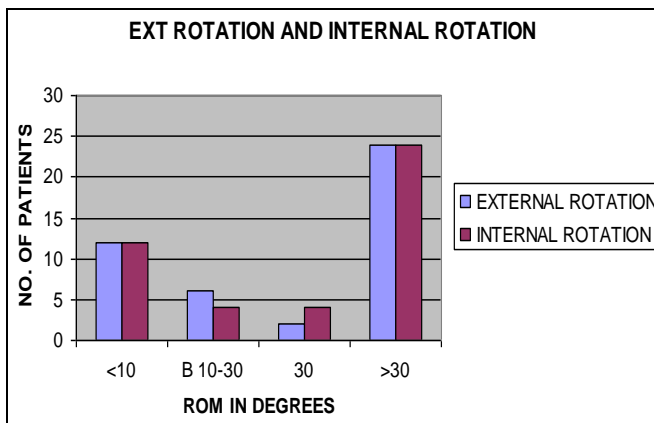


Chart 2

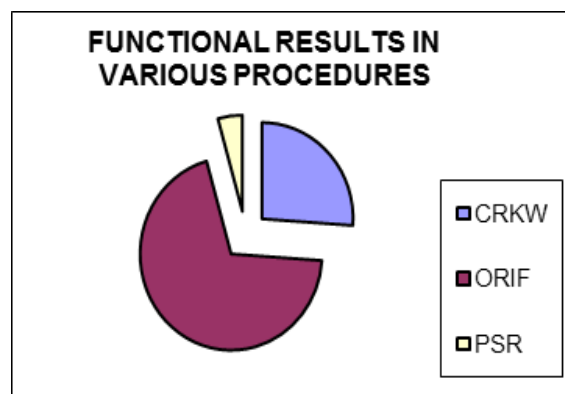
Function	No. of patients
Excellent	24 (60%)
Good	07 (17.5%)
Fair	02 (5%)
Poor (stiffness)	07 (17.5%)

Following is table showing Neer's scoring and our grading to evaluate the functional results in the patients:

Movement	Measurement	Neer's scoring	Our scoring
Internal rotation External rotation	>100 degree	Excellent	Excellent
Internal rotation External rotation	50-100	Satisfactory	Good
Internal rotation External rotation	<50	Failure	Poor

Movement	Measurement	Neer's scoring	Our scoring
Abduction Flexion	>100 degree	Excellent	Excellent
Abduction Flexion	50-100	Satisfactory	Good
Abduction Flexion	<50	Failure	Poor

Following is Final functional results according to Neer's scoring in various procedures



Anatomy

In this series 75% of the patients had perfect anatomic reduction and thus satisfactory to excellent results. The interrelationship between fixation of greater tuberosity and the resultant abduction was very evident. In 2.5% cases where the plate was placed at a higher level 10 degree to 15 degree of terminal abduction was restricted, we removed the implant after fracture union and the patient regained his movement.

Following is table showing final functional results and outcome in all patients

Discussion

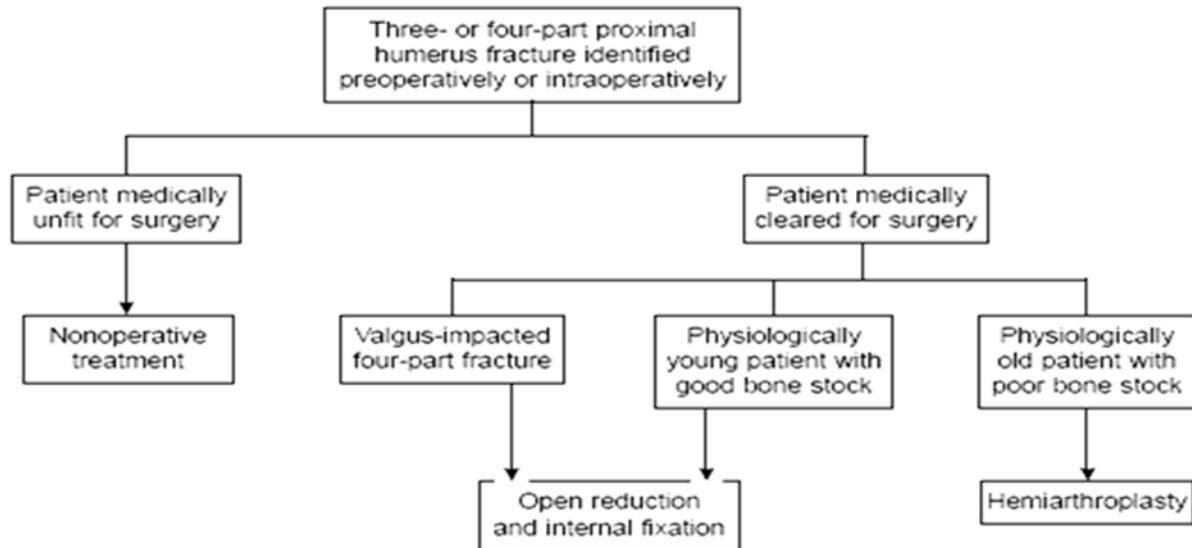
In 1970, Neer compared the results of various acute treatments for three-and four-part proximal humerus fractures. Thirty-nine patients with three-part fractures were treated by closed reduction. Only three patients had a satisfactory result according to Neer criteria. Thirty-eight patients with four-part fractures were also treated by closed reduction. None of these patients had a satisfactory result. Poor results [2-12, 19-25] in both groups were due to inadequate reduction, nonunion, disabling malunion, humeral head resorption, and/or osteonecrosis. Neer concluded that nonoperative treatment was inadequate for active patients [4-6]. Some investigators [1-4, 7-13] have suggested that the closed reduction or open reduction with limited soft tissue disruption and minimum fixation will reduce the prevalence of avascular necrosis [26]. That procedure makes sense, because it has been shown that the primary blood supply to the humeral head is the anterior humeral circumflex artery, which courses in the bicipital groove [1-13-19]. This is precisely the region that is disturbed by a more than limited dissection and application of a plate when open reduction and internal fixation is done. Jakob *et al* presented a technique of open reduction and limited dissection and fixation of three and four part valgus impacted fractures [23]. The success of both these techniques depends on preservation of whatever blood supply to the head of the humerus remains. Closed reduction and percutaneous pinning offers the same advantages when satisfactory closed reduction can be achieved but cannot be maintained without operative fixation of the fragments [9-13]. In 1991, Jakob *et al* emphasized the anatomic features of the four-part valgus-impacted fracture of the proximal humerus [23]. A valgus-impacted head fragment is the distinctive feature of this fracture pattern, which is important because the incidence of osteonecrosis is lower than it is for other displaced four-part proximal humerus fractures [28]. Either closed reduction or limited open reduction and minimal internal fixation led to a 74% satisfactory outcome in that study. The authors suggested that valgus-impacted fractures cause less destruction to the proximal humeral blood supply [25]. Resch *et al* evaluated the results of open reduction and minimal internal fixation of valgus-impacted four-part fractures without lateral displacement of the humeral shaft [8, 9]. They emphasized that in four-part fractures without lateral displacement of the humeral shaft, the periosteum along the medial humeral neck and head should be intact, thereby protecting the articular segment from osteonecrosis. In the technique described by Resch *et al* the medial periosteal soft-tissue hinge is preserved, the head segment is lifted into an anatomic position, bone graft is placed under the head, and the tuberosities are placed between the head and the shaft, thereby buttressing the head segment in a reduced position. Fixation was achieved with intraosseous sutures and interfragmentary screws and/or percutaneously placed Kirschner wires. Of the 22 patients in the study by Resch *et al*, 20 patients did not demonstrate any radiographic signs of osteonecrosis at a mean follow-up interval of 36 months (minimum, 18 months). These findings suggest that limited dissection combined with open reduction and internal fixation is the appropriate treatment for patients with valgus-impacted four-part fractures without lateral displacement of the humeral shaft [22, 23]. In elderly patients with lower physical demands and significant osteoporosis, Hemiarthroplasty may be a better option [27]. Gerber *et al* demonstrated that when osteonecrosis occurred in the setting of anatomic healing of the tuberosities, the clinical results were satisfactory at an average follow-up interval of

7.5 years [28]. This suggests that young patients with good bone quality may benefit from open reduction and internal fixation so long as secure anatomic fixation of the fragments can be achieved and maintained [4-6]. Neer's early description of open reduction for three-part fractures suggested that the outcome was extremely dependent on the technique of the surgeon. Overall, 11 of 30 three-part fractures in that series had an unsatisfactory result, with technical errors, occurring in 7 patients. Four-part fractures treated by open reduction consistently failed, most commonly secondary to osteonecrosis [28]. This led Neer to recommend open reduction and internal fixation for three-part fractures and prosthetic arthroplasty for displaced four-part fractures [2-4, 6-14-22]. Cuomo *et al* demonstrated that this method of treatment can achieve acceptable clinical results [29]. Koval *et al* found plate and screw fixation to be the most biomechanically stable [25]. In an analysis of the operative treatment of severe proximal humerus fractures using a plate, Paavolainen *et al* corroborate Neer's findings and found open reduction and internal fixation worth trying for three-part fractures but unsuccessful in the treatment of four-part fractures [18]. Lee and Hansen evaluated the incidence of post-traumatic osteonecrosis in displaced four-part proximal humerus fractures [29]. In 19 patients with an average follow-up of approximately 2 years, there were no reported cases of osteonecrosis [28]. These results correspond to our series where at average follow up of 20.7 months, we observed only one case (2.5%) of avascular necrosis of humeral head in a middle aged patient with comminuted fracture of humerus treated with ORIF. Therefore, the authors advocated early open reduction and internal fixation rather than primary prosthetic replacement. They argued that although some humeral heads with this injury develop early osteonecrosis, most are quickly revascularized by creeping substitution. It should be noted that some of the patients in that study had a follow up period of less than 1 year, where progression of osteonecrosis can take as long as 2 years to diagnose radiographically. More recently, Esser evaluated the presence and results of open reduction and internal fixation in 26 patients with three-or four-part fractures at an average follow-up interval of 6years. A modified cloverleaf plate was used for fixation. All fractures healed, and there were no cases of osteonecrosis. The author attributed the successful results to two factors: patient selection (young age and good bone quality) and surgical technique (limited exposure, careful soft-tissue dissection, use of small cancellous screws, and placement of the plate high on the head without impingement).³⁰ So we have concluded that open reduction and internal fixation should be the initial treatment of displaced three-and four-part proximal humerus fractures, and that primary prosthetic replacement should be reserved for four-part fractures in elderly patients with osteopenic bones and for any patient with poor bone quality [31]. These findings were corroborated by Savoie *et al*, who also had good results with the treatment of three-part fractures with plates and screws [32]. Elderly patients with displaced fractures and poor bone quality are the primary candidates for hemiprosthesis replacement [1, 17, 27]. Goldman *et al* evaluated the functional results in 26 patients treated with hemiarthroplasty for acute three-and four-part fractures. Nineteen patients (73%) reported slight or no pain postoperatively at an average follow-up interval of 30 months (range, 12 to 66 months). Active forward elevation averaged 107 degrees. Nineteen patients also reported difficulty in response to at least 3 of the 15 questions asked on the American Shoulder and Elbow Functional Questionnaire.

Although the patient pain scores indicated a generally good outcome, most patients had some functional loss due to postoperative stiffness. In 1992, Moeckel *et al* evaluated the results of modular cemented hemiarthroplasty for acute proximal humerus fractures in 22 patients at a mean follow-up interval of 36 months. Twenty patients had adequate relief of pain, with range of motion averaging 119 degrees of forward flexion, 40 degrees of external rotation, and internal rotation to the twelfth thoracic vertebra. We have concluded that although pain relief may be consistently expected in both,

earlier surgical intervention minimizes complications and maximizes function. The role of shoulder arthroplasty appears limited to elderly patients with preexisting shoulder pain and glenohumeral arthritis with osteoporosis who sustain a three- or four-part proximal humerus fracture with comminution [12-15-21-27].

Algorithm for the management of three and four part proximal Humerus fractures



Conclusion

Decision making about the treatment protocol of Three- and four-part proximal humeral fractures is difficult. Nevertheless, an algorithm for treatment has been devised. Preoperative and intraoperative evaluation must address fracture pattern, bone quality, patient motivation, and expectations. A thorough knowledge of normal glenohumeral relationships is essential to achieve optimal surgical results. Four-part valgus-impacted fractures may be treated with minimal dissection and osteosynthesis. In non-valgus-impacted fractures, age and bone quality will determine subsequent management. Patients who are physiologically young and have good bone quality will benefit from attempts to preserve the native anatomy with open reduction and internal fixation. Patients who are elderly and have poor bone quality are better treated with early hemiarthroplasty. Those who are medically unable to undergo the major surgery or rehabilitation may be treated by closed reduction and k wire osteosynthesis or nonoperatively. Postoperative complications are involve carefully supervised rehabilitation program.

Conflict of interest: nil

Funding: none

Ethical approval: not required

References

1. Bigliani LU. Fractures of the proximal humerus. In: Rockwood CA, Matsen FA, editors. The shoulder. Philadelphia: W.B. Saunders. 1990, 278-334.
2. Einarsson F. Fractures of the upper end of humerus. Acta Orthop Scand. 1958; 45(32).
3. Hawkins, *et al*. The three part fractures of the proximal humerus JBJS. 1986; 68-A:1410-1414.
4. Neer CS. Displaced proximal humerus fractures. Part 2. Treatment of 3-part and 4-part fracture displacement. J Bone Joint Surg. 1970; 52-A:1090-1103.
5. Neer CS. Displaced proximal humerus fractures. Part I. Classification and evaluation. J Bone Joint Surg 1970; 52-A:1077-1089.
6. Neer CS II, Rockwood CA. Fractures and dislocations of the shoulder. In: Rockwood CA, Green DP, editors. Fractures. 2nd ed. Philadelphia: JB. Lippincott. 1984, 675-707.
7. Knight RA, Mayne JA. Comminuted fractures and fracture dislocations involving the articular surface of the humeral head. J Bone Joint Surg. 1957; 39-A:1343-1355.
8. Resch, *et al*. Percutaneous fixation of three and Four part fractures of the proximal Humerus JBJS Br. 1997; 79:295-300.
9. Rockwood CA, Green DP. (Editors). Fractures in adults. Philadelphia: J.B. Lippincott. 1984, 675-722.
10. Moda SK. Open reduction and fixation of proximal humerus fractures. J.B.J.S. 1990; 72B:1050-2.
11. Wijnman GA, *et al*. Open Reduction and Internal fixation of three and four part fractures of the proximal humerus. J.B.J.S (Am). 2002; 84:1919-25.
12. Flatow EL. Fractures of the proximal Humerus In; Fractures in Adults 5th end (Buchloz *et al*.) Lippincott, Williams and Wilkins Philadelphia. 2001; 997-1040.
13. Jaberg, *et al*. Percutaneous Stabilisation of the unstable fracture of the proximal humerus. JBJS Am. 1992; 74:508-15.
14. Esser RD. Treatment of Three and Four Part Fractures Of the Proximal Humerus with a Modified Cloverleaf Plate. J orthop Trauma. 1994; 8:15-22.
15. Dines DM, Altchek DW. Hemiarthroplasty techniques for proximal humerus fractures. Complications Orthop. 1991; 6:25-31.

16. Dines DM, Coleman S, Warren RF. Arthroplasty for acute and chronic fractures of the proximal humerus. *Orthopaedics Spec Ed.* 2000; 1(4):26-34.
17. Bigliani LU, McClusky GN. Prosthetic replacement in acute fractures of the proximal humerus. *Semin Arthroplasty.* 1990; 1:129-137.
18. Paavolainen P, *et al.* Operative treatment of severe proximal humerus fractures. *Acta Ortho Scand.* 1983; 54:374-9.
19. Liang PG. The anterior blood supply of the adult humerus. *J Bone Joint Surg.* 1956; 38-A:1105-1116.
20. Bigliani LU, Flatow EL, McClusky GN, Fisher RA. Failed prosthetic replacement for displaced proximal humeral fractures. *Orthop Trans* 15:744-748.
21. Dines DM, Warren RF. Modular shoulder hemiarthroplasty for acute fractures. *Clin Orthop Relat Res.* 1994; 307:18-26.
22. Hawkins, *et all.* Internal fixation techniques for the proximal humeral fractures *Clin Orthop.* 1987; 223:77-85.
23. Jakob RP, Miniaci A, *et al.* Four-part valgus impacted fractures of the proximal humerus. *J Bone Joint Surg.* 1991; 73-B:295-298.
24. Dines DM, Warren RF, Altcheck DW, *et al.* Post traumatic changes of the proximal humerus: malunion, nonunion and osteonecrosis: treatment with modular hemiarthroplasty or total shoulder arthroplasty. *J Shoulder Elbow Surg.* 1993; 2:11-21.
25. Koval, *et al.* Functional outcome after minimally displaced fractures of the proximal humerus. *JBJS (Am).* 1997; 79:203-7.
26. Lee CK, Hansen HR: Post-traumatic avascular necrosis of the humeral head in displaced proximal humeral fractures. *J Trauma.* 1981; 21:788-791.
27. Compito CA, Self EB, Bigliani LU. Arthroplasty in acute shoulder trauma. *Coordination.* 1994; 307:27-36.
28. Gerber C, Hersche O, Berberat C. The clinical relevance of posttraumatic avascular necrosis of the humeral head. *J Shoulder Elbow Surg.* 1998; 7:586-590.
29. Cuomo F, Zuckerman JD, *et al.* The effect of tuberosity placement on results of hemiarthroplasty for fractures of the proximal humerus. Presented at the open and closed meetings of the American Shoulder and Elbow Society, Orlando, Florida, and Philadelphia, 1999, 2000.
30. Esser RD. Treatment of Three and Four Part Fractures Of the Proximal Humerus with a Modified Cloverleaf Plate. *J orthop Trauma.* 1994; 8:15-22.
31. John Naranja R, *et al.* Displaced Three and Four Part Fractures of the Proximal Humerus: Evaluation And Management. *Journal of American Academy of orthopaedic Surgeons.* 2000; 8:373-382.
32. Savoie FH, Geissler WB, Vander Griend RA. Open reduction and internal fixation of three-part fractures of the proximal humerus. *Orthopedics.* 1989; 12:65-70.