



# International Journal of Orthopaedics Sciences

ISSN: 2395-1958  
IJOS 2018; 4(1): 944-946  
© 2018 IJOS  
www.orthopaper.com  
Received: 26-11-2017  
Accepted: 27-12-2017

**Ravikant Jain**  
Professor and Head of  
Department, Department of  
Orthopaedics, SAMC & PG  
Institute, Indore, Madhya  
Pradesh, India

**Nihit Mantri**  
Junior Resident, Department of  
Orthopaedics, SAMC & PG  
Institute, Indore, Madhya  
Pradesh, India

**Dr. Pranav Mahajan**  
Assistant Professor, Department  
of Orthopaedics, SAMC & PG  
Institute, Indore, Madhya  
Pradesh, India

**Correspondence**  
**Dr. Pranav Mahajan**  
Assistant Professor, Department  
of Orthopaedics, SAMC & PG  
Institute, Indore, Madhya  
Pradesh, India

## Comparison between CC Screw and tension band wiring in treatment of medial malleolus fracture

**Ravikant Jain, Nihit Mantri and Dr. Pranav Mahajan**

**DOI:** <https://doi.org/10.22271/ortho.2018.v4.i1n.136>

### Abstract

**Introduction:** Ankle fractures are common fractures treated by orthopaedic surgeons. There has been an increased prevalence of such fractures over the last two decades both in young, active patients and in elderly <sup>[1]</sup>. Unimalleolar fractures are the most common injury of all ankle fractures <sup>[2]</sup>. Isolated medial malleolus fractures are less common than lateral malleolar fractures. Still they constitute a significant portion of ankle injuries and historically their treatment has been controversial. There is a concern that a non operative approach may fail to produce an anatomical reduction of the mortise, leading to ankle instability, non union and post traumatic osteoarthritis of the ankle.

**Objectives:** To evaluate functional and radiological out-come of medial malleolus fractures of ankle joint managed by various modalities along with its intra as well as post operative complications. To evaluate functional recovery of patient at follow up of 1,3,6,9 months. To calculate total time taken for union of fracture.

**Material and Methods:** Present study consists of 30 patients with medial malleolus fractures treated in Department of Orthopedics, SAMC and PGI, Indore, during September 2015 to September 2017.

**Results:** 80% of the patients showed excellent results in our study, and 20% showed good results after 9 months.

**Conclusion:** Open reduction and internal fixation of medial malleolus fractures with CC screws or TBW produced reliable results, with acceptable range of movement and resuming back to activities of daily living. In our study fractures fixed with CC screws produced 69.23% excellent results and those fixed with TBW produced 88.23% excellent results according to Baird and Jackson scoring system after 9 months.

**Keywords:** infection, trauma, surgical complication, ankle injury, unstable ankle

### Introduction

Ankle fractures are common fractures treated by orthopaedic surgeons. There has been an increased prevalence of such fractures over the last two decades both in young, active patients and in elderly <sup>[1]</sup>. Unimalleolar fractures are the most common injury of all ankle fractures <sup>[2]</sup>. Isolated medial malleolus fractures are less common than lateral malleolar fractures. Still they constitute a significant portion of ankle injuries and historically their treatment has been controversial. There is a concern that a non-operative approach may fail to produce an anatomical reduction of the mortise, leading to ankle instability, nonunion and post traumatic osteoarthritis of the ankle.

The epidemiology of ankle fractures is changing; with increased prevalence in elderly population with osteoporotic bones mainly due to increased longevity and more cases of open fractures related to road traffic accidents; the trend is to treat the fracture in order to achieve anatomical articular reduction and to prevent instability and non union. The medial malleolus is closely interrelated with the deltoid ligament which originates from medial malleolar osteo-ligamentous complex and it is very important for ankle fracture stability.

Although fractures about the ankle have traditionally been considered non-controversial with respect to the indications for operative intervention, recent advances in understanding of the biomechanics of the ankle joint have given rise to particular areas of clinical uncertainty.

### Materials and Methods

Present study consists of 30 patients with medial malleolus fractures treated in Department of

Orthopedics, SAMC and PGI, Indore, during September 2015 to September 2017

Patient selection criteria:

**Inclusion criteria**

1. Patients having medial malleolus fracture of ankle joint.
2. Patients of both sex & in age groups of 18-65 years.
3. Patients who are fit for surgery.

**Exclusion criteria**

1. Open ankle fracture.
2. Patients less than 18 years.
3. A previous fracture of either ankle.
4. Patient having bilateral ankle fracture.
5. Patient having any other fracture in ipsilateral limb.

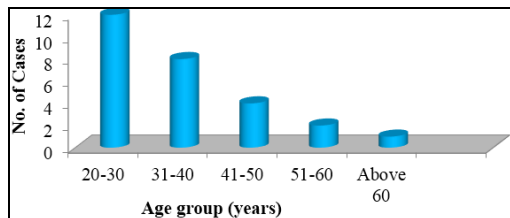
**Observation and Results**

Present study consists of 30 patients with medial malleolus fractures treated in Department of Orthopedics, SAMC and PGI, Indore, during September 2015 to September 2017

**Table 1:** Age Wise Distribution (N=30)

Age (years)	No. of patients	Percentage
20-30	15	50%
31-40	8	26.7%
41-50	4	13.33%
51-60	2	6.6%
Above 60	1	3.33%
Total	30	100%

In this study, patients were in the age group between 20-75 years, majority (90.00%) of the patient in the age group of 21-50 years, maximum incidence being in the age group of 20-30 years (50%). In present study the minimum age group of patient was 20 years, and maximum was 75 years and average age was found to be 33.1 years.

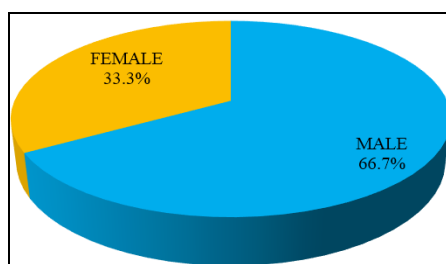


**Graph 1:** Age wise Distribution

**Table 2:** Gender wise distribution (N=30)

Gender	No. of Cases	Percentage
Male(M)	20	66.7
Female(F)	10	33.3
Total	30	100.0

The ratio between male is to female in this study was 2:1(M:F). There was definite male preponderance.

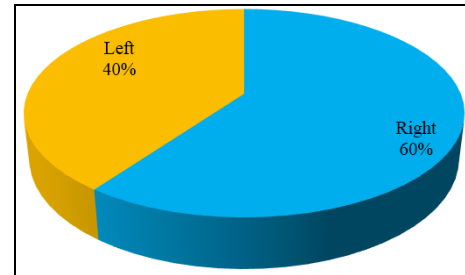


**Graph 2:** Genderwise distribution

**Table 3:** Distribution according to side involved (N=30)

Side Involved	Frequency	Percent
Right	18	60
Left	12	40
Total	30	100.0

The above table shows that right side was involved in 60% of cases and left side was involved in 40% of cases. The right side was involved slightly more than left.



**Graph 3:** Distribution according to side involved

**Discussion**

Present study consists of 30 patients having medial malleolar fractures treated with internal fixation with Tension Band Wiring and CC screw in Department of Orthopaedics, SAMC and PGI, Indore, September 2015 to September 2017.

I will be comparing my data, analysis, and results in our study with the series done by Dr. Maruthi CV and Dr. Shivanna<sup>62</sup> which was a prospective study to know the clinical and radiological outcome in the management of the medial malleolar fractures by tension band wiring. They studied 14 cases of transverse medial malleolar fractures admitted in hospital from January 2010 to October 2014 managed by open reduction and internal fixation with tension band wiring technique. Ayyoub A. Mohammed, Khalid Ahmed Abbas and Ammar Salah Mawlood<sup>56</sup>, they grouped 20 patients with fractured medial malleolus into two groups of operative treatments, group1 treated by malleolar screw fixation and group2 by tension band wiring.

**Age Distribution**

We had patients of age ranging from 20-75 years, majority (90.00%) of the patient in the age group of 21-50 years, maximum incidence being in the age group of 20-30 years (50%).

Average age in our study was 33.1 years.

In present study the minimum age group of patient was 20 years, and maximum was 75 years and average was found to be 33.1 years in comparison to Maruthi CV *et al.* <sup>[6, 2]</sup> study the minimum age group of patient was 20 years, and maximum was 60 years and average was found to be 28.16 years and Mohammed *et al.* <sup>[5, 6]</sup> study where median age was 37 years in both age group, with the range of 24–50years in group 1 and 21–53years in group 2.

**Table 4:** Comparison of average, minimum and maximum age in our study with other studies.

	Minimum age (years)	Maximum age (years)	Average age (years)
Maruthi CV <i>et al.</i> <sup>[6, 2]</sup>	20	60	28.16
Mohammed <i>et al.</i> <sup>[5, 6]</sup>	24	50	37
Our study	20	75	33.1

People between the age group of 21-50 years are more prone to accidents due to their profession and increased vehicular usage.

### Gender

We had 20 males (66.7%) and 10 females (33.33%) patients in our study. The male to female ratio is 2:1. The preponderance of male is because:

- Males are more prone to outgoing, hence more vulnerable to vehicular accidents.
- Due to usual society practice, certain tasks which involve high risk are done by males e.g. working at height, driving, labour and travelling.

In Maruthi CV *et al.* [6, 2] study there were 9 males and 5 females and, in Mohammed *et al.* [5, 6] study the ratio was 4:6

### Results

80% of the patients showed excellent results in our study, and 20% showed good results after 9 months.

In Maruti CV *et al.* [6, 2] study, excellent results were achieved in 11 cases (78.57%) and good in 3 cases.

In Mohammed *et al.* [5, 6] study, excellent and good results were achieved in 80 % in group1 patients and 90 % in group2 patients.

### Summary and Conclusion

Medial malleolus is commonly involved in vehicular accidents, as it is subcutaneous in comparison with other bones. Fracture of medial malleolus is more innocuous owing to it being involved in wound complication and infections. These are common controversies of fracture fixation in this bone because of it being involved in weight bearing and fractures are commonly associated with compromised soft tissues, also any form of abnormality in fracture fixation can result in functional impairment. As against western culture, in India where activities like squatting and cross legged sitting are common, medial malleolus require anatomical reduction and fixation.

With our prospective study we concluded that medial malleolus fractures can be well managed by primary internal fixation either with CC screws or TBW.

Open reduction and internal fixation of medial malleolus fractures with CC screws or TBW produced reliable results, with acceptable range of movement and resuming back to activities of daily living. No statistical differences were found between anterior and posterior surgical approaches. Open reduction with internal fixation either with TBW or CC screws provides a secure, easily applied solution for the challenging medial malleolus fractures. In our study fractures fixed with CC screws produced 69.23% excellent results and those fixed with TBW produced 88.23% excellent results according to Baird and Jackson scoring<sup>48</sup> system after 9 months.

Primary internal fixation with CC screws or TBW is single staged procedure with minimal financial burden of rural population. A trained surgeon, efficient preoperative planning, and a well-planned postoperative protocol are important for improving the outcome.

### References

1. Al-Lamy, Al-Obaidy *et al* Comparative Study of internal fixation of displaced closed fracture of medial malleolus using malleolar screw versus tension-band Wiring: Karbala J. Med, 2008, 2(4).
2. Court-Brown CM, McBirnie J, Wilson G. Adult ankle fractures- an increasing problem? Acta Orthop Scand. 1998; 69(1):43-47.
3. Pradeep Choudhari *et al.* Comparative study of one

- versus two Screws in treatment of isolated fracture of medial malleolus: International Journal of Current Medical and Applied Sciences. 2015; 7(3):151-154.
4. Egol KA, Tejwani NC, Walsh MG, *et al.* Predictors of short-term functional outcome following ankle fracture surgery. J Bone Joint Surg Am. 2006; 88:974-979.
5. Obremskey WT, Dirschl DR, Crowther JD, *et al.* Change over time of SF-36 functional outcomes for operatively treated unstable ankle fractures. J Orthop Trauma. 2002; 16:30-33.
6. Porter DA, May BD, Berney T. Functional outcome after operative.