



International Journal of Orthopaedics Sciences

ISSN: 2395-1958
IJOS 2018; 4(1): 737-744
© 2018 IJOS
www.orthopaper.com
Received: 27-11-2017
Accepted: 28-12-2017

Dr. Parth Deshmukh
SBKS Medical College and
Research Center
Pipaira, Waghodia, Vadodara,
Gujarat, India

Dr. Yogesh C Patel
SBKS Medical College and
Research Center
Pipaira, Waghodia, Vadodara,
Gujarat, India

Dr. Hiren Patel
SBKS Medical College and
Research Center
Pipaira, Waghodia, Vadodara,
Gujarat, India

Dr. Sudhir Kumar Rawat
SBKS Medical College and
Research Center
Pipaira, Waghodia, Vadodara,
Gujarat, India

Dr. Vikramjit Singh Baat
SBKS Medical College and
Research Center
Pipaira, Waghodia, Vadodara,
Gujarat, India

Dr. Ajay Mandloi
SBKS Medical College and
Research Center
Pipaira, Waghodia, Vadodara,
Gujarat, India

Dr. Anirudh Bansal
SBKS Medical College and
Research Center
Pipaira, Waghodia, Vadodara,
Gujarat, India

Correspondence
Dr. Sudhir Kumar Rawat
SBKS Medical College and
Research Center
Pipaira, Waghodia, Vadodara,
Gujarat, India

Outcome of open reduction and internal fixation with plate in fractures shaft of humerus

**Dr. Parth Deshmukh, Dr. Yogesh C Patel, Dr. Hiren Patel, Dr. Sudhir
Kumar Rawat, Dr. Vikramjit Singh Baat, Dr. Ajay Mandloi and
Dr. Anirudh Bansal**

DOI: <https://doi.org/10.22271/ortho.2018.v4.i1k.107>

Abstract

Background and Objectives: Fractures of shaft of humerus consists of 1% - 3% of all fractures. Despite the numerous surgical modalities, plate osteosynthesis remains the gold standard for fixation of humerus shaft fractures. The aim of this study is to see the functional results of humerus shaft fractures treated with plating, reemphasizes the effectiveness of plate osteosynthesis in the management of humeral shaft fractures so as to restore the patient structurally and functionally to near normal status.

Materials and Methods: This is retrospective and prospective study of 30 cases of fractures of shaft of humerus admitted at S.S.G. Hospital, Vadodara, Gujarat in between July 2015 to June 2016. Cases were selected as per inclusion and exclusion criteria. All patients were operated using posterior or anterolateral approach. They were assessed radiologically and clinically for fracture union at regular intervals of 6 wks, 12 wks and 18wks by using DR. R.N. Deweshwar's Score.

Results: Our study of 30 cases, there were 25 men and 5 women, with average age of 39 years. 16 (53.33%) patients were admitted due to fall from height, 12 (40%) due to road traffic accidents and 2 (6.66%) patients due to assault with predominance of right side 20 (66.66%) patients. Out of 30 cases 21 (70%) patients of middle third, 7 (23.33%) were lower third, and 2 (6.66%) were upper third. 28 patients having close fractures and 2 have open injury. Simple transverse fractures were most common that is 12 (40%). 10 (33.33%) patients were having associate injuries. The fracture united in 29 (96.66%) patients with 1 (3.33%) patient going for non-union. Good and full range of shoulder and elbow movements was present in 28 (93.33%) patients with 2 patients having fair shoulder range of movement and 2 patients having fair elbow range of movement.

Conclusion: Open reduction internal fixation with plating is an excellent mode of treatment in fracture of shaft of humerus, which consistently gives long term good results.

Keywords: Fracture shaft of humerus, ORIF, DCP, LCP

Introduction

Fractures of shaft humerus consists of 3% -5% of all fractures [1-3]. It is a common fracture of upper limb. Fractures of shaft humerus are increasing in frequency day by day due to rising population and modernization. Number of multiple injured patients having fracture of shaft of humerus are also increasing as are open fractures of humerus especially after vehicular accidents and work place injuries. The study of fracture of shaft humerus is important due to chances of these fractures to go in malunion (in closed fractures) and non-union (in open fractures) are more [4-8]. The functional disability to the patient after these fractures is a hindrance in earning their daily living especially when dominant extremity involved. Prolonged immobilization leads to stiffness of elbow, weakness of muscle, shoulder hand syndrome.

Operative treatment is indicated for failure to obtain or maintain acceptable alignment after closed reduction, displaced intrarticular and juxtarticular extension of shaft fractures, fractures associated with vascular or nerve injuries or both ipsilateral adjacent fractures, open fractures and non union of fracture of humerus [9-13]. In properly selected cases operative treatment has many advantages. They included anatomical reduction, stable fixation and early mobilization leading to decreased morbidity [14-16].

Once operative management with surgical stabilization is considered several options exist including compression plate and screw osteosynthesis, intramedullary nailing and external fixation. External fixation is most useful in open fractures and in circumstances as infected non unions, fractures with significant soft tissue disruption and severe burns. Disadvantages include pin tract- infection, delayed union, non union, pin loosening and complications related to passing pins through soft tissue like radial palsy^[17-20].

In literature results of humerus plating and nailing are almost similar however humerus interlock nailing has few disadvantages like^[21-25].

- Shoulder abduction restricted because of rotator cuff injury.
- Not suitable implant for humerus having narrow canal
- Not very useful in humerus having deformity because like plate there is no contouring facility in nail
- Requires large instrument set.
- Requires help of radiography.
- Technically more demanding procedure.
- No facility of achieving compression at fracture site.

Plate fixation is a time honored procedure extensively studied over a long period of time giving satisfactory results^[26-29].

Advantages of plate fixation are

- It provides anatomical reduction and rigid fixation.
- Compression can be achieved at fracture site.
- Restriction of shoulder movement is negligible.
- Due to rigid fixation early mobilization is possible.
- It does not require large set of instrumentation or help of radiography.

Material and Methods

This is retrospective and prospective study of 30 cases of fractures of shaft of humerus admitted at S.S.G. Hospital, Vadodara, Gujarat in between July 2015 to June 2016. Cases were selected as per inclusion and exclusion criteria. All patients were operated using posterior or anterolateral approach. They were assessed radiologically and clinically for fracture union at regular intervals of 6 wks, 12 wks and 18 wks by using DR. R.N. DEWESHWAR'S SCORE.

Aims and objectives of study

1) To clinically evaluate the

- a) Rate of union.
- b) The functional outcome of the treatment.
- c) Incidence of complications like non-union, Infection, Radial nerve palsy.

2) To compare the results of my study with the reported work.

Criteria for patient selection

1. Adults above the age of 18 years
2. Fresh fracture with or without neurovascular deficit
3. Close fracture, fracture with open Grade I and II were also included.

Treatment Protocol

All the patients were treated according to protocol which consisted of:

1. Standard A.P. & lateral plain X-ray.
2. Open wound were taken to operation theatre for wound debridement on emergency basis as early as possible.
3. Poly trauma patients were fixed as

4. Shoulder range of movement and elbow range of movement exercises started according implant used and stability of fixation of fracture, post operatively.
5. Patients discharged with AE slab or humerus brace depending on stability of fixation.
6. Weight lifting and routine work, is allowed according to union status radiologically and clinically.
7. Patients follow up depended on the clinical examination as well as the xray findings.

Method of Treatment

Primary Treatment:

- All patients detail history is taken.
- A thorough examination of the patient was done.
- Patients were sent for X-rays. X-rays of humerus with shoulder and elbow joint in AP and lateral view were taken.
- All patients were given initially HAE slab and admitted.

Fractures were then classified using the AO classification of fracture shaft humerus

Classification of all fractures were then classified using the AO classification of fracture shaft humerus. Open fractures were classified according to the Gustilo- Anderson classification

The goal of treatment was to achieve anatomical reduction and stable fixation.

Following principles were followed in our study:-

- Precise pre-operative planning.
- Gentle handling of soft tissues.
- Anatomical reduction of the fractures.
- Rigid, stable fixation.
- Early and active rehabilitation of the limb and the patients

Pre-Operative planning

- All patients in whom surgery was planned were investigated in form of the routine blood investigation, EGG, and other indicated investigations.
- Good quality antero-posterior and lateral radiograph of the shoulder with arm and elbow with arm for diagnosis and to study fracture pattern.
- Pre-operative planning in the form type and geometry of fracture, bone quality, types of plate, width of plate, length of plate, number of screws, number of interfragmentary screw and number of screw holes occupying plate was decided.
- Pre-operatively antibiotic were essential in open injuries.

Operative details

- Open reduction and humerus plating done under brachial block or GA.
- Before shifting the patients in recovery room post-operatively, the distal pulses were checked.
- Post operatively collar and cuff sling given in all patients.
- We have done procedure by two approaches:
 1. Anterolateral: For upper 1/3 shaft humerus
 2. Posterior: For M/3 and L/3 shaft humerus

Post operative management

- Postoperative patients were immobilized with AE slab from next postoperative day morning.
- Postoperative analgesic is given according to patients complain.
- Intravenous antibiotics given for 1st 5 days then shifted to oral antibiotics.
- 1st dressing done on 3rd post-operative day and wound

condition noted.

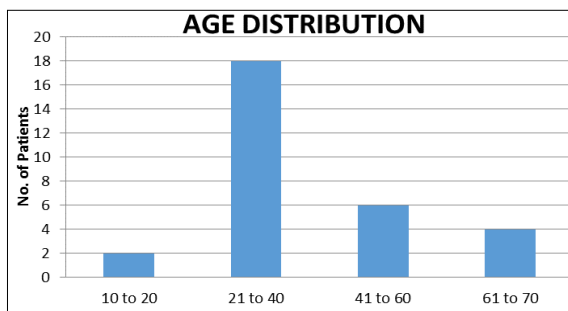
- 2nd post-operative dressing done on 8th day.
- After that patients was discharged with oral antibiotics and analgesics and with AE slab and called on 12 to 14th post-operative day for suture removal.
- After suture removal we have given humerus brace to patients whose fracture fixed with LCP and other patients given AE Slab till SR followed by shoulder and elbow mobilization and was advised to come at 6 weeks.

Follow-Up Regime

- Patients were called for follow up at duration of 6 weeks and clinically status and fracture union noted. X-rays were taken to confirm the progress of union. The shoulder and elbow range of motion were noted. Any complaints regarding pain is noted. Any improvement in post-traumatic radial nerve palsy noted.
- Patients were regularly followed up at regular intervals till fracture was completely united. All patients were called for regular physiotherapy for improvement of shoulder and elbow movements.
- Patients were evaluated clinically and radiologically as per the criteria formulated by Dr. R.N. Daveshwar, graded according to a point system:
 1. Pain
 2. Range of Motion at shoulder and elbow
 3. Radiological evaluation for reduction status, fracture union and infection.
 4. Anatomical evaluation in terms of varus/valgus deformity and fixed flexion deformity.
 5. Functional outcome (work)
 6. Neurological status (Radial Nerve palsy)

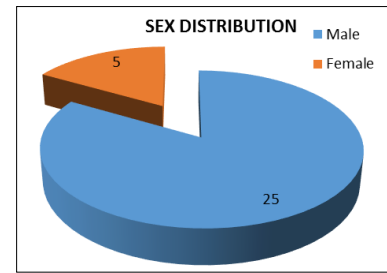
Observation

Age Distribution

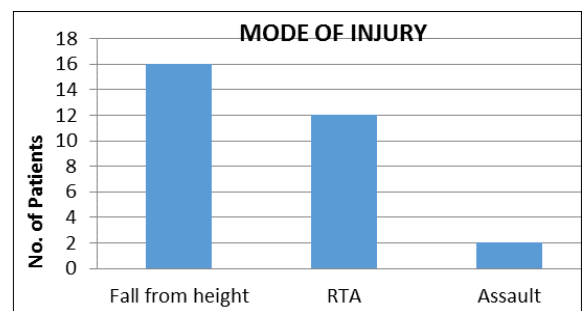


- In our study patients are of age group between 18-70 years.
- Majority of our patients are young age group. 60% patients in 21-40 years.

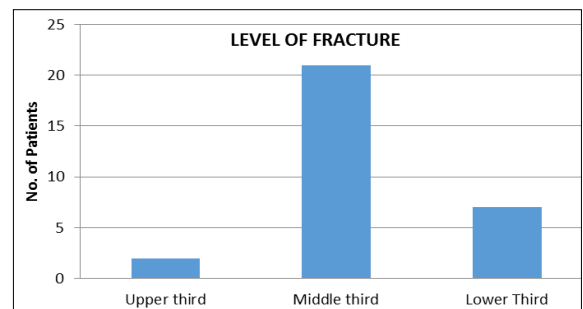
Sex Distribution



- The ratio between Male to Female is 5:1.
- There was male dominance. The lower of fracture in female are attributed to their lesser involvement in outdoor activities.
- The male dominance is attributed to outdoor travelling for bread.
- Most of patients had sustained fracture with fall from height.
- In our study it comprises 16 patients (53.33%). Whereas 2 patients had assault injury.



Level of Fracture



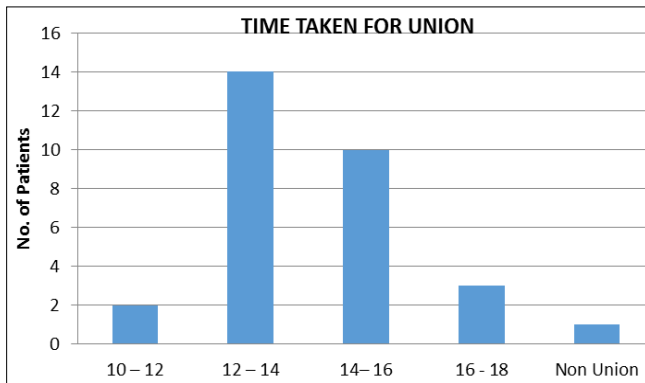
- Majority 21 (70%) patients had fractures in middle thirds of humerus.
- 7 (23.33%) patients had fractures in lower thirds of humerus.
- Upper third level of fracture comprises least no. of patients 2(6.66%).

Table 1: Classification of Fractures

Fracture Pattern		Patients	Percentage (%)
A. Simple fracture	A1-Simple spiral	8	26.66
	A2-Simple oblique($\geq 30^\circ$)	4	13.33
	A3-Simple transverse($< 30^\circ$)	12	40
B. Wedge fracture	B1-Spiral wedge	0	0
	B2-Bending wedge	4	13.33
	B3-Fragmented wedge	2	6.66
C. Complex fracture	C1-Complex spiral	0	0
	C2-complex segmental	0	0
	C3-complex irregular	0	0
Total		30	100

Table 2: Time Taken For Union

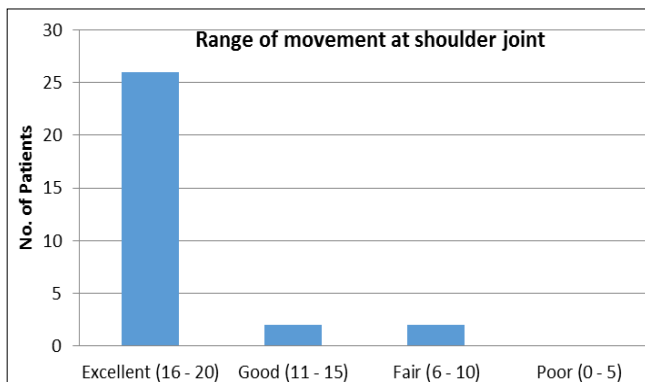
Duration (weeks)	Patients	Percentage (%)
10 – 12	2	6.66
12 – 14	14	46.66
14– 16	10	33.33
16 - 18	3	10
Non Union	1	3.33
Total	30	100



- 14 (46.66%) fracture united between 12-14 weeks.
- 10(33.33%)fracture united between 14-16 weeks
- Average time for unionis 13.5 weeks.
- 1 (3.33%) patients go to nonunion (Case no. 6).

Table 3: Range of movement at shoulder joint: (according to scoring for shoulder range of movement)

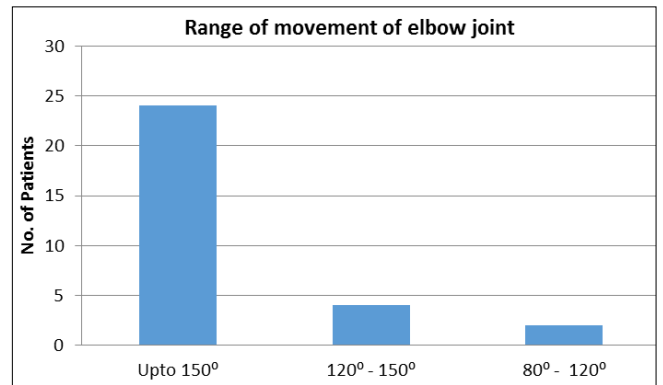
Range of Movement (Score)	Points	Patients	Percentage (%)
Excellent (16 - 20)	3	26	86.66
Good (11 - 15)	2	2	6.66
Fair (6 - 10)	1	2	6.66
Poor (0 - 5)	0	0	0
Total	6	30	100



- 28 (93.33%) of patients in our series had no problem in shoulder movement.
- 2 (6.66%) patients had fair shoulder range of movement. May be due to damage of deltoid insertion during surgery in anterolateral approach for U/ 3 shaft humerusfracture.

Table 4: Range of movement of elbow joint

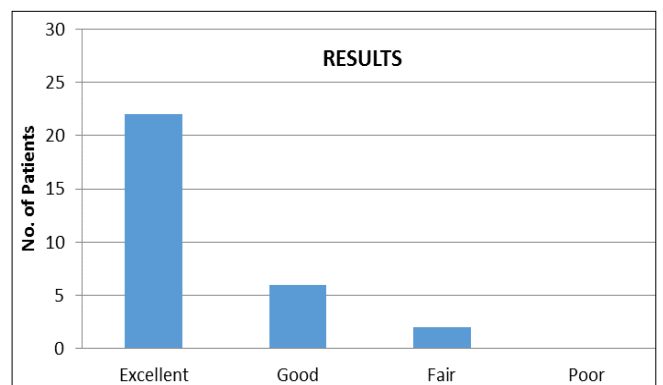
Range of Movement	Patients	Percentage (%)
Upto 150°	24	80
120° - 150°	4	13.33
80° - 120°	2	6.66
<80°	0	0



- Majority 28 (80%) of the patients had no problem in elbow movements.
- 2 (6.66) patients have decreased elbow range of movement dueto impingement of plate as the fracture is L/3 level (Case no. 3 &7).

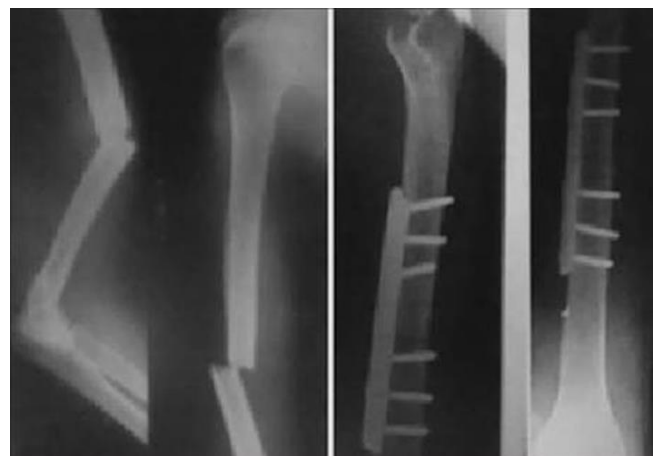Table 5: Result: dr. R.n. Deweshwar's score

Results	Patients	Percentage (%)
Excellent	22	73.33
Good	6	20
Fair	2	6.66
Poor	0	0
Total	30	100

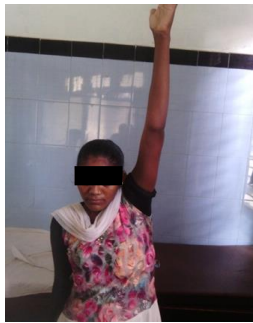

- Majority of patients are having excellent results 22 (73.33%).
- 6 patients had good result (20%).
- 2 patients (6.66%) had fair result.

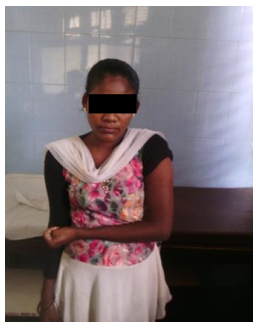Case Excellent Result



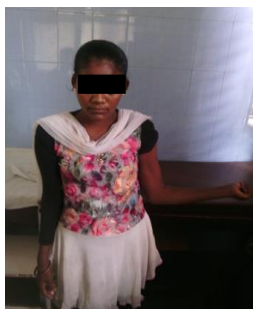- Pre op AP & lateral
- Post op AP & lateral
- Final follow up



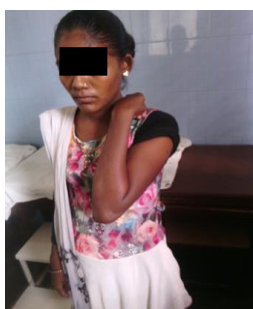Shoulder over head abduction



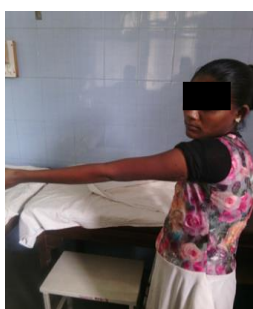Internal rotation



External rotation



Elbow flexion



Elbow extension

Discussion

The present study consisted of 30 patients fracture humerus treated with open reduction and humerus plating in the department of orthopedics, medical college and SSG Hospital, Vadodara. We have compared data and analysis and result in our study with well-known published studies, as of Sameer M. Haveri D. Maheshwarappa [30] which is done at Department of orthopedics, KLE University’s JN Medical college and Doctor Prabhakar Kaur Hospital and Medical research center Balgaum, Karnataka, India in between October 2005 and September 2007.

1) Age

Study	Average Age
Our study	39 yrs
Sameer M. Haveri	42.5 yrs

- We had patients of age ranging from 18-70 years.
- The majority of our patients were in young age group (60%).
- The average age in our study is 39 years.
- The average age in Sameer M. Haveri study is 42.5-years.(range 18-65 years)

2) Sex

Study	Male	Female
Our study	25	5
Sameer M. Haveri	31	4

- The male to female ratio in our study 5:1.
- Sameer M. Haveri study male female is 7.75:1.
- This dominance of male can be explained on the basis that in our society men are the bread earners and are hence more invoked in outdoor activities. So chances of their being involved in vehicular and occupational accidents are more.

3) Mode of injury

Study	Fall	RTA	Assault	Accident at work place
In our study	16 (53.33%)	12 (40%)	2 (6.66%)	0
Sameer M. Haveri	6 (17%)	26 (74%)	1 (3%)	2(6%)

- In our study fall from height and vehicular accident are main mode of injury 28 (99.33%)
- While in (Sameer M. Haveri study) vehicular accident was main cause of injury 26 (74%) which is due to high velocity trauma.
- The observation can be explained by the fact that high velocity vehicular accidents and polytrauma are more common in developing countries due to rising population and modernization.
- In our study 2 Patients fair results, whose mode of injuries was vehicular accident.

4) Side of injury

Study	Right	Left
Our study	20	10
Sameer M. Haveri	16	19

- In our study right side was more predominantly affected in 26 (66.66%) patients.
- In Sameer M. Haveri study left side was more affected in 16 patients & right side was affected in 19 patients.
- This finding had no significance on the final outcome of results in our study.

5) Occupation

In our study Laborers (manual & farm) sustained maximum injury. (Majority were farmer)

- In our study laborers were 80%.
- 2 fair results found in driver category probably due to head injury they remain in altered sensorium & not done physiotherapy properly and also having radial nerve palsy.

6) Level of fracture

Study	Upper third	Middle third	Lower third
Our study	2	21	7
Sameer M. Haveri	4	28	3

- In both series maximum no. of fractures are in middle third region.
- In our series fair result were found in 2 patients and both patients had M /3 level fracture.

7) Fracture configuration (according to classification)

Study	A	B	C
Our Series	24	6	0
Sameer M. Haveri	22	13	0

In Both series Type A fracture is in majority.

- In our study type A fracture found in 24 patients.
- Out 24 patients 22 patients had acceptable (excellent & good) results.
- 2 patients had fair results.(case no.6,28)
- 6 of our patient had 'B' type of fractures.
- Out 6 patients 4 had excellent results and 2 had good results.
- In our study type C fracture not found.
- In Sameer M. Haveri study 22 patients had A and 13 patients had B type of fractures.

8) Associated Injuries

Study	Associated injuries
Our Series	10
Sameer M. Haveri	11

- A total of 10 patients had polytrauma in our series.
- In our study 6 other patients with poly trauma gave excellent result.
- 11 patients had polytrauma in Sameer M. Haveri study.
- While satisfactory results found in all patient with polytrauma in Sameer M. Haveri series.
- In polytrauma patients fixation of the fracture shaft humerus gives advantages of early mobilization of limb and better nursing care.

9) Radial Nerve Palsy

Study	Radial Nerve palsy
Our Study	4
Sameer M. Haveri	1

- 4 patients had post traumatic radial nerve palsy in our series. In 2 patient s it recovers after exploration of radial nerve during surgery.
- In Sameer M. Haveri study post traumatic radial nerve palsy was found in patients out of which recovered after 3 months.
- Open Reduction and Plating gives chance to isolate and explore radial nerve and to look at its condition which helps in further management of nerve injury.
- In both series there is not a single case of post operative radial nerve palsy.

10) Infection

Study	Present	Absent
Our study	0	30
Sameer M. Haveri	1	34

- In our study there is no infection.
- There is no superficial, deep infection & no osteomyelitis in our study.
- In Sameer M. Haveri study 1 deep infection present, which goes to infected non union later.

11) Approach for surgery

In our study posterior approach was commonest 28 (93.33%). While in Sameer M. Haveri study anterolateral approach was commonest.

The patient in whom we operated by anterolateral approach showed restricted shoulder activity which may be due to damage of deltoid insertion from deltoid tuberosity.

12) Fracture Union

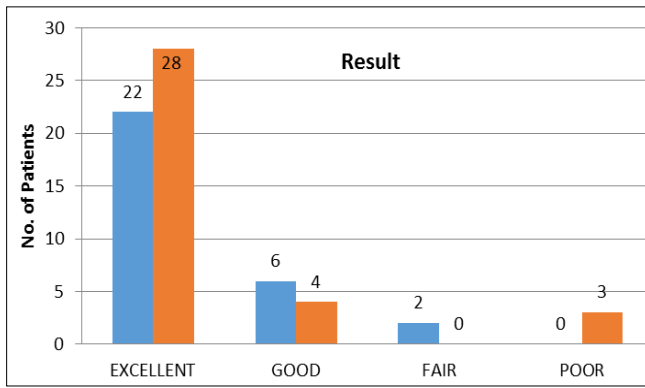
Study	Union Rate
Our series	96.66%
Sameer M.Haveri	94.28%

- From above table there is very high union rate found in patient treated with humerus plating which is comparable in both the studies.
- High union rate can be achieved due to:
 - 1 Anatomical reduction.
 - 2 Rigid fixation.
 - 3 Compression at fracture site.
 - 4 Minimal periosteal stripping.
- These results again emphasize the importance of correct surgical technique and leaving no distraction at fracture site as the factors responsible for such a high union rate.
- According to literature in both varieties of nonunion open reduction and compression plating gives good results. So Humerus plating not only prevents nonunion but is also the treatment of choice of non union.

13) Result: Using criteria devised by Dr. (Prof) R.N. Daveshwar we had studied results of open reduction and internal fixation & humerus plating.

- We had 73.33% excellent results, 6% good results and 2% fair results.

Result	Our Study (30) (DR. R. N. Daveshwar Criteria)	Sameer M. Haveri (35) (Romen <i>Et Al</i> scoring)
Excellent	22 (73.33%)	28 (93.33%)
Good	6 (20%)	4 (13.33%)
Fair	2 (6.66%)	0
Poor	0	3(10%)



- In Sameer M. Haveri study, there were 28(93.33%) excellent results, 4 (13.3%) good results, 3(10%) poor results.
- In our study 22 (73.33%) excellent, 6 (20%) good and 2(6.66%) fair results.
- There were no case with poor results in our study.
- There is no case with fair results in Sameer M.Haveri study.

Thus, analysis of the results of this study shows factors affecting results are

Rigid internal fixation/early Mobilization: Good surgical technique, accurate anatomical reduction, rigid internal fixation and early mobilization had given good results.

Line of management: With better fixation devices, improved operative techniques and antibiotics, we obtained acceptable results.

Anatomical reduction, Rigid fixation and early mobilization had given good results in this study.

Type of trauma/fracture: Soft tissue damage and associated bone necrosis increased time for healing. Associated injury to vital structures had caused delay in fixation and finally poor results.

- Thus, taking these results into consideration open reduction and internal fixation with AO Plating technique remains the best treatment for fractures of shaft of the humerus.

Conclusions

Open reduction and plating gives anatomical reduction and rigid fixation at fracture site hence leading to early mobilization of patient post operatively.

It gives excellent shoulder and elbow range of movement postoperatively and it gives advantage to explore radial nerve while doing fixation so that post traumatic radial nerve palsy can be recovered. We found it technically easy surgery it is a financially cheap surgery which requires minimum inventory and it does not require help of Image intensifier Television. Thus, it is concluded from the study that open reduction and plating is an excellent mode of treatment for closed fracture of shaft of humerus which consistently.

Thus, it is concluded from the study that open reduction and plating is an excellent mode of treatment for closed fracture of shaft of humerus which consistently gives long term good results.

References

1. McKee MD. Fractures of The Shaft of The Humerus Rockwood & Green's Fractures in Adults, 6th Edition, Bucholz, Robert W.; Heckman, James D.; Court-Brown,

Charles M. Lippincott. 2006, 1118-1159.

2. Lin J, Shen PW, Hou SM. Complications of locked nailing in humeral shaft fractures. J Trauma. 2003; 54:94309.
3. McCormack RG, Brien D, Buckley RE, McKee MD, Powell J, Schemitsch EH. Fixation of fractures of the shaft of the humerus by dynamic compression plate or intramedullary nail. A prospective, randomised trial. J Bone Joint Surg Br. 2000; 82:336E]9.
4. Riemer BL, Foglesong ME, Burke CJ 3rd, Butterfield SL. Complications of seidel intramedullary nailing of narrow diameter humeral diaphyseal fractures. Orthopaedics. 1994; 17:19029.
5. Heim D, Herkert F, Hess P, Regazzoni P. Surgical treatment of humeral shaft fractures-the basel experience. J Trauma. 1993; 35:226I?I32.
6. An Z, He X, Zeng B. A comparative study on open reduction and plating osteosynthesis and minimal invasive plating osteosynthesis in treating midEIdistal humeral shaft fractures. Zhongguo Xiu Fu Chong Jian Wai Ke Za Zhi. 2009; 23:41S4.
7. Anderson Lewis. Compression Plate fixation and effects of different types of fixation on fracture healing. JBJS 47 A, 1965.
8. Balfour G V. Vert Mooney, Ashby, ME (19S2) Diaphyseal fractures of the humerus treated by readymade fracture brace (JBJS 64A).
9. Bony L. Bucholz - Management of fractures in patient with polytrautna. JBJS 63, 1986.
10. Campbell's operative orthopaedics Ed. X. 1794; 3:136
11. Esterhal J, Brighton C. Nonunion of humerus.- Response-characteristic to treatment with constant direct stimulation of osteogenesis Clin, Ortho, 1986.
12. Evans DK. Intramedullary Nailing of humerus by / proximal insertion of nail JBJS 5 IB. 1969, 184.
13. Floyd Jergesen. Metallic Surgical implants JBJS 46. 431.
14. Flenry's Extensile exposures.
15. Holstein A, Lewis SB. Fractures of the humerus with radial nerve palsy JBJS 45 A: 13B2.
16. McGurty Bell. Results of plating humeral shaft fractures in patients with multiple injuries - the Sunnybrook experience (JBJS 67 B 19S5).
17. Rockwood C, Green D. fractures in Adults. 1963, 1:653,
18. Robert Griend, John Tomesin. Results of open- reduction and dynamic compression plating a study of 36 patients by. JBJS. 1986; 68(A):430433.
19. Jiang R, Luo CF, Zeng BF, Mei GH. Minimally invasive plating for complex numeral shaft fractures. Arch Orthop Trauma Surg. 2007; 127:531I?15.
20. Ekholm R, Adami J, *et al.* Fractures of the shaft of the Humerus-An Epidemiology of 401 fractures J Bone Joint Surg (Br) 2006;88- B:1469-73.
21. Wilson JN. Watson-Jones. Fractures and Joint Injuries, 6th ed. B.I. Churchill Livingstone PVT Ltd. New Delhi, 2002.
22. Ghromley RK, Mroz RJ. Fractures of humerus, End results after |treatment. Surg. Gynaecol & Obst. 1933; 60: 730.
23. Strohm PC, Reising K, *et al.* Humerus shaft fractures - where are we | today? Actachirurgiaeorthopaedicae. 2011; 78:185-189.
24. Langenberg R. Sarmiento fuctional treatment of Humeral shaft |fractures. Results and Experiences.Zentralblatt fur chirurgie. 1987; 112(20):1271-7.
25. Rutgers M, Ring D, Treatment of diaphyseal fractures of

- the Humerus using a functional brace. *J Orthop Trauma.* 2006; 20:597-601.
26. Seddon H. Surgical disorders of the peripheral nerves *CR.* 1972; 13:229.
 27. Pollock J. Treatment of radial nerve palsy associated with fracture shaft humerus, *JBJS* 63B 1931.
 28. McGurty Bell. Results of plating humeral shaft fractures in patients with multiple injuries - the Sunnybrook experience. *JBJS* 67 B, 1985.
 29. Caldwell JA. Treatment of fractures on the shaft of humerus by hanging casts. *Surg. Gynaec and Obst.* 1940; 70:421-425.
 30. Griend RV, Tomsin J. Open reduction and internal fixation of Humerai shaft fractures - Results using AO plating techniques (*JBJS*).