

ISSN: 2395-1958
IJOS 2018; 4(1): 544-547

www.orthopaper.com
Received: 16-11-2017
Accepted: 18-12-2017

Dr. Shah Waliullah
Asst Professor, Dept. of Orthopaedic Surgery, King George Medical University, Lucknow, Uttar Pradesh, India

Dr. Vineet Kumar
Asst Professor, Dept. of Orthopaedic Surgery, King George Medical University, Lucknow, Uttar Pradesh, India

Dr. Dharmendra
Asst Professor, Dept. of Orthopaedic Surgery, King George Medical University, Lucknow, Uttar Pradesh, India

Dr. Deepak
Asst Professor, Dept. of Orthopaedic Surgery, King George Medical University, Lucknow, Uttar Pradesh, India

Dr. Devarshi Rastogi
Asst Professor, Dept. of Orthopaedic Surgery, King George Medical University, Lucknow, Uttar Pradesh, India

Dr. RN Srivastava
Professor, Dept. of Orthopaedic Surgery, King George Medical University, Lucknow, Uttar Pradesh, India

Correspondence
Dr. Shah Waliullah
Asst Professor, Dept. of Orthopaedic Surgery, King George Medical University, Lucknow, Uttar Pradesh, India

Reverse distal femoral locking plate for the management of unstable peritrochanteric femoral fracture

Dr. Shah Waliullah, Dr. Vineet Kumar, Dr. Dharmendra, Dr. Deepak, Dr. Devarshi Rastogi and Dr. RN Srivastava

DOI: https://doi.org/10.22271/ortho.2018.v4.i1h.80

Abstract
Background: Dynamic Hip screw(DHS) is gold standard for fixation of stable intertrochanteric fractures and for unstable fractures proximal femoral nail (PFN) is preferred implant however PFN is technically demanding and has frequent complications. We have evaluated the efficacy of reverse supracondylar locking plate for the management of unstable peritrochanteric fractures.
Methods and material: 23 patients with unstable peritrochanteric fracture were recruited in our study as per AO classification. All the patients, after getting informed consent, were treated surgically by reverse supracondylar locking plate. Functional outcome was evaluated in terms of Harris Hip Score.
Results: After a minimum follow-up of 29 months, all patients have shown fracture healing and union at mean of 12.4 weeks. The Harris Hip score at most recent follow up was 84.1. Outcomes were excellent in 14.2%, good in 61.9%, fair in 9.5%while poor in 14.2%.
Conclusion: By virtue of our results we can recommend that reverse supracondylar locking plate can be used as an alternative, viable and easily available implant that can be used effectively for unstable peritrochanteric fractures.

Keywords: Reverse distal femoral locking plate, unstable peritrochanteric femoral fracture

Introduction
Trochanteric fracture is a major cause of morbidity and mortality in elderly patients. To avoid this morbidity and mortality, these fractures should be treated at earliest; optimum treatment requires adequate reduction, stable internal fixation and early mobilization. Stable internal fixation can be achieved with either intramedullary or extramedullary implants, however there is lack of consensus regarding fixation of unstable peritrochanteric fractures, whether they do better with intramedullary or extramedullary implants [1, 2, 3].
Proximal femoral nail, by virtue of its biomechanical properties, provides rotational stability to proximal fragment, however PFN is technically demanding and frequently associated with implant failure and failed osteosynthesis [4, 5, 6].
Distal femoral locking plate anatomy matches with opposite proximal femur [7, 8] and so it can be used as an alternative extramedullary implant. We have evaluated the efficacy of reverse supracondylar locking plate for the management of unstable peritrochanteric fractures.

Methods and material
23 patients with unstable peritrochanteric fracture, admitted in our department from March 2010 to July 2012, were recruited in our study. Patients were classified as per AO Classification [9], 13 patients belong to 31 A3 type while rest 10 patients were having 32 C3.1 type fracture. There were 15 males and 8 female patients with mean age 71.9years (range from 46years-94years). All of the patients, after getting informed consent, were treated surgically either by direct or indirect reduction and internal fixation by reverse supracondylar locking plate.
All patients were operated under regional or general anaesthesia, in supine position on fracture table under image intensifier control.

On applying traction, reduction of fracture was observed in fluoroscopy, steinmenn pin was used as joystick to control reduction of proximal fragment, after getting adequate reduction the fracture was hold temporarily with Kirschner wires. If reduction was unsatisfactory, then fracture was opened up through lateral approach and direct reduction was achieved. Reduction was checked in both AP and lateral view fluoroscopically. Supracondylar plate of opposite side was taken that matches the contour of proximal femur of operating side. If reduction was achieved indirectly than plate was slided distally by making 3 centimetre incision over flare of greater trochanter. In cases of open reduction plate was applied directly over the lateral surface of femur and held with K wires distally and proximally. After checking the length and position of plate fluoroscopically, proximal fixation was done initially by passing guide-wires followed by drilling and screw insertion under C-arm control. After locking first proximal screw, distal most screw is locked by making incision over distal end of plate under C arm control. At least three to four proximal screws were locked followed by distal screws over shaft. Closure was done in layers. Post-operatively range of movement exercises were started as patients started tolerating pain. Weight bearing was delayed for six weeks, thereafter partial weight bearing with toe touching allowed for further six weeks. Full weight bearing started after 3 months. All patients were followed clinico-radiologically at 6 weekly intervals initially for three months then at 3 monthly intervals. Functional outcome was assessed in terms of Harris Hip Score.

Results

All patients were followed for a minimum of 29 months. At final follow up all except three patients showed union at mean of 12.4 weeks. Two patients died irrespective of treatment because of additional comorbidities. Two patients developed superficial infection responded well to oral antibiotics get healed without any sequalae. The mean Harris Hip score at last follow up was 84.1. Outcomes were excellent in 14.2%, good in 61.9%, fair in 9.5% while poor in 14.2%.

Results	No. of Patients		
	31A3 n=11	32C3.1 n=10	Total n=21
Mean Harris hip Score			
Excellent	2(18.1%)	1 (10%)	14.2%
Good	6(54.5%)	7(70%)	61.9%
Fair	2 (18.1%)		9.5%
Poor	1(9%)	2 (20%)	14.2%

Functional Outcome at Final Follow-up

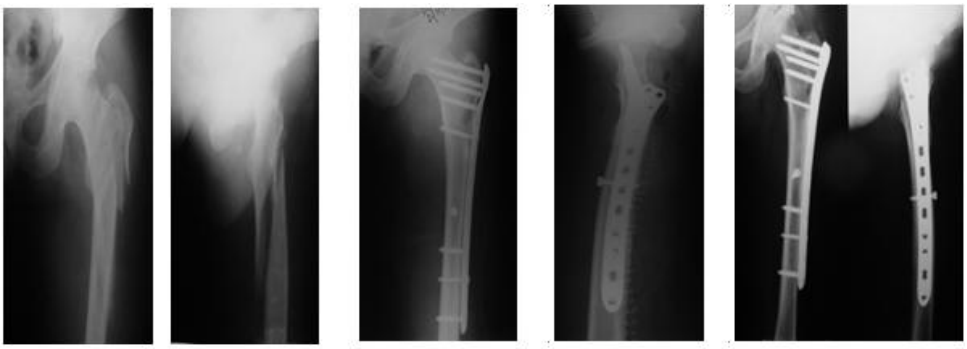

Pre-Op Post-Op Follow-up

Discussion

Trochanteric fracture is a common fracture in elderly population associated with osteoporosis, leading poor quality of bone, results into implant loosening and implants failure. Early treatment and rehabilitation improves outcome and quality of life. Trochanteric fractures can be treated by either extramedullary or intramedullary implants.

For stable trochanteric fractures Dynamic hip screw (DHS) is considered as gold standard [10] as it provides stable fixation and secondary compression at fracture site, however they are frequently associated with loss of fixation and failure in unstable fractures. Other problems associated with dynamic hip screw are screw cut out and medialization of shaft resulting in failure of fixation [11, 12, 13]. To prevent medialization of shaft trochanteric stabilization plate [14, 15] was introduced for the treatment of unstable intertrochanteric fractures. Unstable trochanteric fractures include fractures with broken greater trochanter, breached lateral cortex, lesser trochanter fracture and medial communition [16]. Treatment of these unstable fracture due to mechanical complication range from 0% to 20% [16].

Intramedullary rods with sliding screw in femoral neck-head segment were used to overcome complication associated with DHS. Gamma nail was introduced [17, 18, 19] for management of unstable trochanteric fractures, allowed close reduction, decreased intra-operative blood loss, decrease infection rate, earlier rehabilitation and shortened hospital stay but associated with more intra-operative femoral shaft fracture and distal screw locking. However, the long term functional results are similar to Dynamic hip screw fixation [20].

PFN [21, 22] offers higher rotational stability to proximal femoral segment and has better nail curve to decrease intra-operative femoral shaft fractures however it is technically demanding and associated with implant failure, screw cut-out and non-union.

Trochanteric fixation nail [23] with helical blade allows better purchase in the femoral head and associated with decrease cut out rate and recommended for fixation in osteoporotic elderly patients.

Apart from DHS, Proximal femoral locking plates have been used in these unstable fractures for osteosynthesis as Locking plate [24, 25] provide angle fixed stable implant, better screw purchase and high pull out strength in osteoporotic bones. Zha *et al*. [25] showed good results with proximal femoral locking plate and recommended as a feasible alternative for unstable intertrochanteric fractures. Glassner *et al*. [26] reported failure of proximal femoral plate in management of trochanteric fracture because of varus collapse and implant loosening.

In AO type 31 A3 and 32 C3.1 fractures, where there is fracture of the lateral trochanteric wall or where there is complicated sub-trochanteric fracture with intertrochanteric extension, the basic principle of DHS does not hold. As sub-

trochanteric area is an area with greatest muscular pull on the fractured fragments, so it needs different consideration. Choices available are intramedullary and extra-medullary implants. In extra medullary implants we have DHS and PCCP and in intramedullary implants we have cephalo-medullary implants. Each implant mentioned has their own sets of pros and cons. Their use in fractures has to be individualised based on the fracture configuration and the mechanics particular to that area. In trochanteric fractures as said, that the gold standard is SHS, but it is ideal when there is an intact lateral trochanteric wall, else there is always a good probability that the collapse which is permitted by SHS lateralises the proximal fragment i.e., excessive collapse and varus mal-positioning. To address this flaw was introduced Per Cutaneous Compression Plate [27] and Trochanteric Stabilisation Plate [14, 15], but long term results with large sample size are still not available for these implants and also for fractures with large sub-trochanteric fragments, longer plates are needed which lack in their contour to match anterolateral bowing of femur. Intramedullary implants can very well be used for these fractures, but again it lacks a lateral buttressing property. We, in these specific fracture patterns have used anatomic distal femoral locked plates of opposite limb and is used by reversing it. This placement matches the normal anterolateral bow of femur with the advantage of using inter-fragmentary screws for addressing the large comminuted bony fragment and providing adequate lateral buttress in the trochanteric region. We observed good to excellent outcome in about 75% of our cases and poor outcome in about 14% cases. Poor outcome is mainly due to varus collapse, resulting into implant failure and required re-operation. Certainly, it has the disadvantage of not providing compression and controlled collapse in case of trochanteric fracture if any and applying it needs an anatomical reduction of the trochanteric area to get maximum number of screws in the head and neck of femur for maximal stability. Thus we conclude that the use of distal femur locking plate is a viable option in selected fractures of proximal femur with proper indications. This implant can definitely be an addition in our armamentarium when addressing such a fracture.

Conclusion

By virtue of our results we can recommend that Reverse supracondylar locking plate can be used as an alternative, viable and easily available implant that can be used effectively for unstable trochanteric fractures.

References

1. Parker MJ, Handoll HH. Gamma and other cephalocondylic intramedullary nails versus extramedullary implants for extracapsular hip fractures in adults. Cochrane Database Syst Rev. 2010; 8;(9):CD000093.
2. Audigé L, Hanson B, Swiontkowski MF. Implant-related complications in the treatment of unstable intertrochanteric fractures: meta-analysis of dynamic screw-plate versus dynamic screw-intramedullary nail devices. Int Orthop. 2003; 27:197-203.
3. Jones HW, Johnston P, Parker M. Are short femoral nails superior to the sliding hip screw? A meta-analysis of 24 studies involving 3279 fractures. Int Orthop. 2006; 30:69-78.
4. Simmermacher RK, Bosch AM, Van der Werken C. The AO/ASIF-PFN (PFN): a new device for the treatment of unstable proximal femoral fractures. Injury. 1999; 30: 327-32
5. Curtis MJ, Jinnah RH, Wilson V, Cunningham BW. Proximal femoral fractures: a biomechanical study to compare intramedullary and extramedullary fixation. Injury. 1994; 25(2):99-104.
6. Ongkiehong BF, Leemans R. PFN failure in a subtrochanteric fracture: The importance of fracture to distal locking screw distance. Injury Extra. 2007; 38:445-50.
7. Haq RU, Manhas V, Pankaj A *et al*. Proximal femoral nails compared with reverse distal femoral locking plates in intertrochanteric fractures with a compromised lateral wall; a randomized controlled trial. Int Orthop. 2014; 38(7):1443-1449.
8. Vaishya R, Agarwal AK, Gupta N, Vijay V. Reversed distal femoral locking plate for failed proximal femoral nail with non-union of proximal femoral fractures International Orthopaedics (SICOT). 2016; 40:1709-1715.
9. Muller ME, Allgower M, Schneider R, Willenegar H. Manual of internal fixation Techniques, Recommended by AO-ASIF group. Third Ed. Berlin Heidelberg New York London, Paris, Tokyo Hong Kong Barcelona: Springer-Verlag, 1990.
10. Kulkarni GS, Limaye R, Kulkarni M, Kulkarni S. Current Concept Review Intertrochanteric fracture. Indian journal of Orthopaedics. 2006; 40:16-23.
11. Bridle SH, Patel AD, Bircher M, Calvert PT. Fixation of intertrochanteric fractures of the femur: a randomised prospective comparison of the gamma nail and the dynamic hip screw. J Bone Joint Surg [Br]. 1991; 73-B:330-4.
12. Davis TR, Sher JL, Horsman A *et al*. Intertrochanteric femoral fractures: mechanical failure after internal fixation. J Bone Joint Surg [Br]. 1990; 72-B:26-31.
13. Simpson AH, Varty K, Dodd CA. Sliding hip screws: modes of failure. Injury. 1989; 20:227-31.
14. Cho SH, Lee SH, Cho HL, Ku JH, Choi JH, Lee AJ. Additional Fixations for Sliding Hip Screws in Treating Unstable Pertrochanteric Femoral Fractures (AO Type 31-A2): Short-Term Clinical Results Clin Orthop Surg. 2011; 3(2):107-113.
15. Babst R, Renner N, Biedermann M, Rosso R, Heberer M, Harder F, Regazzoni P. Clinical results using the trochanter stabilizing plate (TSP): the modular extension of the dynamic hip screw (DHS) for internal fixation of selected unstable intertrochanteric fractures. J Orthop Trauma. 1998; 12(6):392-9.
16. Knobe M, Gradl G, Ladenburger A, Tarkin IS, Pape H-C. Unstable Intertrochanteric Femur Fractures: Is There a Consensus on Definition and Treatment in Germany? Clinical Orthopaedics and Related Research. 2013; 471(9):2831-2840. Doi: 10.1007/s11999-013-2834-9.
17. Halder SC. The Gamma nail for peritrochanteric fractures. J Bone Joint Surg [Br]. 1992; 74-B:340-4.
18. Hesse B, Gachter A. Complications following the treatment of trochanteric fractures with the gamma nail. Arch Orthop Trauma Surg, 2004; 124:692-698.
19. Kempf I, Grosse A, Taglang G, Favreul E. Gamma nail in the treatment of closed trochanteric fractures: results and indications apropos of 121 cases. Rev Chir Orthop Reparatrice Appar Mot. 1993; 79:29-40.
20. Leung KS *et al*. Gamma nails and dynamic hip screws for peritrochanteric fractures. A randomised prospective study in elderly patients. J Bone Joint Surg Br. 1992, 74:345-351.

21. Boldin C, Seibert FJ, Fankhauser F, Peicha G, Grechenig W, Szyszkowitz R. The proximal femoral nail (PFN)--a minimal invasive treatment of unstable proximal femoral fractures: a prospective study of 55 patients with a follow-up of 15 months. Acta Orthop Scand. 2003; 74(1):53-8.
22. Werner-Tutschku W, Lajtai G, Schmiedhuber G, Lang T, Pirkl C, Orthner E. Intra- and perioperative complications in the stabilization of per- and subtrochanteric femoral fractures by means of PFN. Unfallchirurg. 2002; 105:881-885.
23. Gardner MJ, Bhandari M, Lawrence BD, Helfet DL, Lorich DG. Treatment of Intertrochanteric Hip Fractures with the AO Trochanteric Fixation Nail Orthopedics. 2005; 28(2):117.
24. Hasenboehler EA, Agudelo JF, Morgan SJ *et al*. Treatment of complex proximal femoral fractures with the proximal femur locking compression plate. Orthopedics. 2007; 30:618-623.
25. Zha GC, Chen ZL, Qi XB, Sun JY. Treatment of pertrochanteric fractures with a proximal femur locking compression plate. Injury. 2011, 26.
26. Glassner PJ, Tejwani NC. Failure of Proximal Femoral Locking Compression Plate. J Orthop Trauma. 2011; 25:76-83.
27. Peyser A, Weil YA, Brocke *et al*. A prospective, randomised study comparing the percutaneous compression plate and the compression hip screw for the treatment of intertrochanteric fractures of the hip. Journal of Bone and Joint Surgery B. 2007; 89(9):1210-1217.