



ISSN: 2395-1958  
IJOS 2018; 4(1): 388-391  
© 2018 IJOS  
www.orthopaper.com  
Received: 06-11-2017  
Accepted: 07-12-2017

**Dr. KV Dhanwantary Naidu**  
Associate Professor, Department  
of Orthopaedic Surgery,  
Konaseema Institute of Medical  
Sciences and Research  
Foundation, Amalapuram,  
Andhra Pradesh, India

## A surgical management of pertrochanteric fractures of femur by dynamic hip screw and proximal femoral nail

**Dr. KV Dhanwantary Naidu**

**DOI:** <https://doi.org/10.22271/ortho.2018.v4.i1f.56>

### Abstract

The incidence of femoral fractures at hip region is increasing with advancement of age in population, globally. Surgical treatment with stable fixation reduces fracture associated complications and helps in regaining of mobility. Dynamic hip screw (DHS) and proximal femoral nail (PFN) are main types of fixations for trochanteric fractures. This study was designed to assess the efficacy of DHS and PFN in trochanteric fractures of femur. A total 50 patients with type I, II, III intertrochanteric and subtrochanteric fractures of femur as per Boyd and Griffin's classification, Seinsheimer's classification and Evans classification were included and were managed operatively by internal fixation with dynamic hip screw (DHS) and proximal femoral nail (PFN). 48% cases in DHS and 44% cases in PFN undergone with surgery within 5 days after injury. In PFN, the range of lag screw length was between 70mm to 95mm whereas in DHS, range was in between 65mm to 100mm. In intra operative complications of this study, there was ill fitting jig in 24% cases of PFN and in DHS method includes shattering of lateral cortex (8%) and difficulty in reduction (8%). Average time for fracture union in this study was between 14-17 weeks. In 12% cases varus deformity was observed in both groups and on an average 82% cases had good range of movement at hip joint in PFN and DHS groups. It was concluded that proximal femoral nail and dynamic hip screw were ideal treatment modalities to treat inter trochanteric and sub trochanteric fractures of the femur.

**Keywords:** Dynamic hip screw (DHS), proximal femoral nail (PFN), Trochanteric fractures of femur

### Introduction

Pertrochanteric and subtrochanteric fractures of femur has significant structural, clinical, anatomical and biochemical characteristics that distinguish them from intracapsular fractures. In past few decades, the treatment for intertrochanteric fractures has gained tremendous changes. The dynamic hip screw (DHS) or sliding hip screw (SHS) development created a revolution in the management of unstable fractures of femur. In the early 90s intramedullary devices were developed for Intertrochanteric fractures fixation. These devices had numerous biomechanical and biological advantages over the conventional dynamic hip screw [1-3].

Proximal femoral nail (PFN) was introduced in 1997, which was designed to overcome implant related complications and facilitate the surgical treatment of unstable intertrochanteric fractures [4]. Postoperative rehabilitation study by Pajarinen *et al.*, suggested that the use of PFN may allow faster post-operative restoration of walking ability when compared to DHS [5]. Study by Cyril Jonnes MS *et al.*, stated that patients underwent PFN returned to pre-injury walking status earlier than patients who underwent DHS [6].

DHS is a standard technique to treat trochanteric fractures which has biomechanical disadvantage because of wider distance between the weight bearing axis and the implants [7-11]. Proximal femoral nail has become most prevalent method to treat trochanteric fractures which associated with few technical errors and expensive [12-16]. With the above literature support the present study was designed to assess the management of intertrochanteric and subtrochanteric fracture of femur by internal fixation method.

### Materials and methods

The present Comparative study was conducted in Department of Orthopaedics, Konaseema institute of Medical Sciences and Research Foundation, Amalapuram during January 2016 to June 2017. A total 50 cases with intertrochanteric and subtrochanteric fractures of femur were recruited.

### Correspondence

**Dr. KV Dhanwantary Naidu**  
Associate Professor, Department  
of Orthopaedic Surgery,  
Konaseema Institute of Medical  
Sciences and Research  
Foundation, Amalapuram,  
Andhra Pradesh, India

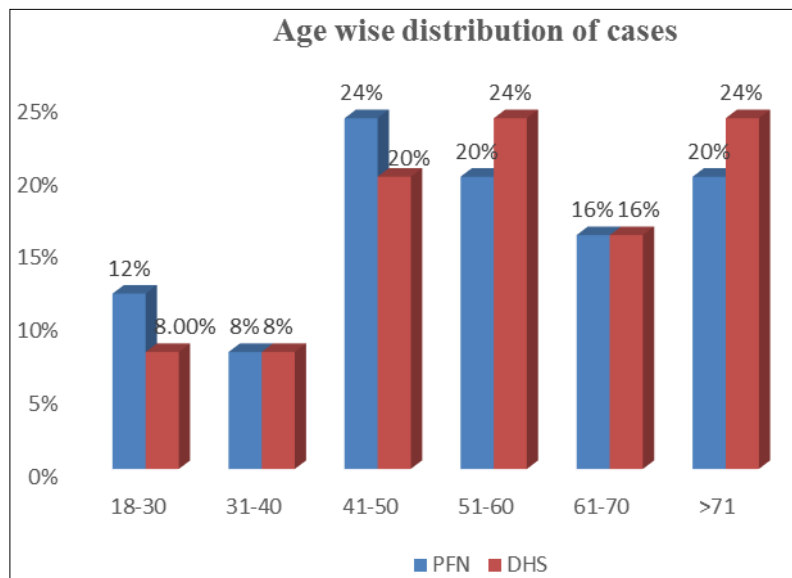
Patients with type I, II, III fractures of femur as per Boyd and Griffin’s classification, Seinsheimer’s classification and Evans classification, cases from age group 18 years and above, cases agreed for 6 months follow up were included and cases with type IV, V fracture and medically not fit for surgery were excluded from the study.

All the patients were subjected to necessary clinical and radiological assessment before and after surgical procedure along with subsequent follow up at outpatient level at regular interval. Before surgical process, neck shaft angle of femur by goniometer, nail diameter of femur at the level of isthmus was measured radiologically. Fifty patients of intertrochanteric and subtrochanteric fractures of femur were managed

operatively by internal fixation with dynamic hip screw (DHS) and proximal femoral nail (PFN).

**Results**

A total fifty patients with subtrochanteric and intertrochanteric fractures of femur were recruited to assess the comparison between PFN and DHS in femoral fractures management. Among fifty cases 52% were males and 48% were females. 72% of patients undergone with PFN technique, had trauma by falling injuries followed by road accidents (24%). In DHS technique, 70% cases had trauma by falling injuries and 24% by rad accidents.



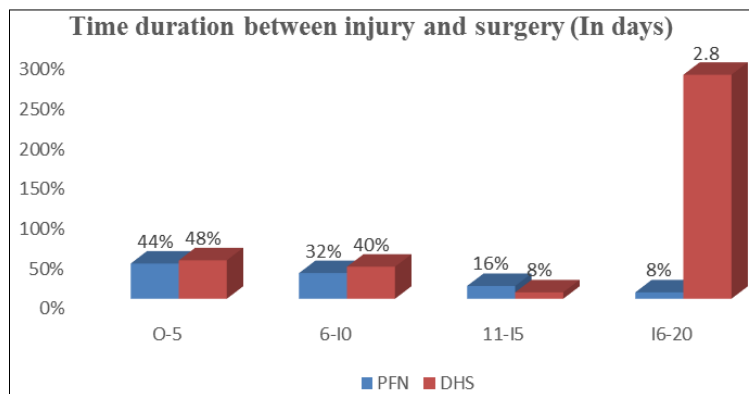
**Fig 1:** Age wise distribution of cases

**Table 1:** According to type of fracture.

| Type of fracture   | PFN    |            | DHS    |            |
|--------------------|--------|------------|--------|------------|
|                    | Number | Percentage | Number | Percentage |
| Inter trochanteric | 18     | 72%        | 19     | 76%        |
| Sub trochanteric   | 7      | 28%        | 6      | 24%        |

Among total cases treated with PFN, 10 cases and 8 cases had inter trochanteric fractures, 4 cases and 3 cases had subtrochanteric fractures on right and left sides respectively. In DHS, 10 cases and 9 cases had inter trochanteric fractures,

3 cases and 3 cases had subtrochanteric fractures on right and left sides respectively. 54% fractures were stable and 46% fracture were unstable in PFN. In DHS, 67% fractures were stable and 33% were unstable.



**Fig 2:** Time duration for surgery

Maximum cases undergone to surgery within 5 days after injury in DHS (48%) and PFN (44%) methods (Figure 2). Open reduction was observed in 32% cases and 24% cases in PFN and DHS respectively. Closed reduction was observed in

68% and 76% cases in PFN and DHS respectively. Head injuries, chest injuries and fracture to forearm bones were observed in few cases.

**Table 2:** length and percentage of ante rotation screw and lag screw in PFN and DHS.

| Length of screw (In mm) | PFN  |                                    | DHS                                |
|-------------------------|--|------------------------------------|------------------------------------|
|                         | Percentage of cases with ante rotation screw | Percentage of cases with lag screw | Percentage of cases with lag screw |
| 65 mm                   | 16%  | -                                  | 12%                                |
| 70 mm                   | 12%  | 4%                                 | 12%                                |
| 75 mm                   | 40%  | 16%                                | 16%                                |
| 80 mm                   | 24%  | 12%                                | 32%                                |
| 85 mm                   | 8%   | 48%                                | 12%                                |
| 90 mm                   | -  | 12%                                | 8%                                 |
| 95 mm                   | -  | 8%                                 | 4%                                 |
| 100 mm                  | -  | -                                  | 4%                                 |

In both methods, infections related to wounds, urinary system and chest region were commonly associated and no complications related cardio vascular, respiratory was found.

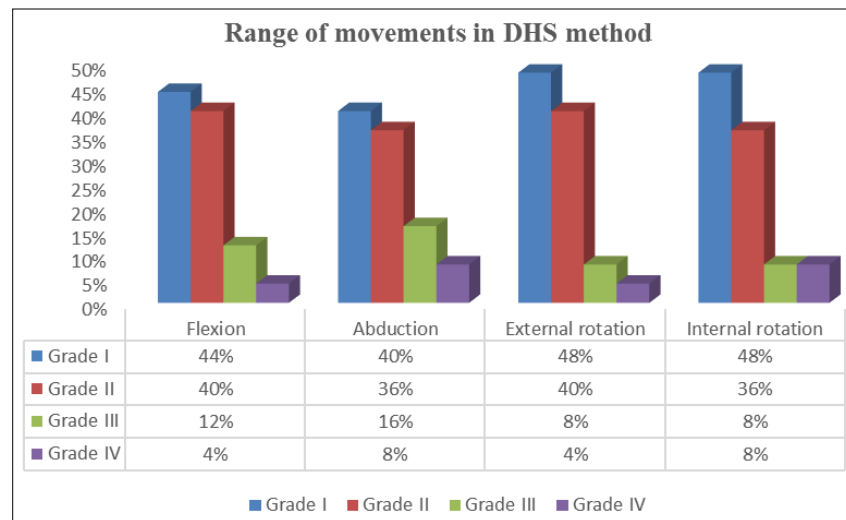
**Table 3:** Alignment difficulties in rotation.

| Type of rotation  | PFN (Percentage) | DHS (Percentage) |
|-------------------|------------------|------------------|
| Varus of hip      | 12%              | 12%              |
| Valgus of hip     | 0                | 0                |
| Internal rotation | 4%               | 0                |
| External rotation | 8%               | 4%               |
| Shortening        | 8%               | 16%              |

Intra operative complications in PFN method includes difficult in jig fitting in 24% cases and in DHS method includes shattering of lateral cortex (8%) and difficulty in reduction (8%). No associated fractures related to trochanters and breakages related to nails, plates, screws were found. Post-operative assessment by radiological method found reverse Z effect in 16% cases, bolt breakage in 4% cases and nail breakage in 12% cases of PFN method and excessive lag screw back out was seen in 12% cases of DHS method.

**Table 4:** Range of Hip movements in PFN method measured by Harris hip score method.

| Range of Motion   | Proximal femoral Nail |     |          |     |           |     |          |    |
|-------------------|-----------------------|-----|----------|-----|-----------|-----|----------|----|
|                   | Grade I               |     | Grade II |     | Grade III |     | Grade IV |    |
|                   | N                     | %   | N        | %   | N         | %   | N        | %  |
| Flexion           | 10                    | 40% | 9        | 36% | 4         | 16% | 2        | 8% |
| Abduction         | 8                     | 32% | 12       | 48% | 3         | 12% | 2        | 8% |
| External rotation | 10                    | 40% | 11       | 44% | 3         | 12% | 1        | 4% |
| Internal rotation | 12                    | 48% | 9        | 36% | 3         | 12% | 1        | 4% |



**Fig 3:** Range of Hip movements in DHS method measured by Harris hip score method.

**Discussion**

Intertrochanteric fractures are more prevalent in elderly people and always associated with osteoporosis, its related fractures. Internal fixation has become the best choice of treatment for trochanteric fractures because it permits early rehabilitation and quick functional recovery. This study designed to assess the efficacy of PFN and DHS in the management of femoral trochanteric fractures. In this study, among fifty cases 52% were males and 48% were females. Majority cases were in between 41-50 years and 51-60 years in both the methods. Study by Daniel F.A *et al.*, and Gallagher *et al.*, stated that fractures were more common in

between age group 50-80 years (17, 18). Among 72% cases undergone with PFN had injuries by falling, whereas in DHS it was 70%.

Maximum number of cases undergone to surgery within 5 days after injury in DHS (48%) and PFN (44%) methods. In this study, 25mm length of PFN nail was used commonly and average diameter of proximal femoral nail was in between 8mm to 14mm. In PFN, the range of lag screw length was between 70mm to 95mm. 85mm lag screw was used in 48% of cases in PFN. In PFN, anti-rotation screw was used in a range between 65mm to 85mm. 75mm anti rotation screw was used in 40% of cases in PFN. Whereas in DHS, range of lag

screw used was ranged from 65mm to 100mm (Table 2).

In both methods, infections related to wounds, urinary system and chest region were commonly associated and no complications related cardio vascular, respiratory was found. In intra operative complications of this study, there was ill fitting jig in 24% cases of PFN and in DHS method includes shattering of lateral cortex (8%) and difficulty in reduction (8%). Average time for fracture union in this study was between 14-17 weeks. In alignment difficulties of rotation, valgus deformity was not observed but varus deformity was observed in 12% cases of both PFN and DHS groups. Shortening was seen in 16% cases of DHS group, ranged from 0.8-1.4cm, which was compensated by referring raised shoe (Table 3).

Range of hip movements measured by Harris hip score method showed, flexion, abduction, internal rotation and external rotation were graded with grade-I and grade-II i.e. in most of the cases movements were good. In both the methods on an average 82% cases had good range of movement at hip joint (Table 4 & Figure 3).

### Conclusion

Proximal femoral nail (PFN) is fruitful in treatment of difficult fractures especially for subtrochanteric fractures with a great stability. None of the case with non-union was found in this study. Implant related complications were less in cases treated with dynamic hip screw. The rate of union was same in PFN and DHS groups. The average range of hip movements were good in 82% of cases treated with both the methods. With the above results it was concluded that proximal femoral nail and dynamic hip screw were ideal treatment methods to treat inter trochanteric and sub trochanteric fractures of the femur.

### References

- Hardy D, Descamps P, Krallis P *et al.* Use of an intramedullary hip screw compared with a compression hip screw with a plate for intertrochanteric femoral fractures. A prospective randomized study of one hundred patients. *J Bone Joint Surg Am.* 1998; 80:618-e630.
- Spivak JM, Zuckerman JD, Kummer FJ. Fatigue failure of sliding hip screw in hip fractures a report of three cases. *J Orthop Trauma.* 1991; 3:325-e331.
- Leung KS, So WS, Shen WY, Hui PW. Gamma nails and dynamic hip screws for per trochanteric fractures. Randomized prospective study in elderly patients. *J Bone Joint Surg Br.* 1992; 74:345-e351.
- Simmermacher RK, Bosch AM, Van der Werken C. The AO/ASIF-proximal femoral nail (PFN): A new device for the treatment of unstable proximal femoral fractures. *Injury.* 1999; 30:327-32.
- Pajarinen J, Lindahl J, Michelsson O, Savolainen V, Hirvensalo E. Pertrochanteric femoral fractures treated with dynamic hip screws or a proximal femoral nail: A randomized study comparing post-operative rehabilitation. *J Bone Joint Surg Br.* 2005; 87(1):76-81.
- Cyril Jonnes MS, Shishir SM, Syed Najimudeen MS. Type II Intertrochanteric Fractures: Proximal Femoral Nailing (PFN) Versus Dynamic Hip Screw (DHS). *Arch Bone Jt Surg.* 2016; 4(1):23-28.
- Goldhagen PR, O'Connor DR, Schwarze D, Schwartz E. A prospective comparative study of the compression hip screw and the gamma nail. *Journal of Orthopaedic Trauma.* 1994; 8(5):367-372.
- Hoffman CW, Lynskey TG. Intertrochanteric fractures of the femur: a randomized prospective comparison of the gamma nail and the ambi hip screw. *Australian and New Zealand Journal of Surgery.* 1996; 66(3):151-155.
- Radford PJ, Needoff M, Webb JK. A prospective randomised comparison of the dynamic hip screw and the gamma locking nail. *Journal of Bone and Joint Surgery B.* 1993; 75(5):789-793.
- Parker MJ, Handoll HH. Gamma and other cephalocondylic intramedullary nails versus extramedullary implants for extracapsular hip fractures in adults, *Cochrane Database of Systematic Reviews.* 2010; 16:3. Article ID CD000093.
- Anand J. *The Elements of Fracture Fixation,* Churchill Livingstone, New York, NY, USA, 1997.
- Nuber S, Schonweiss T, Ruter A. Stabilisation of x hip screw (DHS) with trochanteric stabilisation plate vs. proximal femur nail (PFN), *Unfallchirurg,* 2003; 106(1):39-47.
- Huang ZY, Liu XW, Su JC. Dynamic hip screw vs. proximal femur nail in treatment of intertrochanteric fractures in patients aged over 70 years old. *Shanghai Medical Journal.* 2010; 33(11):1042.
- Pajarinen J, Lindahl J, Michelsson O, Savolainen V, Hirvensalo E. Pertrochanteric femoral fractures treated with a dynamic hip screw or a proximal femoral nail: a randomized study comparing post-operative rehabilitation. *Journal of Bone and Joint Surgery B.* 2005; 87(1):76-81.
- Pires RES, Santana EO, Santos LEN, Giordano V, Balbachevsky D, dos Reis FB. Failure of fixation of trochanteric femur fractures: clinical recommendations for avoiding Z-effect and reverse Z-effect type complications, *Patient Safety in Surgery.* 2011; 5(1):17:1-6.
- Pavelka T, Matějka J, Cervenková H. Complications of internal fixation by a short proximal nail, *Acta Chirurgiae Orthopaedicae et Traumatologiae Cechoslovaca.* 2005; 72(6):344-354.
- Daniel FA, Noesberger B. Is the Proximal Femoral Nail a suitable implant for Treatment of all Trochanteric Fractures? *Clin Orthopaed Related Res.* 2005; 439:221-7. 3.
- Gallagher JC, Melton LJ, Riggs BL *et al.* Epidemiology of fractures of the proximal femur in Rochester, Minnesota. *Clinical Orthop.* 1980; 150:163-171.