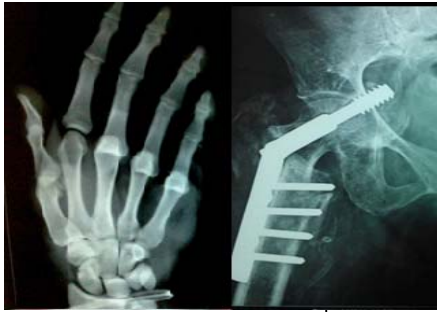



International Journal of Orthopaedics Sciences

ISSN: 2395-1958
IJOS 2018; 4(1): 243-246
© 2018 IJOS
www.orthopaper.com
Received: 16-11-2017
Accepted: 22-12-2017

Kanwarjit S Sandhu
Associate professor,
Department of orthopaedics,
Government medical college,
Patiala, Punjab, India

Amandeep S Bakshi
Assistant professor,
Department of orthopaedics,
Government medical college,
Patiala, Punjab, India

Ravinder K Banga
Senior resident,
Department of orthopaedics,
Government medical college,
Patiala, Punjab, India

Karamdeep S Kahal
Senior resident,
Department of orthopaedics,
Government medical college,
Patiala, Punjab, India

Saurabh Langeh
Junior resident,
Department of orthopaedics,
Government medical college,
Patiala, Punjab, India

Correspondence
Amandeep S Bakshi
Assistant professor,
Department of orthopaedics,
Government medical college,
Patiala, Punjab, India

Functional outcomes in humeral shaft fractures- Conservative management versus operative procedure

**Kanwarjit S Sandhu, Amandeep S Bakshi, Ravinder K Banga,
Karamdeep S Kahal and Saurabh Langeh**

DOI: <https://doi.org/10.22271/ortho.2018.v4.i1d.36>

Abstract

Aim: To compare the functional outcomes of humerus fractures managed by conservative method versus operative procedures in reference to radiological evidence of bony union, final functional outcome and complications.

Material and methods: Prospective randomized study was conducted on 30 patients with Humerus shaft fractures, admitted in the department of Orthopaedics, Government Medical College, Patiala. The patients had been randomly divided into two groups- conservative management or operative treatment, 15 in each group. Patients were followed up for 1 year for radiological, clinical outcomes and complications. Standard treatment for most humeral shaft fractures is non-operative functional bracing; however, certain clinical scenarios necessitate operative intervention. Thirty adult patients with a humerus shaft fracture who satisfied inclusion criteria were treated at Government Medical College, Patiala with either a functional brace (nonoperative treatment group) or compression plating (operative treatment group).

Results: Most of the patients with humerus fractures presented after road side accidents. There is no significant difference in time of union in conservative management (12 ± 2.6 weeks) and operative management (11.7 ± 2.8 weeks). Elbow ROM at fracture union was not significantly different between the 2 groups (average 120.3 degrees range, 80° - 180° vs average 132 , range, 25° - 150°) in the nonoperative and operative groups, respectively ($P=0.5532$). Malunion was more frequent in the conservatively managed patients (12.7%) as compared to the operative group (1.3%).

Conclusion: All humerus fractures needs assessment for conservative or operative management depending on the fracture characteristics and patient expectations.

Keywords: humeral shaft fractures, conservative management, versus operative procedure

Introduction

Fractures of the humeral shaft account for approximately 3% of all fractures.^[1] The fractures were classified as AO type a in 63.3%, type B in 26.2% and type C in 10.4%. Most (60%) occurred in the middle third of the diaphysis with 30% in the proximal and 10% in the distal third. The severity of the fracture and soft-tissue injury was greater with increasing injury severity. Less than 10% of the fractures were open. There is a bimodal age distribution with a peak in the third decade as a result of moderate to severe injury in men and a larger peak in the seventh decade after a simple fall in women.^[2,3] Thirty-three to 90% of humeral shaft fractures are reported to be treated conservatively, with functional bracing being the most common non operative treatment option for the majority of fractures. Operative intervention may include compression plate fixation, intra medullary nailing, or external fixation, depending on the properties of the fracture and other associated injuries.^[4,5]

Functional bracing of humeral shaft fractures may be the current gold standard treatment; however, more recent studies questioned this management for all fractures. Denard *et al.* described a retrospective comparative study of operative versus non-operative management of humeral shaft fractures. They observed a significantly lower rate of nonunion and malunion in those patients undergoing operative management, although they did not find any difference in the final range of motion between these groups. Therefore, authors concluded that "in certain clinical scenarios, these fractures may be well served by compression plating". More recently, a review of non-operative management for humeral shaft fractures demonstrated a higher rate

of non-union for proximal third fractures and suggested that a lower threshold of surgical fixation of such fractures may be considered.^[6] This trend in the current literature towards operative fixation of selected humeral shaft fractures is reflected in a study from Finland where the rate of surgical treatment was demonstrated to have doubled over the last two decade.^[7]

Open reduction and plate fixation and intra medullary nailing, are the two most commonly recognized operative methods of fixation for humeral shaft fractures. There have been multiple randomized controlled trails comparing the outcome of these methods of fixation; however, there are some advantages and disadvantages for both techniques. A meta-analysis of five studies including 237 patients demonstrated that a lower complication rate was observed with open reduction and plate fixation.^[8]

Aim and objectives

To compare functional outcomes of operative vs conservative management of shaft of humerus fractures and related complications at 1 year follow up

Material and methods

This was a prospective observational study conducted in the Orthopaedic department of Government Medical College, Patiala. A total of 30 diagnosed cases of shaft of humerus fracture were taken up after fulfilling the inclusion criteria. An informed consent was taken from all patients and a detailed history and general physical examination was done to rule out any other chronic disease or illness. Patients were divided into two groups, one was managed operatively and other conservatively and functional outcome was compared.

Criteria

Inclusion Criteria:

1. A closed, humerus shaft fracture
2. Age between 18-65 at the time of injury
3. Entry into the study within 2 weeks of injury

Exclusion Criteria:

1. Humeral shaft fractures that extend into the articular surface
2. Open humeral shaft fractures
3. Vascular injury requiring repair
4. Pathologic fracture
5. Immunocompromised patient

Interventions

Patients treated non operatively were placed in a temporary splint and sling on initial hospital presentation. Approximately 1 week thereafter, this splint was exchanged for a functional brace that encircled the arm and consisted of 2 plastic sleeves joined by adjustable hook and loop fasteners. Patients were instructed to passively move the elbow as pain allowed. Active exercises were then instituted when the patient was comfortable, after which the functional brace was gradually weaned.

The patients managed surgically were operated by anterolateral or posterior approach depending on the fracture location. Internal fixation was achieved with either locking or non-locking 4.5-mm plates. The choice of implant was at the discretion of the treating surgeon. Postoperatively, patients were placed in a sling and encouraged to begin ROM exercises on first post-operative day onwards.

The patients were followed up monthly for clinical and

radiological examination for union and complications if any. Bony union was defined as bridging callus on 2 orthogonal views with the disappearance of fracture lines. This definition is in agreement with that of Rutgers and Ring.^[9] Malunion was determined if there was radiographic evidence of angulation $>20^\circ$ in any plane. Malunion was recorded as a dichotomous outcome. Elbow ROM in the affected extremity was determined from the last recorded follow-up visit and was documented in degrees of total arc of motion at the elbow.

Infection was determined by an elevated white blood cell count, the presence of purulent discharge at the fracture site or a positive intraoperative gram stain. Nonunion was defined by failure of the fracture to consolidate 6 months after injury. Radial nerve palsy was identified and recorded. Additional complaints were documented if there were any at follow-up visits when fracture union was established and if the patient experienced any significant pain with movement, limitation of motion that negatively impacted daily living, or dissatisfaction with the cosmetic appearance of the surgical scar. Return to work status was documented for patients who were employed at the time of injury.

Descriptive statistics were used to explore the mean scores and standard deviation of time to union and elbow ROM outcomes, and to summarize demographic, outcome, and complication data.

Results

In the humeral shaft fracture population, there were no significant differences related to age and sex. There were similar no of patients with comorbidities like hypertension, or diabetes. Average patient age in the non-operative group was 37.4 ± 9.8 years and 37.9 ± 14.02 years in the operative group ($P=.59$). Median patient ages were 34 and 30 years, respectively. In the study majority of the patients (60%) were admitted due to a road traffic accident and rest due to fall on outstretched hand or fall from height .

There was no significant difference in time to union between the 2 treatment groups (12 ± 2.6 weeks; range, 8-18 weeks) in the non-operative (11.7 ± 2.8 weeks, range, 8-18 months) in the operative, $P=.8659$).

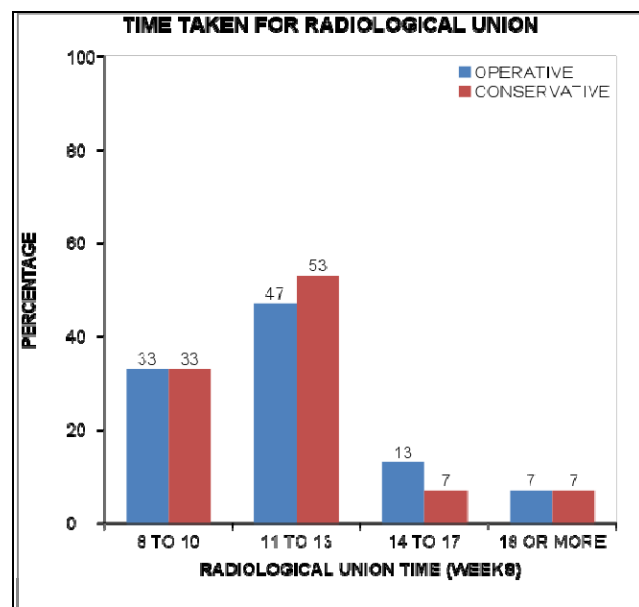


Fig 1

Elbow ROM at fracture union was not significantly different between the 2 groups (average 120.3 degrees range, 80°-180° vs average 132, range, 25°-150°) in the non-operative and operative groups, respectively ($P=0.5532$).

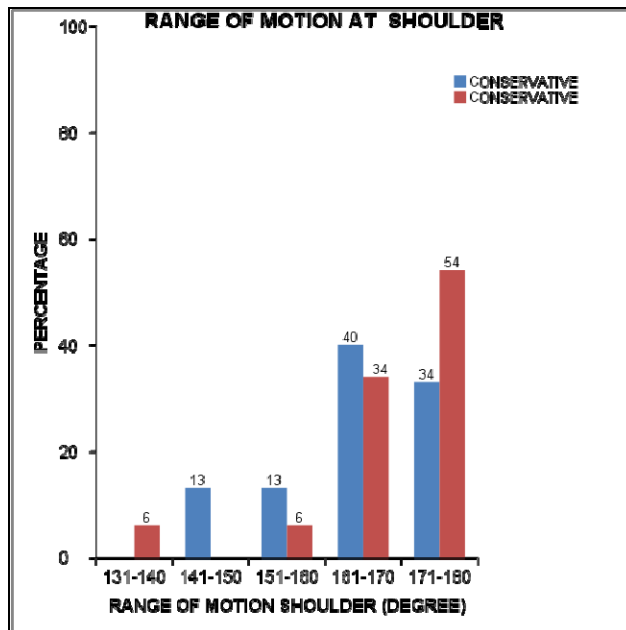


Fig 2

Both the groups had similar rates of non-union (7%). Malunion occurred more frequently in the non-operative group compared to the operative group (12.7% vs 1.3%; $P=0.0011$).

Radial nerve palsies were observed in both groups which was managed conservatively and all the patients regained full function at three months after the injury and did not require any further intervention.

Discussion

Closed treatment of humeral shaft fractures represents an effective method of fracture management and has sustained critical evaluation throughout the literature. [6] Functional bracing remains the gold standard against which all other treatments of humerus fractures measured and is functionally successful in a majority of cases. [4] However, there remains a measured risk of complications and subsequent patient morbidity in fractures treated non-operatively.

The goal of fracture management is restoration of physiologic function. Treatment of humerus fractures is dictated by certain anatomical factors, as outlined by Mast *et al.* [10]. The humerus is not a weight-bearing bone and compressive forces are not as significant a factor in healing as in other long bones, such as the femur and tibia. Rigid immobilization of the shoulder therefore is not necessary because the glenohumeral articulation allows significant mobility with minimal torsional stress. Last, the physiologic-dependent position of the upper arm uses gravitational forces to realign the fracture fragments. This is the concept behind Sarmiento *et al.* [2] description of functional bracing in that the fracture is stabilized by the surrounding soft tissues via the brace while realignment is obtained through the effect of gravity. Additionally, elbow and shoulder ROM is actively preserved with functional bracing and stimulates osteogenesis and healing.

Operative intervention achieves many of the same goals by

providing fracture stability with plate fixation and allowing early mobilization of the adjacent joints. [11] Plate fixation is recommended as the treatment of choice for those fractures requiring operative intervention. Some studies confirm that internal fixation results in similar functional outcome as compared to intramedullary nailing in a majority of humeral fractures but complications are more common, more severe, and required more secondary procedures in the latter. [12] Our results demonstrate that elbow ROM is well preserved in both non-operative and operative treatment groups. Acceptable elbow ROM has been observed in both functional bracing and compression plating separately, and based on our comparative data, both treatment methods yield similar outcomes. Additionally, no significant difference in the time to union or the incidence of infection following an operation as compared to non-operative treatment was noted.

All radial nerve palsies observed after fracture management resolved, and our data support that most radial nerve palsies following humeral shaft fracture treatment are transient and do not require further intervention. [13]

We found an increased incidence of malunion in non-operative treatment. Rutgers and Ring described in their retrospective analysis of 52 patients treated non-operatively that angular deformity $>20^\circ$ was present in 9% of patients and Sarmiento *et al.* in a large series of non-operatively treated humeral shaft fractures noted a 2% incidence of angular deformities $>25^\circ$. A higher incidence (13%) of angular deformity $>20^\circ$ was found, which was significantly greater than that observed in patients treated with operative fixation.

Multiple reports have shown that acceptable humeral shaft healing following non-operative management is dependent on certain fracture patterns. The absence of a validated outcome measure, such as the Disability of the Hand and Shoulder or American Shoulder and Elbow Surgeons' questionnaire, contributed to another significant limitation. Shoulder and elbow ROM is noted to be well-preserved following treatment with a functional brace, while elbow restriction after operative fixation has been reported. [12]

It remains to be seen if compressive plating will occupy a definitive role in the standard treatment of most uncomplicated humeral shaft fractures, certainly in an age of minimally invasive osteosynthesis techniques. Nonoperative treatment of most humeral shaft fractures with bracing remains an effective method that achieves acceptable functional results with few complications; however, the incidence of nonunion and malunion are shown to be significantly greater following nonoperative management. This may result in surgical interventions later with an added morbidity to correct these problems. Literature demonstrates that osteosynthesis of humeral shaft fractures affords early return of upper arm function with no significant incidence of complication.

Conclusion

Nonoperative treatment of most humeral shaft fractures with bracing remains an effective method that achieves acceptable functional results with few complications. Operative fixation may be applied to more cases of humeral shaft fractures than has historically been taught. We need to consider all the advantages and disadvantages of nonoperative and operative management for a majority of these fractures to coordinate an appropriate treatment plan best serving the fracture characteristics and patient expectations. Further research is necessary to verify successful outcomes, analyze associated complications, and achieve optimal patient outcomes.

Consent – Consent taken from all the patients as per consent form in written.

Ethical Study – Study is done as per ethics committee of the institute

References

1. Igbigbi PS, Manda K. Epidemiology of humeral fractures in Malawi. *Int Orthop*. 2004; 28(6):338-41.
2. Sarmiento A, Zagorski JB, Zych GA, Latta LL, Capps CA. Functional bracing for the treatment of fractures of the humeral diaphysis. *J Bone Joint Surg Am*. 2000; 82(4):478-486.
3. Cole PA, Wijdicks CA. The operative treatment of diaphyseal humeral shaft fractures. *Hand Clin*. 2007; 23(4):437-448.
4. Zhao JG, Wang J, Wang C, Kan SL. Intramedullary nail versus plate fixation for humeral shaft fractures: A systematic review of overlapping meta-analyses. *Medicine (Baltimore)*. 2015; 94(11): e599.
5. Wang X, Chen Z, Shao Y, Xia Q, Ma Y, Fu Da. A meta-analysis of plate fixation versus intramedullary nailing for humeral shaft fractures. *J Orthop Sci*. 2013; 18(3):388-97.
6. Kumar S, Shanmugam N, Kumar S, Ramanusan K. Comparison between operative and non-operative treatment of fracture shaft of humerus: An outcome analysis. *Int J Res Orthop*. 2017; 3(3):445-50.
7. Clement ND. Management of Humeral Shaft Fractures; Non-Operative versus Operative. *Arch Trauma Res*. 2015; 4(2):e28013.
8. Kumar S, Shanmugam N, Kumar S, Ramanusan K. Comparison between operative and non-operative treatment of fracture shaft of humerus: An outcome analysis. *Int J Res Orthop*. 2017; 3(3):445-50.
9. Rutgers M, Ring D. Treatment of diaphyseal fractures of the humerus using a functional brace. *J Orthop Trauma*. 2006; 20(9):597-601.
10. Mast JW SP, Harvey JP. Fractures of the humeral shaft. *Clin Orthop Rel Res*. 1975; 12:254-62.
11. Foulk DA, Szabo RM. Diaphyseal humeral fractures; natural history and occurrence of nonunion. *Orthopaedics*. 1995; 18(4):333-5.
12. Denard A Jr, Richards JE, Obremskey WT, Tucker MC, Floyd M, Herzog GA. Outcome of nonoperative vs operative treatment of humeral shaft fractures: a retrospective study of 213 patients. *Orthopedics*. 2010; 33(8).
13. Mahabier KC, Vogels LM, Punt BJ, Roukema GR, Patka P, Van Lieshout EM. Humeral shaft fractures: retrospective results of non-operative and operative treatment of 186 patients. *Injury*. 2013; 44(4):427-30.
14. Mahabier KC, Vogels LM, Punt BJ, Roukema GR, Patka P, Van Lieshout EM. Humeral shaft fractures: retrospective results of non-operative and operative treatment of 186 patients. *Injury*. 2013; 44(4):427-30.