



ISSN: 2395-1958
IJOS 2018; 4(1): 259-262
© 2018 IJOS
www.orthopaper.com
Received: 17-11-2017
Accepted: 21-12-2017

Dr. Amandeep Singh Bakshi
Assistant professor, Department of Orthopaedic surgery, Govt medical college, Patiala, Punjab, India

Dr. Pardeep Kumar
Junior Resident, Department of Orthopaedic surgery, Govt medical college, Patiala, Punjab, India

Dr. BS Brar
Professor, Department of Orthopaedic surgery, Govt medical college, Patiala, Punjab, India

Correspondence
Dr. Pardeep Kumar
Junior Resident, Department of Orthopaedic surgery, Govt medical college, Patiala, Punjab, India

Comparative study between DHS and PFN in intertrochanteric fractures of femur

Dr. Amandeep Singh Bakshi, Dr. Pardeep Kumar, Dr. BS Brar

DOI: <https://doi.org/10.22271/ortho.2018.v4.i1d.39>

Abstract

A total 40 patients with fresh intertrochanteric fracture femur (within 15 days) were included in this study. 20 underwent DHS and 20 underwent PFN procedure. After evaluation at 10, 14, 18 weeks for radiological union and at 6 months for Harris Hip score, we found PFN and DHS to be equal in peri-operative and post-operative complications, long term union. But PFN is better in terms of less blood loss, early mobilization, duration of surgery.

Keywords: PRP, plantar fasciitis, Tennis elbow, Bone grafting

Introduction

Hip fracture contributes to both morbidity and mortality in the elderly. The demographics of world populations are set to change, with more elderly living in developing countries. ^[1] Gulberg et al. has predicted that the total number of hip fractures will reach 2.6 million by 2025 and 4.5 million by 2050. In 1990, 26% of all hip fractures that occurred in Asia were intertrochanteric fractures whereas this figure could rise to 37% in 2025 and 45% in 2050. ^[2] Proximal femoral Fractures account for a large proportion of hospitalization among trauma cases. An overwhelming majority of these patients (>90%) are aged above 50 years. The incidence of these fractures is 2–3 times more in females as compared to male population. Generally, intramedullary fixation and extramedullary fixation are the 2 primary options for treatment of such fractures. The dynamic hip screw (DHS), commonly used in extramedullary fixation, has become a standard implant in treatment of these fractures. Proximal femoral nail (PFN) and Gamma nail are 2 commonly used devices in the intramedullary fixation. Previous studies showed that the Gamma nail led to a relatively higher incidence of post-operative femoral shaft fracture. ^[10]

PFN, introduced by the AO/ASIF group in 1997, has become prevalent in treatment of intertrochanteric fractures in recent years because it was improved by addition of an antirotation hip screw proximal to the main lag screw.

Although the effects of PFN and DHS in treatment of intertrochanteric fractures have been reported, the results and conclusions are not consistent. ^[10] Therefore; we conducted this comparative to investigate whether there is a significant difference between PFN and DHS fixation in treatment of intertrochanteric fractures in terms of various clinical parameters like blood loss, duration of surgery and Harris Hip Score

Material and Methods

The present prospective study was conducted at Govt. Medical College & Rajindra Hospital, Patiala, in patients of inter-trochanteric fractures attending out-patient department and emergency of orthopaedics from 2016 to 2017

A total of 40 patients with fracture inter-trochanteric femur were taken for evaluation of DHS v/s PFN after fulfilling the inclusion criteria.

Inclusion Criteria

Closed inter-trochanteric fracture.

1. Age > 18 years (skeletal maturity)

2. Time < 2 weeks.
3. Patient Willing

Exclusion Criteria

1. Age < 18 years. (skeletal immaturity)
2. Time > 2 weeks.
3. Associated Fracture neck femur.
4. Compound fracture.
5. Patient Refusal

Evaluation of the patient was done with xrays and blood investigations.

All patients were regularly followed up in OPD at an interval of 10,14,18 weeks .In patients with stable inter-trochanteric fractures, either treated with PFN or DHS, partial weight bearing was started early. Unstable inter-trochanteric fracture cases treated with PFN, partial weight bearing will be started at 2-4 weeks while those treated with DHS partial weight bearing was started between 6-8 weeks depending upon reduction and stability of fracture. Full weight bearing was started in all cases only after radiological union.

Clinicoradiological assessment of the patient was done and comparison was done in terms of:

- Duration of surgery
- Total amount of blood loss (during surgery + drain output)
- Timing of early mobilization and full weight bearing
- Radiological assessment for callus formation and bony union.
- Complications with technical and implant failure
- Harris hip score for clinical and radiological assessment at end of 6 months

All the results were analysed by SPSS software. Chi- square test, Mann- Whitney U test and student t test were used for assessment of level of significance. P- Value of less than 0.05 was taken as significant.

Observations and Results

A Total of 40 subjects were included in the present study, out of which, 20 underwent DHS treatment while the remaining 20 underwent PFN treatment. 72.5% patients were aged more than 50 years and 27.5% below 50 yrs in which 55% male and 45% females and 62.5% of cases were due to low velocity and 37.5% due to high velocity trauma.and most of patient belongs to type 2 AO classification.

Mean blood loss among the subjects of the DHS group and the PFN group were found to be 292.50 and 108.50 ml respectively. Significant results were obtained while comparing the mean blood loss in between the subject group of control group respectively (P- value < 0.05).

Mean duration of surgery in the patients of DHS group and

the PFN group were found to be 63.35 and 54.70 minutes respectively. Significant results obtained while comparing the mean duration of surgery in between the subjects of the DHS group and the PFN group (P- value < 0.05).

Mean time of early mobilization with toe touch weight bearing in the DHS group and the PFN group were found to be 41.3 and 14.45 respectively. Significant results were obtained while comparing the mean time of early mobilization till weight bearing in between DHS group and PFN group (P- value < 0.05).

Among the subjects of the DHS group, in 11 patients (55%), complete union occurred in 10 to 14 weeks' time, while in 9 patients (45%), complete union occurred in 14 to 18 weeks' time. Among the subjects of the PFN group, in 14 patients (73.6%), and 5 patients (26.4%), complete union occurred in 10 to 14 weeks and 14 weeks to 18 weeks' time respectively. No significant difference was obtained while comparing the complete union cases in between PFN group and DHS group (P- value > 0.05).

In the DHS group, skin puckering with superficial infection was seen in 1 (5%) patient while in the PFN group Non-union occurred in 1 (5%) patient.

Mean Harris Hip Score among the patients of DHS group and the PFN group were found to be 83.75 and 84.4 respectively. No- Significant results were obtained while comparing the mean HHS in between the DHS group and the PFN group (P- value > 0.05).

Discussion

The present study recruited 40 adult patients with intertrochanteric fractures randomized into 2 groups.

Mean age of the present study population was 58.58 years and more than 80% of the study population was above the age of 55 years.

Male to female ratio in this study was 1.73:1. The difference in current study is probably because the male to female ratio is measured amongst operated fractures only and not for the actual sex incidence for all trochanteric fractures.

In the present study, we observed that majority of the patients (70%) belonged to category 2 of AO classification.

Our study shows that the average duration of surgery for PFN was 54.70 minutes which is shorter than average time required for DHS which is 63.35 minutes. Duration of surgery was shorter in PFN group by a mean of 12.8 min; although the duration of implant fixation was almost similar in both the groups, time required for wound closer was significantly longer in DHS group probably due to larger incision and extensive dissection as compared to the percutaneous technique of PFN.

Table 1: Mean value of various descriptive parameters among subjects of DHS group

Parameter	DHS			PFN		
	N	Mean	Std. Deviation	N	Mean	Std. Deviation
Age	20	60.3000	14.95643	20	56.8500	20.65067
Duration of Surgery (mins)	20	63.3500	4.09460	20	54.7000	4.66905
Total amount of blood loss (ml)	20	292.5000	23.36777	20	108.5000	46.71019
Duration of hospital stay (days)	20	12.8500	1.87153	20	12.0000	2.00000
Timing of early mobilization with toe touch weight bearing (days)	20	41.3	14.48	20	14.45	5.25
Total Harris Hip Score	20	83.75	4.476	20	84.4	15.69

Mean blood loss in the DHS group was 292.5 ml while the mean blood loss in PFN group was 103.5 ml. The difference between the two group was statistically significant ($p < 0.0001$) The walking ability between both the groups was assessed using Harris Hip Score.

The mean Harris Hip Score in PFN group was 84.25 and in the DHS group was 83.45

The results obtained in the current study were comparable to available literature. It was found to be not statistically significant and shows that long term results of both intramedullary and plate fixation are similar

Implant	No. of Cases	Excellent	Good	Fair	Poor
DHS	20	2	12	6	0
PFN	20	6	13	0	1

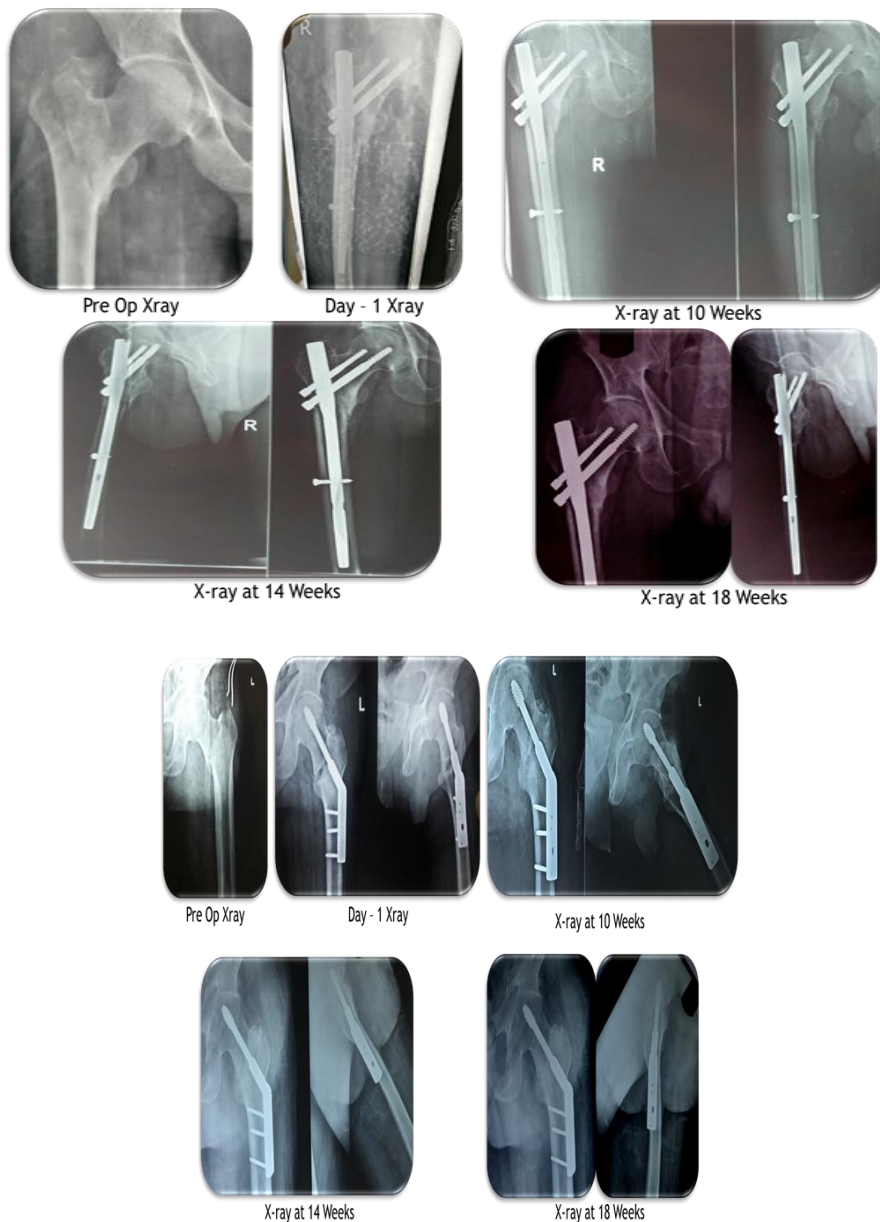
But at 6 months most of cases in PFN belongs to excellent and good groups but in DHS most of cases belongs to good

and fair group of harris hip score.

All the fractures in the dynamic hip screw group had united by 6 months one case of DHS with puckering of skin due to infection need minor surgery.

There was one case of PFN showing implant failure z effect and nonunion and need revision surgery. On the basis of observations made in our study, we can safely conclude that Proximal Femoral nail gives better results in intertrochanteric fractures in terms of Amount of blood loss during surgery, Early mobilization, Duration of surgery.

There is no difference between the two modalities in terms of Number of per operative and post-operative Complications, Long term mobility, Fracture union, But as this study involved small number of patients (n=40), so its results cannot be projected to the general population, for which a trial involving large number of cases is required.



References

1. Dhanwal DK, Dennison EM, Harvey NC, Cooper C. Epidemiology of hip fracture: Worldwide geographic variation. Indian Journal of Orthopaedics. 2011; 45(1):15-22.
2. Gulberg B, Johnell O, Kanis JA. World-wide projection for hip fractures. Osteoporos Int. 1997; 7(5):407-13.
3. Zhang K, Zhang S, Yang J et al. Proximal Femoral Nail vs. Dynamic Hip Screw in Treatment of Intertrochanteric Fractures: A Meta-Analysis. Medical Science Monitor:

International Medical Journal of Experimental and Clinical Research. 2014; 20:1628-1633

4. Baumgaertner MR, Oetgen ME. Intertrochanteric hip fractures. In: Browner BD, Jupiter JB, Levine AM, Trafton PG, editors. *Skeletal Trauma*, 4th ed. Philadelphia: Saunders Elsevier. 2009, 1913-56.
5. Koval KJ, Cantu RV. Intertrochanteric fractures. In: Bucholz RW, Heckman JD, Court-Brown C, editors. *Rockwood & Green's Fractures in Adults*, 6th ed. Philadelphia: Lippincot Williams and Wilkins. 2006, 1793-825.
6. Muller ME, Allgower M, Schneider R. *The comprehensive classification of fractures of long bones*, 3rd edition. New York, Springer-Verlag. 1990, 118.
7. Lavelle DG. Fractures and dislocation of hip. In: Canale ST, Beaty JH, editors. *Campbell's Operative Orthopaedics*, 11th ed. Philadelphia: Mosby Elsevier; 2008: 3237-70.
8. Hoffmann R, Haas NP. Femur, proximal. In: Ruedi TP, Buckley RE, Moran CG, editors. *AO Principles of Fracture Management*. 2 nd expanded ed. New York: Thieme. 2007, 751-66.
9. Jonnes C, SM S, Najimudeen S. Type II Intertrochanteric Fractures: Proximal Femoral Nailing (PFN) Versus Dynamic Hip Screw (DHS). *Archives of Bone and Joint Surgery*. 2016; 4(1):23-28.
10. Bhakat U, Bandyopadhyay R. Comparative Study between Proximal Femoral Nailing and Dynamic Hip Screw in Intertrochanteric Fracture of Femur. *Open Journal of Orthopedics*. 2013; 3:291-295.