

ISSN: 2395-1958
IJOS 2018; 4(1): 01-04
© 2018 IJOS
www.orthopaper.com
Received: 01-11-2017
Accepted: 02-12-2017

Dr. Mahendra Kumar KL
Associate Professor,
Department of Orthopaedics,
Mims, Mandya, Karnataka,
India

Dr. Manjappa CN
Professor, Department of
Orthopaedics, Mims, Mandya,
Karnataka, India

Retrospective analysis of surgical management of patients with distal femur fracture by locking compression plates

Dr. Mahendra Kumar KL and Dr. Manjappa CN

DOI: <https://doi.org/10.22271/ortho.2018.v4.i1a.01>

Abstract

Introduction: The following study was conducted to examine the short term clinical and radiological results particularly early complications and healing rate of distal femur fracture treated with distal femur LCP.

Materials and Methods: The study was conducted in patients treated for distal femur fracture (type A, B & C – AO classification) at Mandya Institute of Medical Sciences, Mandya from month of Nov 2015 to Oct 2017. Forty distal femur fracture patients in this study, were fixed with DF-LCP with Bone grafting where the distal femur fractures were associated with extensive bone loss. Patients' age ranged from 18 to 80 years with mean of 49.

Results: The sample consisted forty patients, 23 were males and 17 females. The patients' ages ranged from 18 - 80 years with mean of 49 years. The causes of fractures were motor vehicle accident in 26 patients and fall in 14 patients. 27 fractures involved the right side and 13 involved the left. The average hospitalization was 15 days with a range of 10 to 20 days. The average number of days from injury to surgery was 5 days with a range of 02 to 07 days. Functional outcome was rated as per NEER'S RATING SCORE, we got excellent results in 18 cases, good in 14, fair in 06 and poor in 02 patients.

Conclusion: The distal femur LCP with accurate positioning and fixation is a good implant to use for fracture of distal femur. We recommend use of this implant in Type A, B, C and osteoporotic fractures with satisfactory results. In our study, we found excellent results in type C and osteoporotic fractures, however, long term studies are needed to prove definitively acceptable outcomes so that this technique can become part in the armamentarium of the orthopedic trauma surgeon.

Keywords: Distal femur fracture, bone graft, osteoporotic fracture, Neer's rating score, distal femur – LCP

Introduction

Distal femur fractures are complex injuries that could be difficult to treat with an incidence of approximately 37 per 1,00,000 person-years.^[1] "Few injuries present more difficult problems than those associated with supracondylar and intercondylar fractures of femur"- Sir Reginald Watson Jones. ^[1] The above statement describes the complexity in treating these fractures. Severe soft tissue damage, comminution, intraarticular extension, injury to the Quadriceps and extra articular adhesions are some of the challenges faced by the surgeons usually caused by high velocity trauma and loss of fixation due to screw pull out are the difficulties following fractures in osteoporotic patients.

In the early 20th century the management of displaced supracondylar fracture femur was based on the principle of Watson jones ^[1] & John charnley ^[2] which comprised skeletal traction, manipulation of fracture and external immobilization in the form of casts and cast bracings. However complications like deformity, shortening, prolonged bed rest, knee stiffness, angulation, joint incongruity, malunion, quadriceps wasting, knee instability and post-traumatic osteoarthritis were on the higher side. This prompted the evolution of more aggressive treatment i.e. Open reduction and internal fixation. The surgical goals of treatment are anatomic reduction of fracture, maintaining articular congruency, restoration of limb length and rotation, pillar reconstruction and early restoration of knee range of movements and bone grafting for extensive bone loss and stable fixation that allows for early mobilization.

Correspondence
Dr. Manjappa CN
Professor, Department of
Orthopaedics, Mims, Mandya,
Karnataka, India

The trend of open reduction and internal fixation is increasing in the recent years with good results being obtained with the AO blade plate, dynamic condylar screw, intramedullary supracondylar nail & locking compression plates. Elderly patients with osteoporotic bones are challenging in the management of fracture around the knee because articular congruency should be maintained for painless movements. Loss of stable fixation in osteoporotic bones is of great concern in elderly patients due to thin cortices, a wide medullary canal, relative osteopenia, and fracture comminution.

Internal fixation with locking plates creates a toggle free, fixed angle construct. [3] The introduction of plates with the option of locked screws has provided the means to increase the rigidity of fixation in osteoporotic bone or in the presence of periarticular or juxta-articular fractures with a small epiphyseal segment. [3] The implant offers multiple points of fixed-angle contact between the plate and screws in the distal part of femur, theoretically reducing the tendency for varus collapse that is seen with traditional lateral plates. [3] It is now well recognized that the best treatment option for distal femur fracture is open reduction and internal fixation with DF-LCP allows both locking and compression screws which has the advantage of combination of conventional compression plating and locked plating techniques which enhances the plate osteosynthesis along with articular surface realignment. Anatomically pre contoured built reduces soft tissue problems and acts as internal external fixator with a distinct advantage of unicortical fixation and least chance of plate back out as the screw gets locked to the plate.

Further, Minimal soft tissue injury occurs when closed reduction is done with MIPPO technique. The holes on the shaft of DF-LCP are oval, which allows proper fixation of compression screw or locking screw which leads to more precise placement of the plate, as it gets compressed more closely to the bone. [2, 4] The purpose of this study is to evaluate the technical requirements, clinical results, radiological results, complications and outcome in the use of these locking compression plates in distal femur fractures.

Methods

This was a retrospective study conducted at department of orthopedics, Mandya Institute of Medical Sciences. The patients who attended the orthopedic department of Mandya Institute of Medical Sciences with distal femur fracture and with their complete data during November 2015 to October 2017 were included in this study. Patients with incomplete data were excluded from the study. Personal data and pattern of injuries who underwent the distal femur LCP operative procedure were extracted from the case records and OT register. Data extraction was manually done by reviewing each case file. Data collected was analyzed using simple statistical method of percentages and functional outcome was rated using Neer’s rating score.

Results

This is a study of 40 cases of Distal Femur fracture in adults and elderly treated by distal femur locking compression plate (DF-LCP) during the study period. All cases were available for follow up. Out of these, the maximum were in the age group of 30 – 65 years (n = 33, 82.5%). There were 23 males (57.5%) and 17 females (42.5%). Motor vehicle accidents were the most common cause of fracture distal femur responsible for 65% (n=26) and other cause was self-fall responsible for 35% (n=14) of cases.

In our study, open fractures accounted for 17.5% (n=7) and remaining being closed fractures 82.5% (n= 33) and 67.5% (n=27) involved right femur and 32.5% (n=13) involved left femur. According to AO classification we had 52.5% (n=21) in 33A, 30% (n=12) in 33B, and 17.5% (n=07) in 33C. There were 10% (n= 4) cases who received autologous iliac crest bone graft. Study revealed 12.5% (n=5) cases with poor knee flexion of <90°, 27.5% (n=11) with flexion range of 90-120° and 60% (n=24) with good flexion of >120°. Two cases had infection at the operative site which required wound debridement, limb shortening (<2 cm) was observed in 10% (n=4) and there were no nonunion in any of the cases.

Table 1: Distribution of cases by type of fracture

AO Classification	No. of cases	Percentage
33A	21	52.5
33B	12	30
33C	7	17.5

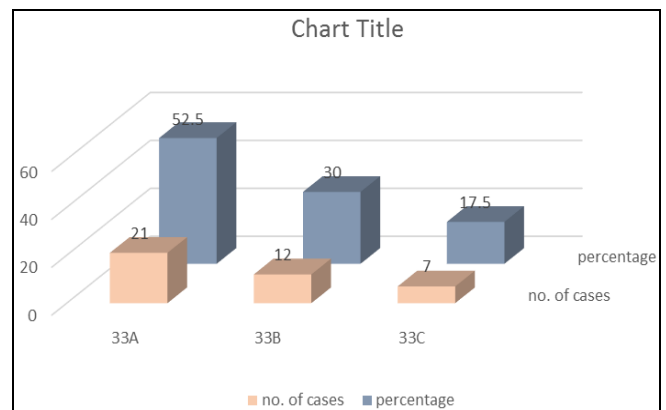
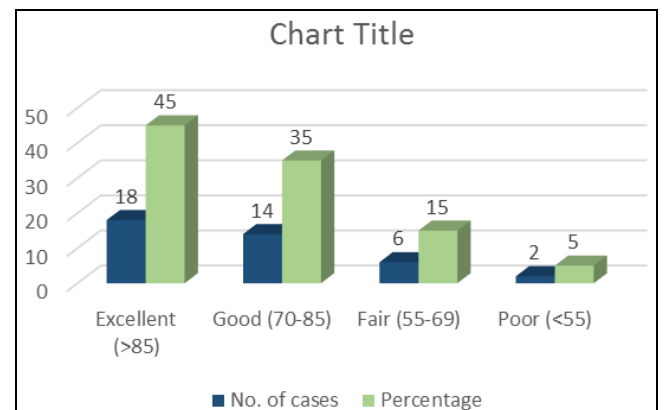


Table 2: Neer’s rating score.

Rating in points	No. of cases	Percentage
Excellent (>85)	18	45
Good (70-85)	14	35
Fair (55-69)	6	15
Poor (<55)	2	05



The functional outcome was assessed according to neer’s rating score and we had excellent results in 45% (n=18), good in 35% (n=14), fair in 15% (n=6) and poor in 5% (n=2).

Discussion

Distal femoral fractures are challenging injuries despite improvements of fixation techniques and plate designs. Some authors [5, 6] have demonstrated the ability of locked plates to absorb more energy before failure compared with angled blade plates or retrograde intramedullary nails, thereby having

a lower incidence of loss of fixation. Although no agreement exists on management of complex distal femoral fractures. The results reported by several authors [7, 8, 9-11] suggest modern locking plates represent an advance for fixing different fracture patterns in this region. These include either high-energy fractures with severe bone comminution that may be further complicated through open injury, fractures in older people with poor bone quality.

The main goals of this techniques is to maintain the important anatomy and vascularity to promote early fracture healing. The LCP is a single beam (fixed angle) construct where strength of its fixation is equal to the sum of all screw- bone interfaces rather than a single screw's axial stiffness and with high pull out resistance as in unlocked plates. It acts as an 'internal fixator', functions by splinting the fracture rather than compression and hence allows a flexible stabilization, avoids stress shielding and induces callus formation. [12, 13]

In this study, standard lateral approach was used for the fixation of simple intraarticular fractures as well as extra articular fractures has been done. However, more extensive approaches are needed for fixation of complex intraarticular fractures (C2/C3) requiring lateral para patellar arthrotomy for direct reduction of joint surface. The recommended number of screws are three to four on either side of the fracture gap. [14, 15]

In a study by Miclau *et al.* [16] bone graft rates of supracondylar femur fractures ranged between 0% and 87%. 10% of cases who received bone graft in our study can be attributed to higher percentage of type A and B fracture patterns with less bone loss.

In a similar retrospective evaluation, Kregor *et al* [11] reported a 93% union rate without secondary bone grafting and 7% required secondary bone grafting and mean knee range of motion was upto 109 degrees. Implant failure was observed in 5 cases, each requiring revision surgery. Our study revealed, 100% union rate of which 10% required bone grafting and 87.5% had good range of knee motion of 90-120⁰, which can be related to lesser sample size.

Yeap, E.J., and Deepak, A.S [17] conducted a retrospective review on eleven patients who were treated for Type A and C distal femoral fractures (based on AO classification) fixed with titanium distal femoral locking compression plate. Clinical assessment was conducted at least 6 months post-operatively using the Schatzker score system. Results showed that four patients had excellent results, four good, two fair and one failure.

Zlowodzki *et al* [18] conducted a study which showed average nonunion, fixation failure, deep infection, and secondary surgery rates were 5.5%, 4.9%, 2.1%, and 16.2% respectively. Some of the technical errors that have been reported for fixation failure have involved waiting too long to bone graft defects, allowing early weight bearing, and placing the plate too anterior on the femoral shaft.

Vallier *et al* [19] in his study concluded that locking plates should only be used when conventional fixed-angle devices cannot be placed and also added cost of locking plates. To decrease the risk of implant failure with locking plates, they recommended accurate fracture reduction and fixation along with judicious bone grafting, protected weight bearing, and modifications of the implant design.

In our study, functional results are close to the functional results achieved in other studies so are the rate of complications. The functional outcome was assessed according to neer's rating score and we had excellent results in 45% (n=18), good in 35% (n=14), fair in 15% (n=6) and

poor in 5% (n=2). Poor results in this study can be attributed to severe knee stiffness and operative site infection. Patients with knee stiffness can be attributed to delayed patient mobilization due to noncompliant nature of the elderly patients were subjected to vigorous physiotherapy protocol (CPM) and wax therapy and desirable knee movements were obtained.

Conclusion

Locking compression plate is a good fixation system for distal end femur fractures particularly intra-articular type that acts as an extramedullary load bearing device, helpful in stabilizing fracture fragments as well as early bony union. This has shown excellent results in majority of intra-articular distal femur fractures. The major advantage is in osteoporotic fractures, since the stability of the construct does not entirely depend on the quality of the bone. It also shows shorter postoperative stay, faster recovery, faster union rates and excellent functional outcome as compared to other alternative procedures. The locking plate-screw system produces a rigid screw-bone fixation which prevents mal rotation and aids in early return of joint functions and weight bearing thus promoting fracture healing. No implant can stabilize every fracture type, however, for best results the device chosen must provide fixation rigid enough for early mobilisation.

We conclude that this method of fixation is optimal tool for distal femur fracture with an excellent functional outcome, early clinical and radiological union, and it can be done on a routine basis with a minimum complications. It provides rigid fixation in the region of distal femur, where a widened canal, thin cortices and frequently poor bone stock makes it difficult and also less periosteal stripping and soft tissue exposure makes this a better option than that of normal plates. However, careful understanding of its basic principles and identification of appropriate fracture pattern for use of LCP are essential to avoid complications like infections, non union and delayed union.

References

1. Arneson TJ, Melton LJ, Lewallen DG *et al.* Epidemiology of diaphyseal and distal femoral fractures in Rochester, Minnesota, 1965-1984. *Clin orthop.* 1988; 234:188-94.
2. Schandelmaier P, Partenheimer A, Koenemann B *et al.* Distal femoral fractures and LISS stabilization. *Injury.* 2001; 32(3):55-63.
3. Heather V, Theresa H, John S *et al.* Failure of LCP condylar plate fixation in the distal part of the femur. *J Bone Joint Surg.* 2006; 88(A):846-53.
4. Enneking WF, Marshall Horowitz. The intraarticular effect of immobilization on the human knee. *JBJS.* 1972; 54(5):973-85,
5. Koval KJ, Hoehl JJ, Kummer FJ. Distal femoral fixation: a biomechanical comparison of the standard condylar buttress plate, a locked buttress plate and the 95-degree blade plate. *J Orthop Trauma.* 1997; 11:521-524.
6. Zlowodzki M, Cole PA, Williamson S. Biomechanical evaluation of the less invasive stabilization system, angled blade plate, and retrograde intramedullary nail for internal fixation of distal femur fractures. *J Orthop Trauma.* 2004; 18:494-502.
7. Cole PA, Zlowodzky M, Kregor PJ. Treatment of proximal tibia fractures using the less invasive stabilization system (LISS): surgical experience and early clinical results in 77 fractures. *J Orthop Trauma.* 2004; 18:528-535.

8. Collinge CA, Sanders RW. Percutaneous plating in the lower extremity. *J Am Acad Orthop Surg.* 2000; 8:211-216.
9. Frigg R, Appenzeller A, Christensen R, Frenk A, Gilbert S, Schavan R *et al.* The development of distal femur less invasive stabilization system (LISS) *Injury.* 2001; 32(Suppl 3):24-31.
10. Jazrawi LM, Kummer FJ, Simon JA *et al.* New technique for treatment of unstable distal femur fractures by locked double-plating: case report and biomechanical evaluation. *J Trauma.* 2000; 48:87-92.
11. Kregor PJ, Stannard JA, Zlowodzki M, Cole PA. Treatment of distal femur fracture using the less invasive stabilization system: surgical experience and early clinical results in 103 fractures. *J Orthop Trauma.* 2004; 18:509-520.
12. Kiran kumar GN, Sharma G, Farooque K, Sharma V. Locking compression plate in distal femoral intra articular fractures: our experience. *International scholarly research,* 2014. Article id 372916.
13. Kristensen O, Nafei A, Kjaersgaard-Andersen P, Hvid I, Jensen J. Long-term results of total condylar knee arthroplasty in rheumatoid arthritis. *J Bone Joint Surg Br.* 1992; 74:803-806.
14. Ricci WM, Loftus T, Cox C *et al.* Locked plates combined with minimally invasive insertion technique for the treatment of periprosthetic supracondylar femur fractures above a total knee arthroplasty. *J Orthop Trauma.* 2006; 20:190-196.
15. Weight M, Collinge C. Early results of the less invasive stabilization system for mechanically unstable fractures of the distal femur (AO/OTA) types A2, A3, C2, and C3). *J Orthop Trauma.* 2004; 18:503-508.
16. Miclau T, Holmes W, Martin RE, Krettek C, Schandelmaier P. Plate osteosynthesis of the distal femur: surgical techniques and results. *Journal of the Southern Orthopaedic Association.* 1998; 7(3):161-170.
17. Yeap EJ, Deepak AS, Distal Femoral Locking Compression Plate Fixation in Distal Femoral Fractures: Early Results. *Malaysian Orthopaedic Journal,* 2007; 1 (1):12-17. ISSN 1985 2533.
18. Zlowodzki M, Bhandari M, Marek DJ, Cole PA, Kregor PJ. Operative treatment of acute distal femur fractures: systematic review of 2 comparative studies and 45 case series (1989 to 2005). *J Orthop Trauma.* 2006; 20(5):366-371.
19. Vallier HA, Hennessey TA, Sontich JK, Patterson BM. Failure of LCP condylar plate fixation in the distal part of the femur. A report of six cases. *J Bone Joint Surg Am.* 2006; 88(4):846-853.