International Journal of Orthopaedics Sciences

ISSN: 2395-1958
IJOS 2017; 3(4): 920-922

www.orthopaper.com
Received: 11-08-2017
Accepted: 13-09-2017

Dr. S Hari Kumar Goud
Assistant professor, Department of Orthopaedics, MNR Medical College, Sangareddy, Telangana, India

Correspondence
Dr. S Hari Kumar Goud
Assistant professor, Department of Orthopaedics, MNR Medical College, Sangareddy, Telangana, India

Surgical treatment for un-united bony fractures by modified phemister bone grafting

Dr. S Hari Kumar Goud

DOI: https://doi.org/10.22271/ortho.2017.v3.i4m.125

Abstract
Bone grafting, a complicated surgical procedure which substitute mislaid bony particles in fractures. Delayed union and non-union of bony fractures represented with a broad spectrum of clinical significance. Modified phemister and combination of petal technique of Jarry and Uhthoff has important advantages in treating complex non-unions of long bones. This study was designed to assess modified phemister bone grafting role in delayed union and non-union of fractures of long bones. A total 30 cases with delayed and non-union of tibial shaft fractures attended the outpatient department were recruited for this study. Majority cases were in age group between 25-40 years (80%). Maximum time duration between injury and grafting was 32 weeks and minimum was 14 weeks. Duration between graft and union was 20.24 weeks, and between injury and clinical union was 41.77 weeks. The average duration to change the cast was 7.1 weeks (1st cast), 12.4 weeks (2nd cast) and 13.8 weeks (3rd cast). The success rate in this study was 93.20% and poor outcome was observed in 2 cases. To treat the fractures in long bones, modified phemister and combination of petal technique of Jarry and Uhthoff are ideal methods to treat delayed and non-union of fractures of long bones. Both the techniques are short, safer and less time consuming.

Keywords: Long bones, Bone fractures, Bone grafting, Phemister

Introduction
Bony fractures, a complicated medical problem and often a difficult issue for orthopaedic surgeons [1]. The relative frequency of various types of fractures has been materially changed since the advent of modern machinery and modern methods of warfare [1, 2].
Non-union of tibial fractures represented with a broad spectrum of clinical significance [3]. Non-union of fracture is often the results of high energy trauma with a massive loss of tissue, infection, malignance of limb and complication of complex fractures with failed primary fixation make each non-union unique [4, 5]. Multiple treatment modalities have been described for non-union and delayed union of fractures including dynamisation, percutaneous injection of bone marrow, intramedullary nailing and functional bracing [3].
Delayed union and non-union are fairly formidable problems which occurs in fractures of long bones due to many causes. It is often taught that non-union is an irreversible process in which the bone ends are joined together by mature fibrous tissues having no inherent capacity to reossify. Based on this assumption all previous attempts were made to excise the fibro cartilaginous bridge and medullary canal was opened by removing the sclerosed bone ends so that the endosteal and intermediary callus could reforms. This excision of bridge made the bone ends free and unstable, which required the need of stabilisation by some external means i.e. massive cortical graft, metal plate and screws or nails.
Modified phemister and combination of petal technique of Jarry and Uhth off has important advantages in treating complex non-unions of long bones. With the above reference the present study was designed to assess the modified bone grafting role in delayed union and non-union of fractures of long bones.

Material and methods
The present study was conducted in the Department of Orthopaedics, MNR Medical College and Hospital, Sangareddy during the period from March 2015 to December 2017.

A total 30 cases with delayed and non-union of tibial shaft fractures attended the outpatient department were recruited for this study. Each patient was subjected to thorough clinical and radiological examinations. Before starting the operative procedure all patients had necessary pathological investigations. All the patients were subjected to informed consent. The patients who were detected pre-operative anaemia, were given pre-operative haematinics proteins, anabolic steroids and appetizers. In some patient pre-operative blood transfusion was done.

Results

The present study included a total 30 cases with the complaints of delayed and non-union of tibial shaft fractures. Among the total cases 60% had simple fracture and rest 40% had complex fractures. A total 63.3% cases had fracture on right side leg whereas 36.6% had fracture on left side leg. Majority of the cases were between 25-40 years (80%) and rest between 41-60 years (20%).

Table 1: Incidence of site of fracture.

Site of fracture	No. of Cases	Percentage
Upper half	8	26.6%
Middle half	9	30%
Lower half	13	43.3%
Total	30	100%

On the radiological assessment of fractures, transverse fractures were found in 56.6% cases, short oblique fracture in 26.6% cases and oblique fractures was found in 16.6% cases. Majority of the fracture occurred due to road accidents (80%).

Table 2: Duration between injury, grafting and union of tibial fractures (Infected and uninfected cases).

Time duration (In Weeks)	Injury/graft (n=30)	Graft/union (n=29)	Injury/union (n=29)
<10	-	-	-
11-20	12	12	-
21-30	15	15	7
31-40	3	2	5
41-50	-	-	11
>51	-	-	6
Average (In weeks)	21.86	20.24	41.77

Maximum duration between injury and grafting was 32 weeks (8 Months) and minimum duration was 14 weeks. Average duration for grafting was 21.86 weeks, average duration between graft and union was 20.24 weeks and average duration between injury and union was 41.77 weeks (10.44 months). After bone grafting one patient could not attended due to personal reasons (Table 2).

Table 3: Duration between injury, grafting and union of tibial fractures (Uninfected cases).

Time duration (In Weeks)	Injury/graft (n=21)	Graft/union (n=20)	Injury/union (n=20)
<10	-	-	-
11-20	8	8	-
21-30	11	11	4
31-40	2	1	4
41-50	-	-	7
>51	-	-	5
Average (In weeks)	22.36	20.43	42.33

In uninfected cases, average duration between injury and grafting was 22.36 weeks, between grafting and union was 20.43 weeks and between injury and union was 42.33 weeks. After bone grafting one patient could not attended due to personal reasons (Table 3).

Table 4: Duration between injury, grafting and union of tibial fractures (Infected cases).

Time duration (In Weeks)	Injury/graft (n=9)	Graft/union (n=9)	Injury/union (n=9)
<10	-	-	
11-20	4	4	-
21-30	4	4	2
31-40	1	1	2
41-50	-	-	4
>51	-	-	1
Average (In weeks)	20.82	19.81	40.52

In infected cases, Duration between injury and grafting was 20.82 weeks, grafting and union was 19.81 weeks and injury and union was 40.52 weeks (Table 4). In this study, the success rate of bone grafting surgery was 86.60% (Figure 1).

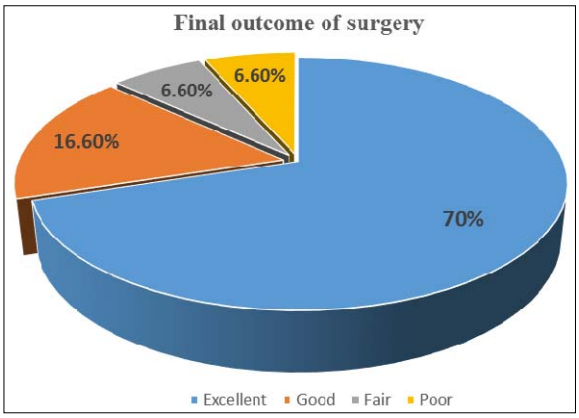

Fig 1: Assessment of final outcome of surgery.

The average time of surgical process in our series was 97.8 minutes. The average duration to change the cast was 7.1 weeks (1st cast), 12.4 weeks (2nd cast) and 13.8 weeks (3rd cast). The bridging callus could not be seen earlier due to cancellous, grafts were placed at fracture site and average time for bridging callus was 6.71 weeks.

Discussion

A total thirty cases with the complaints of delayed and non-union of tibial shaft fractures were recruited. Majority cases were in age group between 25-40 years (80%). 60% of cases had simple fractures and 40 had complex fracture. Right leg was commonly involved than left leg. In this study, Maximum duration between injury and grafting was 32 weeks (8 Months) and minimum duration was 14 weeks. In a study by Forbes DB, it was 10 years with a shortest of 11 weeks. In this study, majority cases received conservative mode of treatment (81%) followed by nailing or grafting (19%). In a study by Forbes DB, 65.4% cases were treated without knowing past treatment history. The average time of operation in our series was 97.8 minutes [6].

In present study, A/K POP cast was used for initial six weeks and started non-weight bearing ambulation with the help of crutches. The average duration to change the cast was 7.1 weeks (1st cast), 12.4 weeks (2nd cast) and 13.8 weeks (3rd cast). Phemister DB, in his study used A/K POP cast for 12 weeks and removed it after 12 weeks after bony union. Forbes

et al, in his series used A/K POP cast used for 12 weeks [7].

In this study, average duration between grafting and bony union was 20.43 weeks and 19.81 weeks in uninfected and in infected cases respectively. In a study by Sethi PK and Singhavi, it was 6 weeks and by phemister DB, it was 12 weeks. In a study by Forbes DB, the average duration was 15 weeks in clean cases and 32 weeks in infected cases [6, 7, 8]. The bridging callus could not be seen earlier due to cancellous, grafts were placed at fracture site and average time for bridging callus was 6.71 weeks.

In this study, after cast removal movements at knee and ankle joints was none but at 6th week movements were improved in >76.6% cases. In a study by phemister DB, no movements observed after cast removal, but movements were improved at 6th week [7]. Post-operative complications were not occurred in this study but superficial sepsis was found in 2 cases. Superficial and deep sepsis was noticed in phemister series. The superficial infection was either due to previous compound fracture or post operatively [6]. The success rate in this study was 93.20% and poor outcome was observed in 2 cases. In phemister series success rate was 93.8% and failure rate was 6.2%. In Forbes series and Sethi *et al*., it was found that 96% success rate and 4% failure rate.

Conclusion

The final outcome is that modified phemister and combination of petal technique of Jarry and Uhthoff are ideal methods to treat delayed and non-union of fractures of long bones. Both the techniques are short, safer and less time consuming. Early bone grafting and bone pedalling may reduce the time of bony union. Cumulatively, maximum duration between injury and grafting was 32 weeks (8 Months) and minimum duration was 14 weeks. Average duration for grafting was 21.86 weeks, average duration between graft and union was 20.24 weeks and average duration between injury and union was 41.77 weeks (10.44 months). The success rate in this study was 93.20% and poor outcome was observed in 2 cases.

References

1. Perry CR. Bone repair techniques, bone graft and bone graft 6. Substitutes. Clin Orthop Relat Res, 1999; 360:71-86.
2. Laurencin C, Khan Y, El-Amin SF. Bone graft substitutes. 1. Expert Rev Med Devices, 2006; 3:49-57.
3. Wiss DA, Stetson WB. Tibial nonunion: treatment alternatives. J Am Acad Orthop Surg. 1996; 4:249-57.
4. Marx RE. Bone and bone graft healing. 28. Oral Maxillofac Surg Clin North Am, 2007; 19:455-66.
5. Jain AK, Sinha S. Infected nonunion of the long bones. Clin Orthop, 2005; 431:57-65.
6. Forbes DB. Subcortical iliac bone grafts in fractures of tibia. JBJS, 1961; 43-B:672.
7. Phemister DB. Treatment of ununited fractures by onlay bone grafts without screw or tie fixation and without breaking down of the fibrous union. JBJS, 1947; 29:946-60.
8. Sethi PK, Singhvi. Modified Phemister bone Grafting in non-union and delayed union of fracture of long bones, instructional course lecture delivered at Annual summer Confer of Ortho Section Association of surgeons of India at Patiala, 1967, I.