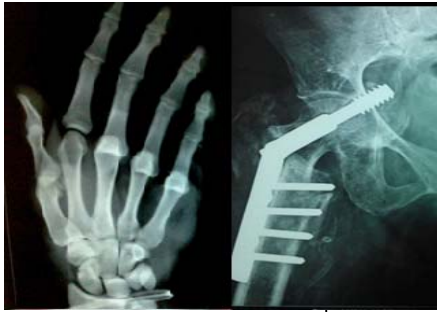



International Journal of Orthopaedics Sciences

ISSN: 2395-1958
IJOS 2017; 3(4): 912-916
© 2017 IJOS
www.orthopaper.com
Received: 06-08-2017
Accepted: 07-09-2017

Rajavel K
Assistant Professors in Medical
College, Chennai, Tamil Nadu,
India

Mahendhira varman J
Assistant Professors in Medical
College, Chennai, Tamil Nadu,
India

A prospective analysis of efficacy of fenestration discectomy in patients with symptomatic lumbar disc prolapse

Rajavel K and Mahendhira varman J

DOI: <https://doi.org/10.22271/ortho.2017.v3.i4m.123>

Abstract

Background: Aim of the study was to evaluate the efficacy of Fenestration Discectomy in symptomatic Lumbar Disc Prolapse in terms of pain relief, recovery of neurological deficit and assessing complication rates.

Material and Method: 20 cases of symptomatic lumbar disc prolapse, not responding to conservative measures for 6 weeks were treated with fenestration discectomy and followed for a period of 2 and a half years from June 2014 to dec 2016.

Result: Out of 20 cases, overall results include best result in 16, good in 2, fair in 1 and poor in 1. Spinal movements improved in 16 cases, worsened in 1 and remained same in 3 cases. SLR improved in 19 cases and remained same in 1 case. Out of 8 patients with neurological deficit, 6 recovered and 2 remained the same. Complications like dural tear occurred in 2 cases, EHL weakness occurred in 1 case and infection occurred in 1 case.

Conclusion: 80 % of cases had best results, 10% had good results, 5% fair result and 5% poor result. Success of surgery depends on selection of patients, correct identification of level intra operatively and avoiding complications.

Keywords: fenestration, disc prolapse, SLR, EHL

Introduction

Back pain ranks second only to upper respiratory illness as a symptomatic reason for office visits to physicians. 70 % of population have low back pain at some part of life. Most causes of backpain responds to conservative measures, some are surgically remediable and some are systemic diseases requiring specific therapy, so careful diagnostic evaluation is important.

First clinical description of disc pathology was by Virchow in 1857. SLR was described by Frost but attributed to Lasegue, his teacher in 1881. Siccard in 1921 observed that lumbar nerve roots could be compressed by ruptured disc and confirmed by myelography using poppy seed oil. Robert Williams was the first to introduce microsurgical discectomy in 1978. Choy introduced laser disc surgery in 1987^[1].

Classical intervertebral disc prolapse presents as back pain radiating to one lower limb with nerve root tension signs, with or without neurological deficit. MRI is the preferred imaging modality. Most cases of symptomatic disc prolapse responds to conservative measures like analgesics, muscle relaxants and physiotherapy in the form of interferential therapy and pelvic traction^[2]. Specific indications for surgery includes failure of conservative measures for 6 weeks, neurological deficit and cauda equine syndrome. Surgeries available includes laminectomy and discectomy, fenestration discectomy, endoscopic surgeries and laser assisted discectomy^[3].

Materials and methods

This study has been made with the prospective analysis of 20 cases of symptomatic lumbar disc prolapse, not responding to conservative measures for 6 weeks, being treated by fenestration discectomy. They were followed for a period of 2 ½ years from 2014 to 2016. Back pain, radiating leg pain, functional endurance and neurological features were the main aspects analyzed.

Correspondence
Mahendhira varman J
Assistant Professors in Medical
College, Chennai, Tamil Nadu,
India

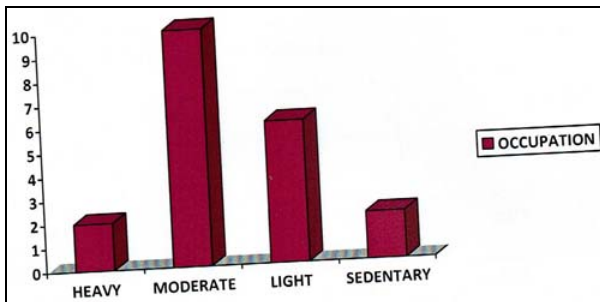
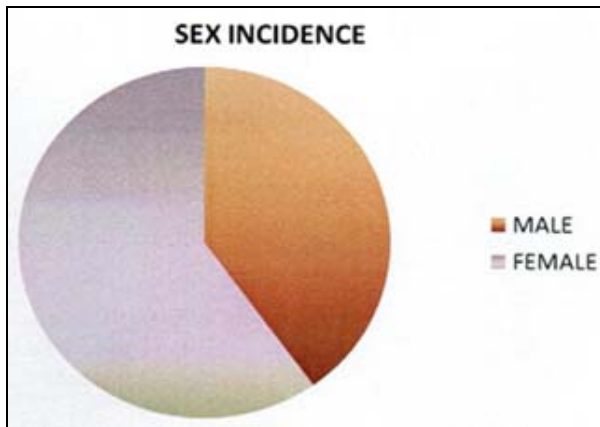
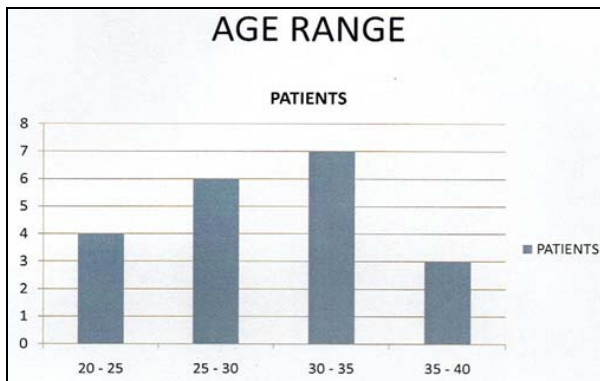
An objective evaluation regarding spinal movements, local tenderness, sciatic scoliosis, SLR, and neurological signs also recorded [4].

Inclusion criteria

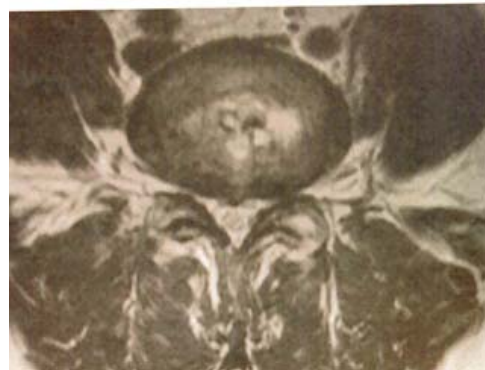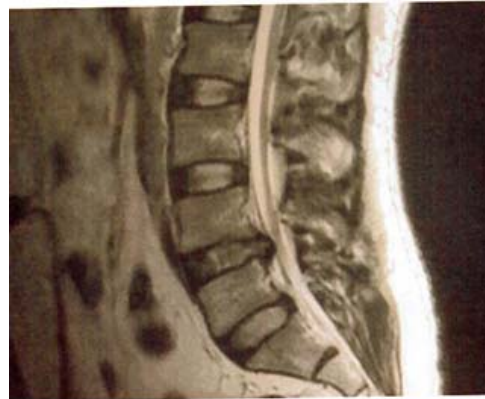- Age between 20 – 45 years.
- Single level Disc
- Unilateral Disc
- With or without Neurological Deficit
- Those patients, who are subjected to 6 weeks of non-operative management, but symptoms being not relieved.

Exclusion criteria

- Age less than 20, more than 45 years.
- Multilevel disc
- Central Disc
- Cauda equine syndrome
- Those patients who underwent less than 6 weeks of non operative measures.
- Failed Back syndrome.
- Spinal instability.

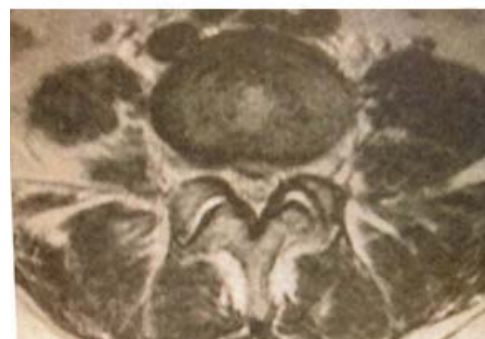
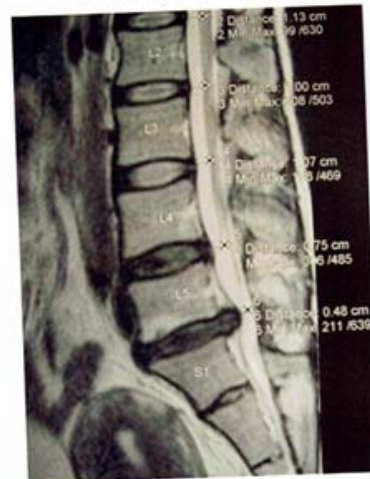

CASE 2
L4 - L5 DISC PROLAPSE



The diagnosis confirmed by clear history, physical examination and imaging modalities. All the patients were subjected to MRI [5, 6, 7].

CASE 11
L5 - S1 DISC PROLAPSE



The results were grouped into four categories according to the relief of pain, working ability and clinical signs.

Procedure

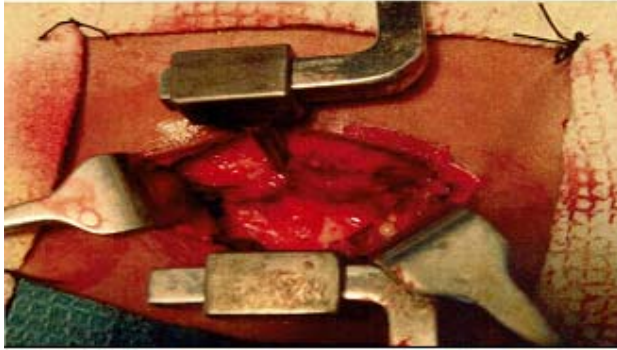
All 20 cases were done under general endotracheal anaesthesia. Prone position with pillows under chest and pelvis were used with particular care not to compress the abdomen.

The operative field was routinely infiltrated with adrenaline saline solution to minimize bleeding. Always the level was

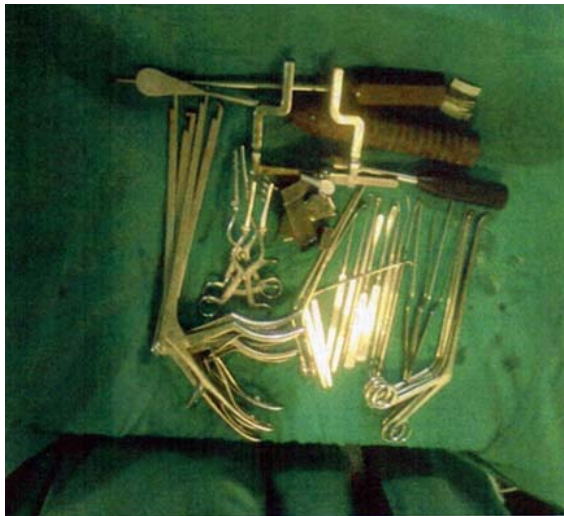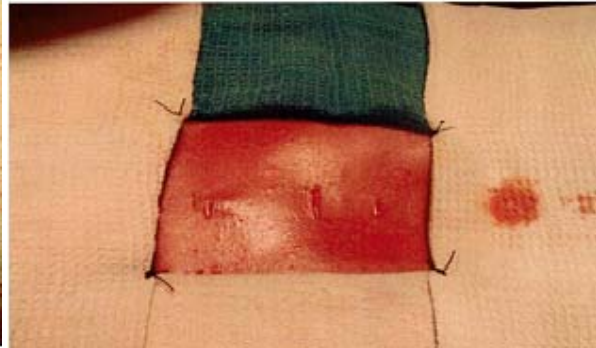
confirmed under image intensifier. Some piece of bone from superior Lamina removed in selected cases, based on the availability of working space.

- Most of the lamina and faced joints were left undisturbed.
- Bipolar electrocautery was used to coagulate the bleeding epidural vessels.
- Use of cotton patties were kept to a minimum.
- Far lateral disc noted in the MRI was excised by angled disc punch in reverse direction [8, 9].

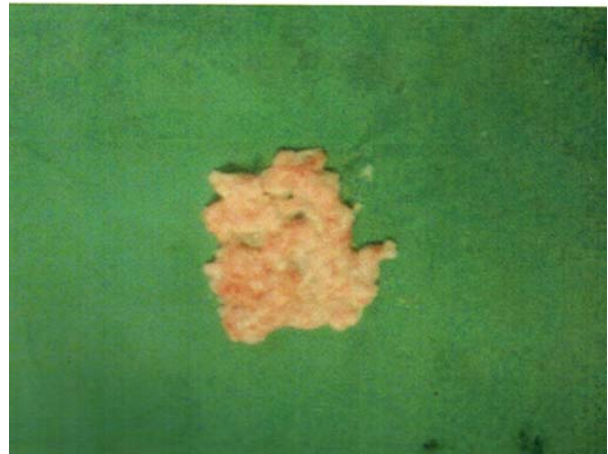
AFTER RETRACTION



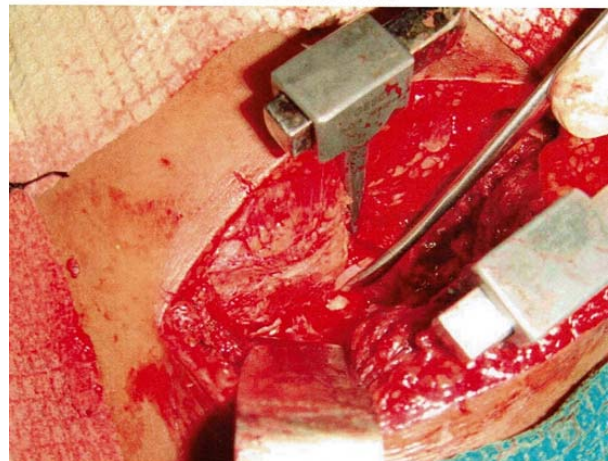PROCEDURE SKIN INCISION



DISC MATERIAL



GLISTENING DISC



Post Operative Protocol

- Patients were mobilized on the day of surgery upto pain tolerance.
- Neurological status assessed.
- One dose of pre-operative antibiotic and 5 day course of post-operative antibiotics used.
- Pain relief assessed by visual analog scale.
- Post operative counseling given to all the patients regarding good posture, body mechanics, spinal extension exercises, Back muscle strengthening exercises, avoiding lifting heavy weight, bending for 3 weeks, ergonomics, lifestyle changes, change of job in heavy manual laborer, return to sports in sports persons.

Follow up

All the patients were followed up for a period of two and a half years.

Results

The efficacy of the treatment was assessed by the following criteria.

1. Pain relief by visual analog scale and comparison with preoperative values.
2. Recovery or worsening of neurological deficits.
3. Post operative straight leg raising test
4. Post operative complications like infection, CSF fistula, new neurologic deficit.

Pain

Results	Number of patients
Best	16
Good	2
Fair	1
Poor	1

Improvement in clinical signs

1. Spinal movements

Spinal movement	Number of patients
Improved	16
Worsened	1
Same	3

2. SLR [Straight leg raising test]

SLR	Number of patients
Improved	19
Same	1

3. Neurological signs

Neurological signs	Number of patients [out of 8 patients]
Improved	6
Same	2
Worsened	0

4. Recurrence of symptoms

Symptoms	Number of patients
Radiating pain	2
Neurological deficit	0

Overall results

Complications

- One case converted into laminectomy and discectomy due to profuse bleeding from the epidural veins not controlled by electro cautery [10,11].

Conclusion

Fenestration Discectomy is an excellent cheap procedure, which can be done on outpatient basis. The key to good results in disc surgery is appropriate patient selection. The optimal patient is one with predominant unilateral leg pain, extending below the knee that has been present for atleast 6 weeks despite conservative measures.

The operated patients had less postoperative pain due to the minimal soft tissue exposure, minimal handling of paraspinal muscles on one side only, less or no damage to lamina, no damage to facet joints [12, 13, 14]. All the patients required less dose of postoperative analgesics.

Postoperative mobilization is very earlier compared to laminectomy and discectomy. All the patients were mobilized on the day of surgery. Patients are allowed to return to their work after 3 weeks in jobs that does not require lifting, after 6 weeks in jobs that require prolonged sitting and 8 weeks for heavy labor.

All the patients had less postoperative morbidity. Problems associated with prolonged bed rest like bed sores, deep vein thrombosis, lung and urinary tract infections, hypocalcemia are not encountered.

80% of patients had best results, 10% good results, 5% fair result and 5% poor result. The success of surgery depends on selection of the patient and correct identification of the level and avoiding complications.

References

1. Saal JA. Natural history and nonoperative treatment of lumbar disc herniation, Spine. 1996; 21(24):2S-9S.
2. Weinstein JN, Lurie JD, Tosteson TD, Skinner JS, Hanscom B, Tosteson AN *et al.* Surgical vs nonoperative treatment for lumbar disk herniation: the Spine Patient Outcomes Research Trial (SPORT) observational cohort. JAMA. 2006; 22;296(20):2451-9. [Medline]. [Full Text].
3. Hahne AJ, Ford JJ, McMeeken JM. Conservative management of lumbar disc herniation with associated radiculopathy: a systematic review. Spine (Phila Pa 1976). 2010; 15;35(11):E488-504. [Medline].
4. Waddell G, Somerville D, Henderson I, Newton M. Objective clinical evaluation of physical impairment in chronic low back pain. Spine. 1992; 17:617-28.
5. Bell GR, Ross JS. Diagnosis of nerve root compression. Myelography, computed tomography, and MRI. OrthopClin North Am. 1992; 23:405-19.
6. Boden SD, Wiesel SW. Lumbar spine imaging: role in clinical decision making. J Am Acad Orthop Surg. 1996; 4:238-48.
7. Haughton VM. MR imaging of the spine. Radiology, 1988; 166:297-301.
8. Hood RS. Far lateral lumbar disc herniations. Neurosurg Clin N Am. 1993; 4:117-124.
9. Jiang W, Sun B, Sheng Q, Song X, Zheng Y, Wang L. Feasibility and efficacy of percutaneous lateral lumbar discectomy in the treatment of patients with lumbar disc herniation: a preliminary experience. Biomed Res Int. 2015, 378612. [Medline].
10. Bell G. Complications of lumbar spine surgery. Wiesel S, Weinstein J. The Lumbar Spine. 2nd. Philadelphia: WB Saunders, 1996.
11. Bernsmann K, Kraemer SA. Clinical results and

- complication rate in lumbar microdisc surgery depending on surgeon's experience. A comparative study. ISSLS Abstracts. 1998, 197.
12. Gibson JN, Grant IC, Waddell G. Surgery for lumbar disc prolapse. Cochrane Database Syst Rev. 2000. CD001350. [Medline].
 13. Gotfryd A, Avanzi O. A systematic review of randomised clinical trials using posterior discectomy to treat lumbar disc herniations. Int Orthop. 2009; 33(1):11-7. [Medline].
 14. Evaniew N, Khan M, Drew B, Kwok D, Bhandari M, Ghert M. Minimally invasive versus open surgery for cervical and lumbar discectomy: a systematic review and meta-analysis. CMAJ Open. 2014; 2(4):E295-305. [Medline].