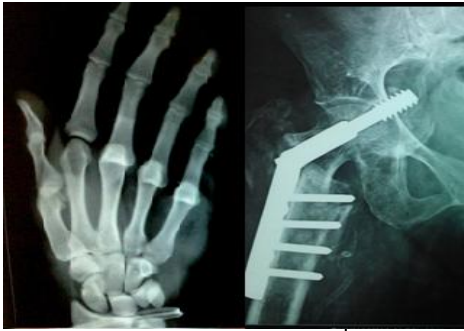

International Journal of Orthopaedics Sciences

ISSN: 2395-1958
IJOS 2017; 3(4): 746-751
© 2017 IJOS
www.orthopaper.com
Received: 12-08-2017
Accepted: 13-09-2017

Dembélé B
Orthopedic and Trauma Unit,
Aristide Dantec University Hospital,
Dakar - Senegal, West Africa

Coulibaly NF
Orthopedic and Trauma Unit,
Aristide Dantec University Hospital,
Dakar - Senegal, West Africa

Diouf AB
Orthopedic and Trauma Unit,
Aristide Dantec University Hospital,
Dakar - Senegal, West Africa

Dia R
Orthopedic and Trauma Unit,
Aristide Dantec University Hospital,
Dakar - Senegal, West Africa

Sarr L
Orthopedic and Trauma Unit,
Aristide Dantec University Hospital,
Dakar - Senegal, West Africa

Daffé M
Orthopedic and Trauma Unit,
Aristide Dantec University Hospital,
Dakar - Senegal, West Africa

Gueye AB
Orthopedic and Trauma Unit,
Aristide Dantec University Hospital,
Dakar - Senegal, West Africa

Ngoussi I
Orthopedic and Trauma Unit,
Aristide Dantec University Hospital,
Dakar - Senegal, West Africa

Sidibé M
Orthopedic and Trauma Unit,
Aristide Dantec University Hospital,
Dakar - Senegal, West Africa

Sané AD
Orthopedic and Trauma Unit,
Aristide Dantec University Hospital,
Dakar - Senegal, West Africa

Diémé CB
Orthopedic and Trauma Unit,
Aristide Dantec University Hospital,
Dakar - Senegal, West Africa

Correspondence
Dr Badara Dembélé
Orthopedic and Trauma Unit,
Aristide Dantec University Hospital,
Dakar - Senegal, West Africa

Tuberculous osteoarthritis of the wrist about three observations and review of the literature

Dembélé B, Coulibaly NF, Diouf AB, Dia R, Sarr L, Daffé M, Gueye AB, Ngoussi I, Sidibé M, Sané AD and Diémé CB

DOI: <https://doi.org/10.22271/ortho.2017.v3.i4k.102>

Abstract

Objectives: To determine the therapeutic modalities and to specify the evolution of the treatment of osteo-articular tuberculosis of the wrist.

Introduction: Osteoarticular tuberculosis is rare 3 to 5% of all localizations by BK. Their diagnosis is often late.

Patients and methods: This was a retrospective study continued from January 2010 to November 2017. 3 patients, 2 men and 1 woman aged 39.66 years (range 19 to 65 years) were involved. The average consultation time was 17 months (range 3 to 24 months). For both patients, it was isolated osteoarthritis of the wrist and for the 3rd, it was associated with another location. Two patients presented a concept of tuberculous contagion and the other a pulmonary tuberculosis associated with Pott's disease. The function was evaluated according to the Mayo Wrist score and the winding of the fingers.

Results: The treatment consisted of debridement in all cases. In all our patients the pathological examination found an epitio-gigantocellular granuloma with caseous necrosis. Anti-tuberculosis chemotherapy was instituted in all patients for a period of 6 months (n = 2, one of which is still in treatment), 9 months (n = 1). At the average follow-up of 5 years in the 2 (extremes 2 and 8 years), we did not observe a recurrence. The function was good the 2 cases that finished their treatment with a complete winding of the fingers.

Conclusion: Treatment is based on debridement and antituberculous chemotherapy. Applied early, it provides excellent results.

Keywords: Osteoarthritis, tuberculosis, wrist, caseous necrosis

Introduction

Osteoarticular tuberculosis (TOA) is defined as all bone, joint and abarticular disorders, caused mainly by Mycobacterium tuberculosis (Bacillus koch) [10].

Tuberculosis has been resurgent in developed countries since the advent of human immunodeficiency virus (HIV) infection. It is one of the most feared diseases in underdeveloped and developing countries where it poses a real public health problem [3].

Osteoarticular tuberculosis represents 3 to 5% of all BK infection localizations.

Its chronic and insidious evolution, long supported by the patients explains the delays of consultation. On the other hand, this unusual presentation, often overlooked, causes the diagnosis to wander and is associated with a therapeutic delay. The erroneous prescription of corticosteroids with deleterious effects aggravates the tuberculous process [5].

The diagnosis is based on bacteriology by the detection of the bacillus of koch and / or histology [8, 13]. The treatment is medico-surgical and is based on antituberculous chemotherapy and debridement for diagnostic and therapeutic purposes [6]. Here we report 3 cases of patients with tuberculous osteoarthritis of the wrist.

Patients and method

This was a continuous retrospective study from January 2010 to November 2017 that concerned all patients received and treated with tuberculous osteoarthritis of the wrist. There were 3 of them, including 2 men and 1 woman, aged 35, 65 and 19 respectively. They were all immunocompetent with a notion of vaccination in childhood.

Observation n °1

Mr A.B, age 35, right-handed with a history of pulmonary tuberculosis treated in the same year, presented two years after a painful swelling of the right wrist without fistulization with stiffness. The clinical examination found a renal swelling on the dorsal surface of the right wrist with pain on palpation. The mobilization of the wrist was painful and limited. The presence of axillary adenopathies was noted.

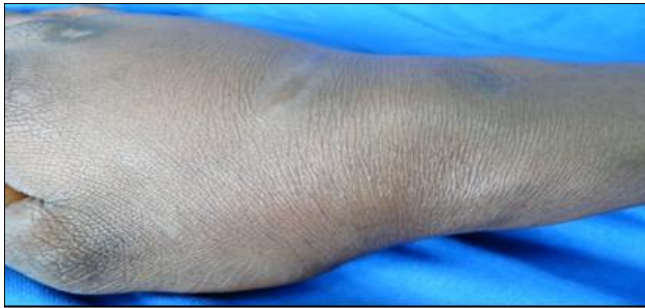

Fig 1: Clinical appearance of the wrist showing dorsal swelling.

The radiograph showed Martini stage III osteoarthritis [30] with geodes and bone erosion.

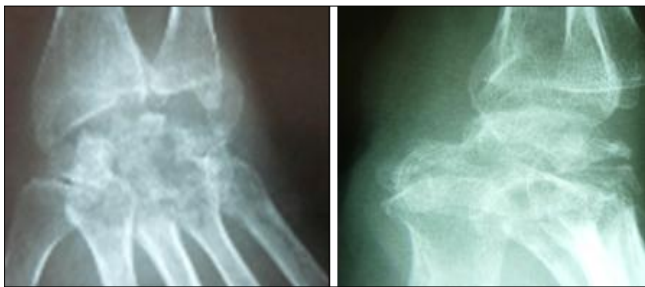

Fig 2: Radiograph of the wrist of face and profile showing osteolytic lesions of carp and the distal end of the radius.

The intradermal reaction to tuberculin was positive at 20 mm; AFB sputum was positive.

A synovial and bone biopsy associated with joint lavage was performed.

Bacteriological examination did not isolate germ.

Anatomopathological examination revealed a tuberculoid granuloma with caseous necrosis.

An anti-bacillary treatment made of four molecules including ERHZ at the initial phase for 2 months followed by a dual HR therapy for 7 months for a total duration of 9 months was instituted and performed.

The evolution was marked by healing with a persistence of stiffness that required functional rehabilitation. After a 7-year follow-up we did not observe a recurrence, the wrist mobility was 50 ° in flexion and 75 ° in extension. The winding of the fingers was complete with a muscle strength at 24 against 56 for the healthy side. The Mayo score was good at 80 points.

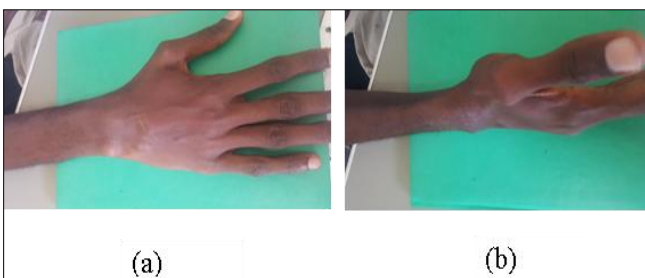

Fig 3: Appearance of the wrist (a) and profile (b).

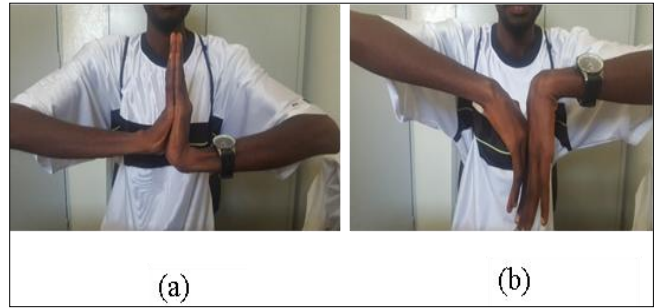


Fig 4: Wrist mobility in extension (a) and flexion (b).

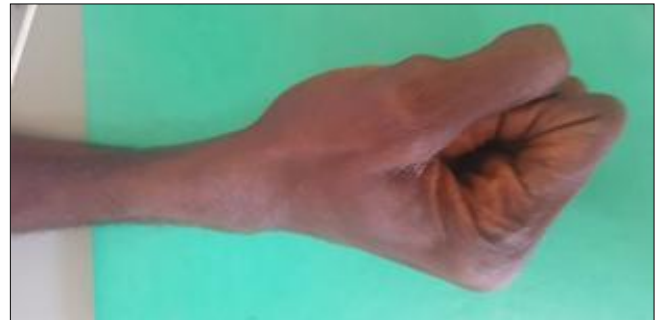

Fig 5: Complete flexion of the fingers.

Observation n ° 2

Mr A. F 65 years old, right-hand man consulted for a painful swelling of the left wrist and lumbar spine pain that had been evolving for more than two years. In his antecedents there was a notion of tuberculous contagion.

The clinical examination found a painful and swollen wrist on the dorso-medial face, fluctuating on palpation, the mobilization of the wrist was almost impossible and painful. The last three fingers were painful to the mobilization against the others were free. On examination of the spine, there was pain on palpation of the L4 and L5 spinal cord, a contracture of the para-vertebral muscles. He also had inguinal lymphadenopathy. There were no neurological disorders and his general condition was bad.

In front of this table a balance sheet was asked in particular: the chest x-ray which was normal. The radiograph of the wrist showed osteolysis with significant destruction of the radiocarpal joint and the ulnar stage IV stage according to Martini [30].

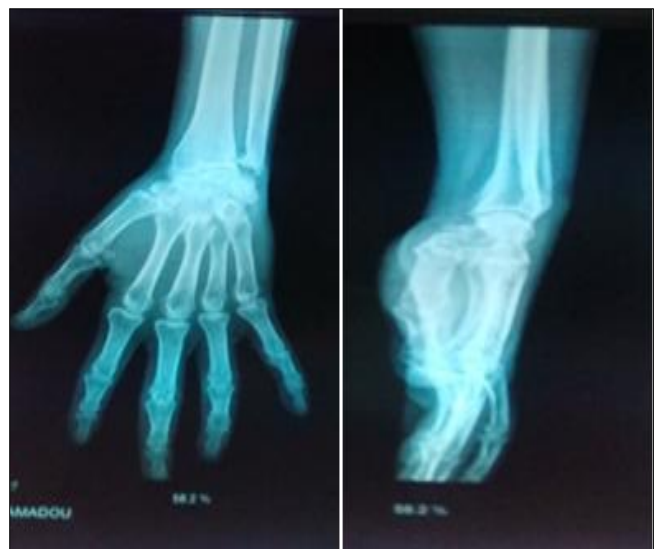

Fig 6: Radiograph of the wrist of face and profile showing joint destruction with osteolysis of stage IV carp.

The radiograph of the lumbar spine showed straightness of the spine with a pinch of the disc L4, L5 without lytic image. On the other hand, there was the presence of geodes on the vertebral bodies. He had no par vertebral abscess.

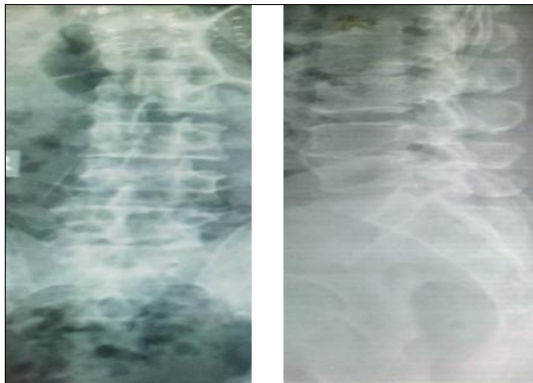

Fig 7: Radiograph of the lumbar spine showing rectitude of the lumbar spine with spondylodiscitis between L4 and L5.

The intradermal reaction to tuberculin was positive at 18 mm as well as sputum bacillus.

A biopsy of the synovial membrane was performed on the right wrist and the suites were simple.

The bacteriological examination showed the bacillus of koch in culture.

An anti bacillary quadritherapy for 2 months based on ERHZ at the initial phase followed by a dual therapy made of HR for 4 months for a total duration of 6 months was performed.

The evolution was marked by healing with persistent wrist stiffness, despite functional rehabilitation sessions. The Mayo wrist score was 65 points equivalent to an average score with full finger roll.

After a decline of 5 years the force was 18 against 40 for the right side. His lumbar spine was painless with distance hand preserved soil.

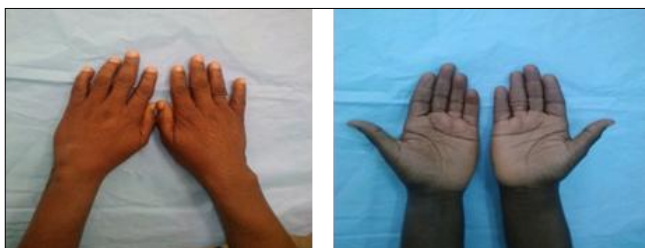

Fig 8: Prono-supination possible after 5 years

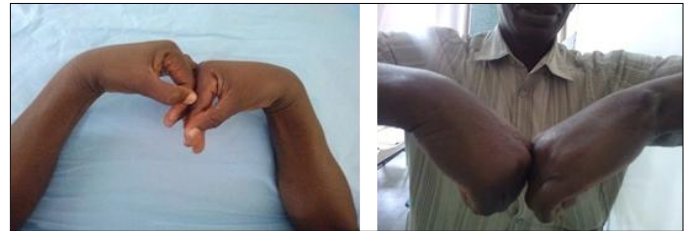

Fig 9: Stiffness of the left wrist flexion after rehabilitation

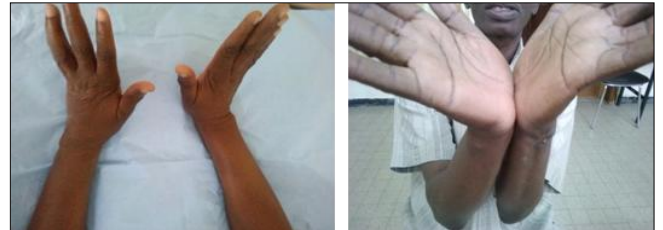

Fig 10: Incomplete extension of the left wrist

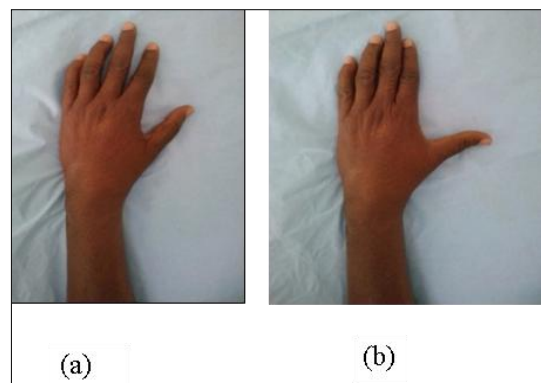


Fig 11: (a) = The possible radial inclination (b) = The ulnar inclination is null.

Observation n ° 3

M-T, aged 19, is a right-handed student with no reported TB history. He had consulted for a tumefaction of the dorsal surface of the right wrist evolving since 3months. She had brought back a notion of vespero-nocturnal cough before. The clinical examination found an inflammatory swelling of the wrist with limitation of the mobility of the wrist which is painful. He had no axillary lymphadenopathy. The radiograph of the wrist showed a narrowing of the joint space, demineralization with significant bone lysis of carp bones and distal radioulnar dislocation associated with ankylosis (Martini type III). That of the lungs was normal.

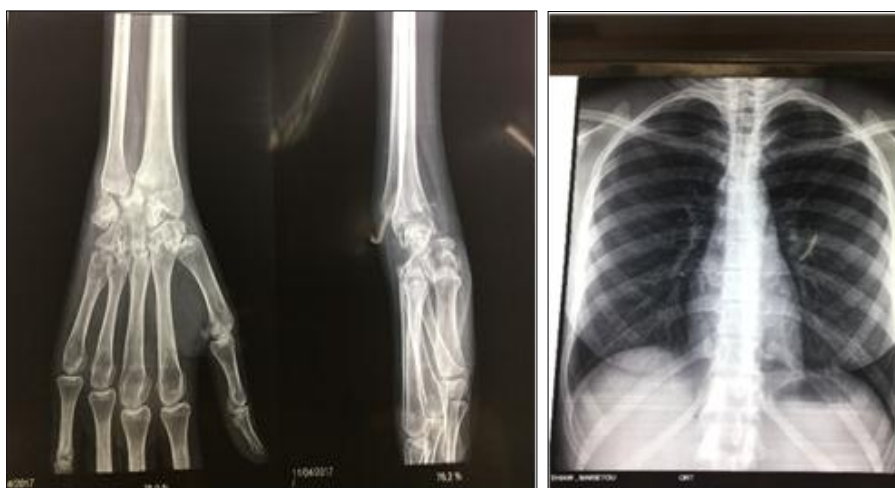

Fig 12: Standard radiograph of wrist and lung.

Tuberculin intradermal reaction was positive at 20 mm with presence of a fluctuating reaction on the anterior aspect of the forearm.

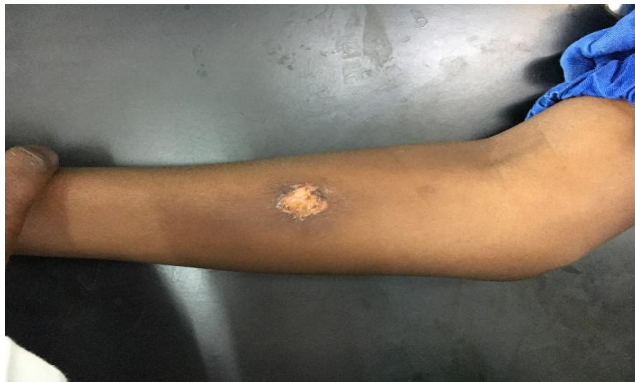

Fig 13: Clinical appearance showing a fluctuating image of the IDRT.

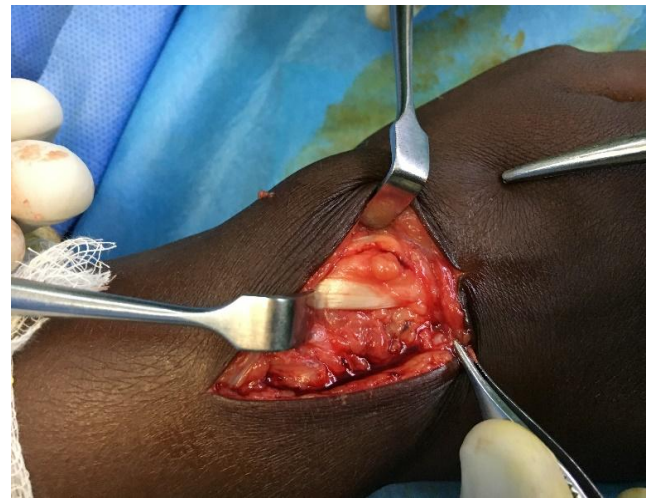


Fig 14: The appearance of synovial joint wrist.

A synovectomy with synovial biopsy was performed on the dorsal aspect of the wrist and the operative follow-up was simple.

Pathological examination revealed granulomatous tenosynovitis of tuberculous origin.

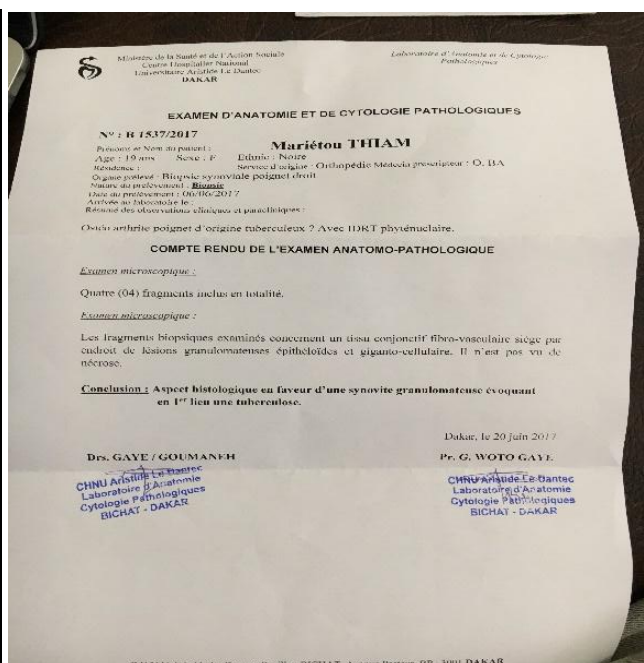
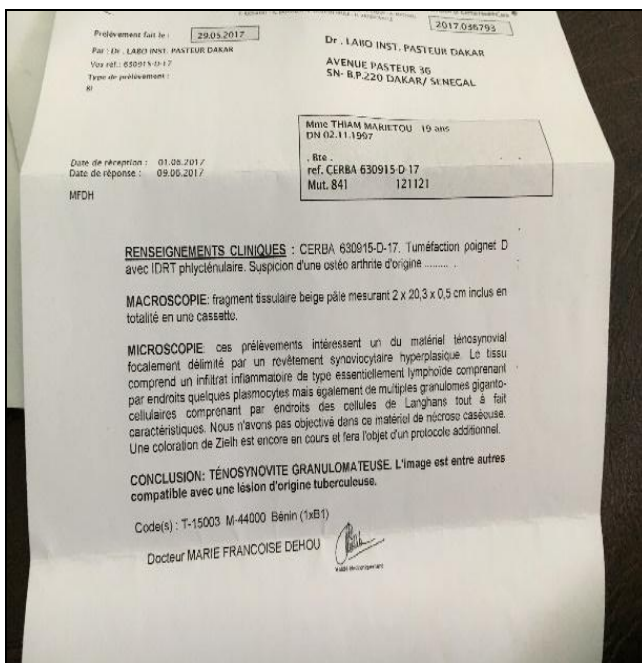


Fig 15: Pathologic findings of the biopsy patch.

A triple antiretroviral therapy was done based on RHZE during the initial phase for a duration of 02 months followed by a maintenance treatment done of RH during 04 months which is outstanding, all for a total duration of 6months. The evolution under treatment is marked by a limitation of articular mobility of the wrist without touching fingers. A functional rehabilitation will be undertaken after 6 months of treatment to allow to find a complete passive mobility.

Discussion

Osteoarticular tuberculosis is rare 3 to 5% of all localizations of BK infection [9] and 15% of extra-pulmonary tuberculosis. It predominates in the spine and the supporting joints [15]. In our study, wrist localization was studied like other authors [11, 13].

The average duration of consultation of our patients was 17 months with extremes of 3 months and 24 months of evolution of the disease. Osteoarticular tuberculosis is marked

by an insidious, progressive onset and swelling becomes evident after several months.

The tolerance of the disease is remarkable. Often the symptoms are so minor that the patient waits a long time before taking a medical opinion. The clinician, meanwhile, rarely evokes the diagnosis of tuberculosis in the face of chronic osteoarthritis of the wrist. This table is most often confused with a rheumatic pathology for which a corticotherapy could be instituted [4], this is not found in our patients. These practices make the evolution faster to complications.

The diagnosis of osteo-articular tuberculosis is based on presumptive arguments, the field, the notion of tuberculous contusion for which we have recorded 1 case. The intra dermal reaction to tuberculin was positive in all of our patients.

We did not find a direct mode of inoculation in our patients by sting.

This infection can be promoted by trauma in 30% of cases [10]. The mode of inoculation is mainly by hematogenous dissemination from a site of pleuropulmonary or urogenital tuberculosis [7]. In our study a patient had a history of treated pleuropulmonary tuberculosis, one had a notion of contagion. Other etiological factors are forced labor, corticosteroid infiltration [16], immunodepression (HIV infection and long-term corticosteroid therapy); these were not found in this study.

Clinically, the local inflammatory signs are discrete, as is the case in our study. The mobility of the wrist becomes limited. One of our patients had a lesion in pre-fistulization. An unobserved carpal tunnel syndrome in our patients can be seen in palm-shaped forms at the wrist [13].

In biology, there is often an inflammatory syndrome. The sedimentation rate is a very evocative but nonspecific element, it is in rule superior to 20 mm at the second hour. In our 3 patients this examination returned normal. The blood count is generally normal, but may sometimes show leukocytosis, as in the Jaraa series [9]. In our study we did not record any cases of leukocytosis.

Ultrasound can highlight an abscessed fluid collection [13]. Ultrasound is also useful for performing an echo-guided puncture with a PCR study of the fluid removed thus avoiding the need for surgery [13]. In our study we did not perform a puncture.

MRI is certainly the most useful and sensitive examination [13]. This examination was not carried out in our study for lack of means in our patients.

All these elements contribute to the presumptive diagnosis, but the diagnosis of certainty calls for the detection of *Bacillus Koch* in bacteriological sampling fluid and / or histological evidence.

We recorded a case of positivity to bacteriology. Bacteriological evidence is present in direct examination only in 20% of cases and cultures are negative in 35 to 45% of cases [1, 11]. In fact, the bacterial density is lower in the synovial fluid than in the tendinous or synovial tissues [1]. This pauci-bacillary nature of infection explains the large number of false negatives in bacteriology.

The methods of gene amplification (PCR) from articular fluid are more sensitive and allow a rapid and specific detection of BK [11]. The absence of BK in cultures can not and should not invalidate the diagnosis. The contribution of Genexpert revolutionized, because of its very high specificity (about 97 - 100%) the diagnosis of tuberculosis [14]. During the study period, this test although appearing in the panel of paraclinical exams existing in Senegal.

Was not asked in our patients. It is currently one of the most requested exams in etiological research in front of a table of tuberculous suspicion.

Regarding the histological study, we observed all the stages found in Kanavel *et al* [11].

All our patients had histological confirmation with the presence of gigantocellular granuloma with caseous necrosis. The treatment is medico-surgical based on the use of antituberculous drugs based on four molecules: rifampicin, isoniazid, pyrazinamide and ethambutol. All our patients had antituberculous chemotherapy after surgery. The latter is most often extensive aiming at complete debridement.

We call this process minimally invasive since the approach was 2 cm. After 2 years and a half, no recurrence was noted. We believe that in the absence of signs of tendon rupture or compressive syndrome, this treatment may be considered. It reduces the functional sequelae due to the risks of adhesion. It

is also aesthetic, because it avoids long incisions for the purpose of expanded debridement. However, given the rarity of this condition, our sample and follow-up are insufficient. We can not be formal in our proposals. It is necessary for us to continue this long-term study to analyze possible risks of recurrence related to this new procedure.

The most recent US guidelines report that rifampicin-treated osteoarticular treatment with a duration of 6 to 9 months was as effective as non-rifampicin treatment with a duration of 18 months [2]. In our patients the duration of the treatment varied between 6 to 9 months. The evolution was favorable with a minimum follow-up of 2.5 years for the last patient. However 2 cases of wrist stiffness were observed despite the functional rehabilitation sessions. These stiffnesses are due to the importance of joint destruction at the time of care. However, the function of the hand was excellent in all. There are, however, cases where there is a residual flexion or extension of the joints, sometimes with a decrease in muscle strength. The risk of recurrent osteoarticular tuberculosis is important and requires long-term monitoring [1]. No patients were seen for a possible recurrence.

Conclusion

Osteoarthritis of the wrist represents a rare localization of tuberculosis. It usually occurs on immunocompromised soil but may also occur in immunocompetent individuals. The treatment is mixed both surgical and medical. The evolution under treatment was towards healing in all our patients with a total functional recovery in 2 patients. It is necessary for this purpose to carry out an early diagnosis which makes it possible to start a treatment as soon as possible in order to avoid complications such as joint damage.

References

1. Aboudola S, Sienko A, Carey RB, Johnson S. Tuberculous tenosynovitis. *Hum Pathol.* 2004; 35(8):1044-6.
2. Alexandre Le Meur, Cedric Arvieux, Michel Cormier.
3. Tenosynovitis of the Wrist Due to Resistant *Mycobacterium tuberculosis* in a Heart Transplant Patient. *Journal of clinical microbiology.* 2005; (1):988-90.
4. Astudillo L, Garrousteb C, Chabrolc A, Saillerd L. La ténosynovite tuberculeuse: une présentation actuellement rare de la tuberculose. *La Revue de Médecine Interne.* 2007; 28:83-160.
5. Burnes P, Bloch AB, Davidson PT. Tuberculosis in patients with human immunodeficiency virus infection. *N Eng J Med.* 1991; 324:1644-50.
6. David Chausse J, Dehais J, Buller R, Chabelard JP. Les ostéo-arthrites et synovites tuberculeuses à foyers multiples. A propos de 10 cas observations. *Bordeaux Mezd.* 1978; 11:1191-6.
7. Fellander M. Tuberculous tenosynovitis of the hand treated by combined surgery and chemotherapy. *Acta chirurgica scandinavica.* 1956; 11:142-50.
8. Gester. Affections des gaines synoviales. *Encyclopédie Médicale Chir Appareil locomoteur.* 1987; 15153:A10, 9:8.
9. Gooding GAW. Tenosynovitis of the wrist. A sonographic demonstration. *J Ultrasond Med.* 1988; 7:225-6.
10. Jaraa M, Qacifa H, Sekkacha Y, El Qatnia M, Elouennassb M, Ghafira. Ténosynovite tuberculeuse: une localisation rare. *La Revue de médecine interne.* 2007;

28: 56-8.

11. Jones KE, Mc Lauchlan CAJ. Unusual presentation of tuberculosis to the accident and emergency department. *Journal of accident and emergency medicine*. 1995; 12:149-50.
12. Kanavel AB. Tuberculous tenosynovitis of the hand: a report of 14 cases. *Surgery, gynecology and obstetrics*, 1923; 37:635-47.
13. Leader M, Revell P, Clarke G. Synovial infection with *Mycobacterium kansasii*. *Annals of the Rheumatism Diseases*. 1984; 43:80-82.
14. Miquel A, Froug C, Adrien C, Bittoun J. Ténosynovite tuberculeuse du poignet: diagnostic échographique et apport de L'IRM.
15. Chang. Rapid and effective diagnosis of tuberculosis and rifampicin resistance with Expert MTB/RIF assay: a meta-analysis. *Journal of infection*. 2012; 64(6):580-588.
16. Pertuiset E. Tuberculose osseuse et articulaire des membres. *EMC-Rhumatologie Orthopédie*. 2004; 1:463-86.
17. Wolfe JN. Xeroradiography of the bones, joints and soft tissues. *Radiology*. 1969; 93:583.