



International Journal of Orthopaedics Sciences

ISSN: 2395-1958
IJOS 2017; 3(4): 669-674
© 2017 IJOS
www.orthopaper.com
Received: 04-08-2017
Accepted: 05-09-2017

Dr. Ramprasath DR
Associate Professor, Department
of Orthopaedic Surgery,
Government Coimbatore Medical
college Hospital, Coimbatore,
Tamil Nadu, India

Dr. Thirunarayanan V
Associate Professor,
Department of Orthopaedic
Surgery, Government
Dharmapuri Medical college
Hospital, Dharmapuri, Tamil
Nadu, India

Dr. Basheer Ahmed S
Resident, Department of
Orthopaedic surgery,
Government Royapettah
Hospital, Chennai-14, Tamil
Nadu, India

Percutaneous screw fixation for sacral & sacro iliac joint injuries: Case series

Dr. Ramprasath D R, Dr. Thirunarayanan V and Dr. Basheer Ahmed S

DOI: <https://doi.org/10.22271/ortho.2017.v3.i4j.92>

Abstract

Introduction: Management of poly trauma patients with pelvic ring injuries is a challenging situation where mobilization is a goal for early rehabilitation. Sacral fractures and sacroiliac joint injuries need to be addressed in these patients for starting early mobilization and rehabilitation and to achieve successful outcome.

Materials and methods: A prospective study was conducted in our department involving 11 patients who were admitted following poly trauma with associated sacral and sacroiliac joint injuries. Denis & Weber classification for sacral fractures, and Tile/ Young and Burgess Classification for SI joint disruption were used. We have performed percutaneous iliosacral screw fixation and achieved good functional outcome in these patients.

Discussion: Thorough knowledge about anatomy of lumbopelvic junction and special radiographic views is mandatory. Prior reduction of the injuries involving sacrum and sacroiliac joint is mandatory before percutaneous fixation. Preoperative evaluation regarding neurological status and sacral dysplasia is the key for a successful outcome.

Conclusion: With clearcut indications and contraindications, percutaneous iliosacral screw fixation appears to be one of the best techniques to achieve good fixation and early rehabilitation

Keywords: Iliac cortical density, Pelvic fractures, Percutaneous screw, Sacroiliac joint, Sacrum

Introduction

Newer advances in the emergency services and trauma care have increased the survival of poly trauma patients with pelvic ring injuries^[1]. Among the fractures involving pelvic ring, 15% to 45% involves sacrum^[2]. Early mobilization and ambulation after addressing sacral injuries plays a vital role in reducing the morbidity and mortality in these patients. The sacrum forms the base for the spinal column as well as the anchor of pelvic ring. Thus injuries of sacrum can lead to both biomechanical instability and nerve conduction abnormalities by injuring cauda equine^[3, 4]. Stabilising the posterior pelvic ring fractures is a great challenge particularly in poly trauma patients^[5] because of inherent difficulty in positioning these patients during surgery. Surgical treatment in pelvic ring lesions aims at good anatomic reduction and early mobilization, to avoid complications arising out of prolonged immobilization in bed^[6, 7]. The purpose of our study is to present the clinical and radiological results of percutaneous screw fixation of sacral and sacroiliac joint injuries.

Materials and methods

This is a prospective descriptive study conducted in our department involving 11 patients (all were male) over a period of 3 years from february 2014 to may 2017. The age range was 21 to 45 years with mean of 30.54. The procedure adopted for stabilizing the sacral fractures and sacroiliac joint disruptions was percutaneous iliosacral screw fixation. Denis & Weber classification and Tile/ Young and Burgess classification for sacral fracture and SI joint disruption respectively, were used in our study. All cases of Denis zone 1 & 2 sacral fractures & injuries involving sacroiliac joint disruption in Tile classification were included in the study. Patients with Denis zone 3 fractures, recessing type of sacral ala and crescent fracture were excluded. Each patient was stabilized hemodynamically in the casualty. Thorough skeletal survey (including CT scan) was done and all the injuries were documented.

Correspondence

Dr. Ramprasath DR
Associate Professor, Department
of Orthopaedic Surgery,
Government Coimbatore Medical
college Hospital, Coimbatore,
Tamil Nadu, India

Principles of damage control orthopaedics was instituted. All patients were evaluated for neurological deficits in lumbosacral dermatomes. In patients with Tile B injuries, pelvis was initially stabilized with either external fixator or sheet wrapped around the pelvis.

Operative procedure

Once the major fractures were stabilized, the sacral/sacroiliac joint injuries were addressed. Under spinal anesthesia with patient in supine position and folded towel under the lumbosacral region, C-arm images were obtained for AP, inlet, outlet and lateral sacral views. After appropriate draping, entry point was selected with a guide wire in the safe zone (Fig. 1). The guide wire was advanced with a drill. Its position was checked periodically using lateral sacral, inlet and outlet views (Fig.2- A,B,C) Once it was confirmed that guide wire is not violating the sacral canal and S1 neural foramen, drilling was done with cannulated drill bit. Appropriate size cannulated cancellous screw with washer

was introduced. Final position of the screw was checked with C-arm (Fig.2- D, E, F). CT scan was done postoperatively in all patients to confirm intraosseous screw position.

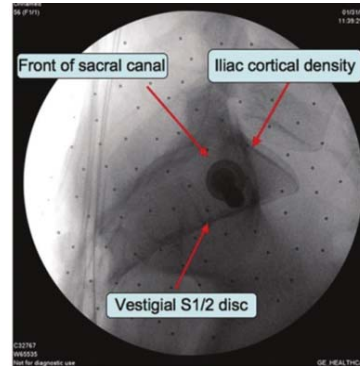


Fig 1: Safe zone shown in lateral sacral view

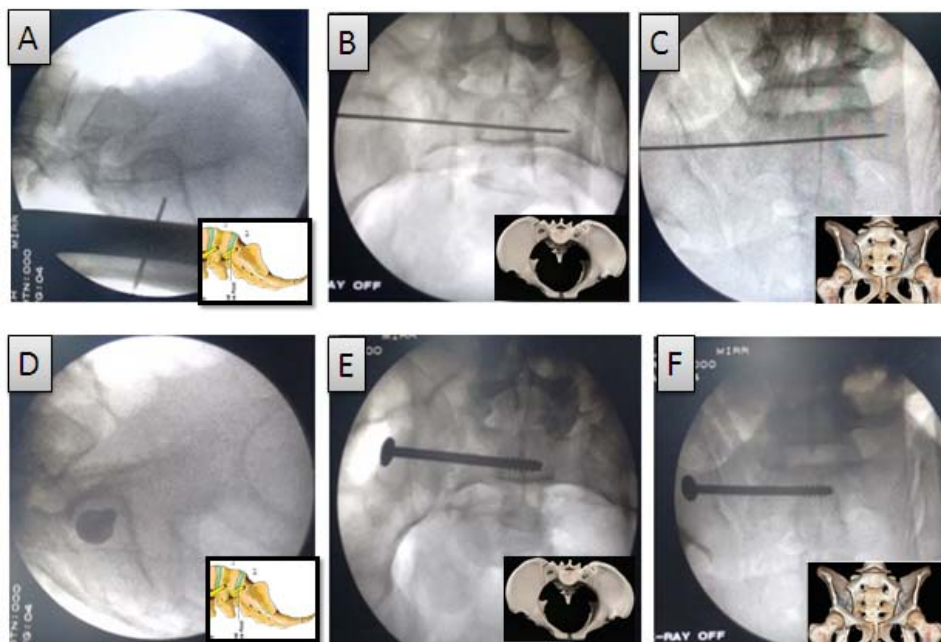


Fig 2: A-Guide wire in lateral view. B. Guide wire in Inlet view. C. Guide wire in outlet view D. Screw in lateral view. E. Screw in Inlet view. F Screw in outlet view

Case Illustration

Illustrative case 1: 34 years male with history of fall from height had Tile B injury (open book pubic diastasis < 2 cm, fracture superior and inferior pubic rami right side and zone II

sacral fracture right side) (Fig.3). The treatment was right side percutaneous iliosacral screw fixation. (Fig. 4). Two years follow up showed good functional outcome. (Fig.5)

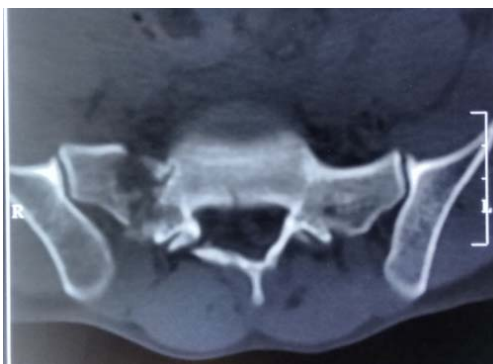

Fig 3: Pre Op CT showing Zone II sacral fracture.

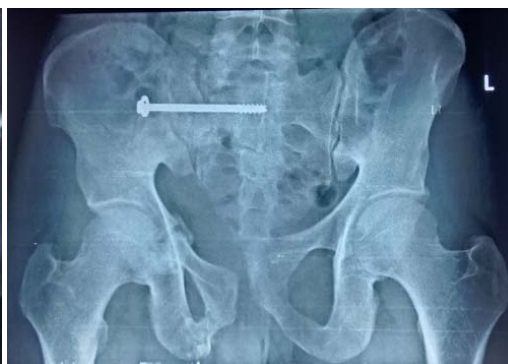

Fig 4: Post op Xray With screw in situ



Fig 5: Two years follow up

Illustrative case 2: 35 years male patient with history of fall from balcony had Tile B injury(pubic diastasis > 2cm with bilateral inferior pubic rami fracture, left zone II sacral fracture)(Fig.6) with distal radius fracture. After plating for radius, pelvic injury was stabilised with anterior pubic plating and percutaneous iliosacral screw fixation (Fig.7). 3 years follow up of patient showed good functional outcome. (Fig.8).

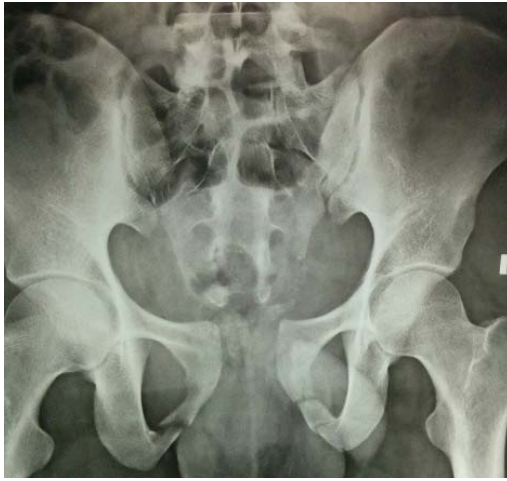

Fig 6: Preop x ray showing pubic diastases with left SI joint disruption.

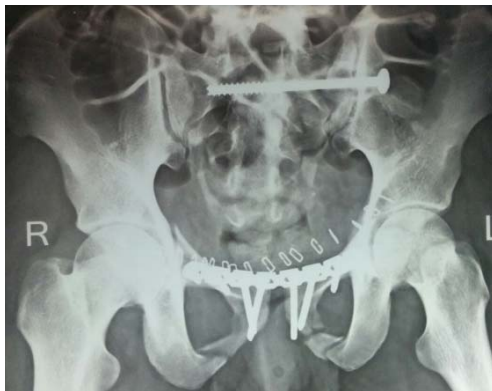

Fig 7: Post op x ray showing anterior pubic plating with screw for left SI joint.



Fig 8: Three years follow up

Illustrative case 3: 33-year-old male with history of RTA was admitted with Tile B injury (right superior and inferior pubic rami fracture with right zone II sacral fracture) (Fig. 9) The treatment was right side percutaneous iliosacral screw fixation. (Fig.10). 2 years follow up showed good functional outcome. (Fig.11)

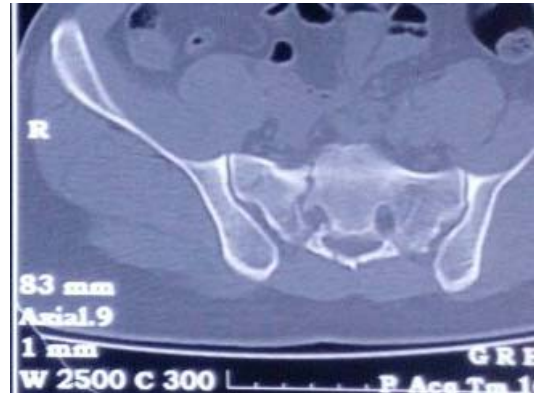

Fig 9: Pre Op CT showing right side zone II sacral fracture.

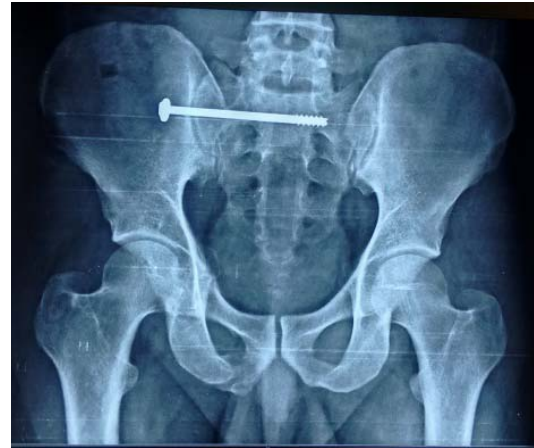

Fig 10: Post op Xray showing implant in situ.



Fig 11: 2 years follow up.

Illustrative case 4: 23 years male patient admitted with truck run over injury with Young and Burgess APC 3 injury (left sacroiliac joint disruption with left superior and inferior pubic rami fracture with right Denis zone 2 sacrum fracture). On the day of injury Patient was initially stabilized hemodynamically and closed reduction & pelvic external fixator applied (Fig.12). On day 7 percutaneous screw fixation for left sacroiliac joint and right sacral fracture was done. (Fig.13).

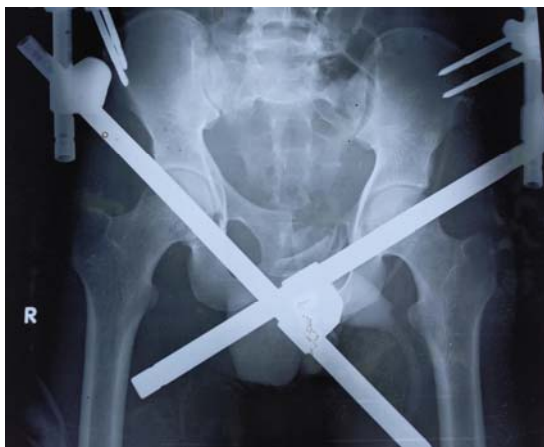

Fig 12: Initial closed reduction & pelvic external fixator application

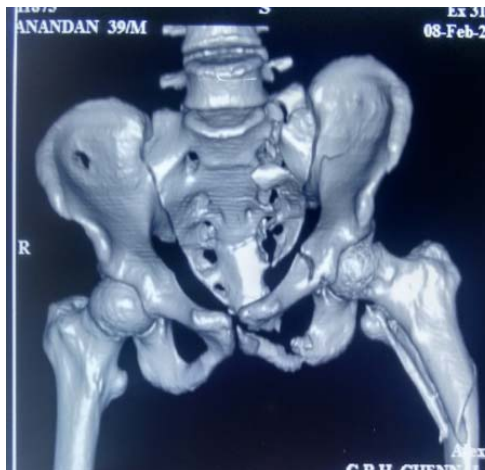

Fig 14: Pre Op CT showing zone II Sacral fracture

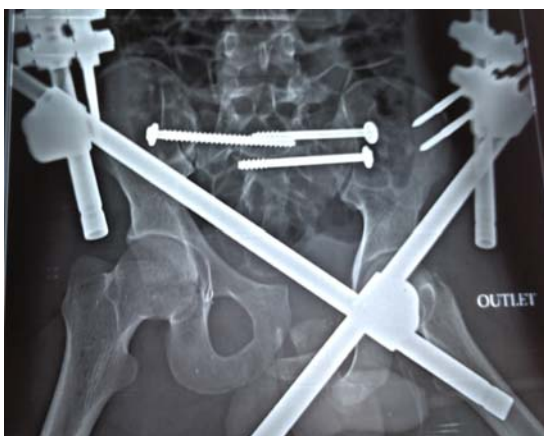


Fig 13: Post Op Xray with screws & pelvic external fixator in situ.

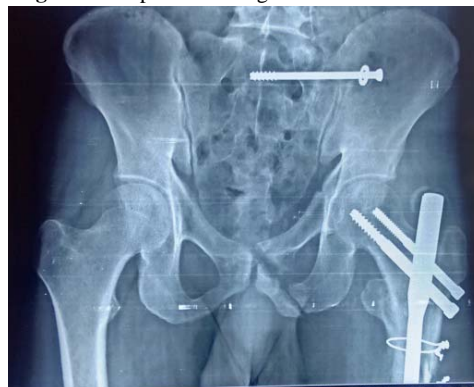

Fig 15: 2 months post Op X ray showing screw backout

Results

There were total of 11 patients (all male patients) in our study. Depending upon the associated injuries, the rehabilitation protocol was individualized for each patient. Mobilization in the form of turning to one side on the bed was encouraged on first post-operative day along with propping up of bed. Patient was made to sit according to pain tolerance. Weight bearing was allowed after 12 weeks of surgery.

Majeed scoring system was used to analyse the clinical improvement (Table 1). X rays were taken in AP, inlet and outlet view on second post-operative day. Follow up X rays were taken at 1 month, 3 month and at 6 month follow op. Follow up period ranged from 2 to 3 years. One case of sacral fracture had screw backout (Fig.14 & Fig.15) at the end of 2 months. But the patient was asymptomatic There were no other complications encountered (Table 1). All other bony and soft tissue injuries healed well.

Table 1: Master chart showing profile of all 11 patients in our study

| S. No | Age & Sex | Diagnosis | Associated Injuries | Procedure done for pelvic ring | Complication | Follow up | Majeed score |
|-------|-----------|--|--|---|----------------------------|-----------|--------------|
| 1 | 45/M | Tile B injury (left superior and inferior pubic rami fracture with left zone II sacral fracture) | Left Proximal tibia # | Percutaneous screw fixation for sacrum | Nil | 3 years | 80 |
| 2 | 37/M | Tile B injury (open book pubic diastases > 2cm with SI joint disruption on right side) | Right supracondylar # femur and # both bone Right leg | Percutaneous screw fixation for sacroiliac joint with plating for pubic diastases | Nil | 2 years | 76 |
| 3 | 34/M | Tile B injury (open book pubic diastasis < 2 cm ,fracture superior and inferior pubic rami right side and zone II sacral fracture right side) | Right acetabular Anterior column # | Percutaneous screw fixation for sacrum | Nil | 2 years | 82 |
| 4 | 26/M | Tile B injury(pubic diastasis > 2cm with bilateral inferior pubic rami fracture , zone II Sacral fracture) | B/L acetabular anterior column # with distal radius # left | Percutaneous screw fixation for sacrum with plating for pubic diastases | Nil | 2 years | 82 |
| 5 | 39/M | Tile B injury (left superior and inferior pubic rami fracture with left zone II sacral fracture) | Left Subtrochanteric # & L2 burst fracture. | Percutaneous screw fixation for sacrum | Asymptomatic screw backout | 2 years | 84 |
| 6 | 23/M | Tile B injury (right side superior & inferior pubic rami fracture with | Nil | Percutaneous screw fixation for sacroiliac | Nil | 2 years | 76 |

| | | right zone2 sacral fracture) | | joint | | | |
|----|------|--|--------------------------------------|--|-----|---------|----|
| 7 | 21/M | Tile C injury (left sacroiliac joint disruption with left superior and inferior pubic rami # with right Denis zone 2 sacrum #) | Scrotal injury managed with surgeons | Day 1- closed reduction and pelvic ext fix. Day 7- Percutaneous screw fixation for left sacroiliac joint and right sacral # | Nil | 2 years | 80 |
| 8 | 28/M | Tile B injury (Right side superior & inferior pubic rami fracture with Right zone2 sacral fracture) | Nil | Percutaneous screw fixation for sacroiliac joint | Nil | 2 years | 84 |
| 9 | 29/M | Tile B injury (open book pubic diastases > 2cm with SI joint disruption on right side) | # Both Bone Right leg | Percutaneous screw fixation for sacroiliac joint with plating for pubic diastases | Nil | 2 years | 78 |
| 10 | 30/M | Tile B injury (open book pubic diastasis < 2 cm ,fracture superior and inferior pubic rami left side and zone II sacral fracture left side) | Nil | Percutaneous screw fixation for sacrum | Nil | 2 years | 76 |
| 11 | 24/M | Tile B injury (Left side superior & inferior pubic rami fracture with Left zone2 sacral fracture) | # Distal Femur Left | Percutaneous screw fixation for sacroiliac joint | Nil | 2 years | 76 |

Discussion

In 1978, Letournal performed iliosacral screw fixation by open technique with the patient in prone position. In 1993 the evolution of various imaging modalities lead to strictly percutaneous iliosacral screw fixation with the patient in supine position by Rouff *et al.* [8]

Preoperative preparation consists of 1) Neurological examination [9] 2) Skeletal survey 3) CTscan (to rule out sacral dysplasia) [10] 4) Enema on the day of surgery (to clear the obscuring bowel shadows radiologically)

Prior reduction of the posterior lesion using an external method (i.e. traction for vertical shear injuries and pelvic compression for open book injuries) is a prerequisite to iliosacral screw fixation [5]. Thorough familiarity with the anatomic features of lumbopelvic junction and neighbouring vessels and nerves is crucial [11]

Guide wire should pass anterior to the sacral canal in Pennal's inlet view, superior to S1 neural foramen in Pennal's outlet view, and through the safe zone (23×12 mm.) [12] in Rouff's lateral sacral view(Fig.1.). Anterosuperior part of S1 body on which Iliac Cortical Density (ICD) overlaps is seen in the lateral view [10]. Violation of ICD by the screw may cause injury to L5 nerve. (Fig. 16)

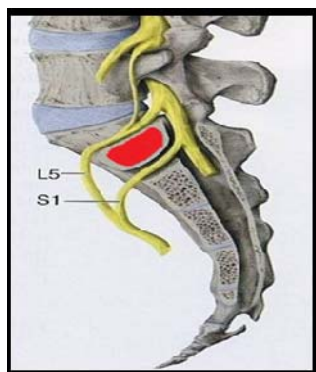


Fig 16: L5 nerve and S1 nerve lies closer to safe zone (red)

Biomechanically finite element bone model analysis showed that the major loads of pelvic ring were shared and burdened

by posterior ring which contributed to 61.5% to 69.5% of the stiffness of the pelvis [3]. This shows that fixation of the posterior pelvic ring is essential in all cases of posterior pelvic ring injuries in order to obtain good stability for early mobilization in the bed(i.e. turning the patient for back hygiene)

Tonetti *et al.* [5] had managed 120 patients by iliosacral screw fixation with mean follow up of 14 months. In this study extraosseous trajectory occurred in 19.8% of cases and neurological status worsened in 16.7% of patients. Local infection occurred in 4 cases and disassembly in 10 [5]. In our study, there were no such complications. In one case of sacral fracture, we observed screw backout after 2 months, but the patient was asymptomatic.

Other modalities of treatment include anterior SI joint plating, posterior tension band metallic plate, posterior transiliac screw fixation. These methods have got their own indications and limitations.

In spite of requiring technical precision, this technique is particularly useful in polytrauma patients providing valuable benefits including absence of non-union and of highly incapacitating sacroiliac pain.

Indication and Contraindications

The indications for percutaneous iliosacral screw fixation include SI joint disruption, sacral fractures in zone I and zone II and sacral insufficiency fractures (i.e. osteoporotic fracture) [13]. Contraindications to this technique include sacral dysplasia [10], present fracture of posterior iliac wing and Denis zone III sacral fractures [14].

Conclusion

Eventhough percutaneous sacroiliac screw fixation is one of the modalities of treatment for sacral and sacroiliac joint injuries, it stands as the best modality of treatment in patients with other comorbidities (like diabetes, ageing) and in polytrauma patients where turning the patient for back hygiene is needed

However it needs thorough knowledge regarding anatomy, orientation towards C-arm images and expertise in performing the procedure.

Acknowledgements

None.

Footnote

Conflicts of Interest: The authors have no conflicts of interest to declare.

Informed Consent: Written informed consent was obtained from the patients for publication of this manuscript and any accompanying images.

References

1. Lee SY, Niikura T, Sakai Y, Miwa M, Nishida K, Kuroda R *et al.* Sacral Fracture Nonunion Treated by Bone Grafting through a Posterior Approach. Case reports in orthopedics. 2013.
2. Denis F, Davis S, Comfort T. Sacral Fractures: An Important Problem Retrospective Analysis of 236 Cases. Clinical orthopaedics and related research. 1988; 227:67-81
3. Chen H, Wu L, Zheng R, Liu Y, Li Y, Ding Z. Parallel analysis of finite element model controlled trial and retrospective case control study on percutaneous internal fixation for vertical sacral fractures. BMC musculoskeletal disorders. 2013; 14(1):217.
4. Vaccaro AR, Kim DH, Brodke DS, Harris M, Chapman J, Schildhauer T *et al.* Diagnosis and management of sacral spine fractures. JBJS. 2004; 86(1):166-75.
5. Tonetti J, Van Overschelde J, Sadok B, Vouaillat H, Eid A. Percutaneous ilio-sacral screw insertion. Fluoroscopic techniques. Orthopaedics & Traumatology: Surgery & Research. 2013; 99(8):965-72.
6. Coldstein A, Phillips T, Sclafani SJ, Scalea T, Duncan A, Goldstein J *et al.* Early open reduction and internal fixation of the disrupted pelvic ring. Journal of Trauma and Acute Care Surgery. 1986; 26(4):325-33.
7. Routt Jr MC, Simonian PT, Mills WJ. Iliosacral screw fixation: early complications of the percutaneous technique. Journal of orthopaedic trauma. 1997; 11(8):584-9.
8. Routt Jr MC, Kregor PJ, Simonian PT, Mayo KA. Early results of percutaneous iliosacral screws placed with the patient in the supine position. Journal of orthopaedic trauma. 1995; 9(3):207-14
9. Ruatti S, Kerschbaumer G, Gay E, Milaire M, Merloz P, Tonetti J. Technique for reduction and percutaneous fixation of U-and H-shaped sacral fractures. Orthopaedics & Traumatology: Surgery & Research. 2013; 99(5):625-9.
10. Chip Jr MC, Simonian PT, Agnew SG, Mann FA. Radiographic recognition of the sacral alar slope for optimal placement of iliosacral screws: a cadaveric and clinical study. Journal of orthopaedic trauma. 1996; 10(3):171-7.
11. Templeman D, Schmidt A, Freese J, Weisman I. Proximity of iliosacral screws to neurovascular structures after internal fixation. Clinical orthopaedics and related research. 1996; 329:194-8.
12. Tonetti J, Cloppet O, Clerc M, Pittet L, Troccaz J, Merloz P *et al.* Implantation of iliosacral screws. Simulation of optimal placement by 3-dimensional X-ray computed tomography, Rev Chir Orthop Reparatrice Appar Mot, 2000; 86:360-369.
13. Tsiridis E, Upadhyay N, Gamie Z, Giannoudis PV.

Percutaneous screw fixation for sacral insufficiency fractures. Bone & Joint Journal. 2007; 89(12):1650-3.

14. Chen HW, Liu GD, Fei J, Yi XH, Pan J, Ou S, Zhou JH. Treatment of unstable posterior pelvic ring fracture with percutaneous reconstruction plate and percutaneous sacroiliac screws: a comparative study. Journal of Orthopaedic Science. 2012; 17(5):580-7.