



International Journal of Orthopaedics Sciences

ISSN: 2395-1958
IJOS 2017; 3(4): 630-633
© 2017 IJOS
www.orthopaper.com
Received: 29-08-2017
Accepted: 30-09-2017

Akloa Komlavi Ehliou Kolima
Department of Orthopaedic and
traumatology Surgery Teaching
University Hospital Sylvanus
Olympio Lomé-Togo

Kombate
Noufanangue Kanfitine.:
Department of Orthopaedic and
traumatology Surgery, Saint-
Jean de Dieu d' Afagnan
Hospital, Lome-Togo

Dellanh Yaovi Yannick
Assistant Head of Clinic,
University of Lomé, Trauma-
Orthopedics Service Of The
Hospital Saint-Jean De Dieu
d' Afagnan, Afagnan, TOGO.

Akpoto Yaovi Mensanvi
Department of Orthopaedic and
traumatology Surgery Teaching
University Hospital Sylvanus
Olympio Lomé-Togo

Fortey Kossivi
Department of Orthopaedic and
traumatology Surgery Teaching
University Hospital Sylvanus
Olympio Lomé-Togo

Abalo Anani Grégoire
Department of Orthopaedic and
traumatology Surgery Teaching
University Hospital Sylvanus
Olympio Lomé-Togo

Correspondence

Akloa Komlavi Ehliou Kolima
Department of Orthopaedic and
traumatology Surgery Teaching
University Hospital Sylvanus
Olympio Lomé-Togo

Surgical treatment of femoral shaft fractures by open intramedullary nailing: Clinical and radiological findings

Akloa Komlavi Ehliou Kolima, Kombate, Dellanh Yaovi Yannick, Akpoto Yaovi Mensanvi, Fortey Kossivi and Abalo Anani Grégoire

DOI: <https://doi.org/10.22271/ortho.2017.v3.i4i.89>

Abstract

Objectives: To describe the therapeutic technique, to assess the duration of consolidation of the fractures of the femoral shaft treated by open centromedullary nailing, to highlight the complications associated with the therapeutic technique and to evaluate the prognosis of the treatment.

Patients and Methods: This was a major retrospective study of the records of patients aged 15 years and older with a femoral shaft fracture and were treated by open-ended centromedullary nailing in the orthopedic and trauma department of Sylvanus Olympio University Hospital in Lomé from January 2010 to December 2016.

Results: One hundred and fifty-four patients underwent osteosynthesis of the open femoral shaft with nailing. The 25-35 age group was the most represented with 35.06%. Patients with a liberal profession were predominant (55.19%). Sixty-four patients (41.56%) underwent locked nailing and 90 patients (58.44%) had an unlocked nailing. Immediate complications were mainly hemorrhagic shock and secondary complications with infection (7.14%) which was superficial in the majority of cases. Delayed consolidation was the leading cause of late complications. 94.81% consolidated within the six-month period. We found only 1.95% of nonunion. The result was very good in 86.02% of cases. 76 patients (49.35%) found the treatment expensive, but the majority of operated patients (98.05%) said they were satisfied with the treatment

Conclusion: Centromedullary open-heart nailing provides good results when asepsis and postoperative procedures are observed.

Keywords: Fracture, femoral diaphysis, centromedullary nail, open hearth

Introduction

The diaphyseal fracture of the femur is a solution of continuity whose line sits between 4 centimeters below the small trochanter and 8 centimeters above the femoro-tibial line [1]. It particularly affects the young, male subject and most often occurs in the wake of violent road trauma and in a context of polytrauma [2]. In the elderly, the fracture occurs in the context of a common fall and is then easily isolated [2].

The fractures of the femur are very frequent, and constitute a real public health problem [3]. The management of these lesions involves two main means: orthopedic and surgical means [2]. Orthopedic treatment has long occupied a place in the therapeutic possibilities of fractures of the femoral diaphysis. Its important disadvantages and its numerous constraints make it, outside of exceptional situations, completely abandoned in favor of more efficient surgical methods [2, 4].

Locked intramedullary nailing has emerged over time as the standard osteosynthesis technique in the treatment of diaphyseal fractures of the femur, in front of the screwed plate and the external fixator [5]. Its closed design has shown its supremacy over the open hearth by its many advantages: lower infectious risk, minimally invasive approach with consequent reduction of transfusion requirements and disease transmission, rapid return to the previous function with minimized impact on productivity [6, 7]. In practice, it requires the use of the image intensifier and an orthopedic table that are not always available at all levels of health systems [8].

At Sylvanus Olympio teaching hospital of Lomé, the unavailability of these equipment has imposed for a long time open osteosynthesis with all the complications that arise. The aim of this work was to determine the results of the treatment of femoral diaphyseal fractures by open intramedullary nailing in the trauma and orthopedics department of Sylvanus Olympio University Hospital (CHU-SO).

Methodology

This was a retrospective and descriptive study, from January 1, 2010 to December 31, 2016, on the records of patients treated for femoral shaft fracture by open intramedullary nailing in the orthopedic surgery department of Sylvanus Olympio teaching Hospital and followed by regular postoperative control.

The operative technique was identical for all our patients. The Patient was placed in lateral decubitus under locoregional or general anesthesia. After debridement, a posterolateral approach centered on the line from the greater trochanter to the lateral condyle was made and followed by the haemostasis of the subcutaneous cellular tissue. (figure 1)

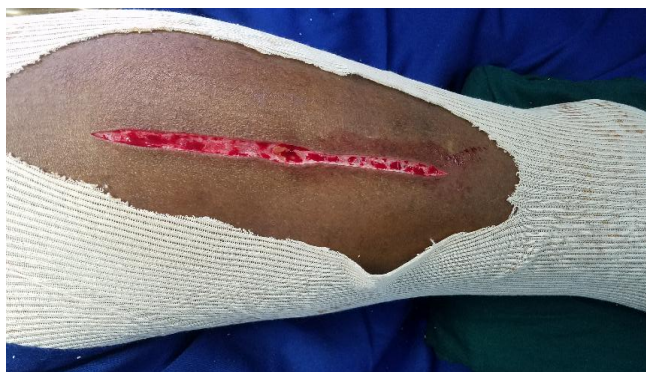

Fig 1: Posterolateral approach (picture from orthopedic department of CHU SO)

The fascia lata was exposed and incised in the direction of these fibers. The vastus lateralis was retracted forward while making the progressive haemostasis of the perforating arteries of the femur up to the fracture site. The bone ends were revived, the fracture was reduced and maintained by a reduction forceps (Figure 2).

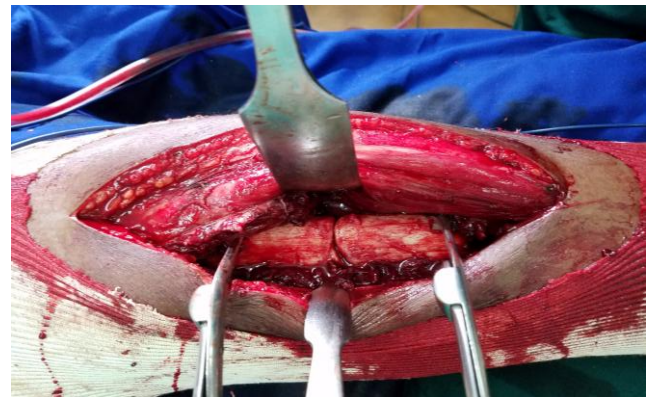

Fig 2: Exposure and reduction of the fracture site (picture from orthopedic Department of CHU SO)

Then came the summit of the great trochanter, which was trepanned. A boring guide was set up for the bore and a second guide helped us to measure the length of the nail to be inserted into the medullary canal. The locked or unlocked nail was inserted into the medullary canal until the proximal end of the nail was flush with the top of the greater trochanter. The different plans were closed under a suction drain. In locked intramedullary nailing, the extension bar helped us to locate approximately the position of the distal nail holes. The femur was again approached in distal, the lateral cortical is wicked and the orifice is widened until visualization of the nail hole. We completed the wicking of the internal cortex and the locking screw was put in place (Figure 3).

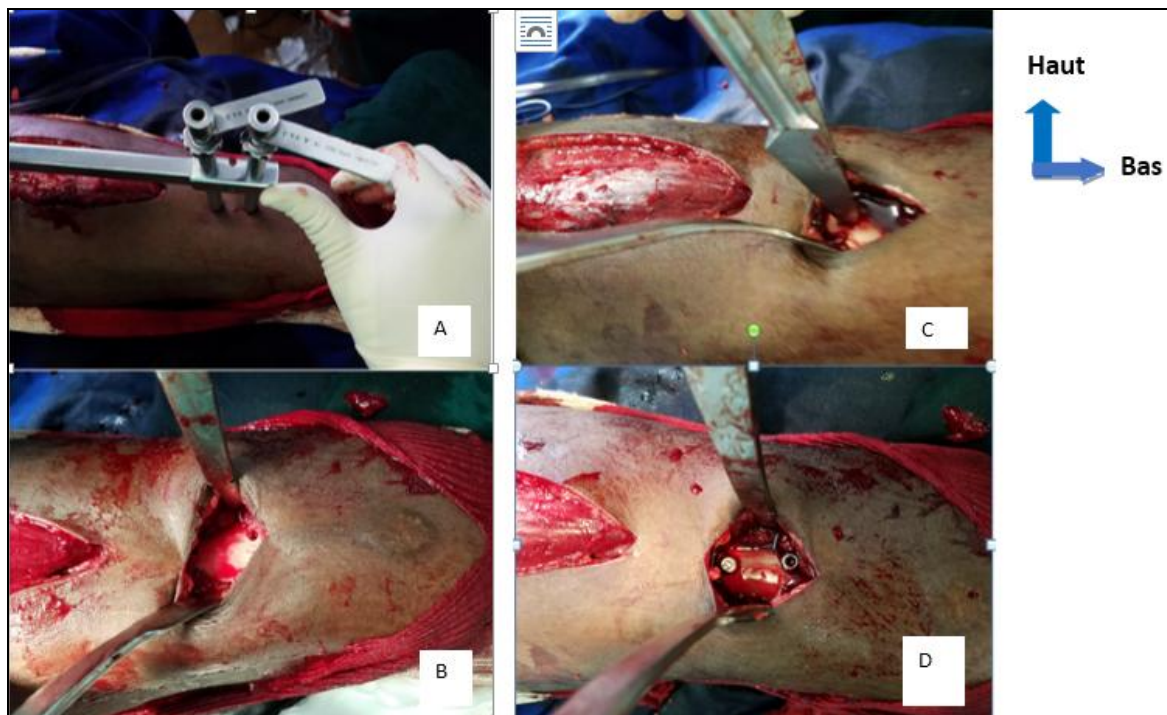


Fig 3: different stages of distal locking (patient of the orthopedic orthopedic service CHU SO)

Fig 3A: Installation of the extension bar and approximate identification of the distal holes of the nail

Fig 3B: orifice left by the wicking of the lateral cortex

Fig 3C: enlargement of the orifices of the lateral cortex.

Fig 3D: screw position after distal locking

The guide rod test allowed us to check if the screw passed through the nail hole. Proximal locking was done using the nail insertion handle.

For each patient record, we studied: age, sex, occupation, mechanism of trauma, cutaneous opening classes according to Gustilo and Anderson, fracture site, type of fracture line, other bone lesions associated, type of nailing (nailing intramedullary locked or not).

The complications studied were divided into: immediate, secondary and late complications:

The determination of the consolidation was made taking into account: the absence of pain, the presence of a unitive callus and joint mobility (Table 1) [1].

The subjective assessment of the results was made by asking the impression of the patient on the treatment, on the cost of the treatment.

Table 1: Criteria for objective assessment of the results of intramedullary nailing of the open femur

Very Good	Good	BAD
No pain No shortening or less than 2cm Mobility of the joints above and below intact No trophic disorders Radio-clinical consolidation	No pain Shortening between 2 and 3cm Radio-clinical consolidation No trophic disorders Susceptibility of the underlying joint and underlying joints	Painful callus Susceptibility of the underlying joint and underlying joints trophic disorders

Results

During the period from January 1, 2010 to December 31, 2016, 312 patients aged 15 years and older were hospitalized for a femoral shaft fracture. Of these, 154 were complete and contacts were used to reach patients. The average age of patients was 33.6 years with extremes of 15 and 65 years. The distribution by age group noted a predominance of the 25 to 35 year bracket (Table 2).

Table 2: Distribution of patients by age group

	Effective	Percentage (%)
[15-25]	42	27,27
[25-35]	54	35,06
[35-45]	29	18,83
[45-55]	19	12,34
[55 et plus]	10	6,49
Total	154	100,00

We noted also a large male predominance: 112 men for 42 women. The sex ratio was 2.66. Patients in the informal sector constituted the largest group with 55.19% (Table 3).

Table 3: Distribution of Patients by Activity Sector

	Effective	Percentage (%)
Informal sector	85	55,19
Officials	32	20,78
Student / student	29	18,84
Unemployed	08	5,19
Total	154	100,00

We found a clear predominance of road accidents (87,66%) following by domestic accident(5,19%). Lesions sat preferentially at the middle third (64,94%). Of the 154 patients enrolled in our study, 16 (10.39%) had cutaneous opening. In this proportion, type I carries the large percentage with 9 cases followed by type II with 4 cases and type III with 3 cases. Ninety patients (58.44%) had an unlocked nail and 64 patients (41.56%) had a locked nail. Eleven patients (7.14%) had an immediate complication. Haemorrhagic shock occurred in 9 patients (5.84%) and anesthetic shock in 2

patients (1.30%). Secondary complications occurred in 13 patients (8.44%) and were dominated by infectious complications with 13 cases (7.14%). The infection was superficial in 8 cases and deep in 3 cases. Late complications accounted for 9.09%. We recorded 5 cases of consolidation delay, 3 cases of malunion and 3 cases of nonunion, two of which were hypertrophic and one atrophic (Table 4).

Table 4: Distribution of late complications according to the type of nail used

	Locked nail	Unlocked nail	Total
Delayed consolidation	2	3	5
Cal vicious	0	3	3
Nonunion	2	1	3
Joint stiffness	1	2	3
Total	5	9	14

Bone healing was achieved in 146 patients (94.81%) within 6 months. Five patients with delayed consolidation consolidated after 12 months with the same treatment. The treatment was good and very good in a proportion of 94.80% for the locked and unlocked nail. It was unfavorable or bad in 5.20% (Table 5).

Table 5: Distribution of patients according to the evaluation of the results according to the type of nailing

	Locked nail n (%)	Unlocked nail n (%)	Total
Very good	56 (87,50)	77 (85,56)	133
Good	4 (6,25)	9 (10,00)	13
Bad	4 (6,25)	4 (4,44)	8
Total	64 (100,00)	90 (100,00)	154

Ninety-six patients (55.84%) found the treatment expensive and 68 patients (44.16%) found it affordable. Among the patients who found the treatment expensive, those with a liberal profession and those who were unemployed had predominated (Table 6).

Subjectively 151 patients (98.05%) reported being satisfied with the treatment received. And 1.95% of the patients were disappointed with the treatment.

Table 6: Breakdown of cost appreciation by occupation

	Officials n (%)	Students n (%)	Unployed n (%)	Informal sector n (%)	Total
Very expensive	0 (0,00)	1 (3,45)	2 (25,00)	7 (8,24)	10
Expensive	9 (28,13)	12 (41,38)	6 (75,00)	49 (57,65)	76
Affordable	23 (71,87)	16 (55,17)	0 (0,00)	29 (34,11)	68
Total	32 (100,00)	29 (100,00)	8 (100,00)	85 (100,00)	154

Discussion

We conducted a retrospective study to determine the results of femoral shaft fracture treated by open intramedullary nailing and compare these results with literature data.

Analysis of the literature shows that femoral shaft fractures occur in young, predominantly on male subjects. Bonneville *et al* ^[9], Mcharo ^[10] reported in their series average ages of 31.86 years and 33.1 years respectively. The main etiology of these lesions being road accidents. It is a lesion which concerns preferentially a young active population both professionally and personally exposing themselves to various risks, little control gear and the rules of the road. The high mobility of this young population would explain the high proportion of informal sector patients that we found in our work and which is also reported by most authors. As in the series of Al-habdan *et al.* in Saudi Arabia ^[11], the lesions of the middle 1/3 of the femoral diaphysis predominated with a proportion of 64.94% and was open in 10.39% of patients. According to Bonneville ^[9] cutaneous opening is present in only 10 to 20% of cases of femur fracture because of the importance of the muscle mass surrounding the femur. These open fractures when they are not properly treated initially expose the patient to infectious complications and osteitis which is particularly dangerous to the femur.

Closed centromedullary nailing has emerged over time as the standard osteosynthesis technique in the treatment of diaphyseal fractures of the femur ^[12]. The unavailability of the image intensifier and the orthopedic table required us to open the fracture site when we had to surgically treat a femur fracture with tips for distal locking. This locked nailing technique without image intensification was also reported by Guifo *et al.* In Yaoundé ^[13]. Immediate complications (7.14%) was dominated by hemorrhagic shock. In our context, the lack of financial means delays the management and the patients are operated on at the stage of callus. This made the intervention more haemorrhagic. Borel *et al* ^[14], Simon *et al* ^[15] found respectively 10.29% and 10.8% of cases of immediate complications. The consolidation was acquired in 98.05%. Late complications such as joint stiffness and nonunion accounted for 1.95% of complications. This proportion is comparable to that of Borel *et al*, and Bonneville *et al* ^[52] found 1.47% of nonunion. The treatment was satisfactory, taking into account the very good and good results, in 94.8% and bad in 5.2% of cases.

Femur Fractures treat by open focus may provide good early consolidation and minimal non-union when soft tissues adjacent to the fracture are preserved and bone fragments are minimally devitalized. It is also recommended to collect the fracture hematoma and reinject it to the fracture site at the end of the osteosynthesis. More than half of the patients (55.84%) found the treatment expensive. In fact, the overall cost of osteosynthesis of the femur by including, the cost of the nail, anesthetic and surgical prescriptions, the operating category and the hospitalization costs amount to about two hundred and fifty thousand francs (380 €) for an unlocked nailing and five hundred thousand francs (760 €) for a locked nailing. The Guaranteed Minimum Interprofessional Salary (GMIS) being 38000 francs (about 58 €) in our country, we understand that this cost is extremely expensive when we do not have health insurance.

Conclusion

Fractures of the femoral diaphysis are frequent lesions affecting a very active young population and mainly related to road accidents. Their management ideally passes through

intramedullary nailing with closed focus, but all conditions are still not met for this ideal treatment. This study allowed us to note that the open intramedullary nailing yielded good results with a consolidation rate comparable to that of the literature. Other prospective randomized comparative studies deserve to be conducted to determine the real effectiveness of these treatments in our contexts.

Reference

1. Bonnemmet F, Clavert P, Cognet JM. Fracture of the femoral diaphysis of the adult. *Encycl Med Chir (Elsevier Masson, Paris), Musculoskeletal System*, 14-0786-A-10, 2006, 23.
2. Lofman O, Bergrund K, Larsson L. Changes in hip fractures epidemiology: redistribution between ages, genders, and fractures types. *Osteoporosis Int.* 2002; 13(1):18-25.
3. Fogerty SJ, Giannoudis PV. Fractures of the femoral shaft. *Surgery, Orthopedic.* 2007; 25(10):430-433.
4. Kempf I, Pidhorz L. Annealing fractures of the femoral diaphysis. *Encycl Med Chir (Elsevier Masson, Paris), Surgical Techniques - Orthopedics-Traumatology*, 2000; 6:44-705.
5. Nowotarski PJ, Turen CH, Brumback RJ, Scaboro JM. Conversion of external fixation to intramedullary nailing for fractures of the shaft of the femur in multiply injured patients. *J Bone Joint Surg Am.* 2000; 82:781-8.
6. Ricci WM, Bellabarba C, Evanoff B. Retrograde versus antegrade nailing of femoral shaft fractures. *J Orthop Trauma.* 2001; 15(3):161-9.
7. Bouchard JA, Barei D, Cayer D, O'Neil J. Outcome of femoral shaft in the elderly. *Clin Orthop Relat Res.* 1996; 332:105-9.
8. Abalo C. intramedullary nailing by nail kuntscher in the treatment of fractures of the femur: about 435 cases carried out in Lome chu. Lome: University of Lome review. 1980; 12(1):122-129.
9. Bonneville P, Cauhepe C, Aigoh F, Bellumore Y, Rongieres M, Mansat M. Risks and results of the simultaneous nailing of bifemoral fractures. *Rev. Med. ort.* 2000; 86:598-607.
10. Mcharo CN, Museru LM. Late open intramedullary Kuntscher nailing of femoral shaft fractures. *Tanzania Medical Journal.* 2005; 20(1):26-7.
11. Al-habdan I. Diaphyseal femoral fractures in children: Should we change the present mode of treatment? *Int Surg.* 2004; 89(4):236-9.
12. Bonneville P. Diaphyseal fractures of the adult. *Encycl Med Chir (Elsevier Masson, Paris), Musculoskeletal System*, 14-031-A-60, 2005, 14.
13. Guifo ML, Muluem OK, Farikou I. Locked intramedullary locking without a gloss enhancer at Yaoundé University Hospital: about 34 cases. *Rev chir orth.* 2016; 102:101-6.
14. Borel JC, Dujardin F, Thomine JM, Biga N. Locked locking of complex fractures of the femoral diaphysis of the adult. *Rev. Med. Orth.* 1993; 79:553-564
15. Simon P, Forturato N. Complication of the intramedullary nailing of the femur as a function of the fracture. *Rev. Med. orth.* 2005; 91:170-172.