



International Journal of Orthopaedics Sciences

ISSN: 2395-1958
IJOS 2017; 3(4): 544-547
© 2017 IJOS
www.orthopaper.com
Received: 14-08-2017
Accepted: 15-09-2017

Dr. DV Prasad
Head of Department & Professor
of Orthopaedics, Rural Medical
College Loni, Taluka - Rahata,
District - Ahmednagar,
Maharashtra, India

Dr. Parminder Singh
PG Student, Department of
Orthopaedics, Rural Medical
College Loni, Taluka - Rahata,
District - Ahmednagar,
Maharashtra, India

Dr. Nikhil M Ingle
PG Student, Department of
Orthopaedics, Rural Medical
College Loni, Taluka - Rahata,
District - Ahmednagar,
Maharashtra, India

Dr. Mahammad Akram A Saji
PG Student, Department of
Orthopaedics, Rural Medical
College Loni, Taluka - Rahata,
District - Ahmednagar,
Maharashtra, India

Dr. Yash B Rabari
PG Student, Department of
Orthopaedics, Rural Medical
College Loni, Taluka - Rahata,
District - Ahmednagar,
Maharashtra, India

Dr. Ranjan Kumar Gupta
PG Student, Department of
Orthopaedics, Rural Medical
College Loni, Taluka - Rahata,
District - Ahmednagar,
Maharashtra, India

Correspondence

Dr. DV Prasad
Head of Department & Professor
of Orthopaedics, Rural Medical
College Loni, Taluka - Rahata,
District - Ahmednagar,
Maharashtra, India

Comparative study of retrograde versus Antegrade nailing in humeral diaphyseal fractures

Dr. DV Prasad, Dr. Parminder Singh, Dr. Nikhil M Ingle, Dr. Mahammad Akram A Saji, Dr. Yash B Rabari and Dr. Ranjan Kumar Gupta

DOI: <https://doi.org/10.22271/ortho.2017.v3.i4h.74>

Abstract

Introduction: DHF can be effectively treated by either antegrade or retrograde IMIL nailing and these is a relatively novel method of fracture fixation. These comparative study of two approaches on DHF using the same locked nails.

Materials and Methods: Our comparative study we have selected 97 patients with DHF. Out of 97 patients, 70 male and 27 females, age ranging from 22 to 70 for males and 20 to 60 for females, 69 right and 17 left, 75 closed and 22 grade I & II compound fractures, RHN nailing was done on 47 and AHN was done on 50 patients.

Results: We analyzed the objective and subjective outcome of RHN and AHN in 97 cases of DHF in various age groups. All fractures unite in good anatomic position. No cases of deep infections but in 1 case there was a posterior cortical break which hasn't altered his all union time which was average 12 weeks. Neurapraxia was developed in 3 cases of AHN and in 1 case of RHN and there was no nerve entrapment in RHN.

In one case of DHF, there was abrasions at the site of proximal screw insertion so proximal locking wasn't done and it was found that more amount of callus was formed comparatively. So proximal locking wasn't done in RHN.

Conclusion: IMIL nailing in the management of DHF is that a 'fixed' nail can be inserted with both antegrade and retrograde techniques regardless of the fracture pattern and location. RHN is long learning curve and should be done very meticulously because posterior cortical break can lead to disastrous situation.

Keywords: RHN- retrograde humerus nailing, AHN- antegrade humerus nailing, DHF- diaphyseal humerus fracture, IMIL- intra-medullary inter-locking

Introduction

DHF treated by either antegrade or retrograde IMIL nailing and these is a relatively novel method of fracture fixation. Its wide implementation began in the last decade of the 20th century and was accepted in everyday practice after IMIL nailing for the femur and tibia [1-6]. Adequate immobilization of humeral fractures is difficult, particularly in the elderly and obese. Non-operative treatment is long and tedious for the patient, results in stiffness of neighboring joints and may lead to pseudarthrotic changes due to shearing muscle forces and instability. Prior to the advent of intra-medullary interlocking devices, compression plates were the gold standards for surgical treatment of DHF. The first interlocked humeral nail was described by Derweduwen in 1979, but experience remained small [21]. By introducing intramedullary nails into everyday practice of humeral fracture treatment, indications for operative treatment of humeral fractures have been broadened. The interlocking device is load bearing device as it is closer to mechanical axis. It requires less exposure, surgical time, blood loss, operative time. Fracture hematoma is not disturbed and it doesn't jeopardize blood supply. Early functioning of elbow is regained by immediate postoperative mobilization. Several reports have demonstrated that with newer implants and improved techniques, locked intra-medullary nailing can have a success rate as high as that of other methods [6, 7]. Nailing can be done by either antegrade or retrograde approach. The present study compared the effectiveness and potential risks of these two approaches on middle humeral shaft fractures using same locked nails. Retrograde nailing is technically more demanding than antegrade insertion because the

position of the olecranon does not allow placement of the nail in the direction of the medullary canal axis. The rotator cuff injury during antegrade nail insertion may result in postoperative disorders during abduction and elevation of the upper arm [2, 6-9]. With certain fracture types and suitable nail design, it is possible to avoid this type of complication, if the nail is inserted using the retrograde technique [10-13].

Materials and Methods

We have selected 97 patients with DHF. Out of 97 patients 70 male and 27 females, age ranging from 22 to 70 for males and 20 to 60 for females. Out of 97 patients 69 right and 28 left, 75 closed and 22 grade I & II compound fractures. Out of 97 patients RHN nailing was done on 47 and AHN was done on 50 patients. This study done during 2008 to 2014 at Pravara Rural Hospital, Loni, Maharashtra. Pre-operative radiographs of arm including shoulder and elbow joint in antero-posterior and lateral views were done to assess fracture pattern, bone quality and canal diameter.

Including criteria

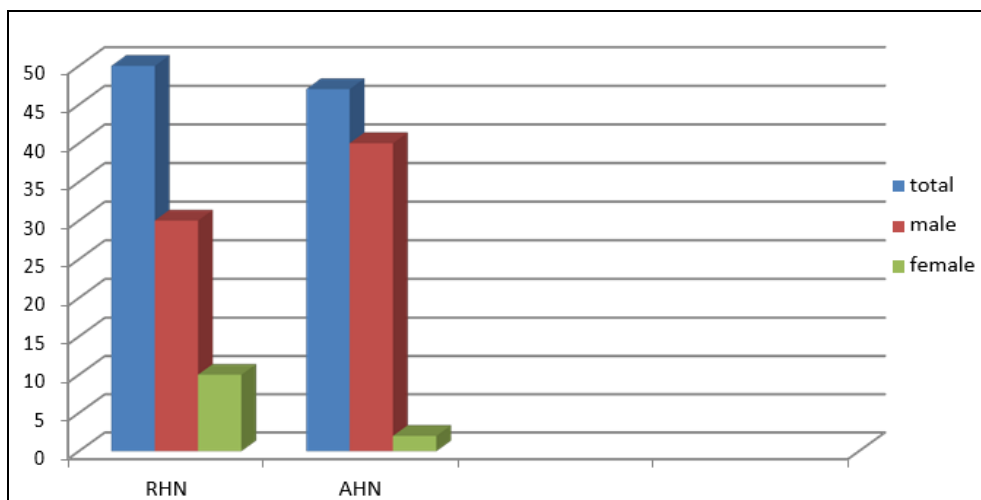
- All patients with Age ranging from 22-70 years and older with either gender
- Fracture in humerus diaphysis from 5cm below the surgical neck and 10cm above the olecranon fossa.
- Polytrauma patients.
- Fresh and closed fractures with inability to maintain closed reduction. (operated within 3 weeks)

- Grade I & II compound fractures. (gustilo and anderson classification)
- Patient giving consent for inclusion in the study.

Excluding criteria

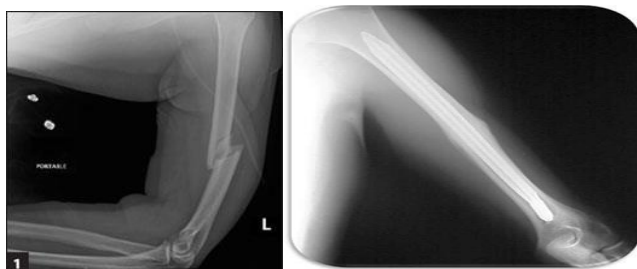- Patients having medullary canal less than 6mm in any view.
- Pathological fractures.
- Progressive neurological deficit and vascular injury and radial nerve palsy.
- All cases were followed for minimum period of 3 weeks to 3.5years

Number of cases	97
Sex	Male 70 (72%)
	Female 27 (28%)
Average age of the patient	22 to 70 for males
	20 to 60 for females
Age of Injury	70(70%) case between 4 to 8 days
	27(30%) cases 10 to 16 days
Associated co-morbid conditions	None 44(45.5%)
	Diabetes Mellitus 25(26.25%)
	IHD (10.5%)
	Both (17.5%)
Technique	Retrograde nailing 47 (48%)
	Antegrade nailing 50 (52%)
Limb side	Right 69(71%)



Surgical Technique

All nailing procedures were performed under GA and image intensifier. RHN technique

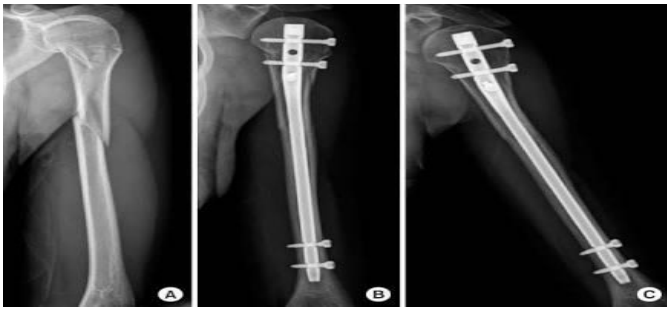

Retrograde nailing in DHF (A- pre operative, B- post operative after 6months) RHN
 Cases 47 Male 30 Female 10
 Position: Lateral Supine Approach: Posterior 2.5cm proximal to olecranon fossa. The width at this point confirmed under

image intensifier. Multiple drill holes are made on posterior cortex only to make the entry portal 1* 1.5 cm oval in shape. We have observed that the entry portal when placed more ulnarwards, roughly 60% on ulnar side when mid-line is drawn through the centre of long axis of humerus we have observed that the medullary cavity is more roomier on the ulnar side and in radial side cortex is thick. An inclined slope was made to introduce the nail. Only the distal fragment was partly received for easy passing of the nail. Nail of appropriate diameter and length was inserted over a zig after receiving the closed reduction. Interlocking was done in distal fragment with the help of zig.

Proximal locking wasn't done purposefully because in one case of DHF, there was abrasions at the site of proximal screw insertion so proximal locking was avoided (to prevent infection) and it was found abundant callus formation, since then we stop proximal locking in RHN. it also reduces our surgery time.

AHN Technique



Antegrade nailing in DHF (A- pre operative, B- post operative, C- post operative after 5months) cases 50 male 40 female 17 The procedures were done in supine position with head rotated to contralateral side on radiolucent table. A longitudinal skin incision 1-3cm centered over tip of greater tuberosity was given. An awl was passed just medial to tip of greater tuberosity, 0.5cm posterior to bicipital groove to make an entry point. Reaming of proximal metaphysis of humerus to a diameter of 8mm for approximately 4cm was done. Close reduction was achieved under C-arm guidance and guide wire was passed, the length of the nail was measured by subtracting exposed guide wire from the total length of guide wire. In 2 cases, where closed reduction failed, minimum open reduction was done. While maintaining the reduction, guide wire was removed and the nail of proper length and diameter was passed till its proximal end was beneath the bone by 0.5cm to avoid subacromial impingement. Proximal and distal locking was done.

ASES American shoulder and elbow Surgeon's score End results were evaluated as per ASES American shoulder and elbow Surgeon's score for 13 activities of daily living requiring full shoulder and elbow movements.

score graded as: 4- normal 3- mild compromised 2- difficult 1- with aid 0- unable Maximum possible score is 52 points.

The 13 activities are- 1Back pocket, 2Wash opposite axilla, 3Comb hair, 4Carry 10lbs at side, 5Sleep on affected side, 6Use hand overhead, 7Lift, 8Perineal care, 9Eat with utensil, 10.use arm at shoulder level, 11Dress, 12Pull, 13Throw Pain was quantified using visual analogous scale with 0 being no pain and 10 being extreme pain. Two tailed T-test revealed no significant difference in pain ($p=0.574$) or ASES score ($p=0.713$)

Results

In all 97 patients reduction was good. The average hospital stay was 4-8 days with range of 3- 18 days. We had no post-operative infection. Majority of patients were followed for 36 months. 6 patients were lost for follow-up at various periods after 28 months. Even in those 6 patients fracture was united and they were carrying daily activities with full range of motion of shoulder and elbow. 66 patients united within 12 weeks (31 RHN and 35 AHN) & 28 patients united at 16 weeks (14 each RHN and AHN). 2 out of poly trauma patients were united in 20 weeks. Only one fracture did not unite (underwent AHN) which was attributed to initial distraction at fracture site. The most common complication in AHN was shoulder stiffness (8 out of 50), shoulder impingement (2 out of 50) and non- union (1 out of 50), radial nerve neurapraxia (3 out of 50) and in RHN, radial nerve neurapraxia (1 out of 47; recovered within 6-12 weeks) and terminal limitation of elbow range of motion (2 out of 47; assessed objectively) was present.

78 cases (37 RHN & 41 AHN) returned to daily routine work within 6-8 weeks post-operatively without any minimal discomfort.

Discussion

Fracture of shaft of humerus are more common in age groups specially in adults and middle aged. There is need for early active mobilization for rapid bone healing.

None of our patient developed secondary infection or deep seated or superficial skin infection. Most of our series fractures unite within 6-12 weeks, average being 8 weeks. Two cases (of AHN) develop elbow stiffness for short duration and improved with physiotherapy. One case (of RHN) found to have occult uni-cortical micro fracture extending up to distal lock but the screw has not loosened as it had a fine purchase in the far cortex and went on healing. This occult fracture was noticed in immediate post- operative x-ray. One patient developed non-union which we attribute to distraction at fracture site. We believe that distraction at fracture site may be prevented during AHN by pushing or thumping at elbow after proximal locking. Once the distraction and rotations are corrected by thumping, distal locking should be done.

Persistent pain after AHN nailing has been a problem in various studies. We concur with the established findings that this problem can be reduced by meticulous dissection, proper repair of rotator cuff. 6 of the patients (underwent AHN) had persistent pain in shoulder in final follow up. However, with RHN will preserve good shoulder function.

Vulnerable structures around the shoulder that could be injured during AHN include the axillary nerve, the circumflex artery, the long head of biceps, and the deltoid. These structures are usually injured by the proximal locking bolts, and modern targeting devices have not abolished this complication 14-19.

RHN is a technically demanding procedure. With patience and gradual learning curve it can be very rewarding in the outcome for the patient and to the operating surgeon professionally with gratifying results. It has all the advantages of locked nails. Lin J reported that in spiral fractures with lateral spike, the radial nerve may be entrapped in fracture site with or without radial nerve palsy 20. He emphasized the importance of nerve exploration in such a situation. We used unreamed nails achieved 96% of union rate and also avoided the possible damage to radial nerve during reaming. We infer that reaming could cause severe radial nerve damage in closed nailing that can be avoided by using unreamed nail.

Conclusion

IMIL nailing give advantages in the treatment of diaphyseal fractures of the femur and tibia but it has not yet produced similar results in the upper limb so Conservative management was the treatment of choice for DHF in elderly. The nail allows minimally invasive approach in less complicated fractures; in case of complex fractures, it allows for bridging of the fracture site. It also provides stable fixation, which prevents pains and increases significantly the possibility of good fracture healing. In addition to this, physical therapy can start earlier, which prevents joint stiffness. A useful guideline that could improve the results of IMIL nailing in the management of DHF is that a 'fixed' nail can be inserted with both antegrade and retrograde techniques regardless of the fracture pattern and location. The choice of approach to the medullary canal depends on the type and position of the fracture, patient's condition, and skill and

affinities of the surgeon. During operative procedure, special attention should be paid to maintain proper reduction and stable fixation, as well as to preservation of neurovascular structures. On the contrary, fracture location could play an important role in the usefulness of nails as these nails are more effective if their entry portal (antegrade or retrograde technique) is closer to the fracture site.

Retrograde nailing had better preoperative and postoperative parameters like fracture healing rate and time to healing. The learning curve is long but after the technique has been completely mastered by the surgeon, the reward is successful and quick healing of the fracture, early mobilization and patient's satisfaction. We concluded that in RHN, excellent union takes place with excellent callus formation with full range of motion at shoulder and elbow without any pain.

	RHN	AHN
Benefits	No shoulder and elbow joint involvement	

	Less time consuming (as proximal locking can be spared)	
limitations	Long learning curve Posterior cortical break Limitation of elbow range of motion	Shoulder impingement (rotator cuff injury) Shoulder stiffness Nerve injury (axillary/radial)

References

1. Brumback RJ. The rationales of interlocking nailing of the femur, tibia, and humerus. *Clin Orthop Relat Res.* 1996; 324:292-320. doi: 10.1007/s00132-008-1376-4.
2. Wallny T, Sagebiel C, Westerman K, Wagner UA, Reimer M. Comparative results of bracing and interlocking nailing in the treatment of humeral shaft fractures. *Int Orthop.* 1997; 21:374-9. doi:10.1302/0301-620X.90B1.19215.
3. Watanabe RS. Intramedullary fixation of complicated fractures of the humeral shaft. *Clin Orthop Relat Res.* 1993; 292:255-63.
4. Farragos AF, Schemitsch EH, McKee MD. Complications of intramedullary nailing for fractures of the humeral shaft: a review. *J Orthop Trauma.* 1999; 13:258-67. doi:10.1302/0301-620X.90B1.19215.
5. Hems TE, Bhullar TP. Interlocking nailing of humeral shaft fractures: the Oxford experience 1991 to 1994. *Injury.* 1996; 27:485-9.
6. Stern PJ, Mattingly DA, Pomeroy DL, Zenni EJ Jr, Kreig JK. Intramedullary fixation of humeral shaft fractures. *J Bone Joint Surg Am.* 1984; 66:639-46. doi: 10.4103/0019-5413.33685.
7. Brumback RJ, Bosse MJ, Poka A, Burgess AR. Intramedullary stabilization of humeral shaft fractures in patients with multiple trauma. *J Bone Joint Surg Am.* 1986; 68:960-9.
8. Robinson CM, Bell KM, Court-Brown CM, McQueen MM. Locked nailing of humeral shaft fractures. Experience in Edinburgh over a two-year period. *J Bone Joint Surg Br.* 1992; 74:55862
9. Riemer BL, D'Ambrosia R, Kellam JF, Butterfield SL, Burke CJ. 3rd. The anterior acromial approach for antegrade intramedullary nailing of the humeral diaphysis. *Orthopedics.* 1993; 16:1219-23.
10. Henley MB, Chapman JR, Claudi BF. Closed retrograde Hackethal nail stabilization of humeral shaft fractures. *J*

- Orthop Trauma. 1992; 6:18-24.
11. Rommens PM, Verbruggen J, Broos PL. Retrograde locked nailing of humeral shaft fractures. A review of 39 patients. *J Bone Joint Surg Br.* 1995; 77:84-9.
12. Blum J, Rommens PM, Janzing H. The unreamed humeral nail – a biological osteosynthesis of the upper arm. *Acta Chir Belg.* 1997; 97:184-9.
13. Garnavos C, Lasanianos N, Kanakaris NK, Arnaoutoglou C, Papathanasopoulou V, Xenakis T. A new modular nail for the diaphyseal fractures of the humerus. *Injury.* 2009; 40:604-10. doi: 10.1016/j.injury.2009.01.130.
14. Evans PD, Conboy VB, Evans EJ. The Seidel humeral locking nail: an anatomical study of the complications from locking screws. *Injury.* 1993; 24:175-6.
15. Albritton MJ, Barnes CJ, Basamania CJ, Karas SG. Relationship of the axillary nerve to the proximal screws of a flexible humeral nail system: an anatomic study. *J Orthop Trauma.* 2003; 17:411-4.
16. Lögters TT, Wild M, Windolf J, Linhart W. Axillary nerve palsy after retrograde humeral nailing: clinical confirmation of an anatomical fear. *Arch Orthop Trauma Surg* 2008; 128:1431-5.
17. Lin J, Hou SM, Inoue N, Chao EY, Hang YS. Anatomic considerations of locked humeral nailing. *Clin Orthop Relat Res* 1999; 368:247-54.
18. Riemer BL, D'Ambrosia R. The risk of injury to the axillary nerve, artery, and vein from proximal locking screws of humeral interlocking nails. *Orthopedics.* 1992; 15:697-9.
19. Prince EJ, Breien KM, Fehringer EV, Mormino MA. The relationship of proximal locking screws to the axillary nerve during antegrade humeral nail insertion of four commercially available implants. *J Orthop Trauma* 2004; 18:585-8
20. Lin J, Shen PW, Hou SM. Complications of locked nailing in humeral shaft fractures. *J Trauma.*2003; 54:943-9
21. Remiger AR, Miclau T, Lindsey RW, Blatter G. Segmental avascularity of the humeral diaphysis after reamed intramedullary nailing. *J Orthop Trauma.* 1997; 11:308-11. doi: 10.1097/TA.0b013e31812eed7f.