



International Journal of Orthopaedics Sciences

ISSN: 2395-1958
IJOS 2017; 3(4): 357-360
© 2017 IJOS
www.orthopaper.com
Received: 26-08-2017
Accepted: 29-09-2017

Dr. Sasi Kuppaswamy
RIMS hospital Erattupetta
Kerala, India

Dr. James C George
MS Ortho, Assistant Professor,
Believers Church Medical College
Hospital, Thiruvalla, Kerala,
India

Dr. Mili Chemmanam
DMRD, DnB Radiology
MGM Muthoot Medical Centre
Pathanamthitta, Kerala, India

Prevalence of lumbar disc herniation and disc degeneration in asymptomatic Indian subjects: An MRI based study

Dr. Sasi Kuppaswamy, Dr. James C George and Dr. Mili Chemmanam

DOI: <https://doi.org/10.22271/ortho.2017.v3.i4e.50>

Abstract

Background: India is a country with a huge human resource been utilised for labour and also is a country of diversity in culture and religions. Thus we have numerous activities which involve bending and twisting of the spine. Therefore we expect more disc degeneration and disc herniation compared to the western world. Indian health care system has traditional medicine and modern medicine. Both systems has easy access to Magnetic Resonance Imaging (MRI) which in fact will display both physiological and pathological changes. This may miss-lead a less experienced health worker and can also create a bad mental impact on an otherwise normal individual.

Aim: Analyse the prevalence of lumbar disc degeneration and herniation in asymptomatic Indian subjects using MRI

Materials and Methods: this was an observational study where we selected subjects without any low back related symptoms and signs and allowed them to undergo lumbar spine screening using a 0.2 tesla machine.

Results: We had 76 subjects with a mean age of 43.7 and studied 380 discs in 4 different age groups. Among disc herniation 273 discs (71.8%) were normal and 107 discs (28.2%) had pathological changes in the form of bulge 68(17.8%), protrusions 30(7.8%) and extrusions 9(2%). None of the subjects had sequestration. Among disc degeneration 256(67.3%) were Grade 1& 2 and 124 (32.7%) were Grade 3, 4&5. In the 76 subjects 37% had disc herniation and 33% had grade 3, 4 and 5 degeneration.

Conclusion: The high prevalence of disc degeneration and disc herniation in MRI of normal subjects, emphasize the value of clinical history and clinical evaluation before starting precious treatment.

Keywords: disc degeneration, herniation, MRI, asymptomatic subjects

Introduction

According to literature, the prevalence of lumbar pain at one time point was approximately 30-40% in Germany. The one year and lifetime prevalence was approximately 60-70% and more than 80%, respectively [1]. In a study from Korea the prevalence of disc herniation, annular fissure and disc degeneration in asymptomatic subjects were 81.4%, 76.1%, and 75.8% respectively [2]. The disc degeneration and herniation can be physiological, mechanical or both. The load on the lumbar disc in a sitting position and in a standing position with 20 degrees of flexion can reach upto 250% of body weight [3, 4]. A combined lateral bend, flexion, and axial rotation vibration loading could cause tracking tears proceeding from the nucleus through the posterolateral region of the annulus suggesting that mechanism for disc herniation is mechanical leading to instability of the motion segment [5].

In India we have numerous activities which involve bending and twisting of the spine. The religious postures, floor sitting for eating food, squatting in an Indian toilet and cleaning the floors are some among them. Due to these reasons there is a possibility for more asymptomatic disc degeneration and herniation in Indian population compared to that of the West. Unfortunately there is no Indian data available in the literature. MRI will display both physiological and pathological changes which may miss-lead a less experienced health worker and can also create a bad mental impact on an otherwise normal individual. Given this background, the authors attempted to analyze the prevalence of lumbar disc degeneration and herniation in asymptomatic Indian subjects.

Correspondence

Dr. James C George
MS Ortho, Assistant Professor,
Believers Church Medical College
Hospital, Thiruvalla, Kerala,
India

Materials and Methods

Institutional ethical committee approval was obtained before the initiation of the study. Informed consent was taken from every subject. People who visited the hospital from January 2015 to December 2015 between 20 -60 years were screened by the public relations team. All the healthy subjects were screened by the second author through a questionnaire enquiring for history of back pain, leg pain and claudication, paraesthesia of legs and weakness of lower limb muscles.

Asymptomatic subject was defined as one with a negative answer to the questionnaire and have never seen a physician, physiotherapist, chiropractor, acupuncture, traditional herb medication (ayurveda), or other such health care professional, and have never missed a workday due to low back ache and related symptoms in the past. The rationale for these criteria was the notion that episodes of transient back pain are very common and less likely to be recalled after spontaneous regression [6]. Cases in which hospitalization treatment was administered for trauma such as a traffic accident were also excluded, because trauma required hospitalization may have undetected lumbar diseases.

Patients under went MRI using a GE 0.2Tesla sigma profile 4 Dmachine. Five sagittal images (two right sides and one midline and two left side) were taken using T2 sequences. Images are reported by the co-author. Teleradiology by Mediff technology was utilized for visualizing the images using the installed software. MRI images were analyzed for disc herniation and disc degeneration. Disc herniation was classified into disc bulge, disc prolapse, disc extrusion and disc sequestration based on intactness of posterior longitudinal ligament. Disc degeneration was classified as per Pfirrmann grading into 5 grades in T2 weighted images [7]. Grade 1 disc is hyper intense to cerebrospinal fluid, grade 2 isointense to cerebrospinal fluid, grade 3 intermediate, grade 4 intermediate to hypo intense and grade 5 hypo intense to cerebrospinal fluid.

Total number of normal individuals participated in study was distributed into 4 age groups as A) 20-29, B) 30-39, C) 40-49 and D) 50-60 and 5 levels (L1L2, L2L3, L3L4 and L5S1). Data were entered in Microsoft Excel and analysis was

performed using SPSS statistical program version 21.0. Simple proportions were done for all there levant variables and assessment for prevalence of disc degeneration and herniation. There is no external funding for the study and there is no conflict of interest among the authors.

Results

Among the 120 individuals screened, 76 were eligible for the asymptomatic criteria. There were 31 males and 45 females. Mean age was 43.7 with a standard deviation of 11.4 (Table 1). The maximum participation was in the age group 50–60 years. In each patient 5 levels were assessed. Therefore a total number of 380 discs were evaluated for disc degeneration and herniation. Among disc degeneration 256 (67.3%) were Grade 1 & 2 and 124 (32.7%) were Grade 3, 4 & 5. Among disc herniation 273 discs (71.8%) were normal and 107 discs (28.2%) had pathological changes in the form of bulge 68 (17.8%), protrusions 30 (7.8%) and extrusions 9 (2%). None of the subjects had sequestration (Table 2).

Among the 76 subjects evaluated 67% had grade 1 and 2 degeneration and 33% had grade 3, 4 and 5 degeneration. In Group A (20-29) it was 82% and 18%, in Group B (30-39) 74.5% and 25.5%, in Group C (40-49) 74% and 26% and in Group D (50-60) 53% and 47% respectively. In the 76 subjects 63% had no herniations at all while remaining 37% had some herniations at one or more disc levels. In Group A, 21% had disc bulge while 13% had protrusions. In Group B it was 19% and 9% respectively. In Group C 26% had bulge, 8% had protrusion and 4% had extrusion. In Group D it was 20%, 12% and 7% respectively. The number of patients in each group is shown in (Table 3).

Among the subjects more than 40 years 38% had grade 3, 4 or 5 degeneration and 38% had some form of herniation. Since there were more females in the study than males, sex distribution for prevalence of degeneration and herniation was not compared. Levels for grade 3, 4, and 5 degeneration were L1L2 (3%), L2L3 (7.2%), L3L4 (24%), L4L5 (29%) and L5S1 33% while that for herniations were L1L2 (0%), L2L3 (1.8%), L3L4 (20%), L4L5 (39%) and L5S1 (40.9%) (figure 1 & 2).

Table 1: Demographic Data

| Age | Number | Male | Female | Mean |
|----------|--------|------|--------|------|
| A(20-29) | 15 | 6 | 9 | 27.5 |
| B(30-39) | 11 | 3 | 8 | 39.8 |
| C(40-49) | 24 | 11 | 13 | 49.7 |
| D(50-60) | 26 | 10 | 16 | 57.9 |
| Total | 76 | 31 | 45 | 43.7 |

Table 2: Prevalence in various disc levels

| Level | Grade 1-2 | Grade 3-4 | Grade 5 | Normal | Bulge | Protrusion | Extrusion | Sequestration |
|-------|-----------|-----------|---------|--------|-------|------------|-----------|---------------|
| L1 L2 | 72 | 4 | 0 | 76 | 0 | 0 | 0 | 0 |
| L2L3 | 67 | 9 | 0 | 74 | 1 | 0 | 1 | 0 |
| L3L4 | 46 | 30 | 0 | 55 | 18 | 3 | 0 | 0 |
| L4L5 | 38 | 36 | 2 | 35 | 28 | 9 | 4 | 0 |
| L5S1 | 33 | 41 | 2 | 33 | 21 | 18 | 4 | 0 |
| Total | 256 | 120 | 4 | 273 | 68 | 30 | 9 | 0 |

Table 3: Prevalence in different age groups

| Age | Grade1-2 | Grade3-5 | Normal | Bulge | Protrusion | Extrusion | Sequestration |
|-------|----------|----------|--------|-------|------------|-----------|---------------|
| 29-29 | 12 | 3 | 10 | 3 | 2 | 0 | 0 |
| 30-39 | 8 | 3 | 7 | 2 | 1 | 1 | 0 |
| 40-49 | 17 | 7 | 15 | 6 | 2 | 1 | 0 |
| 50-60 | 14 | 12 | 16 | 6 | 3 | 1 | 0 |
| total | 51 | 25 | 48 | 17 | 8 | 3 | 0 |

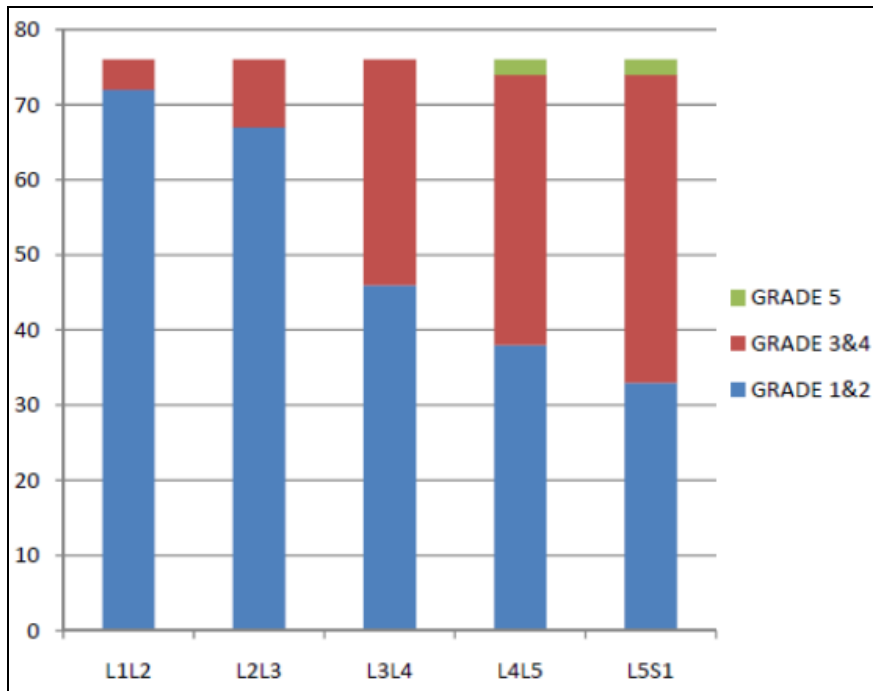


Fig 1: Grades of disc degeneration at various levels (y axis: number of subjects)

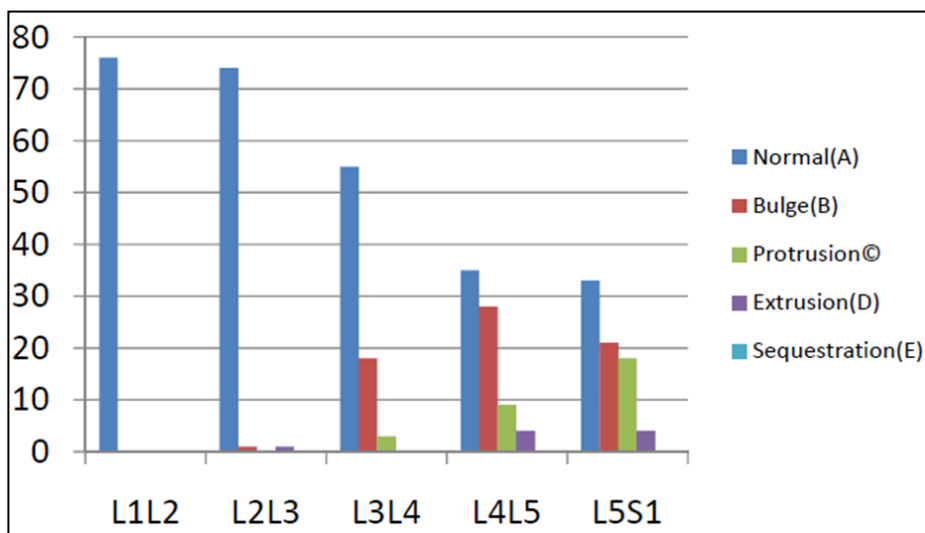


Fig 2: Types of herniation at various levels(y axis: number of subjects)

Discussion

Intervertebral discs (IVDs) are pads of fibrocartilage which lie between the vertebrae of the spine. They allow the vertebral column to bend and twist and distribute compressive loading on the adjacent vertebral bodies [8]. A motion segment consists of two vertebrae and an IVD. The IVD has three main components: a soft, deformable, nucleus pulposus, which is surrounded by the fibrous concentric layers of the anulus fibrosus, and bonded above and below to adjacent vertebral bodies by the thin layers of the cartilaginous end plates. The

fiber orientation of the anulus fibrosus is suitable to resist hoop stresses generated by the hydrostatic pressure of nucleus pulposus in the healthy conditions.

Degenerative process is thought to start in the nucleus pulposus, exhibiting a decrease in its proteoglycan concentration [9, 10] and gradual change in Type 1 collagen into a more fibrotic Type 2 collagen [11]. The arrangement of the elastic fibers plays a very important role in the overall mechanical properties of the anulus fibrosus [12] Elastic anisotropy in the anulus is maintained with degeneration, with

posterolateral and outer lamellae regions having decreases of about 30–50% with advancing degeneration [13]. When degeneration is combined with extreme and constant spine movements it can end up in disc herniation.

In India unlike western world we still rely on human labour than mechanical devices. Indian women will start her day with cleaning house with broom, milking a cow, cooking in traditional stoves fuelled by wood and cleaning the utensils by sitting on the floor. Western toilet is not used in the most places of country and squatting for bowel and bladder movement are common. Even though India has various religions and customs, almost all of them have long sitting hours either with crossed leg or kneeling or bowing etc. India being one among largest agricultural country in the world is still not modernised and depends on human labour which also tears down the back. All though India is developing rapidly with technology and mechanics, we still use manual devices for changing a punctured tube, cutting tree, digging for pipes etc where in western world it is automated or semi-automated. As we know Indian is not only has diversity of religions, customs and cultures we also know we have variety of treating option right from allopathy, ayurveda, siddha, homeopathy, unnnani, acupuncture etc having their own advantage and disadvantages. Everyone has power to choose any investigation as part of their treatment programme. MRI is easily available to all these practitioners who will be blindly following the report mentioned by the radiologist.

The radiologist may not have any clinical details most of the time and would be reporting by seeing the images alone. This ends up in either over treating an otherwise normal individual. Therefore this study aimed at finding out the prevalence of lumbar disc degeneration and herniation in Indian asymptomatic subjects is very relevant.

Western literature from United States, Europe and Korea shows prevalence of disc herniation and degeneration from 27% to 84% in various age groups [2, 15, 16, 17, 18]. Pfirrmann grading of degeneration considers grade 1 and 2 as normal [7]. Therefore in our study 67.3% of disc degenerations were normal. Of the 32.7% degenerated discs and 28.2% herniated discs none had any low back symptoms. As in multiple studies mentioned, when age advances degenerative changes increases, so also in our study the degeneration which was seen in 18% of Group A increased to 47% in Group D. Among 37% of asymptomatic people who had herniated discs in the MRI the maximum numbers belonged to the extremes of ages that is Group A and D. Asymptomatic disc bulges and protrusions followed the same pattern while extrusions were noticed more as age advanced, that is in Group C and D. Asymptomatic sequestered disc was not seen in any patients in our study as well as in Western literature. While other studies demonstrated more degeneration and herniation at L4L5 level our study showed more changes in L5S1 level.

The high prevalence of disc degeneration and disc herniation in MRI of normal subjects, emphasize the value of clinical history and clinical evaluation before starting precious treatment. There is no difference in statistics of MRI findings of asymptomatic western population and Indian population except in the spinal level in spite of gross variation in life style and habits.

References

1. Wenig CM, Schmidt CO, Kohlmann T, Schweikert B. Costs of back pain in Germany. *Eur J Pain*. 2009; 13:280-286.
2. Sang Jin Kim, Ph.D. MD, Tae Hoon Lee, MD, Ph.D. Soo

- Mee Lim, MD. Ph.D. Prevalence of Disc Degeneration in Asymptomatic Korean Subjects. Part 1: Lumbar Spine *J Korean Neurosurg Soc*. 2013; 53(1):31-38.
3. Nachemson A. The load on lumbar disks in different positions of the body. *Clin Orthop Relat Res*. 1966; 45:107.
4. Nachemson A. Mechanical stresses on lumbar disks. *Curr Pract Orthop Surg*. 1966; 3:208.
5. Wilder DG, Pope MH, Frymoyer JW. The biomechanics of lumbar disc herniation and the effect of overload and instability. *J Spinal Disord*. 1988; 1(1):16-32.
6. Boos N, Rieder R, Schade V, Spratt KF, Semmer N, Aebi M. Volvo Award in clinical sciences. The diagnostic accuracy of magnetic resonance imaging, work perception, and psychosocial factors in identifying symptomatic disc herniations. *Spine (Phila Pa 1976)*, 1995; 20:2613-2625.
7. Pfirrmann C, Metzdorf A, Zanetti M, Hodler J, Boos N. Magnetic resonance classification of lumbar intervertebral disc degeneration. *Spine (Phila. Pa. 1976)*. 2001; 26:1873-1878
8. Humzah MD, Soames RW. Human intervertebral disc: structure and function. *Anat. Rec*. 1988; 220:337-356.
9. Adams MA, Roughley PJ. What is intervertebral disc degeneration, and what causes it? *Spine (Phila. Pa. 1976)*. 2006; 31:2151-2161.
10. Roughley PJ. Biology of intervertebral disc aging and degeneration: involvement of the extracellular matrix. *Spine (Phila Pa 1976)*. 2004; 29:2691.
11. Coventry MB, Ghormley RK, Kernohan JW. The Intervertebral Disc: Its Microscopic Anatomy and Pathology: Part I Anatomy, Development, and Physiology. *J Bone Joint Surg Am*. 1945; 27:105.
12. Haefeli M, Kalberer F, Saegesser D, *et al*. The course of macroscopic degeneration in the human lumbar intervertebral disc. *Spine (Phila Pa 1976)*. 2006; 31:1522.
13. Smith LJ, Fazzalari NL. The elastic fibre network of the human lumbar anulus fibrosus: architecture, mechanical function and potential role in the progression of intervertebral disc degeneration. *Eur Spine J*. 2009; 18:439.
14. Acaroglu ER, Iatridis JC, Setton LA, *et al*. Degeneration and aging affect the tensile behavior of human lumbar anulus fibrosus. *Spine (Phila Pa 1976)*. 1995; 20:2690.
15. Jensen MC, Brant-Zawadzki MN, Obuchowski N, Modic MT, Malkasian D, Ross JS. Magnetic resonance imaging of the lumbar spine in people without back pain. *N Engl J Med*. 1994; 331(2):69-73.
16. Borenstein DG1, O'Mara JW Jr, Boden SD, Lauerman WC, Jacobson A, Platenberg C, *et al*. The value of magnetic resonance imaging of the lumbar spine to predict low-back pain in asymptomatic subjects: a seven-year follow-up study. *J Bone Joint Surg Am*. 2001; 83(9):1306-11.
17. Alyas F1, Turner M, Connell D. MRI findings in the lumbar spines of asymptomatic, adolescent, elite tennis players. *Br J Sports Med*. 2007; 41(11):836-41.
18. El Barzouhi A1, Vleggeert-Lankamp CL2, Lycklama à Nijeholt GJ3, Van der Kallen BF3, van den Hout WB4, Koes BW5, *et al*. Leiden–The Hague Spine intervention Prognostic Study Group. Reliability of gadolinium-enhanced magnetic resonance imaging findings and their correlation with clinical outcome in patients with sciatica. *Spine J*. 2014; 14(11):2598-607.