International Journal of Orthopaedics Sciences

ISSN: 2395-1958
IJOS 2017; 3(4): 274-284

www.orthopaper.com
Received: 21-08-2017
Accepted: 25-09-2017

Dr. A Suchinder
Assistant professor, Department of Orthopaedics Melmaruvathur adhiparasakthi institute of medical college science hospital and Research Institute, GST road, melmaruvathur, Tamil Nadu, India

Dr. K Chittaranjan
Associate professor, Department of Orthopaedics Melmaruvathur adhiparasakthi institute of medical college science hospital and Research Institute, GST road, melmaruvathur, Tamil Nadu, India

Dr. D Venkatesh
Senior resident, Department of Orthopaedics Melmaruvathur adhiparasakthi institute of medical college science hospital and Research Institute, GST road, melmaruvathur, Tamil Nadu, India

Correspondence
Dr. A Suchinder
M.S. (Orthopedics)
Assistant Professor, Department of Orthopedics, Government Medical College, Haldwani, Uttarakhand, India

A study of functional outcome of correction of cubitus varus deformity by stepcut translation osteotomy

Dr. A Suchinder, Dr. K Chittaranjan and Dr. D Venkatesh

DOI: https://doi.org/10.22271/ortho.2017.v3.i4d.40

Abstract
Objective

- To analyse the cosmetic and functional outcome of correction of cubitus varus deformity in adolescents and adults by step cut translation osteotomy.
- To analyse the amount of varus deformity correction obtained.
- To analyse the amount of correction of Lateral condyle prominence obtained.
- To analyse the post-operative arc of motion and the difference in the post-operative range of motion in comparison with the pre-operative range.
- To analyse the associated complications, and
- To come to a conclusion as to the efficacy of the procedure.

Keywords: cubitus varus, deformity, osteotomy, restabilization

Introduction

"The difficulties experienced by surgeons in making an accurate diagnosis; the facility with which serious blunders can be made in prognosis and treatment; and the fear shared by so many of the subsequent limitation of function, serve to render injuries in the neighbourhood of the elbow less attractive than they might otherwise have proved.

"These words of wisdom by Sir Robert Jones echoed the opinion of many others at the beginning of 20th century [1] and these concerns are applicable even today.

Supracondylar fracture of the humerus is the most common elbow injury in childhood. Nerve injury or vascular insufficiency may be associated with the injury [15]. But, cubitus varus (Gunstock deformity/Bow elbow) is the most common long term complication following supracondylar fractures of the humerus and distal humeral medial physeal injuries in children. This complication is associated more with conservative treatment of displaced supracondylar fractures. It has been found that even undisplaced supracondylar fractures lead onto a varus deformity later. In India, the prevalence of traditional bone setters who widely practice non-operative management consisting immobilization of the injuries using cloth, raw egg, bamboo sticks etc. Thus incidence of mal-united supracondylar fractures seems to be a lot higher than compared to the western developed world. The reported incidence varies from 9% to 58% according to various modalities of treatment. In the last century, many methods of treatment of this mal-union have been described, the number indicating that each method has its own flaws and limitations.

Fig 1: Anatomical Specimen of cubitus varus

The three basic components of this deformity are horizontal rotation, coronal (varus) tilt and anterior angulation. Smith proved that varus tilting of the distal fragment was the most important cause of change in the carrying angle and also showed that rotation of the distal fragment does not cause cubitus varus, but is the most important factor leading to medial tilt [2]. Labelle *et al*. found varus tilting of the distal fragment to be the cause of deformity in all of their patients with cubitus varus after supracondylar fracture [3].

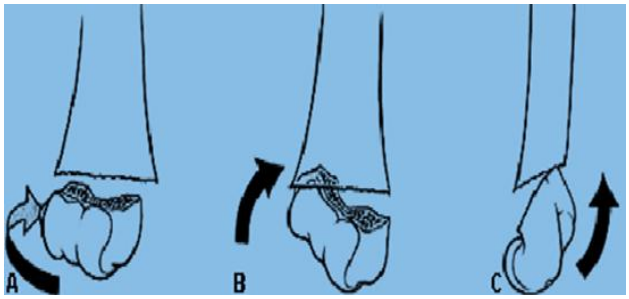

Fig 2: The three deformities of cubitus varus

A: Internal rotation of the distal fragment B: Varus angulation of the distal fragment C: Hyperextension

Growth disturbance in the distal humerus, especially overgrowth of the lateral condyle, can occur. Growth disturbance as a cause of cubitus varus has largely been refuted. Despite a remarkable potential for remodeling in children, an established varus deformity has no spontaneous remodeling, the only method to correct the deformity is surgery.

Material and Methods

This is a prospective and retrospective study comprising of 15 patients with cubitus varus deformity following an old supracondylar fracture of the humerus. All the cases were treated surgically by step-cut translational osteotomy and the study was conducted at Melmaruvathur adhiparasakthi institute of medical college science hospital and Research Institute,

These patients were reviewed periodically both clinically and radiologically for a minimum period of 12 months following corrective osteotomy.

Inclusion Criteria

- Patients with cosmetically deformed elbow
- Age limit of 13-25 years

Exclusion Criteria

- Patients who have physeal injury and growth arrest

Our method of treatment

Pre-Operative Evaluation

- All patients were thoroughly evaluated from the systemic point of view and received appropriate treatment for existing co-morbidities, if present, like Bronchial asthma etc. prior to and after the surgery
- Thorough clinical examination as mentioned above was done to have a clear picture of the deformity
- Likewise, templating was done as it is the best guide to obtain exact correction during surgery

Surgical Technique

- Patients are operated under regional anesthesia
- Lateral decubitus position
- Tourniquet applied
- Parts painted and draped
- Tourniquet inflated after exsanguination with Esmarch tourniquet
- Posterior Campbell's approach (Triceps splitting approach)
- Using the template, the osteotomy site is marked
- Step-cut wedge taken
- The lateral edge of the distal fragment is moved into the apex of the proximal osteotomy site
- If present, internal rotation deformity corrected by lateral rotation of the distal fragment
- After correcting all the deformities, the carrying angle is evaluated on table in full extension of the elbow
- Once the correction is satisfactory, the osteotomy site is securely fixed with either an Asian-DCP, Recon plate or a "Y" humeral plate.
- After thorough wound wash, wound was closed in layers with drain-in-situ

Fig 3: Posterior Campbell's approach

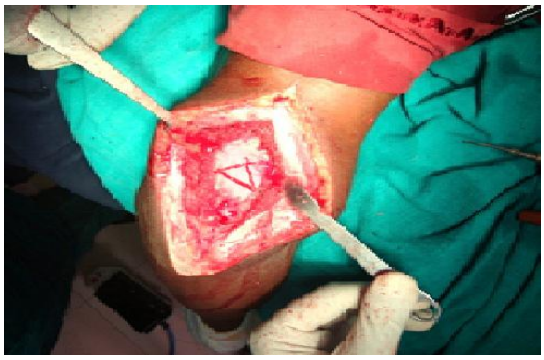

Fig 4: Step-cut wedge marked

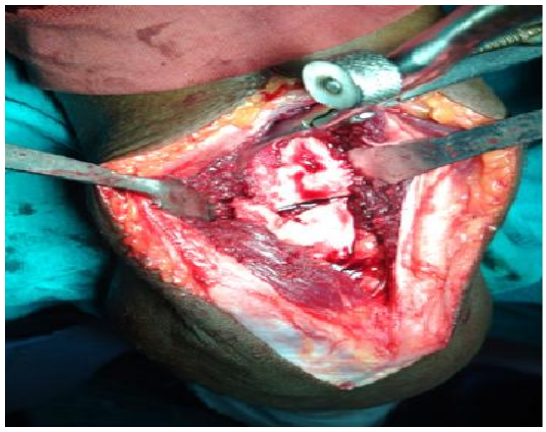

Fig 5: Translation of the distal fragment after completion of the osteotomy demonstrating the "ARM-CHAIR" effect

Fig 6: Fixation of the osteotomy with plate and screws

Postoperative Care

- Post-operatively, patient is immobilized in an Above-Elbow POP slab with the elbow in 90 degrees of flexion and forearm in mid-prone position for a period of 2-3 weeks
- Drain is removed 2-3 days after surgery
- Suture removal done usually on the 13th day
- Later, range of motion exercises are begun (both active and passive)
- Weight bearing or lifting objects were deferred until there is satisfactory radiological union and patient doesn't have any pain usually till 3 months post-surgery.

Follow Up

- Patients were followed up for a minimum period of 12 months
- Patients were assessed once in 3 weeks both clinically and radiologically
- Radiologically, sign of callus formation is noted and clinically, the improvement in the range of motion and the improvement in the prominence of lateral epicondyle were noted.
- All patients were assessed according to Flynn's criteria
- In patients who requested for the implant to be removed, it was done after consolidation of the callus was noted in the radiographs, usually not before 6 months after the primary surgery

Patient's Data

Total no. of patients: 15

Mode of injury: Supracondylar fracture of humerus (in all cases)

Age distribution: The patients were in the age group of 13-24 yrs. The average age of the patients was 18 yrs.

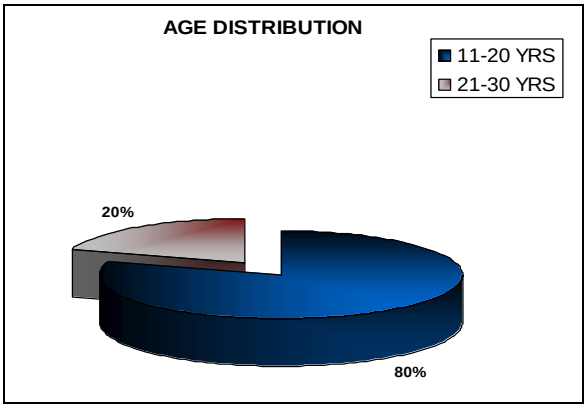

Fig 7

Sex Distribution

There were 9 male patients and 6 female patients as shown in the graph below.

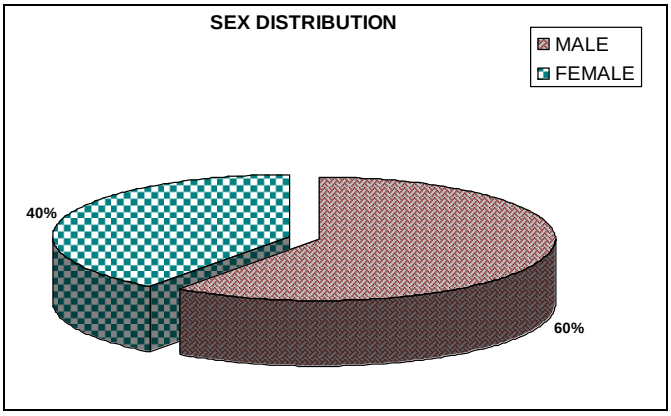

Fig 8

Side Involved

There was a minor predilection to the left side, as in 8 cases the left side was involved against 7 with the right sided involvement.

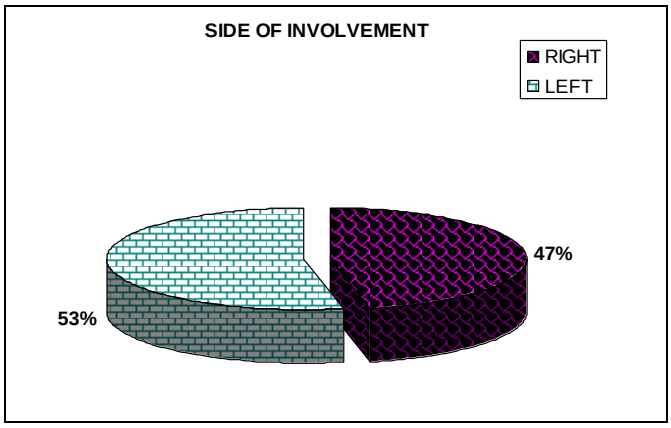

Fig 9

Time from Injury to Corrective Surgery

In our study the time between the initial fracture and the corrective procedure ranged between 6-18 years. The average time interval was 11.3 years from injury to the corrective osteotomy. 7 patients were operated between 6-10 years after the initial injury, 6 patients underwent the procedure between 11-15 years and 2 of the cases had a time interval exceeding 15 years.

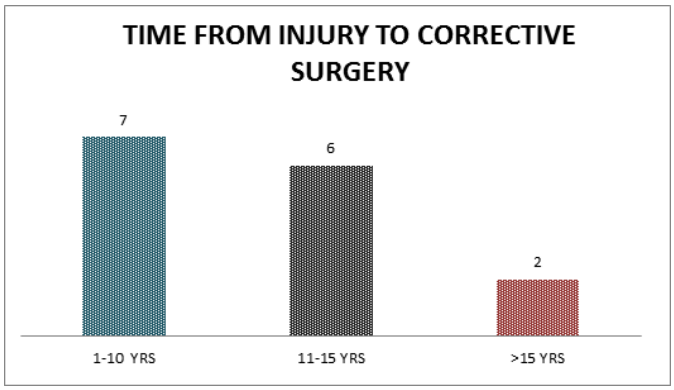

Fig 10

Duration of follow up
All our patients were followed up periodically with a minimum follow up duration of 12 months and a maximum follow up duration of 20 months.

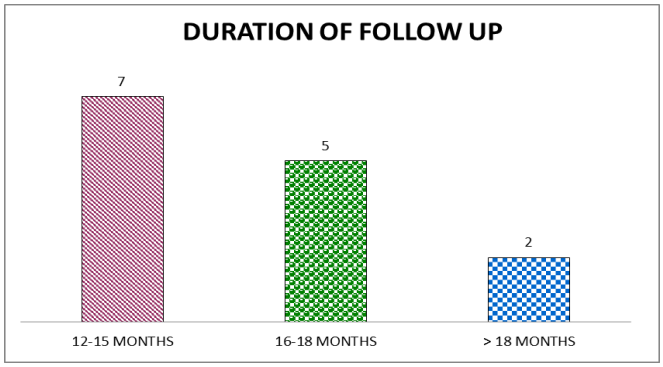

Fig 11

Scoring System
The analysis of the functional outcome after surgery was done by Flynn's criterion which is shown in the table below.

Table 1: Flynn's Criteria

Outcome	Loss In Carrying Angle {Alignment} (Degrees)	Loss In Elbow Motion (Degrees)
Excellent	0-5	0-5
Good	6-10	6-10
Fair	11-15	11-15
Poor	>15	>15

Results
The post-operative outcome was designated as Excellent, Good, Fair and Poor according to the Flynn's grading system of functional outcome of elbow.

Functional Outcome
In our study comprising of 15 patients, 8 patients (53.33%) had excellent results, 5 patients (33.33%) had good results and 2 patients (13.33%) had fair results as shown in the table and graph below.

Table 2

Results	No. of patients	Percentage (%)
EXCELLENT	8	53.33
GOOD	5	33.33
FAIR	2	13.33
Total	15	100

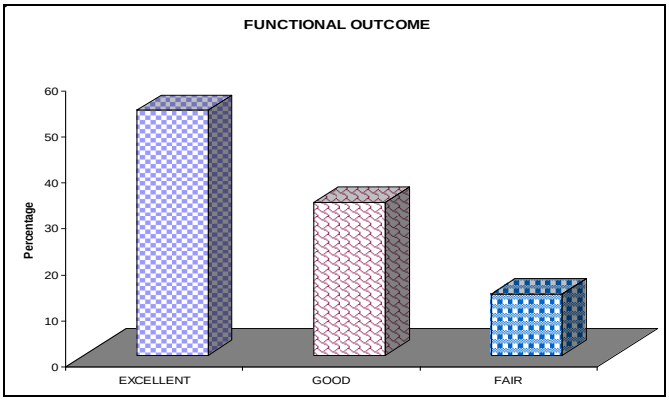

Fig 12

Time to Union
All the cases except one case (case no. 14) which had delayed union (time for union; 24 weeks) healed without any complications. The time for union in other cases was between 10-14 weeks. The mean duration of union was 12.67 weeks.

Table 3

Duration	No of cases	Percentage
10-12 WEEKS	11	73.33
13-16 WEEKS	3	20.00
>16 WEEKS	1	6.67
Total	15	100

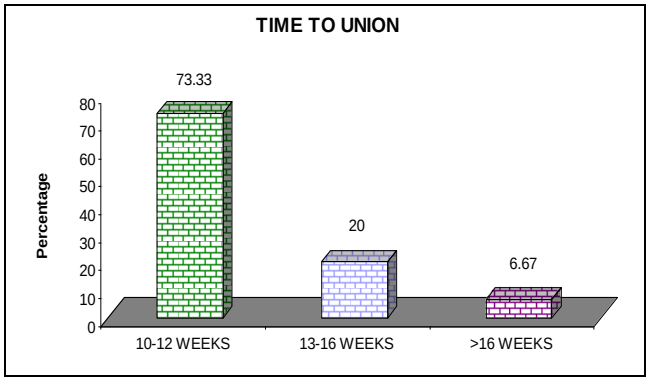

Fig 13

Post-Operative Humerus-Elbow-Wrist Angle
In our study the pre-operative varus angulation of the elbow was corrected to valgus angulation in all cases post-operatively. 7 patients had a valgus angulation of 0-5 degrees, 7 patients had a valgus angulation of 6-10 degrees and 1 case had more than 10 degrees of valgus angulation post correction. The average post-operative humerus-elbow angle was 6.13 degrees of valgus. The following graph represents the aforesaid information.

Table 4

Post-Operative HEW Angle	No of cases	Percentage
0-5 DEGREES	7	46.67
6-10 DEGREES	7	46.67
>10 DEGREES	1	6.67
Total	15	100.00

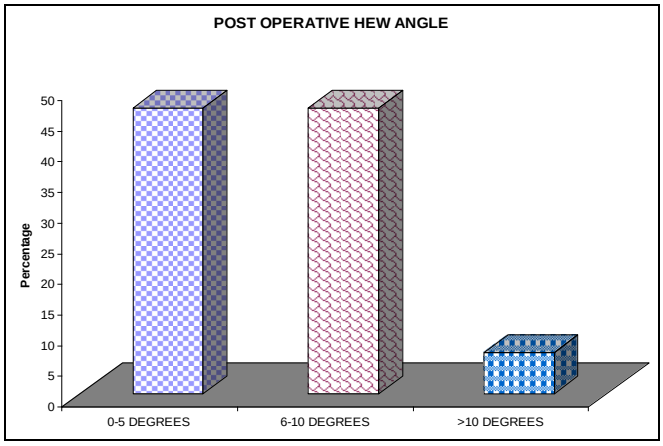

Fig 14

Difference In Hew Angles Between The Two Limbs
Also, when the difference between the humerus-elbow-wrist angles of the corrected limb and the normal limb were evaluated it was found that the difference between the two

limbs was less than 5 degrees in 8 cases and was between 6-10 degrees in 7 cases with a mean difference of 4.47 degrees between the normal and the operated limb as depicted in the graph below.

Table 5

Difference in HEW Angle	No of cases	Percentage
0-5 DEGREES	8	53
6-10 DEGREES	7	47
Total	15	100.00

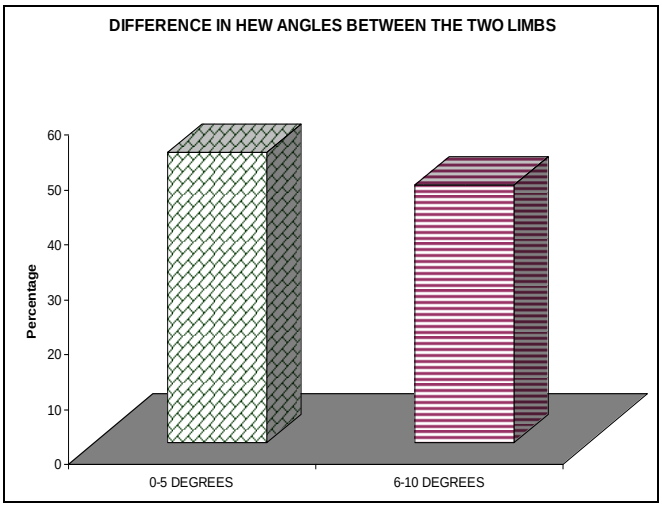

Fig 15

Range Of Motion

The post-operative range of flexion was in the range of 110-120 degrees in 4 patients and was more than 120 degrees in 11 patients with a mean 126 degrees.

Table 6

Post-operative range of Flexion	No of cases	Percentage
110-120 DEGREES	4	27
>120 DEGREES	11	73
Total	15	100.00

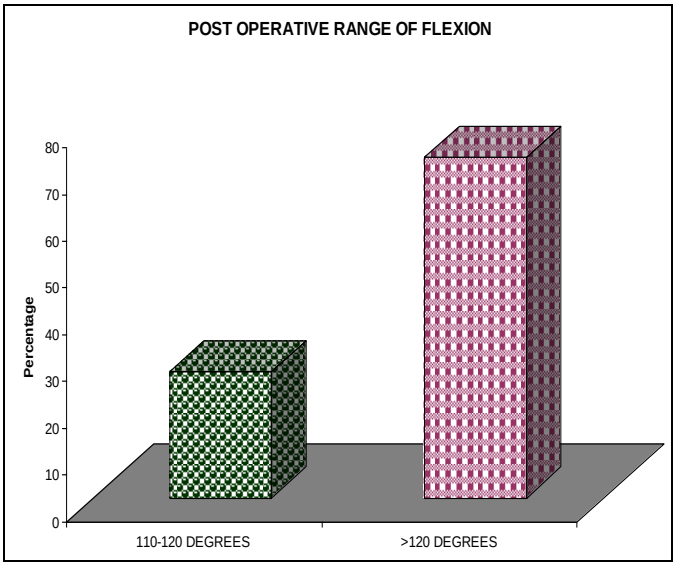

Fig 16

The post-operative range of extension was in the range of 1-10 degrees in 13 patients and 2 cases had lag in terminal extension.

Table 7

Post-Operative Range of Extension	No of cases	Percentage
0 DEGREES	2	13
1-10 DEGREES	13	87
Total	15	100.00

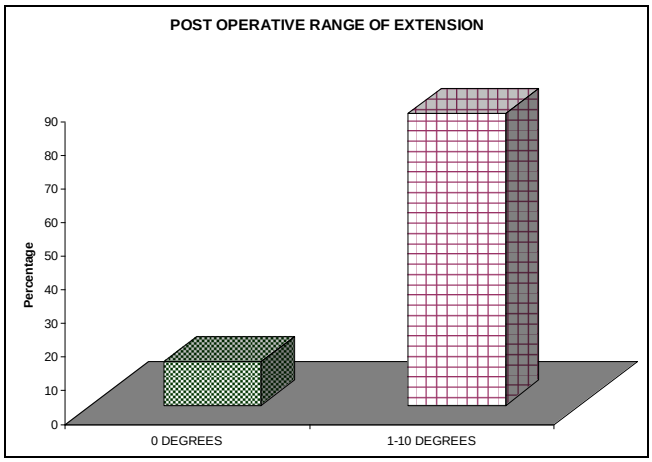

Fig 17

Difference in Range Of Motion

The difference in range of motion when compared to the pre-operative range was compared and the values are tabulated below with a graph depicting it.

Table 8

Difference in ROM (degrees)	No. of Pts	Percentage
0-5	8	53.33
6-10	5	33.33
11-15	2	13.33
TOTAL	15	100.00

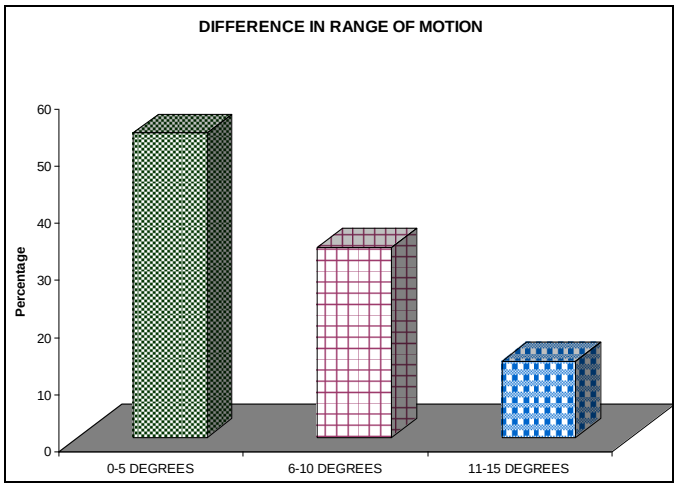

Fig 18

Post-Operative Lateral Prominence Index

In our study the range of pre-operative Lateral prominence index was 8-21%. The range of post-operative Lateral prominence index was -3 to -20%. The post-operative corrected values are tabulated below with a graph depicting it.

Table 9

Post-op LPI (%)	No. of pts	Percentage
0 to -10	10	66.67
-11 to -20	5	33.33
Total	15	100.00

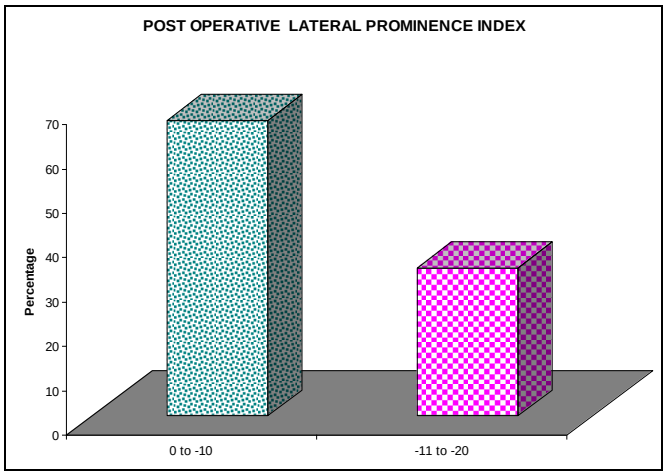

Fig 19

Amount of Correction of The Lateral Prominence Obtained Post-Operatively

The amount of correction of the lateral prominence obtained ranged between 12-38%. The values of the amount of correction is tabulated below and depicted in a graph.

Table 10

Amount of correction (%)	No. of pts	Percentage
11-20	5	33.33
21-30	7	46.67
31-40	3	20.00
Total	15	100.00

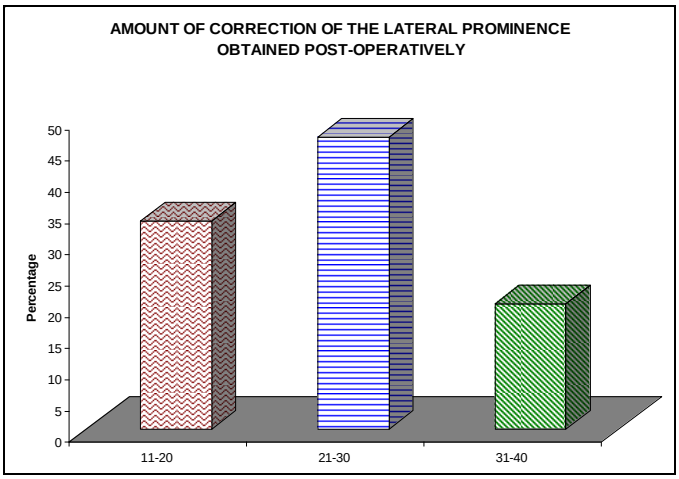

Fig 20

Complications

The various complications encountered in our study are listed in the table below.

Table 11

Type of complication	No. of patients	Case no.
Extensor Lag	2	7, 14
Implant failure	1	7
Re-surgery	1	7
Delayed union	1	14

Discussion

Cubitus varus deformity after supracondylar fracture of the humerus is typically the result of a mal-union and not due to disturbance in growth which will neither correct nor progress with time. Though there is a controversy regarding the indications for surgical correction of this deformity, many of them have recommended early surgical intervention once the fracture has united and elbow motion has been restored [16].

Since Siris first described a lateral closing wedge osteotomy [4] in 1939 for the correction of cubitus varus deformity, various types of osteotomy have been proposed. The three major types are the simple lateral closing wedge osteotomy, the step-cut lateral closing wedge and the dome rotational osteotomy.

Lateral closing wedge osteotomy is the commonly performed one, as it is easy to perform and a safer procedure as well, but has its own limitations like difficulty in achieving strong fixation of the osteotomy site which in turn prevents the early mobilization of the joint and also doesn't prevent the protrusion of the lateral condyle and /or a lazy 'S" deformity of the elbow [3, 6]

The simple step-cut osteotomy corrects the deformity in the horizontal plane, but, allows only limited translation of the distal fragment in the coronal plane and any attempt in correcting larger deformities will render the lateral humeral condyle very prominent. Also, the osteotomy is stabilized with a single screw which delays the initiation of the movements of the elbow which is not preferred in adolescents and adults [18]

The dome osteotomy allows correction in the coronal as well as horizontal planes, thus avoiding the residual prominence of the lateral condyle. However, due to the soft tissue contracture it is difficult to attain complete correction in the coronal plane; thus, some prominence of the lateral condyle persists [20].

There are other techniques which have been described in the literature namely, the pentagonal osteotomy [22] which correct the deformity as well as avoid the protrusion of the lateral condyle, but, this procedure is complicated and the results are not always reproducible. The external fixation methods with various types of fixators have been described which corrects the deformity as well as improves the lateral prominence index, but, causes discomfort to the patient as well as has chances of pin tract infection and neurovascular injury.

The three dimensional osteotomy [25] allows good correction of the deformity. The ability for rigid fixation is attained due to the availability of the wide bony contact, but, the chances for limited flexion of the elbow and external rotation of the shoulder are higher with this technique. Lateral oblique closing wedge osteotomy provides good correction of the deformity; provides good hold of the osteotomy site and avoids the prominence of the lateral condyle. But, when larger rotational deformity is to be corrected, the bony contact at the osteotomy site has to been compromised as the lateral cortex is used as a hinge.

There are other types of osteotomies which have been described in the literature for the correction of cubitus deformity like the Arc osteotomy and the Reverse 'V' osteotomy which gives good correction of the deformity as well as avoids the lateral condylar prominence along with providing stable fixation of the osteotomy site.

On comparing the outcome of uni-planar osteotomy and multi-planar osteotomy for the correction of cubitus varus deformity, it was proved that the outcome was similar with respect to the coronal plane alignment and the post-operative range of motion of elbow attained. But, patients who underwent three-dimensional osteotomy had significantly greater loss of alignment on long term follow-up, since; the healing was difficult after multi-planar osteotomy due to the small area of bony contact available at the osteotomy site.

The need for correcting post-traumatic cubitus varus was initially advocated primarily for the correction of cubitus varus deformity. However, there are associated complications with long term cubitus varus like activity-related pain, functional limitation of the elbow, snapping sensation of the elbow during the elbow motion which is because of the medial dislocation of the medial head of the triceps and ulnar nerve during elbow flexion ulno-humeral joint instability due to lateral collateral ligament strain. Posterior instability of the ipsilateral shoulder, postero-lateral rotatory instability of the elbow tardy ulnar nerve palsy and cubital tunnel syndrome has also been reported. Also post-traumatic cubitus varus has been associated with the risk of developing a subsequent lateral condyle fracture of the humerus due to changes in the torsional and shear forces at the elbow, second fracture of the distal humerus after varus mal-union of a supracondylar fracture of the humerus, so is the rare chance of developing osteochondritis dissecans of the humeral trochlea due to the varus mal-alignment causing repetitive axial force across the medial aspect of the elbow leading to micro trauma to the trochlea during day to day work. Thus, surgical correction is indicated not just for cosmesis; but, for preventing the functional disability caused by it.

The step-cut translational osteotomy gives a very good correction of the angular deformity; as well as giving a rigid fixation of the osteotomy site and corrects the prominence of the lateral condyle by medial translation of the distal fragment. The location of the apex determines the amount of correction. It also has the advantage that during surgery after the initial osteotomy, if the radiographic and gross examination reveals under correction of the deformity, additional correction can be obtained by moving the apex further medially. Likewise, if the deformity has been over corrected, it can be corrected by moving the apex further lateral wards. The lateral spike of bone which is left intact gives inherent stability at the osteotomy site by providing "ARM-CHAIR" effect and helps in preventing the loss of fixation. Also, this method prevents other complications like tardy ulnar nerve palsy, prominent lateral humeral condyle, postero-lateral rotatory instability of the elbow and restores the biomechanics of the elbow. This technique is relatively a simpler one and the results are reproducible and are associated with very few complications, and even if present are easily correctable and doesn't cause any permanent structural or functional damage.

Various methods of fixation have been used to stabilize the osteotomy like K-wires [9-11, 13, 15, 20, 23, 24], staples [14, 21, 24, 26], screws [7, 18, 25], screws with wire [6, 15, 17, 19, 23], plate and screws [4, 8], Steinmann pins [5, 16], and various types of external fixators. In our study the method of fixation used was an Asian Dynamic compression plate, Reconstruction plate or a 'Y' humeral plate with screws. The advantage in using this method of fixation is that the plate and screws provide a very stable fixation of the osteotomy, thus allowing early mobilisation and also preventing chances of implant failure or loosening.

The overall complication rate in our study was 13.33%. Weiss J M *et al.* reported an overall complication rate of 32% in his study.

Range of motion of elbow

2 patients had extensor lag post-operatively, of which 1 patient (Case no: 7) had a lag of 5 degrees as the patient had a re-surgery for implant failure after an episode of fall after the initial surgery and the other case (Case no: 14) had a lag of 10 degrees because of the failure of the patient to undergo the post-operative rehabilitative training. 4 patients (Case no's: 3,5,10 & 15) had loss of 10 degrees of terminal flexion when compared to the pre-operative range and 1 case (Case no: 14) had 15 degrees loss of terminal range of flexion. The mean flexion post-operatively was 126 degrees. There was no case with hyper-extension. Kim H T *et al*. reported good range of movements in all his cases post-operative Weiss J M *et al* reported loss of range of motion post-operatively in 12 cases [29.27%] in his study The reason for the limited range of motion in most of the cases was due to poor follow up of the patients for post-operative physical rehabilitation and non-compliance to the physical training post-operatively.

Delayed Union / Non Union

There was one case (case no. 14) of delayed union in our study group which was because the patient didn't follow the post-operative immobilisation protocol as advised. So the patient was immobilised on Plaster of Paris cast for 4 weeks and was removed later when signs of union was appreciated clinically and radiologically, after which range of movements were started and complete union was attained by 24 weeks after surgery and the case had minimal extensor lag. The union of the osteotomy in all the other cases was achieved between 10-14 weeks post-operatively. The mean time for union was 12.67 weeks. This was because of the stable fixation of the osteotomy and the early initiation of the elbow motion. Kim H T *et al*. reported the mean time for union in their cases was 12 weeks. Neither Kim H T *et al*, Weiss J M reported any case of non-union or delayed union in their study.

Lateral Condylar Prominence

None of the case in our series had a prominence of the lateral humeral condyle. The mean pre-operative lateral prominence index was 15.2% and the mean post-operative lateral prominence index was -9.53% and the mean amount of correction obtained was 24.73% against 8.2% reported by Kim H T *et al*. in their study. The reason for achieving good correction of the prominent lateral condyle was because of the translation of the distal fragment medially.

Implant Failure

There was one case (Case no: 7) of implant failure which was because the patient had sustained a slip and fall on the 14th post-operative day. The patient came to us 3 days later and was posted for re-surgery on the 21st post-operative day during which the old implant was removed and the osteotomy site stabilized with another humeral 'Y' plate and screws and patient was again immobilized for 3 weeks and then the range of motion exercises were begun and the patient underwent regular rehabilitation program and at the end of follow up patient had a fair functional and cosmetic outcome. Weiss J M *et al*. reported 4 cases (9.76%) which had implant loosening for which re-surgery was required.

Neurovascular Complications

None of the cases in our study had any nerve or vessel injury as compared to Kim H T *et al*. who reported 1 case (5.26%) with tardy ulnar nerve palsy post-operatively and Weiss J M *et al*. who reported 4 cases (9.76%) with post-operative transient ulnar nerve palsy

Residual Deformity

None of the cases in our study had residual deformity post-

operatively. Weiss J M *et al*. reported 4 cases (9.76%) with residual varus following corrective surgery in his study.

Infection

We didn't encounter any case of superficial or deep infection as compared to Weiss J M *et al*. who reported 1 case (2.44%) of deep infection in his study.

Unsightly Scar

All our cases healed with a cosmetically acceptable scar after the surgery. Kim H T *et al*. reported 1 case (5.26%) of considerable scarring at the incision site.

Other Complications

None of the patients in our series had postero-lateral rotatory instability of the elbow, instability of the shoulder, re-fracture, and fracture of the lateral condyle, unsightly scar or osteochondritis dissecans of the humeral trochlea.

Clinical Illustration

Patients name: **Miss. Malliga**
Case no: 1
Age: 15 years
Sex: Female
Side: Left
Time from injury to surgery: 8 years

Fig 21: Pre-OP clinical photo

Fig 22: Pre-OP X-ray Pre-OP LPI = 14%

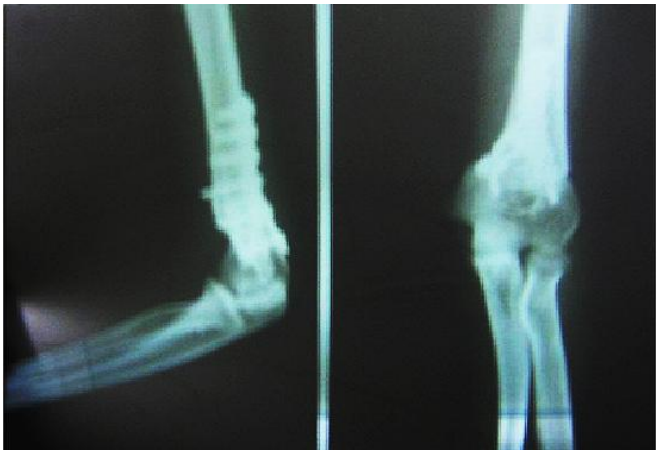

Fig 23: Immediate post-OP X-ray

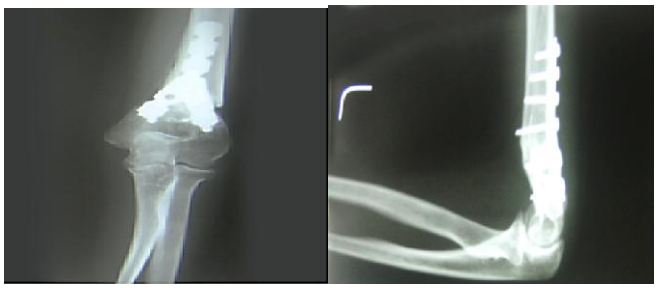

Fig 24: 1 year post-OP X-ray

Fig 25: Post-OP clinical photos

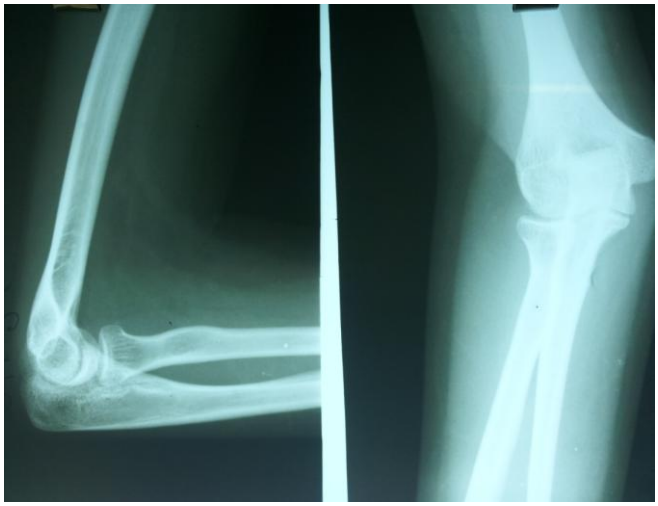

Fig 26: Post implant removal X ray Post-OP LPI = - 6%

Fig 27: Post-OP clinical photos

Patient's name: Mr. Kannan
Case no: 2
Age: 17 years
Sex: Male
Side: Left
Time from injury to corrective surgery: 9 years

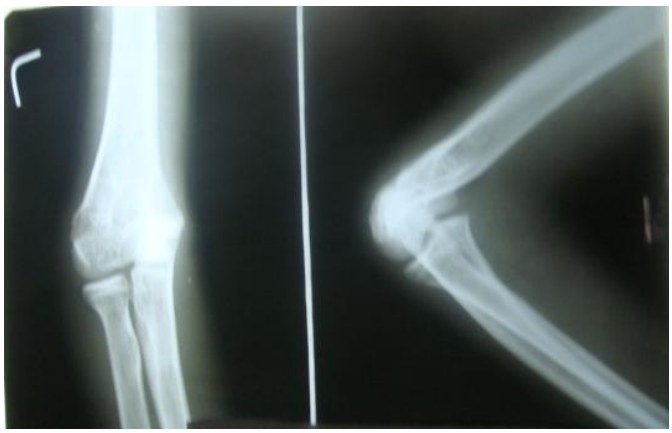

Fig 28: Pre-OP X-ray Pre OP LPI = 18%

Fig 29: Pre-OP clinical Photos

Fig 30: Immediate Post-OP X-rays Post OP LPI = - 20%

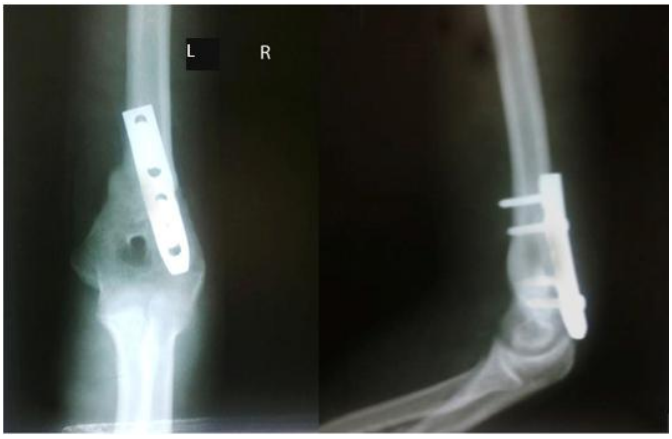

Fig 31: Post-complete union X-ray

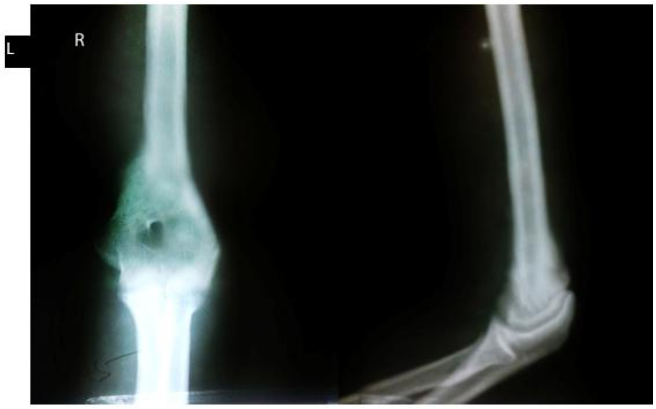

Fig 32: Post-implant removal X-ray

Patient's name: Ms. Rathi
Case no: 3
Age: 18 years

Sex: Female
Side: Right
Time from injury to corrective surgery: 6 years

Fig 33: Pre-op X-ray

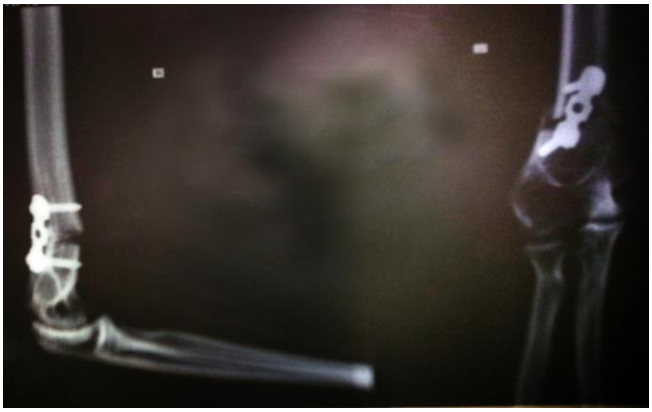

Fig 34: Immediate Post-op X-ray

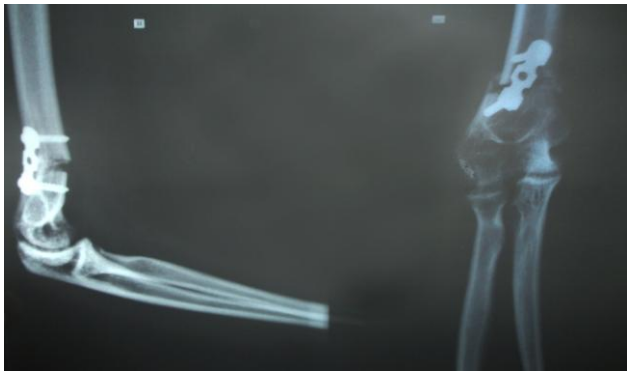

Fig 35: X-ray showing delayed union (16 weeks post-op)

Fig 36: X-ray showing complete union (24 weeks post op)

Summary

Our study comprises of 15 patients with cubitus varus deformity which have been managed by step-cut translational osteotomy at Melmaruvathur adhiparasakthi institute of medical college science hospital and Research Institute

- The sex distribution in our study was 9 males (60%) and 6 females (40%).
- The age distribution in our study; the youngest being 13years old and the eldest aged 24years. The average age of the patients was 18 years.
- The predisposing factor for the cubitus varus deformity in all cases were a supracondylar fracture of the humerus.
- The post-operative humers-elbow-wrist angle ranged between 3 to 12 degrees of valgus with a mean value of 6.13 degrees of valgus and the difference in the humero-elbow-wrist angle between the normal and the affected limbs ranged between 0-7 degrees with a mean difference of 4.47 degrees.
- The post-operative Lateral prominence index ranged between -3 to -20% with a mean corrected lateral prominence index of -9.53%
- 86.67% of the cases in our study had excellent and good results which was attributed to the three-dimensional correction of the deformity with stable fixation which allowed early mobilization post-operatively. The mean post-operative range of flexion achieved was 126 degrees. The osteotomy united between 10-14 weeks in all cases with a mean union time of 12 weeks.
- There was 1 case of implant failure as the patient sustained a slip and fall on the14th post-operative day, which was treated by surgery for the implant removal and re-stabilization of the osteotomy site with another implant a week later, and this case had a fair outcome. We did not encounter any ulnar nerve injury or vessel injury which can be attributed to the posterior approach followed in our series.
- There was one case (case no. 14) of delayed union in our study group which was because the patient didn't follow the post-operative immobilisation protocol as advised. So the patient was immobilised on Plaster of Paris cast for 4 weeks till signs of union was appreciated clinically and radiologically and complete union was attained by 24 weeks after surgery and the case had minimal extensor lag and was designated as fair outcome.
- The results obtained in our study are comparable with the results obtained in the studies published by other authors in International journals.

Conclusion

- The Modified French technique is ideal in children because of the immature bone, but, in case of adolescents and adults who have mature bone a technique which gives a rigid fixation of the osteotomy and which allows early mobilisation is needed as only then good cosmetic and functional outcome can be expected.
- The step-cut translational osteotomy for the correction of cubitus varus gives good to excellent results in adolescents and young adults. (86.67% in our study).
- Our patients were able to achieve a good correction of the varus deformity and had an average valgus angulation of 6.53% post-operatively.
- The patients in our study were having a good functional range of movement post-operatively, with a mean flexion of 125.67 degrees.
- None of the case had a prominent lateral condyle post-

surgery, with an average lateral prominence index of -9.53%.

- The time for union ranged between 10-14 weeks in all cases but one who had delayed union (complete union by 24 weeks). The mean healing time was 12.67 weeks.
- This technique gives good cosmetic appearance post-surgery as all the three components of the deformity as well as the prominence of the lateral humeral condyle can be corrected. Since rigid fixation of the osteotomy is provided by the plate and screws, as well as by the lateral bony spike, early range of motion is permitted post-operatively thus preventing contractures due to long term immobilisation as well as promotes early union of the osteotomy.
- Also. this technique can be performed with ease and the results are easily reproducible.
- Although our study comprises only a small group of patients, we can confidently say that step-cut translational osteotomy is an effective method of treating cubitus varus deformity in adolescents and young adults due to its overall good cosmetic and functional outcome and our results were comparable with that of the other authors.

Reference

1. Jones RA. Note on the Treatment of Injuries about the Elbow. Provincial Med J. 1895; 1:28-30.
2. Smith L, Elgin. Deformity following supracondylar fractures of the humerus. J Bone Joint Surg *(Am)*. 1960; 42-2:235-52.
3. Labelle H, Bunnell WP, Duhaime M. Cubitus varus deformity following supracondylar fractures of the humerus in children. J Pediatr Orthop. 1982; 2:539-46.
4. Siris IE. Supracondylar fractures of the humerus: analysis of 330 cases. Surg Gynecol Obstet. 1939; 68:201-22.
5. King D, Secor C. Bow elbow (Cubitus varus). J Bone Joint Surg. 1952; 34-A:572-6.
6. French PR. Varus deformity of the elbow following supracondylar fractures of the humerus in children. Lancet. 1959; ii:439-41.
7. Amspacher JC, Messenbaugh JF Jr. Supracondylar osteotomy of the humerus for correction of rotational and angular deformities of the elbow. South Med J. 1964; 57:846-50.
8. Langenskiõld A, Kivilaakso R. Varus and valgus deformity of the elbow following supracondylar fracture of the humerus. Acta Orthop Scand. 1967; 38:313-20.
9. Nassar A. Correction of varus deformity following supracondylar fracture of the humerus. J Bone Joint Surg [Br]. 1974; 56-B:572-3.
10. Rang M. Children's fractures. Philadelphia: JB Lippincott Company, 1974.
11. Sweeney JG. Osteotomy of the humerus for malunion of supracondylar fractures. J Bone Joint Surg [Br]. 1975; 57- B:117.
12. Alonso-Llames M, Diaz Peletier R, Moro Martin A. The correction of post-traumatic cubitus varus by hemi-wedge osteotomy. Int. Orthop. 1978; 2:215-8.
13. Sandhu HS, Madaan R. Open wedge osteotomy and triceps release in the management of cubitus-varus deformity. Ind J Orthop. 1982; 16-1:1-8.
14. Carlson CS Jr, Rosman MA. Cubitus varus: a new and simple technique for correction. J Pediatr Orthop. 1982; 2:199-201.
15. Bellemore MC, Barrett IR, Middleton RW, Scougall JS, Whiteway DW. Supracondylar osteotomy of the humerus for correction of cubitus varus. J Bone Joint Surg [Br]. 1984; 66:566-72.
16. Oppenheim WL, Clader TJ, Smith C, Bayer M. Supracondylar humeral osteotomy for traumatic childhood cubitus varus deformity. Clin Orthop. 1984: 188:34-9.
17. Borate MP, Sancheti KH. French osteotomy for correction of cubitus varus deformity. Ind J Orthop. 1987; 21-2:133-7.
18. DeRosa GP, Graziano GP. A new osteotomy for cubitus varus. *Clin Orthop*. 1988; 236:160-5.
19. McCoy GF, Piggot J. Supracondylar osteotomy for cubitus varus - The value of straight arm position. J Bone Joint Surg [Br]. 1988; 70-B:283-6.
20. Kanaujia RR, Ikuta Y, Muneshige H, Higaki T, Shimogaki K. Dome osteotomy for cubitus varus in children. Acta Orthop Scand. 1988; 59(3):314-8.
21. Rai PK. Correction of cubitus varus by supracondylar valgus-rotation osteotomy. Ind J Orthop. 1988; 22(2):169-71.
22. Laupattarakasem W, Mahaisavariya B, Kowsuwon W, Saengnipanthkul S. Pentalateral osteotomy for cubitus varus. Clinical experiences of a new technique. J Bone Joint Surg [Br]. 1989; 71-B:667-70.
23. Wong HK, Lee HK, Balasubramaniam P. The lateral condylar prominence – A complication of supracondylar osteotomy for cubitus varus. J Bone Joint Surg [Br]. 1990; 72-B:859-61.
24. Graham B, Tredwell SJ, Beauchamp RD. Supracondylar osteotomy of the humerus for correction of cubitus varus. J Pediatr Orthop. 1990; 10:228-31.
25. Uchida Y, Ogata K, Sugioka Y. A new three-dimensional osteotomy for cubitus varus deformity after supracondylar fracture of the humerus in children. J Pediatr Orthop. 1991; 11:327-31.