



International Journal of Orthopaedics Sciences

ISSN: 2395-1958
IJOS 2017; 3(4): 153-159
© 2017 IJOS
www.orthopaper.com
Received: 03-08-2017
Accepted: 04-09-2017

Dr. Sujata Aiyer
Associate Professor, Department
of Orthopaedics, Seth G S
Medical College & KEM
Hospital, Parel, Mumbai, India

Dr. Rajib Naskar
Postgraduate Resident,
Department of Orthopaedics,
Seth G S Medical College & KEM
Hospital, Parel, Mumbai, India

Dr. Balgovind S Raja
Postgraduate Resident,
Department of Orthopaedics,
Seth G S Medical College & KEM
Hospital, Parel, Mumbai, India

Dr. Jitesh Manghwani
Speciality medical Officer,
Department of Orthopaedics,
Seth G S Medical College & KEM
Hospital, Parel, Mumbai, India

Dr. Ganesh Khairnar
Postgraduate Resident,
Department of Orthopaedics,
Seth G S Medical College & KEM
Hospital, Parel, Mumbai, India

Dr. Santosh Bindumadhavan
Speciality medical officer,
Department of Orthopaedics,
Lokmanya Tilak Medical College
& Sion Hospital, Sion, Mumbai,
India

Correspondence

Dr. Sujata Aiyer
Associate Professor, Department
of Orthopaedics, Seth G S
Medical College & KEM
Hospital, Parel, Mumbai, India

Incidence of residual varus deformity in operated cases of supracondylar humerus fracture in children

Dr. Sujata Aiyer, Dr. Rajib Naskar, Dr. Balgovind S Raja, Dr. Jitesh Manghwani, Dr. Ganesh Khairnar and Dr. Santosh Bindumadhavan

DOI: <https://doi.org/10.22271/ortho.2017.v3.i4c.22>

Abstract

Supracondylar fractures in children are very frequently occurring fracture in children requiring surgical treatment. The aim of surgery is to mainly prevent future cubitus varus deformity. However even after surgery and restoration of the carrying angle many children presents with varus deformity or reduction in carrying angle. The aim of our study was to see the incidence of such varus deformity in postoperative cases. We have studied 160 cases of supracondylar humerus fracture who have undergone surgery, open reduction and cross K-wire fixation and we have found that almost 24% cases there were loss of carrying angle but only few of them were clinically significant. So we can conclude that closed reduction and K wire fixation is an effective mode of treatment for supracondylar humerus fracture in children to prevent future varus deformity.

Keywords: Supracondylar humerus fracture, Cubitus varus deformity, Closed reduction, K-wire fixation.

1. Introduction

- Supracondylar fractures are the second most common elbow injury in children with incidence about 16% of all paediatric fractures [1] and most common fracture requiring surgical treatment in children [2].
- The peak age for supracondylar fractures is between 6 and 7 years of age [3]. At this age, the supracondylar area is undergoing remodelling and is typically thinner with a more thinner cortex, predisposing this area to fracture.
- These are often significant fractures that may be associated with morbidity due to malunion, neurovascular complications, and compartment syndrome.
- In this fracture, cubitus valgus causes little problem, primarily because the carrying angle is 5 to 7 degrees of physiological valgus and anything more than this is an accentuation of the normal. On the other hand, cubitus varus produces a cosmetic deformity but only rarely any limitation of motion. Many authors have shown that pure posterior displacement causes little deformity and that pure horizontal rotation like-wise causes little deformity because rotation is adequately compensated for at the shoulder joint. Coronal tilting can occur with opening of the lateral aspect of the fracture site, causing angulation into a varus position, or with impaction of the medial side of the fracture site, resulting in cubitus varus. Horizontal rotation predisposes to coronal tilting, and a combination of horizontal rotation, coronal tilting, and posterior displacement can result in a three-dimensional deformity of cubitus varus.

Aim of the study

1. To measure the incidence of residual varus deformity in cases of operated type III supracondylar humerus fracture treated with closed reduction and internal fixation with K-wires.

Objective

- To assess the changes in carrying angle in operated elbow as compared with normal (non-operated) elbow after patient archives full extension of elbow.
- To assess elbow range of motion at one year.

Material and methods

Study design

Prospective and Retrospective type of observational study.

Patients will be followed up post-operatively after one year of the surgery for measurement of varus deformity.

Patients who have already undergone surgery before the commencement of the study will be assessed retrospectively with the help of case papers and pre and post operative X-rays and such patients will then be followed up till the period of one year post surgery for final clinical assessment.

160 patients.

Sample Size Calculation

The sample size is calculated using method described to estimate a proportion with specified precision in desired sample of population. The said sample size is required to estimate the true value with the desired precision and confidence for a population of the specified size.

The data used in the calculation is based on the previously published literature on suggested observed proportion with respect to incidence of varus deformity in patients of type III supracondylar fracture which were treated by open reduction at a tertiary care hospital. The study did measurements of varus deformity and loss of function at elbow in children presenting to tertiary care hospital. (Dowd GS *et al*, 1979) (Sibinski M *et al*, 2006) In current study we will do the measurements of carrying angle, range motion at elbow.

From estimation of previous data the incidence of varus deformity observed in sample of study population with varus deformity in type III supracondylar fracture was 8% to 12% (Avg 10%). The average confidence interval was estimated to be 8.89. The desired precision of the estimate (allowable or acceptable error in the estimate) is half the width of the desired confidence interval. The calculated sample size is 139 subjects. Since patients will be followed up over a period of 1 year since surgery, 10% drop out rate is expected. Therefore the final estimated sample size is 154.

Sample size is calculated using the formula:

$$n = (Z^2 \times P(1 - P))/e^2$$

where

Z = value from standard normal distribution corresponding to desired confidence level (Z=1.96 for 95% CI)

P is expected true proportion

e is desired precision (half desired CI width).

Study Period

The cases were followed by one year post-surgery and checked for any residual varus deformity.

Inclusion and Exclusion criteria:

All cases of type III supracondylar humerus fracture aged between 3 to 16 years, treated with closed reduction and K-wires fixation were included in the study.

The cases excluded were:

- Fracture in children less than 3 years and more than 16 years of age.
- Patient with any other fracture in the same limb.
- Pathological fracture.
- Bilateral supracondylar injuries.
- Open fractures.

Methodology

We have conducted a retro-prospective study of 160 cases of

Gartland type III supracondylar humerus fracture aged between 3-16 years, treated with closed reduction and K-wires fixation. Gartland classification was followed to exclude type I and type II fractures from the study. Also cases with pathological fracture, Open fracture, bilateral fracture or any other fracture in the same limb were excluded.

There were 108 male and 52 female patient with average age of 6.2 years. On an average surgery was undertaken 13.9 hr post-injury.

After initial radiological assessment and pre anaesthesia check up, patient taken up in operation theatre under general anaesthesia. Reduction achieved by progressive traction and flexion with olecranon pressure. After confirming the reduction under c-arm IITV, fracture was fixed with K-wires. Number and configuration of k-wires, depending upon the fracture pattern, stability after reduction, were either cross K-wires with one medial and one or two lateral, or only two lateral K-wires. Final reduction and clinical carrying angle were checked immediately postoperatively and the limb were immobilized in an above elbow slab in pronation for 3 weeks. Plaster removal done after 3-4 weeks when patient came for followup in OPD, radiological assessment were done for union and after confirmation, K wires were removed.

Patients followed up at 3 months, 6 Months and One year. At each visit, clinical assessment were done for loss of carrying angle and loss of range of motion.

Ethics

The study was conducted as per national and international guidelines for conducting research in human subjects.

The protocol was submitted to institutional ethics committee for review and study was initiated only after obtaining approval from the committee.

Statistics

The sample size is calculated using method described to estimate a proportion with specified precision in desired sample of population. The said sample size is required to estimate the true value with the desired precision and confidence for a population of the specified size.

The data used in the calculation is based on the previously published literature on suggested observed proportion with respect to incidence of varus deformity in patients of type III supracondylar fracture which were treated by open reduction at a tertiary care hospital. The study did measurements of varus deformity and loss of function at elbow in children presenting to tertiary care hospital. (Dowd GS *et al*, 1979) (Sibinski M *et al*, 2006) In current study we will do the measurements of carrying angle, range motion at elbow.

From estimation of previous data the incidence of varus deformity observed in sample of study population with varus deformity in type III supracondylar fracture was 8% to 12% (Avg 10%). The average confidence interval was estimated to be 8.89. The desired precision of the estimate (allowable or acceptable error in the estimate) is half the width of the desired confidence interval. The calculated sample size is 139 subjects. Since patients will be followed up over a period of 1 year since surgery, 10% drop out rate is expected. Therefore the final estimated sample size is 154.

Sample size is calculated using the formula:

$$n = (Z^2 \times P(1 - P))/e^2$$

where

Z = value from standard normal distribution corresponding to desired confidence level (Z=1.96 for 95% CI)

P is expected true proportion

e is desired precision (half desired CI width).

Case Study

Age: 3-16 years (SD = 3.3)

Mean age: 6.2 years (Mean age for male was 6.17, for female it was 6.25)

Sex: 108 male and 52 female.

Side of injury: 89 Cases having fracture on left side while 71 cases having fracture on the right.

Average time of surgery after the trauma: 13.9 hours

Average Timing of K-wire removal was 3.2 weeks.

Complications: None of the patients were seen major complications such as arterial injury, compartment syndrome, septic arthritis, osteomyelitis or nonunion.

Two patients were having Transient ulnar Nerve palsy, which recovered completely on 3 weeks followup.

Loss of Range of motion:

Only 3 cases were found where were loss of carrying angle ranging from 2 to 5 degrees.

Loss of reduction: Loss of carrying angle compared to opposite side were found in 38 cases (23.75%). The two tailed P value found to be 0.0001, which is statistically significant.

But there were only 11 cases, where loss of carrying angle were more than 5 degrees. The P value is equals to 0.18, that is not statistically significant.

According to Flynn's criteria 152 fixation was excellent, while 8 result were good.

Discussion

Supracondylar fracture of humerus is the commonest injury around elbow in children. Supracondylar fracture of humerus demand great respect in treatment because if it is not treated properly, it may give rise to neurovascular compromise, difficulty in obtaining or maintaining reduction and poor late results because of stiffness of elbow or malunion, varus deformity. In our study we have followed up 160 patients of type III supracondylar humerus fracture treated with closed reduction and fixation with K-wires for a period of 1 year to see the incidence of loss of carrying angle and loss of range of motion of the elbow. The epidemiological data in this study is consistent with earlier publications.

Supracondylar humerus fracture is more common in 3-13 years of age (Alcott WH, Bowden BW, Miller PR) 24 and (Buhr AJ, Cooke AM. Fracture patterns. Lancet 1959;1: 531-536) In our study also the average age is 6.2 years.

It is more common in male child, because they are more involved in running, jumping as compared to female child. (Alburger PD, Weidner PL, Randal RB). In our study also we have found that incidence are more in male.

Left side is more commonly involved than right side (Wilkins KE. Fractures and dislocations of the elbow region. In: Rockwood CA Jr, Wilkins KE, King RE, editors. Fractures in children. 3rd ed. Philadelphia: JB Lippincott; 1991. pp. 526-617.) In our study also it was found that most of the fracture is on the right side.

According to study of Cheng; 85% of patient comes to hospital within 24 hours. Skaggs *et al*, in their study of 204 patients, found that average interval between time of injury and operation was 1.4 days. In Weiland *et al*, study of 58

cases, 51 patients underwent surgery within 24 hours. In our study also average timing of surgery since trauma is 14 hours. Average surgery time was 25 minutes in our study.

There was no difference in the loss of reduction with respect to timing of surgery in our study. This result is in concurrence with many previous studies which found no difference in those cases treated immediately within 8 h of injury and those treated more than 8 h after the injury [31]. However if limb is grossly swollen, ecchymoses or with neurovascular compromise, should be operated at earliest. A systematic review and a prospective series by Loizou CL, Simillis C, Hutchinson JR had elucidated that the chances of converting to open reduction increased with delay in closed reduction and pinning. Ramachandran *et al*. [32] in an analysis of a retrospective case series concluded that delay in management of low energy supracondylar fracture humerus with gross swelling increased the risk of compartment syndrome. The analysis, however, showed that in selected cases, delay in pinning a type III supracondylar fracture humerus did not adversely affect the outcome. The decision to delay can be made on a case-by-case basis after considering the logistic constraints like the capacity of the team and the urgency of the clinical situation.

Ulnar nerve injury was seen in 2-7% cases in medial pinning. In Kumar *et al* [28], series of 44 patients 5 patients had postoperative temporary nerve palsy and they recovered full function.

In a Weiland *et al* series of 52 cases he came across five preoperative neurological deficits. Two patients had combined radial and median nerve and one each of radial, ulnar and median nerve deficit. All patients recovered in 2 weeks postoperatively. In Srivatsava [29] study group, 42.2% of the patient had nerve injury. In our study 2 (1.2%) patient having transient ulnar nerve palsy, which recovered within 3 weeks of followup.

According to Lewis E. [27] *et al* after closed reduction and percutaneous pinning of a displaced, uncomplicated, extension-type supracondylar humerus fracture, 94% of the child's normal elbow ROM should be expected by 6 months after pinning. Additional improvement may be anticipated to occur as much as 1 year after the injury. In Ramsey *et al* [30] series of 15 patients, 12 were considered essentially normal with carrying angle loss of <3-4°, but three patient had 5-15° of varus deformity without significant motion at elbow. In Weiland *et al*, 2 study of 52 patients, 5 patients had varus angulation of <10°, six had 10-20° and two had varus deformity of >20°.

In our study also 3 cases (1.8%) were found to have loss of elbow motion of 2-5 degrees. Loss of carrying angle compared to opposite side were found in 38 cases (23.75%). But there were only 11 cases (6.8%), where loss of carrying angle were more than 5 degrees.

In his study Pirone *et al*. concluded that "The highest percentages of excellent results were achieved by percutaneous Kirschner-wire fixation (78 per cent), skeletal traction (67 per cent), and open reduction with internal fixation (67 per cent)." In our study of closed reduction and K-wires fixation, 95% were excellent according to Flynn's criteria, while 5% were good result.

Table 1: Comparison of the present study and other previously done similar studies

Comparison of the present study and other previously done similar studies						
Treatment	Author	Total number of cases	Flynn's criteria			
			Excellent	Good	Fair	Poor
Closed reduction and application of cast	Pirone <i>et al</i>	101	51(51%)	27(27%)	3(3%)	20(20%)
Skeletal traction	Pirone <i>et al</i>	24	16(67%)	5(21%)	1(4%)	2(8%)
Open reduction and internal fixation	Reitman <i>et al</i>	65	18(55%)	8(24%)	3(9%)	4(12%)
Closed reduction and percutaneous K-wire fixation	Flynn <i>et al</i>	52	42(80%)	7(14%)	2(4%)	1(2%)
Open reduction and K-wire fixation	Mazda <i>et al</i>	26	24(92%)	1(4%)	0	1(4%)
Open reduction and K-wire fixation	Prasad M Gowda <i>et al</i>	30	18(60%)	7(23.3%)	3(10%)	2(6.7%)
Closed reduction and percutaneous K-wire fixation	Present study	160	152(95%)	8(5%)	0	0

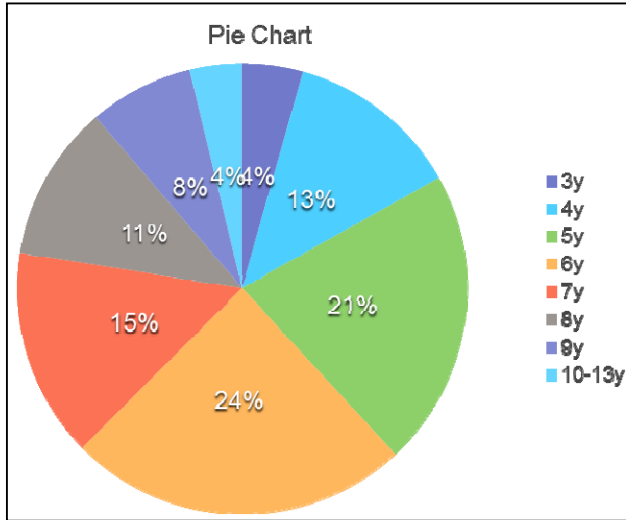


Fig 1: Age distribution of the children presented with supracondylar humerus fracture

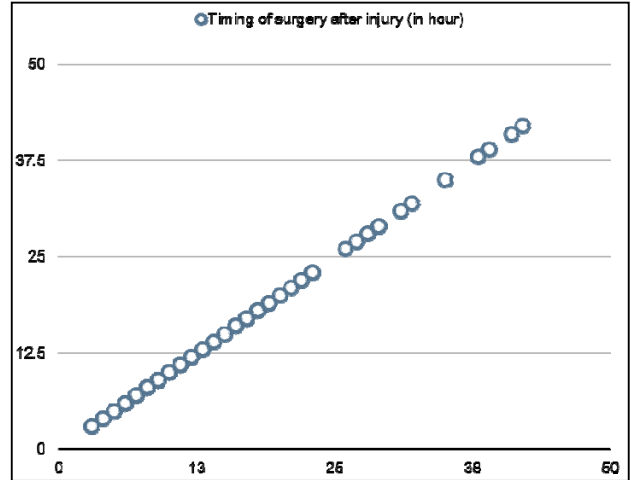


Fig 3: showing timing of surgery after injury (in hour)

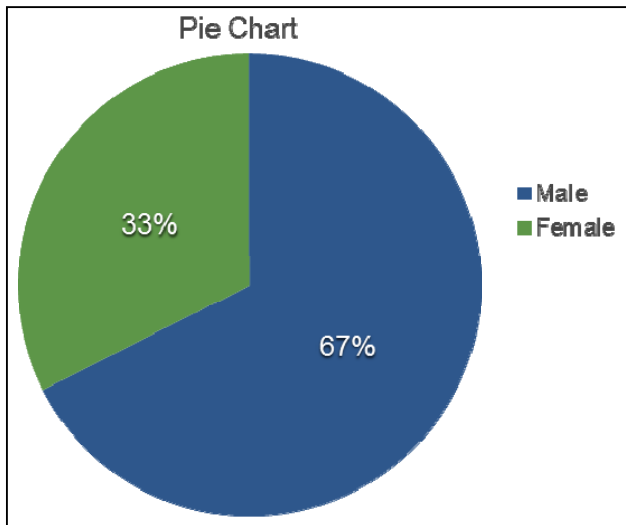


Fig 2: Sex distribution of children presented with supracondylar humerus fracture.

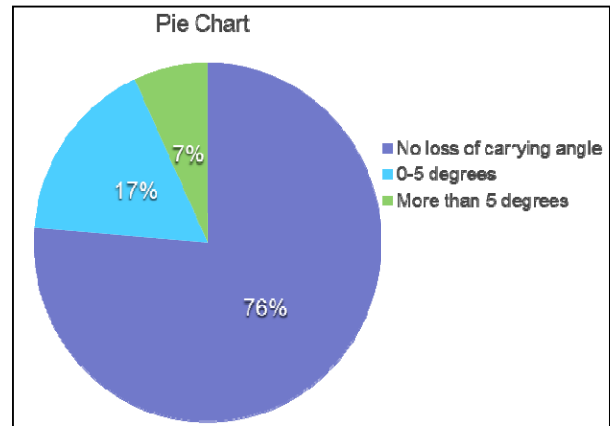


Fig 4: showing loss of carrying angle in children after surgery

Table 2: Side-wise distribution of the patients

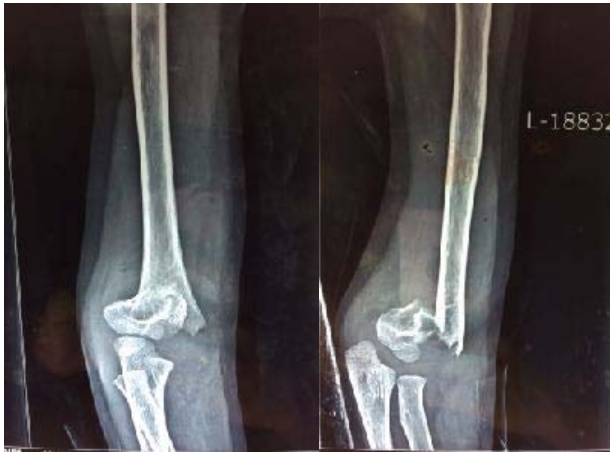Distribution according to side of injury	
Side Of Injury	Numbers
Left	89
Right	71
Total	160

Table 3: Distribution of the children according to Flynn's criteria

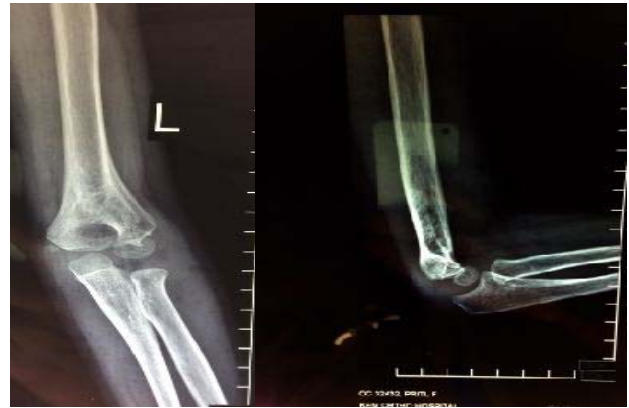Loss of carrying angle	
Loss of carrying angle	number of cases
No loss of carrying angle	122
0-5 degrees	27
More than 5 degrees	11
Total	160

Distribution according to Flynn's criteria

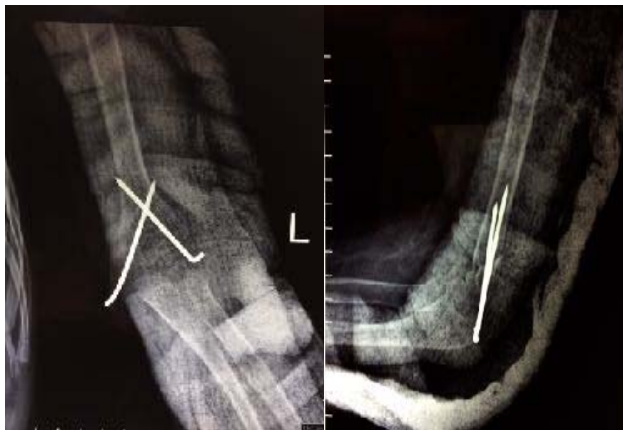Loss of carrying angle	number of cases
Excellent	152
Good	8
Total	160



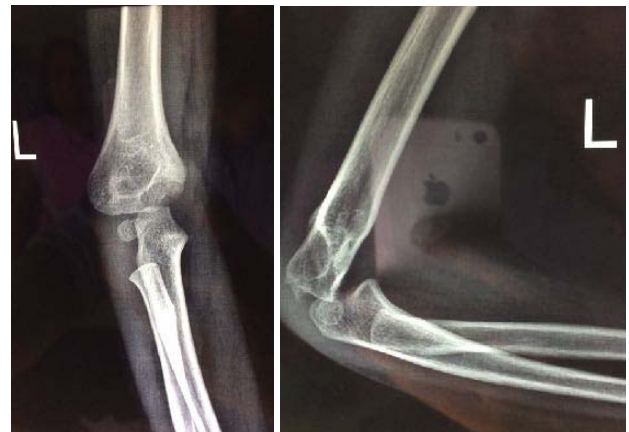Case 1: pre-operative X-ray of left sided supracondylar humerus fracture



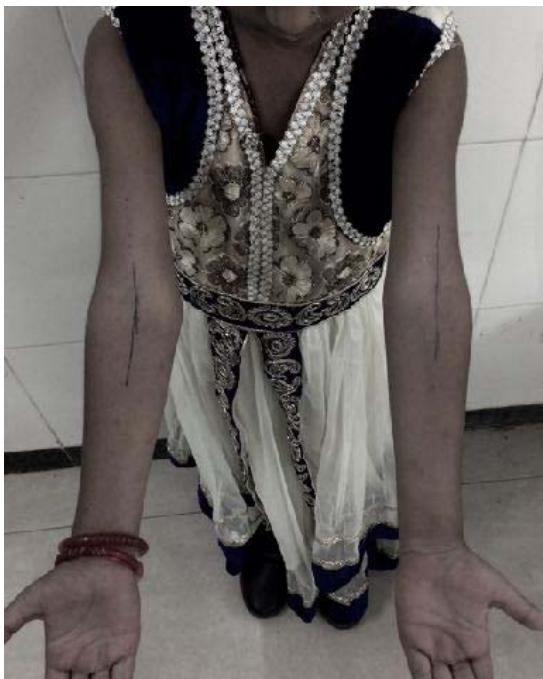Case 1: K-wire removal after 3 weeks



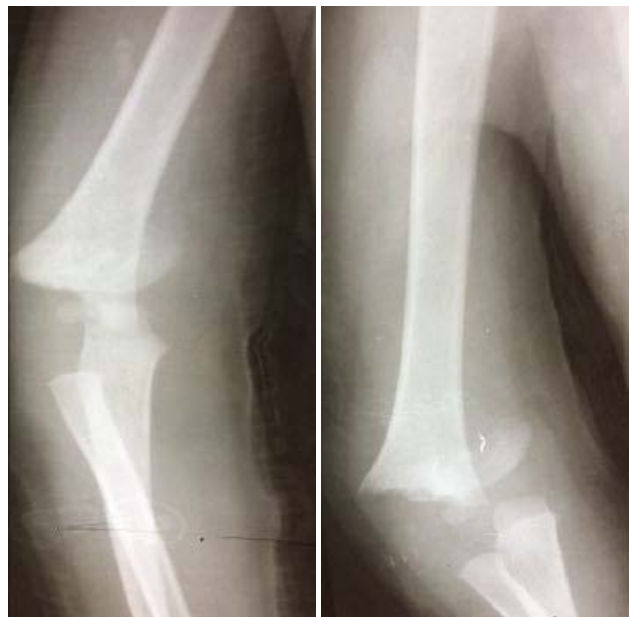Case 1: Immediate post-operative X-ray



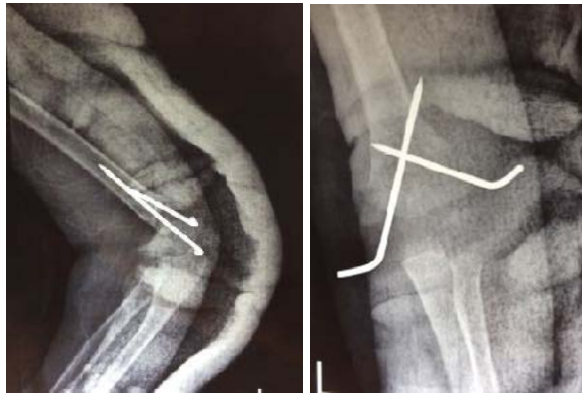Case 1: One year post-operative X-ray



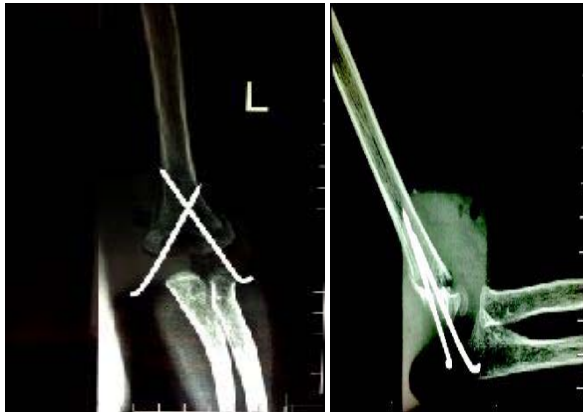Case 1: Loss of carrying angle of 7 degrees on the left side 1 year post-operative



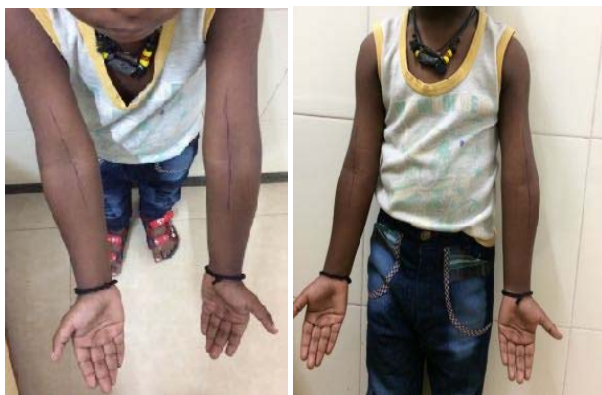Case 2: Pre-operative X-ray with supracondylar humerus fracture.



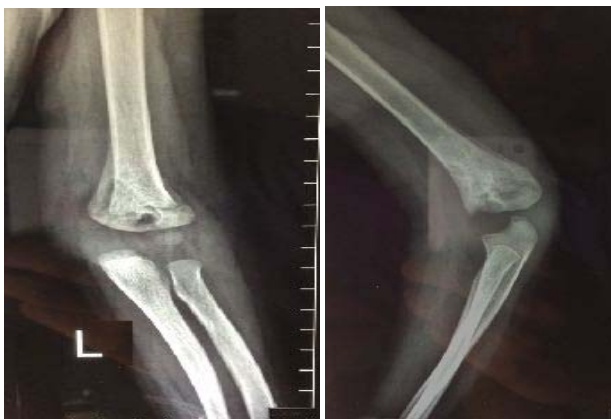Case 2: Immediate post-operative X-ray.



Case 2: Post-operative 3 weeks



Case 2: Clinical picture showing loss of carrying angle of 5 degrees on left side one year after surgery.



Case 2: One year post-operative x-ray.

Conclusion

- Closed reduction and cross K-wire fixation is an effective method of treating type III supracondylar humerus fracture and is superior to other conservative methods of treatment. We recommend close reduction and K-wires fixation for all type III supracondylar humerus fracture.
- Loss of elbow motion and clinically apparent cubitus varus deformity following closed reduction and K-wire fixation is very minimal. We recommend to follow-up the patient for at least 1 year post-surgery for any clinical deformity.
- Less than 5 degrees of loss in carrying angle is not significant clinically and can be observed safely. If loss is more than 5 degrees, child should be observed till period of maximum remodelling or at least one year post-surgery, before any deformity correction is planned.

Reference

1. Cheng JC, Shen WY. Limb fracture pattern in different pediatric age groups: a study of 3,350 children. *J Orthop Trauma.* 1993; 7(1):15-22. doi:10.1097/00005131-199302000-00004.
2. Wilkins KE. Fractures and dislocations of the elbow region. In: Rockwood CA Jr, Wilkins KE, King RE, editors. *Fractures in children.* 3rd ed. Philadelphia: JB Lippincott, 1991, 526-617.
3. Henrikson B. Supracondylar fracture of the humerus in children. A late review of end-results with special reference to the cause of deformity, disability and complications. *Acta Chir Scand Suppl.* 1966; 369:1-72.
4. Ippolito E, Caterini R, Scola E. Supracondylar humerus fracture in children analysis at maturity of 53 patient treated conservatively *JBJS* 1974; 56A:263
5. Dunlop J. Transcondylar fractures of the humerus in childhood. *J Bone Joint Surg.* 1939; 21:59-73.
6. Dodge HS. Displaced supracondylar fractures of the humerus in children-treatment by Dunlop's traction. *J Bone Joint Surg Am.* 1972; 54:1408-1418.
7. Prietto CA. Supracondylar fractures of the humerus. A comparative study of Dunlop's traction versus percutaneous pinning. *J Bone Joint Surg Am.* 1979; 61:425-428.
8. Miller OL. Blind nailing of the T fracture of the lower end of the humerus which involves the joint. *J Bone Joint Surg.* 1939; 21:933-938.
9. Swenson AL. The treatment of supracondylar fractures of the humerus by Kirschner-wire transfixion. *J Bone Joint Surg Am.* 1948; 30:993-997.
10. Flynn JC, Matthews JG, Benoit RL. Blind pinning of displaced supracondylar fractures of the humerus in children. Sixteen years' experience with long-term follow-up. *J Bone Joint Surg Am.* 1974; 56:263-272.
11. Pirone AM, Graham HK, Krajchich JI. Management of displaced extension-type supracondylar fractures of the humerus in children. *J Bone Joint Surg Am.* 1988; 70:641-650.
12. Morrey BF, Chao EY. Passive motion of the elbow joint. *J Bone Joint Surg Am.* 1976; 58(4):501-508.
13. An KN, Morrey BF, Chao EY. Carrying angle of human elbow joint.
14. Radiographic evaluation of normal carrying angle in adult. Mohammad Omar Alsubael and Abelmanem Awad M. Hegazy.
15. Beals RK. The normal carrying angle of the elbow. A radiographic study of 422 patients. 1976; (119):194-6.

16. Cheng JC, Ng BK, Ying SY, Lam PK. A 10-year study of the changes in the pattern and treatment of 6,493 fractures. *J Pediatr Orthop*. 1999; 19(3):344-350.
17. Houshian S, Mehdi B, Larsen MS. The epidemiology of elbow fracture in children: analysis of 355 fractures, with special reference to supracondylar humerus fractures. *J Orthop Sci* 2001; 6(4):312-5.
18. Strait RT, Siegel RM, Shapiro RA. Humeral fractures without obvious etiologies in children less than 3 years of age: when is it abuse? *Pediatrics*. 1995; 96(4Pt1):667-71.
19. Mahan SD, May CD, Kocher MS. Operative Management of Displaced Flexion Supracondylar Humerus Fractures in Children. *J Pediatr Orthop* 2007; 27:551-556.
20. Shanon FJ, Mohan P, Chacko JD, Souja LG, Dorgan's percutaneous lateral cross wiring of supracondylar fracture *JPO* 2005 ; 25(1):130-1.
21. Willkins KE. The operative management of supracondylar fracture humerus *OCNA*. 1990; 21:269,
22. Archibeck M, Scott S, Peters C. Brachialis muscle entrapment in the displaced supracondylar humerus fractures: A technique of closed reduction and report of initial results. *J P Ortho*. 1997; 17:298-302.
23. Pivot J, Lascombes P, Metaizeau JP. Supracondylar fracture of the humerus in children. Treatment by downward pinning. *Fr J Ortho Surg*. 1990; 76:171-177.
24. Alcott WH, Bowden BW, Miller PR. Displaced supracondylar fracture of the humerus in children: long term followup of 69 patients. *J Am Osteopath Assoc* 1977; 76:910-915.
25. Takahara M, Sasaki I, Kimura T. Second fracture of the distal humerus after varus malunion of a supracondylar fracture in children. *J Bone Joint Surg [Br]* 1998; 80B:791-797.
26. Siris IE. Supracondylar fractures of the humerus: an analysis of 330 cases. *Surg Gynecol Obstet* 1939; 68:201-222.
27. Time of Return of Elbow Motion after Percutaneous Pinning of Pediatric Supracondylar Humerus Fractures. Lewis E, Zions MD, Christopher J, Woodson MD, Nahid Manjra PA, Charalampos Zalavras MD.
28. Kumar R, Kiran EK, Malhotra R, Bhan S. Surgical management of the severely displaced supracondylar fracture of the humerus in children. *Injury*. 2002; 33(6):517-22.
29. Srivastava S. The results of open reduction and pin xation in displaced supracondylar fractures of the humerus in children. *Med J Malaysia* 2000; 55(Suppl C):44-8.
30. Ramsey RH, Griz J. Immediate open reduction and internal xation of severely displaced supracondylar fractures. *Clin Orthop*. 1973; 90:130-4.
31. Mehlman CT, Strub WM, Roy DR, Wall EJ, Crawford AH. The effect of surgical timing on the perioperative complications of treatment of supracondylar humeral fractures in children. *J Bone Joint Surg Am*. 2001; 83:323-7.
32. Ramachandran M, Skaggs DL, Crawford HA, Eastwood DM, Lalonde FD, Vitale MG *et al*. Delaying treatment of supracondylar fractures in children: Has the pendulum swung too far? *J Bone Joint Surg Br*. 2008; 90:1228