



ISSN: 2395-1958
IJOS 2017; 3(4): 42-49
© 2017 IJOS
www.orthopaper.com
Received: 10-08-2017
Accepted: 11-09-2017

Dr. RK Jain
Professor and Head of
Department, Department of
Orthopaedics, Sri Aurobindo
Institute of Medical Sciences,
Indore, Madhya Pradesh, India

Dr. Siddharth Patel
Resident, Department of
Orthopaedics, Sri Aurobindo
Institute of Medical Sciences,
Indore, Madhya Pradesh, India

Developmental dysplasia of hip – An overview

Dr. RK Jain and Dr. Siddharth Patel

DOI: <https://doi.org/10.22271/ortho.2017.v3.i4a.10>

Abstract

Developmental dysplasia of the hip refers to a spectrum of severity ranging from mild acetabular dysplasia with a stable hip, to more severe forms of dysplasia with hip instability, to established hip dysplasia with or without subluxation or dislocation. DDH affects 1-3% of newborns and is responsible for 29% of primary hip replacements in people up to the age of 60 years. Ligamentous laxity is also believed to be associated with hip dysplasia, though this association is less clear. The treatment of DDH is age-related and the goal is to achieve and maintain concentric reduction of the femoral head into the acetabulum. A dislocated hip which can be reduced and a reduced hip that can be subluxated should be treated with the orthosis. All such hips should be treated in orthosis or harness beginning at the time of diagnosis. This results from excessive pressure on the femoral head after reduction in extreme abduction and internal rotation leading to vascular occlusion. Avascular necrosis results from excessive pressure on the femoral head after reduction in extreme abduction and internal rotation leading to vascular occlusion. Developmental dysplasia of the hip is a challenging condition. Formal training in the treatment of various age groups with DDH is mandatory. Successful treatment with Orthoses requires careful counselling of parents. Surgical management requires careful pre-operative planning and adequate follow up to ensure the best clinical outcomes.

Keywords: Avascular necrosis, developmental dysplasia, femoral head, hip

Introduction

Developmental dysplasia of the hip – DDH, (formerly known as congenital dislocation of the hip - CDH) is now the preferred term, reflecting as an ongoing developmental process. The definition of DDH is not universally agreed upon. It refers to a spectrum of severity ranging from mild acetabular dysplasia with a stable hip, to more severe forms of dysplasia with hip instability, to established hip dysplasia with or without subluxation or dislocation.

Early detection and treatment of developmental dysplasia of the hip (DDH) is critical for the best chances of obtaining a well-functioning, pain-free hip joint well into adulthood, and research has shown that a child's age at initial reduction is correlated to radiographic outcomes.

If detected within first six weeks of life is considered as early detection, and one detected beyond three months and into walking age is considered as late presentation DDH.

DDH may lead to impaired hip function and premature degenerative joint disease particularly if treatment is delayed Hip instability if detected in the neonatal period can be effectively treated by non-surgical means in a majority of instances, while delay in its diagnosis increases the likelihood of surgical intervention. It has been said that delayed presentation of children with DDH is a common occurrence in India.

Overview

Background

The term congenital dislocation of the hip dates back to the time of Hippocrates. It has been diagnosed and treated for several hundred years. Most notably, Ortolani, an Italian paediatrician in the early 1900s, evaluated, diagnosed, and began treating hip dysplasia. Galeazzi later reviewed more than 12,000 cases of DDH and reported the association between apparent shortening of the flexed femur and hip dislocation. Since then, significant progress has been made in the evaluation and treatment of DDH [1, 2, 3, 4, 5].

Correspondence

Dr. RK Jain
Professor and Head of
Department, Department of
Orthopaedics, Sri Aurobindo
Institute of Medical Sciences,
Indore, Madhya Pradesh, India

Epidemiology

DDH affects 1-3% of newborns and is responsible for 29% of primary hip replacements in people up to the age of 60 years.⁶ A systematic review of unscreened populations estimated the prevalence of clinically diagnosed, established hip dysplasia to be 1.3 per 1,000 but in populations screened clinically with Ortolani and Barlow tests, the prevalence is higher at 1.6-28.5 per 1,000 and it is higher still with ultrasound screening^[6].

Predisposing Factors

The exact cause of hip dysplasia is not clear, but this condition does appear to be related to a number of different predisposing factors^[7].

- **Racial background:** In Native Americans and Laplanders, the prevalence of hip dysplasia is much higher (nearly 25-50 cases per 1000 persons) than in other races, and the prevalence is very low in southern Chinese and black populations^[8-12].
- **Genetic predisposition:** Also appears to exist, in that the frequency of hip dysplasia is 10 times higher in children whose parents had DDH than in those whose parents did not^[13].
- **Intrauterine positioning and sex:** Female sex, being the first-born child and breech positioning are all associated with an increased prevalence of DDH. An estimated 80% of persons with DDH are female^[14], and the rate of breech positioning in children with DDH is approximately 20% (compared with 2-4% in the general population)^[15].
- Other musculoskeletal disorders of intrauterine mal positioning or crowding, such as metatarsus adducts and torticollis, have been reported to be associated with DDH^[16-19].
- Oligohydramnios is also reported to be associated with an increased prevalence of DDH^[20].
- The left hip is more commonly associated with DDH than the right hip, possibly because of the common intrauterine position of the left hip against the mother's sacrum, which forces it into an adducted position.
- Children in cultures in which the mother swaddles the baby, forcing the infant's hips to be adducted, also have a higher rate of hip dysplasia^[21].

Hip dysplasia can be associated with underlying neuromuscular disorders, such as cerebral palsy, meningomyelocele, arthrogryposis, and Larsen syndrome, though such cases are not usually considered DDH.

Anatomy

The normal growth of the acetabulum depends on normal epiphyseal growth of the tri-radiate cartilage and on the three ossification centres located within the acetabular portion of the pubis (os acetabulum), Ilium (acetabular epiphysis), and Ischium. Additionally, normal growth of the acetabulum depends on normal interstitial appositional growth within the acetabulum. The presence of the spherical femoral head within the acetabulum is critical for stimulating normal development of the acetabulum.

Abnormal development of the hip includes the osseous structures, such as the acetabulum and the proximal femur, as well as the labrum, capsule, and other soft tissues. This condition may occur at any time, from conception to skeletal maturity.

The anatomy of the dislocated hip, especially after several months, often includes formation of a ridge called the neo-

limbus. Closed reduction is often unsuccessful at a later date, secondary to various obstacles to reduction. These include adductor and psoas tendon contraction, ligamentous teres, a transverse acetabular ligament, and pulvinar and capsular constriction. With long-standing dislocations, interposition of the labrum can also interfere with reduction.

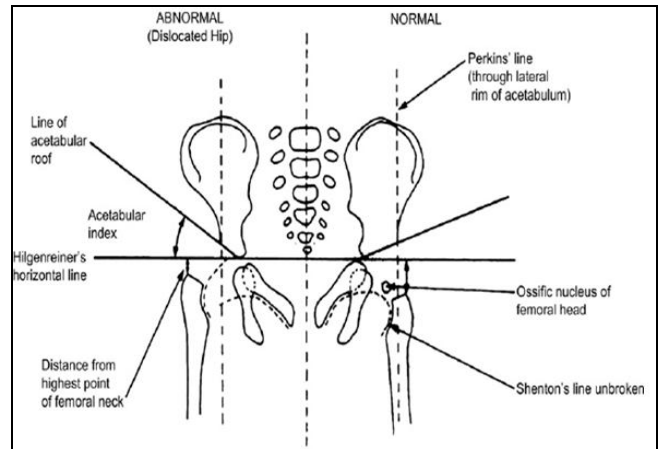



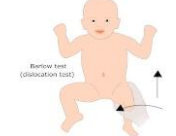
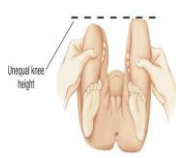
Fig 1: Schematic diagram of Normal Neonatal Hip Joint compared to Developmental Dysplasia of Hip Joint in Neonate.

Pathophysiology

DDH involves abnormal growth of the hip. Ligamentous laxity is also believed to be associated with hip dysplasia, though this association is less clear. Children often have ligamentous laxity at birth, yet their hips are not usually unstable; in fact, it takes a great deal of effort to dislocate a child's hip. Therefore, more than just ligamentous laxity may be required to result in DDH.

At birth, white children tend to have a shallow acetabulum^[6, 7], this may provide a susceptible period in which abnormal positioning or a brief period of ligamentous laxity may result in hip instability. However, this characteristic is not as true for children of African descent, who have a lower rate of DDH⁸

Diagnostic Tests Recommended

	<p>Ortolani test: The examiner applies gentle forward pressure to each femoral head in turn, in an attempt to move a posteriorly dislocated femoral head forwards into the acetabulum. Palpable movement suggests that the hip is dislocated or subluxated, but reducible.</p>
	<p>Barlow test: Gentle backward pressure is applied to the head of each femur in turn, and a subluxable hip is suspected on the basis of palpable partial or complete displacement.</p>
	<p>The Galeazzi sign: The child is examined lying supine with the hips and knees flexed to 90° and the height of each knee is compared. Unilateral femoral shortening may signify hip dislocation or rarer abnormalities of the femur. False negative results may occur with bilateral hip dysplasia or when the pelvis is not level.</p>

Other physical signs for late dislocation include asymmetry of the gluteal thigh or labral skin folds, discrepancy in leg length, a widened perineum on the affected side, buttock flattening, asymmetrical thigh skin folds and standing or walking with external rotation of the affected leg.

Both Barlow and Ortolani tests detect an unstable hip but do

not detect an irreducible dislocated hip, which is best detected by identifying limited abduction of the flexed hip. Nor do they detect a stable hip with abnormal anatomy - eg, acetabular dysplasia.

The Barlow and Ortolani tests are useful in neonates but become difficult by 2-3 months of age. Stable hips may be dysplastic. Limited hip abduction (less than 60°) when the hip is flexed to 90° is the most important sign of a dislocated or dysplastic hip [22]

Benign hip clicks, resulting from soft tissues snapping over bony prominences during hip movement, should be distinguished from the clunks produced during the Ortolani manoeuvre as the dislocated femoral head is reduced and from the subluxation felt during the Barlow test.

Children aged 3-6 months: The physical signs are rather different and so are the requirements of examination. Unilateral limitation and asymmetry of hip abduction is the most reliable sign of DDH after eight weeks. If the hip is dislocated it is in a fixed position.

Older children there is limited abduction when fully flexed. They may walk on toes on the affected side or present with a painless limp.

Bilateral dislocation: It is present in about 20% of cases, it

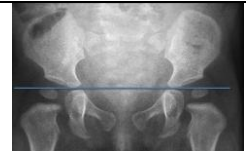


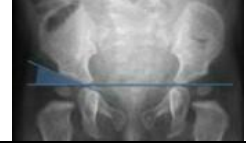

can be quite difficult to diagnose, especially after the neonatal period. There is often a waddling gait with hyperlordosis. The Galeazzi sign for hip shortening is often absent, as are asymmetrical thigh and skin folds, or asymmetrically decreased abduction. Careful examination is needed with a high level of suspicion.

Crowe classification of Developmental Dysplasia of Hip

Crowe I	Femur and acetabulum show minimal abnormal development.	Less than 50% Dislocation
Crowe II	The Acetabulum shows abnormal development	50% to 75% Dislocation
Crowe III	The Acetabulum is developed without a roof. A false Acetabulum develops opposite dislocated femur head position.	75% to 100% Dislocation
Crowe IV	The Acetabulum insufficiently Developed. Since the femur is positioned high up on the pelvis.	High Hip Dislocation

Investigations

Radiography: It become primary imaging modality at 4-6 months after the femoral head begins to ossify. Radiological features in DDH.

	<p>Hilgenreiner's line:</p> <ul style="list-style-type: none"> • Horizontal line through right and left tri radiate cartilage. • Femoral head ossification should be inferior to this line
	<p>Perkin's line:</p> <ul style="list-style-type: none"> • Line perpendicular line to Hilgenreiner's through a point at lateral margin of acetabulum. • femoral head ossification should be medial to this line
	<p>Shenton's line:</p> <ul style="list-style-type: none"> • Arc along inferior border of femoral neck and superior margin of obturator foramen • Arc line should be continuous delayed ossification of the femoral head is seen in cases of dislocation
	<p>Acetabular Index (AI)</p> <ul style="list-style-type: none"> • Angle formed by a line drawn from point on the lateral tri-radiate cartilage to point on lateral margin of acetabulum and Hilgenreiners line. • Should be less than 25° in patients older than 6 months.
	<p>Centre Edge Angle (CEA)</p> <ul style="list-style-type: none"> • Angle formed by a vertical line from the centre of the femoral head and to the lateral edge of the acetabulum, • 25° to 40° is normal. Less than 25° or grater than 40° is considered abnormal. • Reliable only in patients over the age of 5 years. • Acetabular teardrop not typically present prior to hip reduction. • Development of teardrop after reduction is thought to be good prognostic sign for hip function

Ultrasound evaluates for acetabular dysplasia and/or the presence of a hip dislocation.

- Useful before femoral head ossification (<4-6 months of age).
- May produce spurious results if performed before 4-6 weeks of age.
- Allows view of bony acetabular anatomy, femoral head, labrum, ligamentous teres, hip capsule

Alpha Angle

- Angle created by lines along the bony acetabulum and the Ilium
- Normal is greater than 60°

Beta Angle

- Angle created by lines along the labrum and the ilium
- Normal is less than 55°
- Femoral head is normally bisected by a line drawn down from the ilium

Normal ultrasound in patients with soft-tissue 'clicks' will have normal acetabular development. It allows for monitoring of reduction during Pavlik harness treatment. It is not cost effective for routine screening

Arthrogram

- Used to confirm reduction after closed reduction under anaesthesia

- Help identify possible blocks to reduction

Inverted Labrum

- Labrum enhances the depth of the acetabulum by 20% to 50% and contributes to the growth of the acetabular rim
- In the older infant with DDH the labrum may be inverted and may mechanically block concentric reduction of the hip

Inverted Limbus

- Represents a pathologic response of the acetabulum to abnormal pressures caused by superior migration of the head
- Consists of fibrous tissue
- Transverse acetabular ligament
- Hip capsule is constricted by ilio-psoas tendon causing hour-glass deformity of the capsule, pulvinar, ligamentous teres.

CT scan: CT study of choice to evaluate reduction of the hip after closed reduction and spica casting.

MRI: Does not play significant role in primary diagnosis.

Screening Programme for DDH

The objective of any screening programme is to identify “pre-clinical” cases (in the case of DDH, read as “neonatal hip instability”) earlier in their natural history than would occur in the absence of screening [22].

Two basic assumptions commonly made in evaluating the effectiveness of screening are

1. All or most cases of the disease will pass through a detectable “pre-clinical phase” of illness.
2. In the absence of intervention, all or most cases in the “pre-clinical phase” would progress to a clinical phase.

A Cochrane review found that there was insufficient evidence to give clear recommendations regarding screening for DDH. There was some inconsistent evidence that universal ultrasound results in a significant increase in treatment compared to the use of targeted ultrasound or clinical examination alone. The review concluded that ultrasound strategies have not been demonstrated to improve clinical outcomes including late-diagnosed DDH and surgery [23]

A large long-term randomised controlled study of universal or selective ultrasound versus a well-done physical examination showed higher treatment rates but no reduction in late cases of DDH [24-29]. There was also no difference, at skeletal maturity, in acetabular dysplasia or degenerative change.

Universal ultrasound examination is not recommended by Public Health England but selective ultrasound examination for babies with specific risk factors is recommended. An ultrasound examination of the hips should be performed within 6 weeks of age [30]

Management of developmental dysplasia of the hip

The treatment of DDH is age-related and the goal is to achieve and maintain concentric reduction of the femoral head into the acetabulum. The best outcome can be expected only if the treatment is started very early.

This has been achieved in the developed world, through improved awareness and training, increased surveillance (use of ultrasound), and quicker access to paediatric orthopaedic surgeons.³¹ must be noted that there are very few specialized paediatric orthopaedic surgeons in the developing world, and

fellowship programs for paediatric orthopaedic surgery should be initiated to cater for this requirement, in addition to the myriad of other paediatric orthopaedic conditions [32].

Treatment of a neonate with developmental dysplasia of the hip

Subluxation of hip noted at birth may correct spontaneously. Some physicians may continue with observation before initiating treatment. When observation is chosen, steps should be taken to ensure close follow up because some of these hips will subsequently dislocate if left alone. The child should then be re-evaluated both clinically and by ultrasound at three weeks of age to confirm concentricity.

Hips that are still dislocated need further treatment. Orthoses, such as Erlanger, Thübinger or Pavlik, which promote abduction and flexion of the hip joint can reduce unphysiological pressure to the antero lateral acetabulum and are a preferred treatment option in this age group, aiming for development of a normal lateral edge of the cartilaginous acetabulum.

A dislocated hip which can be reduced and a reduced hip that can be subluxated should be treated with the orthosis. All such hips should be treated in orthosis or harness beginning at the time of diagnosis. These harnesses are very dynamic and successful tools in the treatment of DDH, although they are sometimes difficult to handle for the parents.

Once properly applied, they allow motion while the hips are flexed (>90°) as well as abducted and treatment is continued until the hip is stable, as evidenced by negative Barlow and Ortolani tests. The normal degree of valgus of femoral head and neck requires this degree of flexion to promote spontaneous reduction of dislocation.

Application of an orthosis should be followed by bi-weekly clinical examination, and ultrasonography if required. If the hip is reduced at three weeks following application of orthosis, the patient may continue to wear it for a further three weeks. After six weeks, the orthosis is removed and the hip is examined both clinically and by ultrasound.

If the hip is reduced then the orthosis can be discontinued. The dislocated hip, even after 3–4 weeks of orthosis use, should be evaluated and may be treated with an abduction brace [33-36]. The child needs regular follow up until skeletal maturity to identify the late squeal, such as acetabular dysplasia [37-40].

The hip should not be placed in a position of hyper flexion and hyper abduction as it may result in high pressure on the femoral head leading to osteo necrosis. In addition, there is evidence of an increased risk of femoral nerve palsy [41-44] or inferior dislocation of the femoral head due to hyper flexion [45]. On the other hand; inadequate flexion will fail to reduce the hip.

The Pavlik harness is contraindicated ‘when there is major muscle imbalance, as in meningomyelocele (L2 to L4 functional level); major stiffness, as in arthrogryposis, ligamentous laxity, as in Ehlers-Danlos syndrome’ or where the family situation cannot guarantee careful and consistent use of the harness.

Treatment of a child (one to six months)

Orthosis is the choice of treatment in this age group. The hip should be placed in 90 degree flexion with the proximal femur pointing towards tri-radiate cartilage. The hip which is not reducible at the time of clinical examination may still be treated with orthosis; however, higher dislocations are less likely to reduce than the lower ones [45, 46]. The position of the

hip must be confirmed after application of orthosis with AP X-ray.

The child should be examined at regular intervals to ensure the reduction. The orthosis should be continued for at least six weeks after the stability is achieved. If the hip fails to reduce with orthosis then other options should be considered, such as an abduction (Von Rosen) splint. The main aim of treatment is to achieve concentric reduction and to prevent a vascular necrosis. Whatever method is used, it must be ensured that reduction can occur spontaneously. The hips should never be immobilised in a forced position.

Nakamura *et al.* reported his results of 115 patients with 130 hips. The mean age was 4.8 months and there was a mean follow up of 16 years. Patients were treated with a Pelvic harness with a mean duration of treatment of 6.1 months. Twenty-two hips required supplementary surgery for residual dysplasia, the choice of surgery depending on the state of joint and surgeon's preference. A satisfactory outcome (Severin classes I and II) was achieved in 119 patients [47].

Treatment of child (six months to two years)

The child in this age group may be treated with either closed or open reduction, followed by a spica cast. The aim is to achieve reduction without damaging the femoral head.

There are several studies favouring reduction of hips after the appearance of ossific nucleus [48]. Segal *et al.* reported on hips in children less than 12 months of age [49]. Thirty-eight hips were reduced closed while 17 were reduced by an open method. One patient with bilateral hip dislocation was treated initially by closed means and later treated by open reduction at three months. Avascular necrosis (AVN) developed in only one of 25 patients in which a nucleus was present while 17 of 32 patients developed AVN when reduction was performed before the appearance of an ossific nucleus at a mean follow up of 59 months.

Roposch *et al.* conducted a meta-analysis including 6 observational studies of a total of 358 patients with a mean age of 9.6 months at the time of reduction. Closed as well as open reduction was performed in 3 studies, open reduction alone was performed in 2 studies and closed reduction alone was performed in one study. They noted that the presence of an ossific nucleus had an insignificant effect on the development of AVN when all grades were considered. Forty-one (19%) patients developed AVN when an ossific nucleus was present as compared to 30 (22%) patients when this was absent. However, the absence of an ossific nucleus was associated with the development of osteonecrosis when grade II or more were considered; 14 (7%) patients with an ossific nucleus and 18 (16%) without an ossific nucleus [50].

On the other hand, there are studies which do not confirm this. Konigsberg *et al.* presented his results of 40 patients in whom an open reduction through a medial approach had been performed. Average age was 7.7 months, ranging from 2.4 to 18.9 at the time of surgery, with a mean follow up of 10.3 years. Only one of 20 hips reduced before the age of six months developed AVN [51]. Other investigators have reported that hips reduced after the appearance of an ossific nucleus have a higher number of operative procedures [52]. In addition, due to reduced growth potential, hips reduced later will not remodel as well as those reduced earlier.

The use of pre-reduction traction is controversial. It is supported by many studies showing a decreased rate of AVN and relative success of closed reduction [53-55]. On the other hand, there are studies showing a similar rate of open reduction (56) and AVN in which traction was not used [56, 57].

Open reduction may be achieved through a medial or anterior approach. Minimal dissection is required in a medial approach and allows the surgeon to achieve a stable reduction without the risk of AVN [58]. Disadvantages of the medial approach include inadequate exposure, risk to medial circumflex femoral vessels and inability to perform capsulorrhaphy. Post-operatively a cast is applied and changed after six weeks for a total period of three months.

The anterior approach has a better visualization and allows the surgeon to perform a good capsulorrhaphy [59]. The choice of approach depends upon patient age and the surgeon's experience. A medial approach is recommended for children under one year of age with a maximum age limit of 18 months in expert hands.

Treatment of older child (two years of age and older)

In older children, the femoral head lies in a more proximal location. Previously, pre-operative traction was used to bring the head into the normal position, but now femoral shortening has replaced the use of traction. Femoral shortening is usually required after the age of two years to reduce the pressure on the femoral head after reduction. This will decrease the risk of osteonecrosis [60].

Sankar *et al.* studied the factors predicting the need for femoral shortening in 72 hips (64 patients). All patients underwent open treatment for DDH with a mean age of 35.6 months and a mean follow up of 21.4 months. He concluded that the patients over the age of 36 months and patients with vertical displacement greater than 30% of the width of pelvis were more likely to require femoral shortening [61].

The aim of femoral derotation varus osteotomy is to achieve concentric reduction. Spence *et al.* compared two groups of patients undergoing open reduction through an anterior approach either with femoral derotation osteotomy (38 patients with 47 hips) or innominate osteotomy (33 patients with 37 hips). Mean age at reduction was 25.3 months in the first group and 21.9 months in the second group. Mean duration of follow up was 6.2 years. Acetabular remodelling and stability was better in the patients with innominate osteotomy compared to femoral derotation osteotomy [62].

Adequate post-reduction coverage of the femoral head is essential. The risk of residual dysplasia at skeletal maturity increases as open reduction is performed in older children. If femoral head coverage is inadequate, then pelvic osteotomy should be considered in this age group. Salter innominate and Pemberton osteotomy are the most commonly used techniques [63].

If closed or open reduction is performed in a child under 18 months of age, the child should be followed till the age of 3.5–4 years. If the femoral head coverage is still inadequate, then pelvic osteotomy should be considered. Bohm *et al.* studied 73 hips in 61 patients with a mean age of 4.1 years at the time of surgery. He concluded that good clinical results can be expected if normal acetabular anatomy is restored without the development of AVN. However, pelvic osteotomy should preferably be performed at a later stage than at the time of open reduction [64]. Thomas *et al.* presented the results of 80 hips in 60 patients with a mean follow up of 43.3 years. All patients underwent open reduction, capsulorrhaphy and Salter innominate osteotomy at a mean age of 2.8 years. Failure was defined as the joint requiring replacement surgery. They reported a 54% survival rate with excellent prognosis in two-thirds who were able to function at a high level [65].

El-Sayed *et al.* reported 71 surgical interventions in 55

patients (ages ranging from two to four years) in whom open reduction, Salter innominate osteotomy, and proximal femoral osteotomy were performed in a single stage. The mean follow up was five years and four months. They reported favourable clinical and radiological results. Mean pre-operative acetabular index was 41.86 while the final mean acetabular index was 16.78 [66].

Late presentation acetabular dysplasia

A number of patients present late in adolescence with complaints of aching pain either in the groin or lateral hip pain which increases after exertion. After detailed physical and radiographic assessment, a treatment strategy is devised for these dislocated hips. The goal of treatment is to attain concentric reduction by realignment osteotomy of the acetabulum to cover the femoral head such as Salter, Pemberton and Dega osteotomy. For hips that cannot be concentrically reduced, the aim is to cover the femoral head with structures that become fibro cartilage. The Chiari osteotomy and the shelf procedure are two such approaches [67].

Complications

Avascular necrosis

This results from excessive pressure on the femoral head after reduction in extreme abduction and internal rotation leading to vascular occlusion. The incidence of AVN varies widely from 0–73% [68] depending on the age, mode of treatment and criteria used to describe AVN. Four percent incidence was reported by Weiner *et al.* in children under the age of three months. AVN can easily be prevented by performing femoral shortening [69].

Change in femoral head density, failed ossification and widening of the femoral neck suggest a vascular changes.⁷⁰ The greater trochanter is usually preserved and continues to grow whereas the femoral epiphysis is damaged which disturbs hip biomechanics. There are a number of procedures to correct the mechanical imbalance, such as trochanteric epiphysiodesis [71], trochanteric advancement [72] and a lateral closing wedge along with trochanteric advancement.

Residual dysplasia

Acetabular index measures the severity of the residual dysplasia. In current literature, the definition of acetabular dysplasia is inconsistent [73]. Gwynne *et al.* defines dysplasia as definite if the acetabular index is more than 30 degrees at 6-month X-rays (corresponding to more than 2 SD above normal at this age) and as mild if greater than 25 degrees [74]. Cashman reported a 3.5% incidence of residual acetabular dysplasia in his study [75]. Acetabulum remodels in response to the pressure exerted by the femoral head after concentric reduction. However, this process may remain inefficient and results in a shallow acetabulum providing inadequate coverage and poor outcome [76]. This can be treated by acetabular reorientation surgery [77].

Prognosis

Overall, the prognosis for children treated for hip dysplasia is very good, especially if the dysplasia is managed with closed treatment. If closed treatment is unsuccessful and open reduction is needed, the outcome may be less favourable although the short-term outcome appears to be satisfactory.

If secondary procedures are needed to obtain reduction, then the overall outcome is significantly worse. Some authors believe that patients with bilateral hip dysplasia have a poorer prognosis because of frequent delays in diagnosis and greater

treatment requirements [24, 25].

In a study comparing the outcomes of walking-age children with bilateral hip dislocations who underwent open reduction and pelvic osteotomy with or without femoral osteotomy with those of walking-age children with unilateral dislocated hips who underwent the same set of procedures, the radiographic outcomes were similar [26]. In this study, the rate of osteonecrosis was higher in the bilateral group, but this difference was explained by older age at surgery and a greater degree of hip dislocation before surgery. The authors concluded that the clinical outcomes after surgery of the children with bilateral hip dislocations were worse mainly because of asymmetric outcomes.

Conclusion

Developmental dysplasia of the hip is a challenging condition. Formal training in the treatment of various age groups with DDH is mandatory. Paediatricians and family physicians should have a high index of suspicion and referral to a paediatric orthopaedic surgeon should be made early. The outcome of treatment during the first six months of life is much better than in late-diagnosed DDH. Successful treatment with Orthoses requires careful counselling of parents. Surgical management requires careful pre-operative planning and adequate follow up to ensure the best clinical outcomes.

References

1. Sankar WN, Weiss J, Skaggs DL. Orthopaedic conditions in the newborn. *J Am Acad Orthop Surg.* 2009; 17(2):112-22. [Medline].
2. Karmazyn BK, Gunderman RB, Coley BD, Blatt ER, Bulas D, Fordham L. ACR Appropriateness Criteria on developmental dysplasia of the hip--child. *J Am Coll Radiol.* 2009; 6(8):551-7. [Medline].
3. AIUM practice guideline for the performance of an ultrasound examination for detection and assessment of developmental dysplasia of the hip. *J Ultrasound Med.* 2009; 28(1):114-9. [Medline].
4. Janssen D, Kalchschmidt K, Katthagen BD. Triple pelvic osteotomy as treatment for osteoarthritis secondary to developmental dysplasia of the hip. *Int Orthop.* 2009; 33(6):1555-9. [Medline].
5. El-Sayed M, Ahmed T, Fathy S, Zyton H. The effect of Dega acetabuloplasty and Salter innominate osteotomy on acetabular remodelling monitored by the acetabular index in walking DDH patients between 2 and 6 years of age: short- to middle-term follow-up. *J Child Orthop.* 2012; 6(6):471-477. [Medline]. [Full Text].
6. McKibbin B. Anatomical factors in the stability of the hip joint in the newborn. *J Bone Joint Surg Br.* 1970; 52(1):148-59. [Medline]. [Full Text].
7. Rális Z, McKibbin B. Changes in shape of the human hip joint during its development and their relation to its stability. *J Bone Joint Surg Br.* 1973; 55(4):780-5. [Medline]. [Full Text].
8. Skirving AP, Scadden WJ. The African neonatal hip and its immunity from congenital dislocation. *J Bone Joint Surg Br.* 1979; 61-B(3):339-41. [Medline]. [Full Text].
9. Ziegler J, Thielemann F, Mayer-Athenstaedt C, Günther KP. [The natural history of developmental dysplasia of the hip. A meta-analysis of the published literature]. *Orthopade.* 2008; 37(6):515-6, 518-24. [Medline].
10. Getz B. The hip joint in Lapps and its bearing on the problem of congenital dislocation. *Acta Orthop Scand*

- Suppl. 1955; 18:1-81. [Medline].
11. Hoaglund FT, Yau AC, Wong WL. Osteoarthritis of the hip and other joints in southern Chinese in Hong Kong. *J Bone Joint Surg Am.* 1973; 55(3):545-57. [Medline].
 12. Rabin DL, Barnett CR, Arnold WD, Freiburger RH, Brooks G. Untreated congenital hip disease: a study of the epidemiology, natural history, and social aspects of the disease in a Navajo population. *Am J Public Health Nations Health.* 1965; 55:1-44. [Medline].
 13. Bjerkreim I, Arseth PH. Congenital dislocation of the hip in Norway. Late diagnosis CDH in the years 1970 to 1974. *Acta Paediatr Scand.* 1978; 67(3):329-32. [Medline].
 14. Wilkinson JA. A post-natal survey for congenital displacement of the hip. *J Bone Joint Surg Br.* 1972; 54(1):40-9. [Medline]. [Full Text].
 15. Carter CO, Wilkinson JA. Genetic and environmental factors in the etiology of congenital dislocation of the hip. *Clin Orthop Relat Res.* 1964; 33:119-28. [Medline].
 16. Salter RB. Etiology, pathogenesis and possible prevention of congenital dislocation of the hip. *Can Med Assoc J.* 1968; 98(20):933-45. [Medline]. [Full Text].
 17. Ramsey PL, Lasser S, MacEwen GD. Congenital dislocation of the hip. Use of the Pavlik harness in the child during the first six months of life. *J Bone Joint Surg Am.* 1976; 58(7):1000-4. [Medline]. [Full Text].
 18. Kumar SJ, MacEwen GD. The incidence of hip dysplasia with metatarsus adducts. *Clin Orthop Relat Res.* 1982; 164:234-5. [Medline].
 19. Weiner DS. Congenital dislocation of the hip associated with congenital muscular torticollis. *Clin Orthop Relat Res.* 1976; 121:163-5. [Medline].
 20. Dunn PM. Perinatal observations on the etiology of congenital dislocation of the hip. *Clin Orthop Relat Res.* 1976; 119:11-22. [Medline].
 21. Kutlu A, Memik R, Mutlu M, Kutlu R, Arslan A. Congenital dislocation of the hip and its relation to swaddling used in Turkey. *J Pediatr Orthop.* 1992; 12(5):598-602. [Medline].
 22. Barlow TG. Early diagnosis and treatment of congenital dislocation of the hip. *J Bone Joint Surg Br.* 1962; 44-B:292-301. [Full Text].
 23. Sankar WN, Young CR, Lin AG, Crow SA, Baldwin KD, Moseley CF. Risk Factors for Failure After Open Reduction for DDH: A Matched Cohort Analysis. *J Pediatr Orthop.* 2011; 31(3):232-9. [Medline].
 24. Greene WB, Drennan JC. A comparative study of bilateral versus unilateral congenital dislocation of the hip. *Clin Orthop Relat Res.* 1982; (162):78-86. [Medline].
 25. Zions LE, MacEwen GD. Treatment of congenital dislocation of the hip in children between the ages of one and three years. *J Bone Joint Surg Am.* 1986; 68(6):829-46. [Medline].
 26. Wang TM, Wu KW, Shih SF, Huang SC, Kuo KN. Outcomes of open reduction for developmental dysplasia of the hip: does bilateral dysplasia have a poorer outcome? *J Bone Joint Surg Am.* 2013; 95(12):1081-6. [Medline].
 27. Sewell MD, Rosendahl K, Eastwood DM; Developmental dysplasia of the hip. *BMJ.* 2009; 339:b4454. doi: 10.1136/bmj.b4454.
 28. Shorter D, Hong T, Osborn DA. Cochrane Review: Screening programmes for developmental dysplasia of the hip in newborn infants. *Ev id Based Child Health.* 2013; 8(1):11-54. doi: 10.1002/ebch.1891.
 29. Laborie LB, Engesaeter IO, Lehmann TG. Screening strategies for hip dysplasia: long-term outcome of a randomized controlled trial. *Pediatrics.* doi: 10.1542/peds.2013-0911. Epub 2013 Aug 19. 2013; 132(3):492-501.
 30. Newborn, Infant Physical Examination Programme: Handbook 2016/17; Public Health England 10. Choudry Q, Goyal R, Paton RW; Is limitation of hip abduction a useful clinical sign in the diagnosis of developmental dysplasia of the hip? *Arch Dis Child.* 2013; 98(11):862-6. doi:
 31. Gordis L. The scope of screening. *J Med Screening* 1994; 1:98-100.
 32. Hansson G, Nachemson A, Palmén K. Screening of children with congenital dislocation of the hip joint on the maternity wards in Sweden. *J Pediatr Orthop.* 1983; 3:271-9.
 33. Bennett GC. Screening for congenital dislocation of the hip. *J Bone Joint Surg [Br].* 1992; 74-B:643-44.
 34. Lennox IAC, Mc Laughlan, Murali R. Failures of screening and management of congenital dislocation of the hip. *J Bone Joint Surg [Br].* 1993; 75-B:72-75.
 35. Editorial. Screening for congenital hip dysplasia. *Lancet.* 1991; 337:947-48.
 36. McKee L. Screening babies for hip dislocation is not effective. *Br Med J.* 1998; 316:1261.
 37. Tredwell SJ. Neonatal screening for hip joint instability: its clinical and economic relevance. *Clin Orthop.* 1992; 281:63-8.
 38. Fulton MJ, Barer ML. Screening for congenital dislocation of the hip: an economic appraisal. *Can Med Assoc J.* 1984; 130(9):1149-56.
 39. Paton RW, Srinivasan MS, Shah B. Ultrasound screening for hips at risk in developmental dysplasia of the hip: is it worth it?
 40. Maxwell SL, Ruiz AL, Lappin KJ. Clinical screening for developmental dysplasia of the hip in Northern Ireland. *BMJ.* 2002; 324:1031-3. [PMC free article] [PubMed]
 41. Umer M, Nawaz H. Developmental dysplasia of hip--where do we stand? *J Pak Med Assoc.* 2008; 58:2-4. [PubMed]
 42. Hedequist D, Kasser J, Emans J. Use of an abduction brace for developmental dysplasia of the hip after failure of Pavlik harness use. *J Pediatr Orthop.* 2003; 23:175-7. [PubMed]
 43. Tucci JJ, Kumar SJ, Guille JT. Late acetabular dysplasia following early successful Pavlik harness treatment of congenital dislocation of the hip. *J Pediatr Orthop.* 1991; 11:502-5. [PubMed]
 44. Mubarak S, Garfin S, Vance R. Pitfalls in the use of the Pavlik harness for treatment of congenital dysplasia, subluxation, and dislocation of the hip. *J Bone Joint Surg Am.* 1981; 63:1239-48. [PubMed]
 45. Rombouts JJ, Kaelin A. Inferior (obturator) dislocation of the hip in neonates: A complication of treatment by the Pavlik harness. *J Bone Joint Surg Br.* 1992; 74:708-10. [PubMed]
 46. Grill F, Bensahel H, Canadell J. The Pavlik harness in the treatment of congenital dislocating hip: Report on a multicenter study of the European Paediatric Orthopaedic Society. *J Pediatr Orthop.* 1988; 8:1-8. [PubMed]
 47. Nakamura J, Kamegaya M, Saisu T. Treatment for developmental dysplasia of the hip using the Pavlik

- harness: long-term results. *J Bone Joint Surg Br.* 2007; 89:230-5. [PubMed]
48. Carney BT, Clark D, Minter CL. Is the absence of the ossific nucleus prognostic for a vascular necrosis after closed reduction of developmental dysplasia of the hip? *J Surg Orthop Adv.* 2004; 3:24-9. [PubMed]
 49. Segal LS, Boal DK, Borthwick L. Avascular necrosis following treatment of DDH: The protective influence of the ossific nucleus. *J Pediatr Orthop.* 1999; 19:177-84. [PubMed]
 50. Roposch A, Stöhr KK, Dobson M. The effect of the femoral head ossific nucleus in the treatment of developmental dysplasia of the hip. A meta-analysis. *J Bone Joint Surg Am.* 2009; 91:911-8. [PubMed]
 51. Konigsberg DE, Karol LA, Colby S. Results of medial open reduction of the hip in infants with developmental dislocation of the hip. *J Pediatr Orthop.* 2003; 23:1-9. [PubMed].
 52. Luhmann SJ, Bassett GS, Gordon JE. Reduction of a dislocation of the hip due to developmental dysplasia: Implications for the need for future surgery. *J Bone Joint Surg Am.* 2003; 85:239-43. [PubMed]
 53. Gage JR, Winter RB. Avascular necrosis of the capital femoral epiphysis as a complication of closed reduction of congenital dislocation of the hip: A critical review of twenty years' experience at Gillette Children's Hospital. *J Bone Joint Surg Am.* 1972; 54:373-88. [PubMed]
 54. DeRosa GP, Feller N. Treatment of congenital dislocation of the hip: Management before walking age. *Clin Orthop Relat Res.* 1987; 225:77-85. [PubMed]
 55. Tavares JO, Gottwald DH, Rochelle JR. Guided abduction traction in the treatment of congenital hip dislocation. *J Pediatr Orthop.* 1994; 14:643-9. [PubMed]
 56. Quinn RH, Renshaw TS, DeLuca PA. Preliminary traction in the treatment of developmental dislocation of the hip. *J Pediatr Orthop.* 1994; 14:636-42. [PubMed]
 57. Weinstein SL. Traction in developmental dislocation of the hip: Is its use justified? *Clin Orthop Relat Res.* 1997; 338:79-85. [PubMed]
 58. Weinstein S. Closed versus open reduction of congenital hip dislocation in patients under 2 years of age. *Orthopedics.* 1990; 12:221-7. [PubMed]
 59. Dhar S, Taylor JF, Jones WA. Early open reduction for congenital dislocation of the hip. *J Bone Joint Surg Br.* 1990; 72:175-80. [PubMed]
 60. Schoenecker PL, Strecker WB. Congenital dislocation of the hip in children: Comparison of the effects of femoral shortening and of skeletal traction in treatment. *J Bone Joint Surg Am.* 1984; 66:21-7. [PubMed]
 61. Sankar WN, Tang EY, Moseley CF. Predictors of the need for femoral shortening osteotomy during open treatment of developmental dislocation of the hip. *J Pediatr Orthop.* 2009; 29:868-71. [PubMed]
 62. Spence G, Hocking R, Wedge JH. Effect of innominate and femoral varus derotation osteotomy on acetabular development in developmental dysplasia of the hip. *J Bone Joint Surg Am.* 2009; 91:2622-36. [PubMed]
 63. Wenger DR. Congenital hip dislocation: Techniques for primary open reduction including femoral shortening. *Instr Course Lect.* 1989; 38:343-54. [PubMed]
 64. Bohm P, Brzuske A. Salter innominate osteotomy for the treatment of developmental dysplasia of the hip in children. Results of seventy three consecutive osteotomy after twenty-six to thirty-five years of follow-up. *J Bone Joint Surg.* 2002; 84A:178-86. [PubMed]
 65. Thomas SR, Wedge JH, Salter RB. Outcome at forty-five years after open reduction and innominate osteotomy for late-presenting developmental dislocation of the hip. *J Bone Joint Surg Am.* 2007; 89:2341-50. [PubMed]
 66. El-Sayed MM. Single-stage open reduction, Salter innominate osteotomy, and proximal femoral osteotomy for the management of developmental dysplasia of the hip in children between the ages of 2 and 4 years. *J Pediatr Orthop B.* 2009; 18:188-96. [PubMed]
 67. Staheli LT, Chew DE. Slotted acetabular augmentation in childhood and adolescence. *J Pediatr Orthop.* 1992; 12:569-80. [PubMed]
 68. Keret D, MacEwen GD. Growth disturbance of the proximal part of the femur after treatment for congenital dislocation of the hip. *J Bone Joint Surg Am.* 1991; 73:410. [PubMed]
 69. Weiner DS, Hoyt WA, Jr O'Dell HW. Congenital dislocation of the hip: the relationship of premanipulative traction and age to a vascular necrosis of the femoral head. *J Bone Joint Surg Am.* 1977; 59:306-11. [PubMed]
 70. Salter RB, Kostuik J, Dallas S. Avascular necrosis of the femoral head as a complication of treatment for congenital dislocation of the hip in young children: A clinical and experimental investigation. *Can J Surg.* 1969; 12:44-61. [PubMed]
 71. Iversen LJ, Kalen V, Eberle C. Relative trochanteric overgrowth after ischemic necrosis in congenital dislocation of the hip. *J Pediatr Orthop.* 1989; 9:381-5. [PubMed]
 72. Macnicol MF, Makris D. Distal transfer of the greater trochanter. *J Bone Joint Surg Br.* 1991; 73:838-41. [PubMed]
 73. Dornacher D, Cakir B, Reichel H. Early radiological outcome of ultrasound monitoring in infants with developmental dysplasia of the hips. *J Pediatr Orthop B.* 2010; 19:27-31. [PubMed]
 74. Gwynne Jones DP, Vane AGS, Coulter G. Ultrasound measurements in the management of unstable hips treated with the Pavlik harness. *J Pediatr Orthop.* 2006; 26:818-22. [PubMed]
 75. Cashman JP, Round J, Taylor G. The natural history of developmental dysplasia of the hip after early supervised treatment in the Pavlik harness. *J Bone Joint Surg Br.* 2002; 84:418-25. [PubMed]
 76. Albiñana J, Morcuende JA, Weinstein SL. The teardrop in congenital dislocation of the hip diagnosed late: a quantitative study. *J Bone Joint Surg Am.* 1996; 78:1048-55. [PubMed]
 77. Kim HT, Kim JI, Yoo CI. Acetabular development after closed reduction of developmental dislocation of the hip. *J Pediatr Orthop.* 2000; 20:701-8. [PubMed]