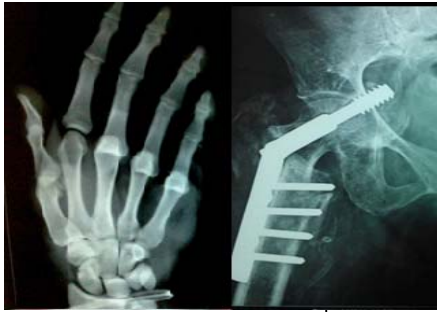



International Journal of Orthopaedics Sciences

ISSN: 2395-1958
IJOS 2017; 3(3): 1062-1066
© 2017 IJOS
www.orthopaper.com
Received: 24-05-2017
Accepted: 25-06-2017

Dr. Nilesh Indulal Kachnerkar
Assistant Professor, Department
of Orthopaedics, Government
Medical College Aurangabad,
India

Dr. Nikhil Lakde
Resident Doctor, Department of
Orthopaedics, Government
Medical College Aurangabad,
India.

Dr. Sharad Salokhe
Resident Doctor, Department of
Orthopaedics, Government
Medical College Aurangabad,
India

Neglected old posterior dislocation of elbow: Treatment and results of open reduction

Dr. Nilesh Indulal Kachnerkar, Dr. Nikhil Lakde and Dr. Sharad Salokhe

DOI: <https://doi.org/10.22271/ortho.2017.v3.i3o.154>

Abstract

Neglected old dislocations of elbow are found only in developing countries in significant numbers and there is very less literature of this condition from developed countries. It is a huge challenge for orthopaedic surgeons in developing countries as even after treatment it is difficult to achieve full range of motion and function in a neglected case. In this article we report treatment and results of one of the largest series of 15 cases on neglected posterior elbow dislocation. Our management protocol was opening joint through posterior approach and using Speed Technique doing a V-Y plasty for triceps and most of times fixing reduced joint by 2 diverging k wires. At one year follow up

Keywords: Neglected elbow dislocation, open reduction, Speed V-Y plasty technique, Stiffness

1. Introduction

Neglected dislocations of elbow are rarely found in developed world but is quite a common phenomenon in developing countries. Because of the misconceptions associated and less compliance with rehabilitation it's a huge challenge for treatment to orthopaedic surgeons. Neglected old dislocation are defined as those posterior dislocations of elbow which are not treated or reduced within three weeks of injury [1-3]. These patients present late with very little range of motion of elbow for activity of daily living and hence their treatment becomes mandatory of any future functional requirement [2,4]. The time since injury and age of patient determine mode of treatment [3, 5]. Most authors recommend open reduction for late presenting cases upto 3 months after injury [1, 6, 7]. Functional outcome of open reduction is inversely proportional to time since injury [7]. Total elbow replacement, excisional arthroplasty and arthrodesis is advised for cases presenting late after 3 months[a], though no concrete treatment protocols exists for late cases. We in our series of 15 patients present the results of elbows treated by open reduction, regardless of time since injury.

2. Material and Methods

Between the period April 2015 to August 2017, ten men and five women a total of 15 patients which is one of the largest series reported yet were treated at our institute for neglected old posterior dislocation of elbow. The time since injury ranged from 1 to 6 months. All most all the patients had taken some form of traditional non-medical treatment. Elbow stiffness and pain were the main indications for surgery. On examinations patient presented with anteriorly prominent distal humerus, olecranon was prominent and shortened triceps, the three point relationship of elbow was disturbed. The joints were fixed with only a few degrees of range of movements. The active range of elbow movements were measured using a handheld goniometer (Table 1 all patient details). All patients were preoperatively evaluated using Mayo Elbow Performance Index [MEPI] (table 2). All patients were treated with open reduction and fixation with k wires and also in some cases associated fractures were fixed.

2.1 Surgical Operative Technique

The patient was positioned laterally on operation theatre table with arm support at elbow so that full flexion and extension can be carried out. The procedure was carried out either under general anesthesia or regional anesthetic block under tourniquet control. Speed's procedure for

Correspondence

Dr. Nilesh Indulal Kachnerkar
Assistant Professor, Department
of Orthopaedics, Government
Medical College Aurangabad,
India

open reduction was used [1] in all cases. Midline posterior incision was taken, skin flaps elevated, ulnar nerve isolated and protected, Seeds V-Y plasty done for triceps muscle[fig.2c]. Dense fibrous tissue filled up the olecron fossa, coronoid fossa, and the radial head, whilst the collateral ligaments were contracted. The fibrous tissue was carefully excised, the contracted capsule and collateral ligaments were cut, myositis ossificans was excised when obstructing reduction. Radio-capitular and ulno-trochlear reduction was achieved by manipulation, associated fractures were fixed according to the standard procedures and most of the times the joint was found unstable so it was held in reduced position by 2 k-wires of size 2.5mm in diversing configuration in ulno-humeral direction. The V-Y plasty repaired, wash given, drain kept and all the incision was closed in layers, dressing done, posterior above elbow slab was applied. Drain was removed after 48 hours, i.v. antibiotics were given for 3 days then patient was shifted to oral antibiotics for 5

days, sutures were removed on 12th day and k-wires were removed after 2 weeks. Pronation and Supination were started at 2 weeks but flexion and extension were started only after 4 weeks for fear of redislocation [1], elbow pouch was continued in between exercises, muscle strengthening exercises were begun after 6 weeks.

The Mayo Elbow Performance Index was used to asses function of elbow preoperatively, postoperatively and at all follow ups. Depending on Mayo scores results were rated as excellent (90-100), good (75-89), fair (60-74), or poor(<60). The follow up radiographs were evaluated for articular alignment and post traumatic arthrosis using rating scale by Broberg and Morrey [11]. Absence of radiographic was defined as grade 0, slight joint narrowing as grade 1, moderate joint space narrowing with minimal osteophytes as grade 2, and severe degenerated changes with loss of joint space as grade 3.

Table 1: Patient characteristics and outcomes

Case No.	1	2	3	4	5	6	7	8	9	10	11	12	13	14	15
Age	18	21	25	26	30	22	31	33	40	19	20	22	35	38	42
Sex	M	M	M	F	M	M	F	F	F	M	M	F	M	M	M
Side	R	L	R	R	R	R	R	L	L	L	R	L	R	L	R
Duration of dislocation (months)	1	2	4	2	4	4	3	5	6	6	1	4	4	6	6
Mode of injury	fall	fall	fall	RTA	RTA	fall	fall	RTA	fall	RTA	RTA	fall	fall	RTA	RTA
Associated Fracture	-	-	Radial head	Radial head	-	-	-	Med. Condyle	-	-	Terrible triad	-	-	-	Captulum.
Pre-op ROM	10 To 35	30 To 55	15 To 35	15 To 40	20 To 45	20 To 45	15 To 30	15 To 30	20 To 45	15 To 55	15 to 30	15 To 55	20 To 45	10 To 35	15 To 30
Pre-op MEPI	25	10	20	40	25	25	15	15	25	10	40	10	25	25	40
Post-op ROM	70 to 100	15 To 90	25 To 110	10 To 110	10 To 70	20 To 85	15 To 95	15 To 100	20 To 85	15 To 90	10 To 110	15 To 90	10 To 70	70 To 95	10 To 110
Post-op MEPI	80	75	75	95	55	70	80	75	70	75	95	75	55	85	95
Grade result	G	G	G	E	P	F	G	G	F	G	E	G	P	G	E
Follow up (months)	18	12	14	12	24	12	18	16	28	24	20	20	22	20	18
Complications	-	-	Stiff.	-	-	-	-	Inftn.	-	-	Necrosis	-	-	-	Inftn

*RTA=road traffic accident, *Inftn= infection, Stiff=stiffness, *Med.Condyl=medial condyle, Captulum.=capetullum.

Table 2: Mayo Elbow Performance Index Score

PAIN (Max.,45 points)	<ul style="list-style-type: none"> • None(45 points) • Mild(30 points) • Moderete(15 points) • Severe(0 points)
Range Of Motion (Max.,20 points)	<ul style="list-style-type: none"> • Arc >100 degrees (20 points) • Arc 50 to 100 degrees (15 points) • Arc < 50 degrees (5 points)
Stability (Max.,10 points)	<ul style="list-style-type: none"> • Stable (10 points) • Moderately unstable (5 points) • Grossly unstable (10 points)
Function (Max.,25 points)	<ul style="list-style-type: none"> • Able to comb hair (5 points) • Able to feed oneself (5 points) • Able to perform personel hygiene task (5 points) • Able to on shirt (5 points) • Able to put on shoes (5 points)

3. Results

The mean age of patients was 28 years (18-42). The majority of patients were male 66% (10 out of 15). The mode of injury was mainly fall 60% and road traffic accidents 40% cases. All 15 cases were treated by traditional ways before coming to our hospital. The mean operating time was 90 (range, 60-150) minutes. The mean follow up period was 18 months (range, 12-28). Based on the Mayo Elbow Performance Index [10], at the final follow up, 13 patients had satisfactory outcomes (3 excellent, 8 good, 2 fair) and 2 had poor outcomes, the mean score was 77. 10 patients had no pain, 3 had mild pain and 2 had moderate pain during weight lifting. At final follow up no patient had any sign of instability; the mean score was 10. The mean arc of flexion was 100 degrees (range, 40 to 130). The mean arc of pronation supination was 140 degrees with all achieving more than 100 degrees arc. All patients regained functional range of movements with most activities of daily living possible. All 15 patients had no difficulty in performing functional task.

Complications: 2 patients had superficial skin infection which recovered with i.v antibiotics, 1 patient had severe stiffness which recovered functional ROM by physiotherapy and 1 patient had necrosis of skin flaps which required split thickness skin graft.

4. Discussion

The neglected dislocations of elbow are rare in west but still frequent presentations in developing countries, delay in treatment is due to resort to traditional quaks [21]. These bonesetters use massage and forcefull manipulation which increase complications [22]. Most authors agree on treatment consensus and recommend closed reduction for elbow dislocation upto 3 weeks post injury. After that closed reduction can be more hazardous than beneficial [1-3]. Most authors advise open reduction from 3 weeks to 3 months, total elbow replacement, excisional arthroplasty and arthrodesis is recommended thereafter [1, 5, 6]. Arthrodesis is reserved for heavy workers and arthroplasty for good ROM. Open reduction is not advised after 3 months of dislocation for fear of cartilage damage [6, 7]. But in our study series we achieved satisfactory results with surgery upto 6 months and these findings are consistent with those of another study achieving similar results by open reduction upto 2 years [2].

Associated fractures with neglected elbow dislocation has poor prognosis compared to those without fractures [6]. In our series we had 5 patients having associated fractures. we had 2 patients with radial head fracture, 1 with medial condyle, 1 with capetulum and 1 with terrible triad fracture, all these fracture were fixed during open reduction. These patients had less ROM than others but they were able to perform activity of daily living.

Mahaisavariya etal recommended open reduction without triceps lengthening in dislocations from 1 to 3 months old [17]. On the other hand in other study recommended lengthening in elbows dislocated for 60 months [18]. We found that Speed's V-Y plasty aided in easy reduction and infact lengthened the contracted triceps muscle.

Some authors recommend open reduction and hinged external fixation to facilitate early rehabilitation and good stability [19, 20]. But our study with open reduction and k wire fixation with supervised postoperative rehab protocols have achieved equally good results. We removed sutures at 12 days, removed k wires at 2 weeks and started supination-pronation. we allowed flexion-extension at 4 weeks in between elbow was kept in support, started muscle strengthening exercises at 6 weeks.

5. Conclusion

The results of open reduction and fixation of neglected old posterior dislocation of elbow are both assuring and satisfying irrespective of duration of dislocation, age of patient or preoperative range of motion provided a supervised physiotherapy protocol is followed. In our series of study we were able to achieve functional, stable and painless elbows so its really worth to give attempt of open reduction in neglected old elbow dislocations contraray to the popular belief. Limited large series literature is available on this topic and much research is need for commom consensus.

Case 1

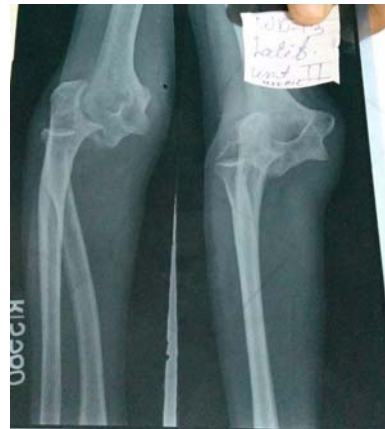

Fig 1a: Preoperative X ray of neglected elbow dislocation

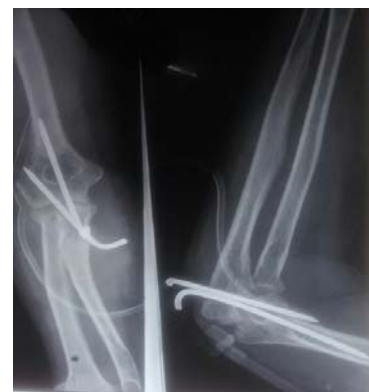

Fig 1b: postoperative x ray with k wires

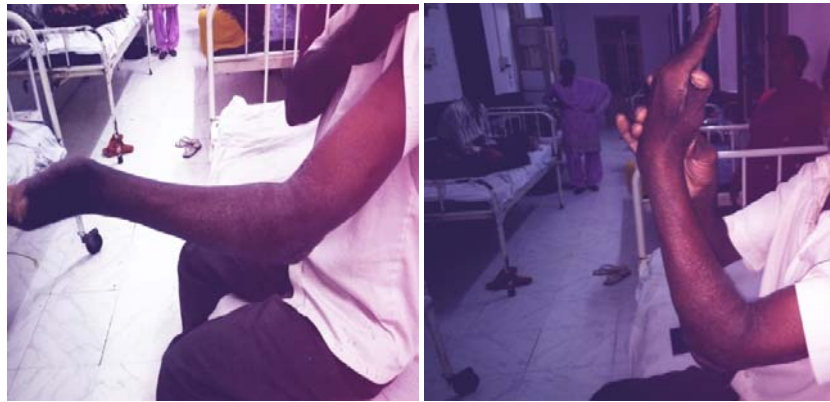

Fig1c: postoperative range of movements

Case 2

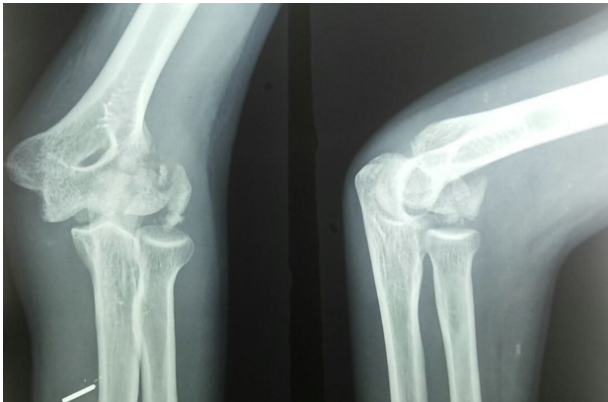


Fig 2a: preoperative x ray with fracture capitulum and dislocation

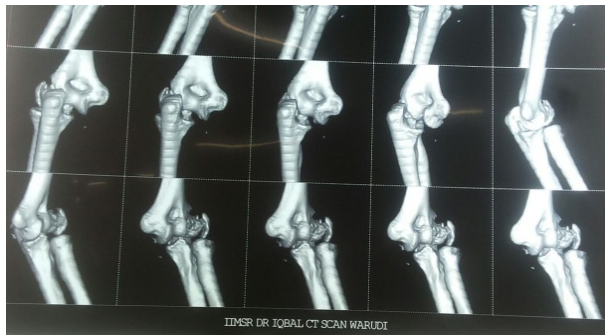

Fig 2b: 3D CT elbow

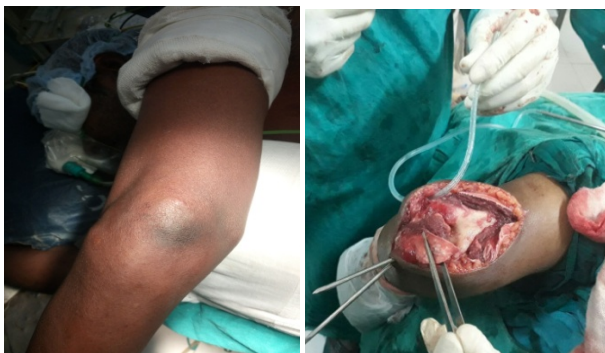

Fig 2c: Speed technique of V-Y plasty

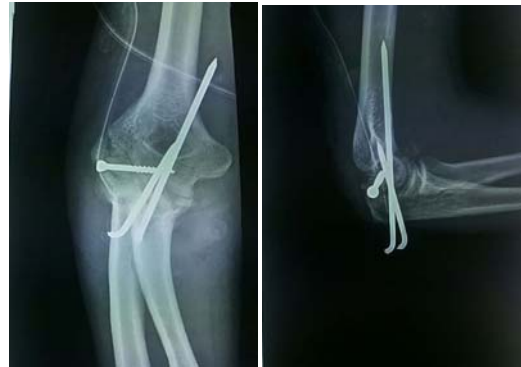

Fig 2d: postoperative x ray with cc screw and k wires

Case 3

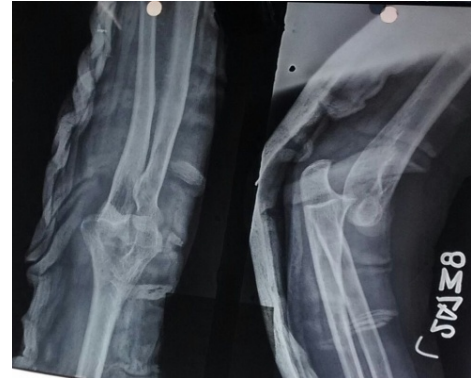

Fig 3a: preoperative x ray of 4 months old dislocation

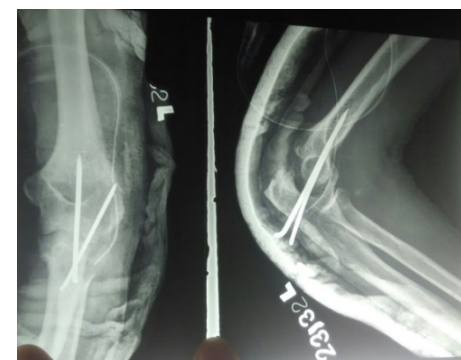


Fig 3b: postoperative x ray showing reduced but distracted joint space

6. References

1. Freeman BL III. Old unreduced dislocations. In: Crenshaw AH, editor. Campbells operative orthopaedics. 9th ed. St Louis: Mosby, 1998; I:2673-4.
2. Rockwood CA. Treatment of old unreduced posterior dislocation of elbow. In: Rockwood CA, editor. Rockwood and Green's fracture in adults. 4th ed. Philadelphia: Lippincot-Raven; 1996; I:975-6.
3. Naidoo KS. Unreduced posterior dislocation of the elbow. J Bone Joint Surg Br. 1982; 64:603-6.
4. Morrey BF, Askew LJ, Chao EY. A biomechanical study of normal function of elbow motion. J Bone Joint Surg Am. 1981; 63:872-7.
5. Fowles JV, Kassab MT, Douik M. Untreated posterior dislocation in children. J Bone Joint Surg Am. 1984; 66:921-6.
6. Bruce C, Laing P, Dorang J, Kleneman L. Unreduced dislocation of the elbow: Case report and review of literature. J Trauma. 1993; 35:962-5.
7. Allende G, Freyetes M. Old dislocation of the elbow. J Bone Joint Surg. 1944; 26:691-706.
8. Arafles RP. Neglected posterior dislocation of elbow. A reconstruction operation. J Bone Joint Surg Br. 1987; 69:199-202.
9. Benjamin A. Treatment of old unreduced dislocation of the elbow. In: Wilson JN, editor. Watson-Jones fracture and joint injuries. New Delhi: Churchill Livingstone, 1998, 630-5.
10. Morrey BF, Adams RA. Semiconstrained arthroplasty for the treatment of rheumatoid arthritis of elbow. J Bone Joint Surg Am. 1992; 74:479-90.
11. Broberg MA, Morrey BF. Results of treatment of fracture dislocation of the elbow. Clin Orthop Relat Res. 1987; 216:109-19.
12. Billett DM. Unreduced posterior dislocation of elbow. J Trauma. 1979; 19:186-8.
13. Protzman RR. Dislocation of the elbow joint. J Bone Joint Surg Am. 1978; 60:539-41.
14. Roberts PH. Dislocation of the elbow. Br J Surg. 1969; 56:806-15.
15. Purser DW. Dislocation of the elbow and inclusion of the medial epicondyle in the adult. J Bone Joint Surg Br. 1954; 36:247-9.
16. Ring D, Jupiter JB, Zilberfarb J. Posterior dislocation of the elbow with fracture of the radial head and coronoid. J Bone Joint Surg Am. 2002; 84:547-51.
17. Mahaisavariya B, Laupattarakasem W. Neglected dislocation of the elbow. Clin Orthop Relat Res. 2005; 431:21-5.
18. Mahaisavariya B, Laupattarakasem W, Supachutikul A, Taesiri H, Sujaribudhunkoon S. Late reduction of the dislocated elbow. Need triceps be lengthened? J Bone Joint Surg Br. 1993; 75:426-8.
19. Jupiter JB, Ring D. Treatment of unreduced elbow dislocation with hinged external fixation. J Bone Joint Surg Am. 2002; 84:1630-5.
20. Lo CY, Chang YP. Neglected elbow dislocation in a young man: treatment by open reduction and elbow fixator. J Shoulder Elbow Surg. 2004; 13:101-4.
21. Mehta S, Sud A, Tiwari A, Kapoor SK. Open Resduction for Late-Presenting Posterior Dislocation of the Elbow. Journal of Orthopaedic Surgery (Hong Kong), 2007; 15:15-21.
22. Coulibaiya NF, Teimdjoa H, Sanea AD, Sarr YF, Ndiaye S. Posterior Approach for Surgical Treatment of