



International Journal of Orthopaedics Sciences

ISSN: 2395-1958
IJOS 2017; 3(3): 937-940
© 2017 IJOS
www.orthopaper.com
Received: 09-05-2017
Accepted: 10-06-2017

Dr. Khadabadi NA
Assistant Professor,
Department of Orthopaedics
KLE University's Jawaharlal
Nehru Medical College, Belagavi
Karnataka, India

Dr. Saidapur SK
Assistant Professor,
Department of Orthopaedics
KLE University's Jawaharlal
Nehru Medical College, Belagavi
Karnataka, India

Is PHILOS as good as it sounds to be? Analysis of complications and functional outcome of PHILOS plating

Dr. Khadabadi NA and Dr. Saidapur SK

DOI: <https://doi.org/10.22271/ortho.2017.v3.i3m.139>

Abstract

Aim: Proximal humeral fractures have posed a challenge for internal fixation. Among several methods, most recently, PHILOS (Proximal humeral Internal Locking system) plates have been promoted as most effective method to achieve fixation and union. However, there are no enough studies evaluating the complications and outcome of PHILOS plating. Some studies have shown complication rates ranging from 3.7% to 33.5%. So with this study, we aim to analyze the efficacy and the functional outcome following open reduction and internal fixation with PHILOS plate for displaced proximal humerus fractures.

Methodology: In this study, we identified 38 patients in our orthopaedic unit treated surgically by open reduction and internal fixation using the proximal humeral internal locking system (PHILOS) plate from January 2013 to December 2016. All those patients who had a radiographic and regular clinical follow-up for at least 6 months were included in the analysis. Surgery was done for displaced 2-part, 3-part and 4-part proximal humerus fractures (Neer's Classification) through deltopectoral approach during the time period. Six patients who did not fit into inclusion criteria, did not attend regular follow-up or had incomplete records were excluded from analysis. The study group comprising 32 patients was analyzed for complications and functional outcome by studying patient records and x-rays. The functional outcome was measured using Constant shoulder scoring system.

Results: 68% of the patients were males (22 males and 10 females) and male to female ratio was 2.2:1. The mean age of the patients was 47 ± 16 years (Range 31-63 years). Involvement of left side proximal humerus fracture was more common (58%). 55% patients had 2-part fracture according to Neer's classification. The range of movements at first, second and third follow ups increased gradually during subsequent follow ups. According to Constant Shoulder scores, 50% of the patients had excellent outcome followed by 21.9% good, 12.5% fair and 15.6% poor outcome. Total of 7 patients out of 32 had complications (21.8%) and most common complications noted were inadequate reduction, subacromial impingement, adhesive capsulitis and loss of varus reduction. There were no nerve injuries or infection.

Conclusion: Proximal humeral internal locking system (PHILOS) plate for the treatment of proximal humerus fractures leads to a satisfactory functional outcome in majority of the patients. However, functional results depend on correct anatomical reduction of the fracture and stable fixation. Complications still occur due to fracture severity and lack of technical expertise. However, complications like inadequate reduction, varus malalignment, subacromial impingement can still occur with this system. Varus malalignment was found to be a strong predictor of poor functional outcome.

Keywords: Proximal humeral internal locking system (PHILOS) plate; Proximal humerus fractures. Functional outcome, complications

Introduction

Proximal humerus fractures (PHFs) accounts for approximately 4-5% of all the fractures and is next to hip fractures and distal radius fractures in the elderly population. The incidence is approximately 3/10,000 persons a year and is rapidly increasing with age ^[1-3] Women are affected twice as often as men ^[2]

The majority of patients with this fracture are elderly, which increases the risk for their bones to be osteoporotic or brittle. The quality of the bone seems to be crucial both for the surgical intervention and the functional outcome ^[2]. Furthermore, an elderly patient's physical and sometimes mental fragility can create difficulties during the rehabilitation to return to normal

Correspondence
Dr. Saidapur SK
Assistant Professor,
Department of Orthopaedics
KLE University's Jawaharlal
Nehru Medical College, Belagavi
Karnataka, India

Status [2-5]. The majority of PHFs are caused by what is called low energy trauma, for example, a fall from a standing position with an arm stretched out [2-5]. Proximal humerus fractures remain a significant and growing medical concern due to the strongly associated morbidity and epidemiological trends indicating an aging population [3,5].

A wide variety of treatment modalities have been used in the past. These include trans-osseous suture fixation, tension band wiring, standard plate and screw fixation, hemi replacement arthroplasty, percutaneous wire, and screw fixation. But no consensus is available on the ideal treatment modality especially of 3-part and 4-part fractures. Pre-contoured locking plates work on the principle of angular stability, less disruption of vascularity, and less chances of plate failure.

The Proximal humeral internal locking system (PHILOS) plate fixation provides greater angular stability than do conventional implants. It works as a locked internal fixator and provides better anchorage of screws in osteoporotic bone, with good functional outcomes.

In proximal humerus fractures, PHILOS plate offers a good functional outcome with context to the early joint mobilisation and rigid fixation of the fracture. The locking plate can be used with a minimally invasive technique which permits indirect fracture reduction thus lowering the possibility of avascular necrosis (AVN) and also lowering of time of immobilization reduces the possibility of frozen shoulder. Furthermore, the proximal locking screw having the capability of being applied in multi directions makes it a fixating device with a high stability in osteoporotic bones.

Despite the diversity in fixation methods and technical evolution, reports continue to show variety of complications like inadequate reduction, subacromial impingement, adhesive capsulitis, malunion in varus position, migration of screws etc [6-8]. Frankhauser *et al* [6] and Duralde and Leddy [8] reported complication rates of 20-30% with locking plates such as pseudarthrosis, inadequate reduction, subacromial impact, nerve injuries and infection. Miyazaki AN *et al* [9] reported overall complication rate of 35.7% with PHILOS plating.

Considering the advantages of PHILOS plating and the scarcity of data on the complications, efficacy and the functional outcome following internal fixation with PHILOS plate for displaced proximal humerus fractures, the present study was planned to analyse complications and overall outcome at our center.

Methodology

Our study group involves thirty eight patients with displaced proximal humerus fractures treated with PHILOS plate fixation in our unit of the department from January 2013 to December 2015. Patient records, operation notes, pre-operative and post-operative x-rays were studied. Those patients who attended regular follow-up for at least 6 months and had recorded Constant Shoulder Scores were included. Six patients who did not fit into inclusion criteria or did not attend regular follow-up or had incomplete records were excluded from analysis. The inclusion criteria for analysis were: age group >18years, displaced 2-part, 3- part and 4-part fracture of proximal humerus (Neer's classification) [10], acute fractures. Patients having fractures associated with neurovascular injury, compound and pathological fractures, infection around the proximal humerus region were excluded from analysis. A total of 32 patients were included in the analysis. Patient demographics, fracture type, rehabilitation and follow-up details, Constant Shoulder Scores,

complications were analysed. Neer's classification was used to classify fractures.

Detailed physical examination and required investigations were done prior to surgery. All patients were counseled regarding treatment options and decision regarding the operation was taken in consultation with patients. Informed consent was obtained from all patients. Associated injuries, if any, were treated as indicated.

Operative Technique: All patients received a prophylactic dose of antibiotic intravenously preoperatively. A deltopectoral approach was used in beach chair position under brachial block or general anaesthesia. The fracture site was exposed and reduced with minimal soft tissue dissection. Briefly, the anatomical relationship between humeral head and greater tuberosity was reduced and fixed temporarily with K wires. In case of obvious rotation or displacement of the humeral head, a joy stick technique was used. Then the shaft fragment was reduced by abduction, traction and rotation of the arm. The fragments were indirectly reduced with the help of traction sutures, which are placed in the insertions of rotator cuff tendons, and by extremity rotation. When acceptable reduction is obtained, the PHILOS plate was placed at least 1 cm distal to the upper end of the greater tuberosity and fixed to the humeral shaft. An aiming device is then attached to the upper part of the plate, and the head fragments are secured with Kirschner wires, after image intensifier control. The required lengths of the locking head screws is determined with a direct measuring device, and four to six locking screws are then inserted using a specially designed hexagonal screw driver. Proximal locking screws were inserted to hold the humeral head.

After surgery, the shoulder was immobilised in a universal shoulder immobilizer. Appropriate antibiotics as well as analgesics were used. Immediate post-operative check radiographs were taken to determine the alignment of the bone and maintenance of reduction. Post-operative care was given as per standard protocol and early mobilisation was started. Gentle pendulum exercises were started after a week as per comfort of the patient. ROM exercises were gradually increased with an aim to regain full range of movement with terminal stretching exercises in 4-6 weeks. After suture removal by 10th day, patients were followed-up at 6 weeks, 3 months and 6 months for x-rays to assess the fracture union and functional outcome by using Constant Shoulder Scores.

Follow up was done at 6 weeks, 3 months and 6 months (and more as required) to assess the functional and clinical outcome using Constant Shoulder Score. The final assessment was done using Constant shoulder score for outcome

Results

Thirty two patients with displaced proximal humerus fractures were treated with PHILOS plating. Out of 32 patients, 17 had 2-part fracture, 11 patients had 3-part fracture and 4 patients had 4-part fractures. The mean age of the patients was 47 ± 16 years (Range 31-63 years). Majority of the patients (68%) were males (22 males and 10 females). The male to female ratio was found to be 2.2:1. Most of the patients reported road traffic accident as the nature of trauma (50%) and involvement of left side was more common (58%). Maximum (53.1%) patients had 2-part fracture according to Neer's classification. The mean time for radiological union was 13 weeks (10-24 weeks). The range of motion at first, second and third follow ups increased gradually during subsequent follow ups. According to Constant Shoulder scores majority of the patients had excellent outcome (50%) followed by good

(21.9%), fair (12.5%) and poor outcome (15.6%). Analysis of complications revealed that there were 3 cases of inadequate reduction, 2 cases of sub-acromial impingement and 1 case of frozen shoulder. One patient developed varus malunion of the fracture. There were no cases of nerve injury, infection, implant failure or non-union.

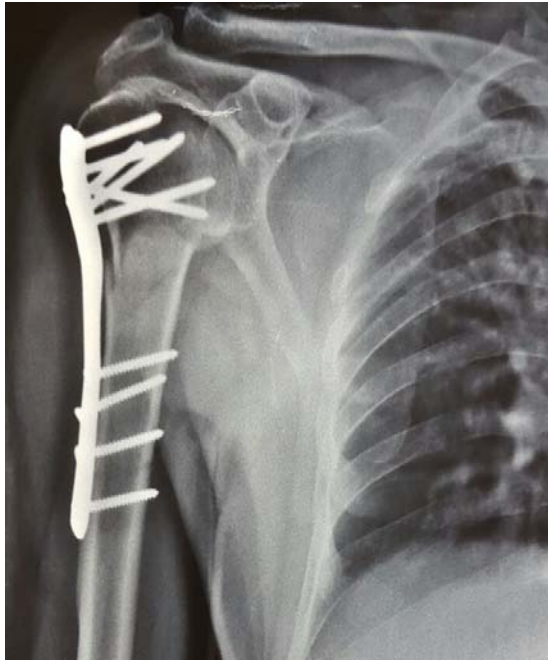


Fig 1: Post-op X-ray: PHILOS plating- Inadequate reduction

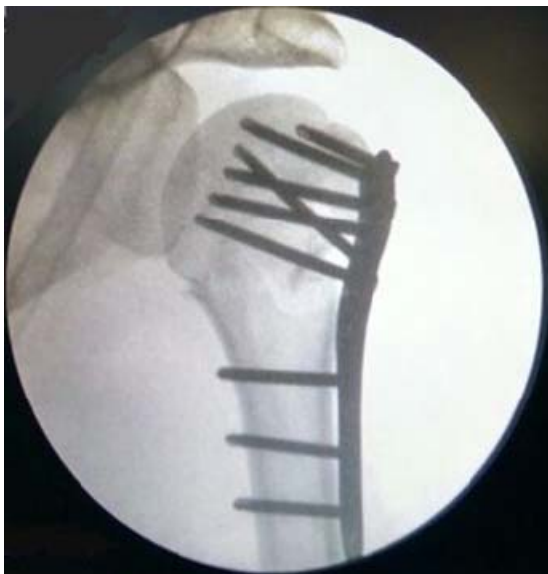

Fig 2: Post-op X-ray: Ideal positioning of the PHILOS plate

Discussion

Surgical management of proximal humeral fractures is challenging. A wide variety of treatment modalities have been described for the fixation of displaced and comminuted fractures. These include transosseous suture fixation, tension band wiring, standard plate and screw fixation, hemireplacement arthroplasty, percutaneous wire, and screw fixation. But no consensus is available on the ideal treatment modality especially of 3-part and 4-part fractures as all these methods have varying rate of complications. Locking plate fixation (PHILOS) have advantages over other methods and

have been reported to be superior to non-locking plates. Preservation of soft tissue attachments of bony fragments is vital to maintain the vascularity and to prevent AVN.

In our study, total of 7 patients out of 32 had complications (21.8%). In literature, the reported complication rates are ranging from 3.7% to 35.7% [9, 11, 12]. The main complication in our study was inadequate reduction of the fracture (Fig. 1). There were 3 cases (9.4%) which were mainly associated with 3 and 4 part fractures. In literature, 13.7% to 25% of cases had this complication [6, 13, 14]. According to Koukakis *et al* [15] and Duralde and Leddy [8], main surgical difficulty is achieving fracture reduction to anatomical position and maintaining the position is a greatest challenge. So we feel that proper pre-op planning with good quality x-rays, CT scan and adequate training to achieve surgical expertise are important.

In our study, the second most frequent complication was subacromial impingement caused by the plate. We had 2 patients (6.2%) who had plate placement slightly higher than recommended position i.e. less than five millimeters from the apex of the greater tubercle [8, 16]. The rate of occurrence of this complication is about 0-12.5% in literature [6, 13, 15, 16]. To avoid this complication, positioning of the plate has to be accurate and lower than 8mm from apex of the greater tubercle [9]. (Fig. 2).

Loss of reduction in varus position is another important complication of the fixation. We had one case (3.2%) which was fixed in varus position and healed with malunion. Miyazaki *et al* [9] reported that 3.3% of their cases developed this complication. Varus malposition is defined as a head shaft angle of less than 120 degrees. According to Agudelo *et al* [13], primary varus reduction is an important risk factor which may lead to poor outcome. Our patient had poor results according to Constant shoulder score. We also had one case of adhesive capsulitis due to inadequate physiotherapy in an elderly patient leading to poor results.

The analysis of functional outcome shown that 16 of our patients had excellent outcome (50%) followed by good in 7 patients (21.9%), fair in 4 patients (12.5%) and poor outcome in 5 patients (15.6%). Overall, 71.9% of patients had excellent to good results and 28.1% of patients had fair to poor results. Geiger EV *et al* [17] reported excellent to good results in 57.1% patients, moderate in 3.6% and 39.3% poor results.

Conclusion

Currently, the PHILOS plate is the best available construct and a stable implant to use for fractures of the proximal humerus in Neer's 2-part, 3-part, and 4-part and osteoporotic fractures of the proximal humerus, particularly in elderly patients hence allowing early mobilization of the shoulder. Proximal humeral internal locking system (PHILOS) plating of the treatment of proximal humerus fractures leads to a satisfactory functional outcome in majority of the patients. However, complications like inadequate reduction, varus malalignment, subacromial impingement and frozen shoulder can still occur with this system also. We have to remember that PHILOS is not a panacea for all the problems associated with proximal humerus fractures. So the surgeons should be aware of all potential complications, plan the surgery meticulously and patients should be counseled about the outcome.

References

1. Grönhagen C, Abbaszadegan H, Révay S, Adolphson P. Medium-term results after primary hemiarthroplasty for

- comminute proximal humerus fractures: A study of 46 patients followed up for an average of 4.4 years. *J Shoulder Elbow Surg.* 2007; 16(6):766-73.
2. Handoll H, Gibson J, Madhok R. Interventions for treating proximal humeral fractures in adults. *Cochrane Database Syst Rev.* 2003(4):CD000434.
 3. Court-Brown C, Caesar B. Epidemiology of adult fractures: A review. *Injury* 2006; 37(8):691-7.
 4. Court-Brown C, Garg A, McQueen M. The epidemiology of proximal humeral fractures. *Acta Orthop Scand.* 2001; 72(4):365-71.
 5. Lanting B, MacDermid J, Drosdoweck D, Faber K. Proximal humeral fractures: a systematic review of treatment modalities. *J Shoulder Elbow Surg.* 2008; 17(1):42-54.
 6. Fankhauser F, Boldin C, Schippinger JP, Haunschmid C, Szyszkowitz R. A new locking plate for unstable fractures of the proximal humerus. *Clin Orthop Relat Res.* 2005; (430):176-81
 7. Brunner F, Sommer C, Bahrs C, Heuwinkel R, Hafner C, Rillmann P *et al.* Open reduction and internal fixation of proximal humerus fractures using a proximal humeral locked plate: a prospective multicenter analysis. *J Orthop Trauma.* 2009; (23):163-72.
 8. Duralde XA, Leddy LR. The results of ORIF of displaced unstable proximal humeral fractures using a locking plate. *J Shoulder Elbow Surg.* 2010; 19(4):480-8
 9. Miyazaki AN, Estelles JS, Fregoneze M, Santos PD. *et al.* Evaluation of the complications of surgical treatment of fractures of the proximal extremity of the humerus using a locking plate. *Rev Bras Orthop.* 2012; 47(5):568-74
 10. Neer CS. Displaced proximal humeral fractures. I: classification and evaluation. *J Bone Joint Surg [Am]* 1970; 52-A:1077-89.
 11. Fazal MA, Haddad FS. Philos plate fixation for displaced proximal humeral fractures. *J Ortho Surg.* 2009; 17(1):15-8
 12. Sudkamp N, Bayer J, Hepp P. Open reduction and internal fixation of proximal humerus fractures with use of the locking proximal humerus plate. Results of a prospective, multicenter, observational study. *J Bone Joint Am.* 2009; 91(6):1320-8
 13. Agudelo J, Schurmann M, Stahel P, Helwig P. Analysis of efficacy and failure in proximal humerus fractures treated with locking plates. *J Orthop Trauma.* 2007; (21):676-81.
 14. Owsley KC, Gorczyca JT. Displacement/ screw cutout after open reduction and locked plate fixation of proximal humerus fractures. *J Bone Joint Surg Am.* 2008; 90(2):233-40
 15. Koukakis A, Apostolou CD, Taneja T, Korres DS, Amini A. Fixation of proximal humerus fractures using the PHILOS plate: early experience. *Clin Orthop Relat Res.* 2006; (442):115-20
 16. Handschin AE, Cardell M, Contaldo C. Functional results of angular- stable plate fixation in proximal humeral fractures. *Injury.* 2008; 39(3):306-13
 17. Geiger EV, Maier M, Kelm A, Wutzler S, Seebach C, Marzi I. Functional outcome and complications following PHILOS plate fixation in proximal humeral fractures. *Acta Orthop Traumatol Ture.* 2010; 44(1):16.