



International Journal of Orthopaedics Sciences

ISSN: 2395-1958
IJOS 2017; 3(3): 895-900
© 2017 IJOS
www.orthopaper.com
Received: 01-05-2017
Accepted: 02-06-2017

Dr. Mukesh S Dwivedi
Department of Orthopaedics
GMERS, Gotri, Vadodara,
Gujarat, India

Dr. Jitendra Rathva
Department of Orthopaedics
GMERS, Gotri, Vadodara,
Gujarat, India

Dr. Vikas Patel
Department of Orthopaedics
GMERS, Gotri, Vadodara,
Gujarat, India

Role of Ilizarov ring fixator in definitive management of tibia shaft fractures: A prospective observational study of 50 cases

Dr. Mukesh S Dwivedi, Dr. Jitendra Rathva and Dr. Vikas Patel

DOI: <https://doi.org/10.22271/ortho.2017.v3.i3m.131>

Abstract

Introduction: Tibia shaft fractures can be treated with various modes, each having its merits and demerits. The aim of our study was to analyze clinical outcome of Ilizarov technique in patients with tibia shaft fracture.

Method: 50 patients with isolated tibia shaft fracture treated with Ilizarov external fixator were followed prospectively for one year. Depending upon the level of fracture 4 or 5 rings were used. Weight bearing as per patient pain tolerance was allowed within 24 to 48 hours. The decision of frame removal was taken based on Ramos criteria. The function was evaluated based on Johner and Wruh's criteria.

Results: According to Johner and Wruh's criteria, 34 patients had excellent, 12 patients had good and 4 patients had fair results. No poor results were noted. There was no case of re-operation and re-fracture. Pin-site infections were seen in 14% cases but there were no deep infections.

Conclusion: Ilizarov technique can be used as an early definitive management in tibia shaft fractures with excellent clinical outcome.

Keywords: Ilizarov method, tibia fracture, external fixation

Introduction

The incidence of closed and open tibial fractures is increasing with increasing trend in social development and metropolisation. Due to distal location and less soft tissue envelope of tibia, open fractures are more common in tibia than in any other long bones [1]. Severely comminuted fractures and open fractures pose problems of delayed union and non union [2]. Extent of soft tissue injury in closed fractures often affects the union time. When conservative treatment is inappropriate several methods of surgical management can be used [3, 4]. Open reduction and internal fixation [ORIF] with plates and screws achieves stability, allows joint mobilization but does not allow early weight bearing which as a stimulus is a must for early union [5]. Minimally invasive percutaneous plate osteosynthesis [MIPPO], shows high rate of healing and low rate of soft-tissue complications [6, 7]. Close intramedullary nailing [IMN] preserves extra osseous blood supply, doesn't disturb fracture haematoma and maintains the integrity of soft tissue envelope, allows early weight bearing [2], but it compromises the intramedullary blood supply and in open fractures increases the risk of infection [8, 9, 10]. IMN has been recommended in management of closed fractures and Gustilo I and II tibial shaft fractures [11, 10, 12, 13, 14, 6]. Few reports have described uniplanar and biplanar external fixator in treatment of close tibial shaft fractures. However they do not allow weight bearing, can cause problems of pin loosening, infection and at times can cause insufficient mechanical stability [15]. This has contributed to the limited use of external fixators as primary treatment and restricted the indications for it to fractures with major soft tissue damage [16]. According to original recommendations, the classical Ilizarov circular fixator can be a valid alternative in primary treatment of tibial fractures [17]. We have evaluated the principle of trans-osseous neo-osteohistogenesis using the circular ring fixator (Ilizarov ring fixator).

Correspondence
Dr. Mukesh S Dwivedi
Department of Orthopaedics
GMERS, Gotri, Vadodara,
Gujarat, India

Method

A prospective study of 50 cases of comminuted tibia fractures treated primarily by Ilizarov external fixator was carried out at GMERS, Gotri medical college vadodara, a tertiary care centre from may-2014 to April 2017. The study protocol was approved by hospital ethics committee and written informed consent was taken from all the patients.

Inclusion Criteria

Medically fit patient between age group 17-65 yrs were included. Gustilo Anderson type I, II and III-A were included. Isolated injury involving leg were included.

Exclusion Criteria

Patient with any other associated bony injury. Patient with open grade III-B and C injury. Age more than 65 yrs. Fracture line extending into intra-articular region, knee or ankle were excluded. Patient who found the fixator to be aesthetically unacceptable.

Injury was classified as upper third, middle third or lower third based on the anatomical level of fracture. Also the fracture was classified according to AO classification [18]. Gustilo-Anderson classification was used to classify open fractures [19]. Soft tissue injury was graded according to Tscherne classification for closed fractures [20].

After proper pre-operative anaesthetic evaluation the surgery was performed under spinal anesthesia in all cases. Calcaneal pin was passed in all cases and traction table was used to achieve proper alignment. Biplanar fluoroscopy was used during reduction and passage of wires and pin. Depending upon the level of fracture four or five full rings of 160mm size or 5/8 ring were used for frame assembly. Proximal tibio-fibular joint was fixed with wire passed from lateral to medial side. Ankle syndesmosis was stabilized by passing wire. Other wires were passed avoiding injury to neuro-vascular structures by remaining in safe zones. All the wires were passed by using intermittent drilling using a low RPM drill to decrease the chances of thermal necrosis to bone. Wires were fixed to ring using wire fixation bolts and tensioned to a minimum of 120kg. Olive wires were used in some cases to achieve final reduction. 4.5 mm Schanz pins were used in few cases to provide additional stability. Final reduction was assessed under fluoroscopy and sterile dressing applied at pin insertion sites. Post operative adequate analgesic cover and prophylactic antibiotics were given. Partial weight bearing, knee and ankle mobilization exercises were started within 24 hrs. Patients were encouraged to do high sitting and full weight bearing as per their pain tolerance capacity. Once patients were comfortable with full unrestricted weight bearing, they were discharged. First follow-up was at two weeks and thereafter every month. At each follow-up wires were checked for loosening or infection, knee and ankle mobilization was assessed. Patients were demonstrated pin tract care at each visit. Radiological evaluation was done at each monthly visit. The patients were assessed clinically and radiologically for alignment, bone contact and later on callus formation in the out patient clinic. The decision of frame removal was taken after clinical and radiological assessment as described by Ramos *et al* [21]. The fracture was regarded as united when 3 out of 4 cortices on antero-posterior and lateral x-rays showed bridging callus, fracture was stable under manual stress and patient was able to walk without pain after the connecting rods had been removed. Johner and Wruh's criteria was used for final evaluation of patients [21].

Results

In this study, during a 3-year period from may-2014 to april-2017, 50 patients with tibia shaft fracture were followed up. 42 were male and 8 were female. Age of the patients ranged from 17 yrs to 65 yrs with average age of 37 years. 27 cases had vehicular accident and 23 cases had fall from varying degrees of height. 29 patients had closed injuries which were classified based on Tscherne classification. Out of them 6 were grade I, 16 were grade II, 7 were grade III. 21 patients had open injuries and were classified based on Gustilo-Anderson's classification as grade I- 4, grade II- 13 and grade III-A - 4. Based on anatomical level of fracture 18 had upper third fracture, 17 had middle third fracture and 15 had lower third fracture. Based on AO classification they were as per table no 1 [18]. Time interval from date of admission to date of operation was 1 to 13 days with average of 4.46 days. Total duration of hospital stay was from 3 days to 11 days with average stay of 5.38 days. Blood loss was negligible as no patient required blood transfusion. Weight bearing was started in all patients within 24 hrs except in case no 18. Total duration of ilizarov frame kept ranged from 74 days (10.5 weeks) to 152 days (21.7 weeks). Average time was 111 days (16 weeks). Earliest frame removal was done in case no.38 and longest time of frame was kept in case no18. Pin tract infection occurred in 7 patients which resolved with proper pin tract care and antibiotics and did not need change of wire. Shortening of upto 2 cms was seen in 4 patients. No significant varus or valgus deformity was noted at knee or ankle. Even in open injuries no case of osteomyelitis was seen. No patient required any additional procedure like bone grafting for achieving union. No patient required any additional protection in form of casting or bracing after frame removal. Based on Johner and Wruh's criteria [22] final results were rated as 34 excellent, 12 good, and 4 fair (table no 2). No poor results were seen.

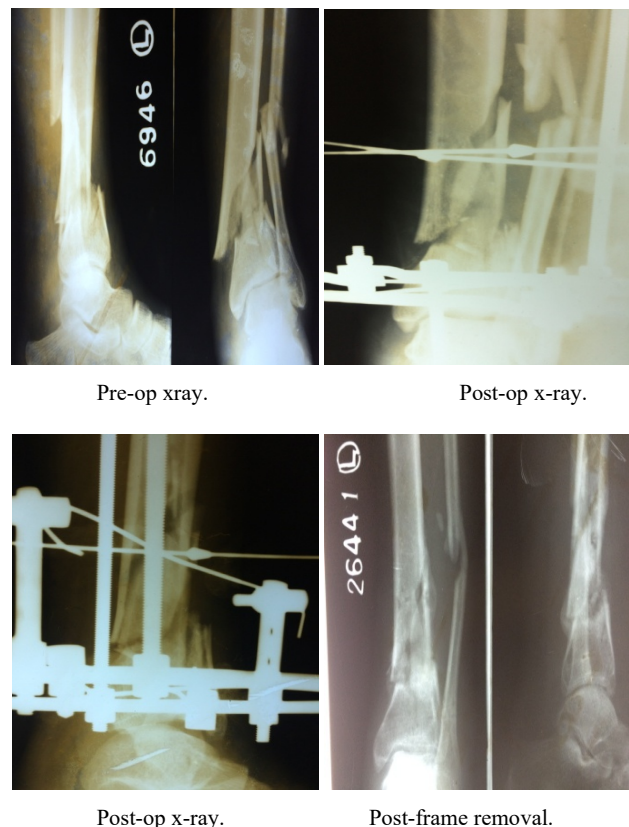


Table 1

41-A2	41-A3	42-A2	42-A3	42-B1	42-B3	42-C2	42-C3	43-A1	43-A3
3	12	1	4	7	3	1	6	1	12

A.O. Classification^[18]

Table 2: Johner and Wruh’s criteria^[22].

Criteria	Excellent	Good	Fair	Poor
Nonunion/infection	None	None	None	Yes
Neurovascular injury	None	Minimal	Moderate	Severe
Deformity				
Varus/valgus°	None	2-5	6-10degrees	>10 degrees
Pro/recurvatum	0-5 degrees	6-10 degrees	11-20degrees	>20 degrees
Rotation	0-5 degrees	6-10 degrees	11-20degrees	>20 degrees
Shortening	0-5mm	6-10mm	11-20mm	>20mm
Mobility				
Knee	Full	>80%	>75%	<75%
Ankle	Full	>75%	>50%	<50%
Subtalar	>75%	>50%	<50%	
Pain	None	Occasional	Moderate	Severe
Gait	Normal	Normal	Mild limp	Significant
Strenuous activity	Possible	Limited	Severely limited	Impossible
RESULT	34	12	4	0

Discussion

Ilizarov method is a highly versatile technique applicable in number of clinical situations^[23] It is a safe and effective treatment modality for tibial fractures^[24]. Hosney and Fadel achieved union in all the 34 open tibial fractures managed by Ilizarov fixator^[25]. Sidharthan *et al.* achieved union in all the 42 high energy tibial fractures managed with Ilizarov fixator and advocated the use of Ilizarov technique in high energy tibial fractures since the device provides early and definitive management of these fractures^[26]. We also achieved union in all 50 cases of comminuted extra-articular fractures managed by Ilizarov external fixator. We had 21 cases of open injuries which united without any case of post-traumatic osteomyelitis. Even in closed fractures with soft tissue injuries, Tscherene II and III, (23 cases), union was achieved as this device leads to no stripping of soft tissues as compared to ORIF or MIPPO and minimal disturbance to vascularity of bone and the fracture as compared to IMN. This is in contrast to intra-medullary nailing which interferes with intra-medullary circulation. The interference with circulation is seen in both unreamed and reamed nailing although the degree of compromise is a matter of controversy^[9].

Soft tissue management holds the key to achieving good functional result in open tibial fractures. Shtarker *et al.* used primary suturing and ilizarov fixation in treatment of open tibia fractures with good results^[27]. Due to non-availability of plastic surgeon in our set-up we could not address III-B injuries and referred them to higher centre.

Pin-site infections form the bulk of complications associated with Ilizarov fixator. Good care of pin sites and aggressive management of superficial infections is essential to prevent deep infection. Pin site infection results in wire loosening and often requiring change of wires^[24]. Insufficient pin care has been associated with higher incidence of pin-tract complications^[24]. Use of half pins results in half the number of sites of soft tissue transfixation which can decrease the number of pin site and soft tissue complications and can potentially improve the comfort of patient and the tolerance to treatment. We had pin-site infection in 7 cases which did not spread deeper and cleared off with early and proper pin site dressing and antibiotics. Paley had suggested this to be a “local problem” rather than an obstacle or a true complication

^[24].

Ilizarov frame allowed early mobilization of patient (partial weight bearing followed by full weight bearing) within limits of pain. Effective 360 degree construct discouraged translational and angular motions while still allowing some dynamic axial movements. Bony contact in combination with compression at fracture site augments the frame’s stability, which results in load sharing between the frame and the bone and the ability to bear weight^[28]. This produced cyclic axial micromotion at the fracture site which is beneficial for fracture healing^[29, 30, 31]. Despite being less stiff in axial compression Ilizarov frame is moderately to highly stiff in AP and Lateral bending strains^[31]. For all wire frames, many biomechanical parameters have been defined that affect stiffness. Half-pins are used with Ilizarov frame to simplify application, induce higher rigidity in the frame and reduce soft tissue complications^[32]. Many studies have indicated that axial compression is coupled with translational and angular motion in half-pin mountings^[32]. We have used half pins in few cases without any complications.

The time to achieve union with Ilizarov fixator varies in different studies since different authors have used different criteria for assessment of union. Inan *et al.* reported bony union in 19 weeks in all type III-A fractures^[33]. The average time of union in our study was 16 weeks. We have followed the criteria laid down by Ramos *et al.*^[21]. There was no case of non-union in our study.

IMN or ORIF is associated with potential risk of non-union, delayed union, malunion and infection needing additional procedures. Since Ilizarov technique is a minimally invasive method with little interference to biology of fracture, it leads to decreased incidence of infection or non-union. By compression and or distraction during the course of treatment, progress of union can be managed without requiring any additional secondary procedure. No patient in our study required any additional procedure to alter the course of bony union.

When using the Ilizarov technique some tethering of muscles and tendons is inevitable and this would theoretically affect the ROM of knee and ankle^[34]. Muscle contracture and joint stiffness are significant problems especially seen in patients when fixator is applied for longer periods or fracture is near

the joint ^[24]. Patient education and early range of motion activities is a must to avoid problems of stiffness. In our study 4 patients had fair results due to knee and ankle stiffness.

Incidence of Refracture in the consolidate is a troublesome complication but seen in rare case ^[35]. These fractures usually arise due to early frame removal. In our study no patient had refracture. Earliest frame removal was done at 10.5 weeks in our study.

Malunion used to be more commonly seen in conservatively treated comminuted fractures of tibia. Ilizarov external fixator allows the surgeon to correct malalignment while the fracture is undergoing union. Dickson *et al.* found malunion in 5.7% patients treated with Ilizarov ^[24]. In long term follow-ups after tibial fractures there is no evidence that the malalignment of the lower limb will lead to any restriction of motion, pain or osteoarthritis of knee and ankle even with an angulation of upto 15 degree ^[36, 37, 38].

Anterior knee pain after IMN remains a troublesome complication regardless of the surgical approach used, ranging from 5 to 86% ^[39]. Removal of nail failed to eliminate the pain, which according to some, persisted in as many as 69% at an average of 1.5 years ^[40, 41]. We had no case of anterior knee pain.

Another major operation is required in patients who were treated with either IMN or ORIF or MIPPO for metal removal ^[42]. All our patients underwent frame removal under mild sedation and analgesia avoiding a second major surgical procedure for frame removal.

Conclusion

Ilizarov apparatus involves non-invasive operation, provides 360 degree stability, respects the vascularity of fracture fragments. It allows early joint mobilization and early weight bearing stimulus which aids compressive effects on the fracture callus. It improves and increases venous and lymphatic return preventing swelling and disuse osteopenia. The risk of infection and subsequent osteomyelitis associated with other forms of fixation is also minimized. This system allows for adjustment of the alignment, and for compression and or distraction both during surgery and at subsequent follow-ups. The complication profile for Ilizarov frame is however less serious in nature than that of IM fixation and ORIF. We conclude that Ilizarov technique is a safe and effective method for treatment of tibia fractures to improve the functional capacity of patient and to promote union.

Recommendation

We highly recommend this technique as primary and definitive treatment for close tibia fractures irrespective of the extent of soft tissue injury and in open grade I, II and III-A fractures.

Conflict Of Interest

The authors have no conflict of interest to declare.

Funding

This study is not supported by any grant from any organization or company.

References

- Nicoll EA. Closed and open management of tibial fractures. Clin Orthop Relat Res [Internet]. 2017; (105):144-53. Available from: <http://www.ncbi.nlm.nih.gov/pubmed/4430162>
- Foot CJ, Guyatt GH, Bhsc KNV, Mundi R, Chaudhry H,

- Heels-andsell D. Which Surgical Treatment for Open Tibial Shaft Fractures Results in the Fewest Reoperations? A Network Meta-analysis. Clin Orthop Relat Res [Internet]. 2015; 2179-92. Available from: <http://dx.doi.org/10.1007/s11999-015-4224-y>
- Newman SDS, Mauffrey CPC, Krikler S. Distal metadiaphyseal tibial fractures. Injury [Internet]. 2011; 42(10):975-84. Available from: <http://www.ncbi.nlm.nih.gov/pubmed/22073415>
- Coles CP, Gross M. Closed tibial shaft fractures: management and treatment complications. A review of the prospective literature. Can J Surg [Internet]. 2000; 43(4):256-62. Available from: <http://www.ncbi.nlm.nih.gov/pubmed/10948685>
- Mukherjee S, Arambam MS, Waikhom S, Santosha, Masatwar PV, Maske RG. Interlocking Nailing Versus Plating in Tibial Shaft Fractures in Adults: A Comparative Study. J Clin Diagn Res [Internet]. 2017; 11(4):RC08-RC13. Available from: <http://www.ncbi.nlm.nih.gov/pubmed/28571220>
- Richard RD, Kubiak E, Horwitz DS. Techniques for the Surgical Treatment of Distal Tibia Fractures. Orthop Clin North Am [Internet]. 2014; 45(3):295-312. Available from: <http://www.ncbi.nlm.nih.gov/pubmed/24975759>
- He G-C, Wang H-S, Wang Q-F, Chen Z-H, Cai X-H. Effect of minimally invasive percutaneous plates versus interlocking intramedullary nailing in tibial shaft treatment for fractures in adults: a meta-analysis. Clinics (Sao Paulo) [Internet]. 2014; 69(4):234-40. Available from: <http://www.ncbi.nlm.nih.gov/pubmed/24714830>
- Larsen LB, Madsen JE, Høiness PR, Øvre S. Should insertion of intramedullary nails for tibial fractures be with or without reaming? A prospective, randomized study with 3.8 years' follow-up. J Orthop Trauma [Internet]. 2004; 18(3):144-9. Available from: <http://www.ncbi.nlm.nih.gov/pubmed/15091267>
- Study to Prospectively Evaluate Reamed Intramedullary Nails in Patients with Tibial Fractures Investigators the S to PERIN in P with TF (SPRINT), Bhandari M, Guyatt G, Tornetta P, Schemitsch EH, Swiontkowski M, *et al.* Randomized trial of reamed and unreamed intramedullary nailing of tibial shaft fractures. J Bone Joint Surg Am [Internet]. 2008; 90(12):2567-78. Available from: <http://www.ncbi.nlm.nih.gov/pubmed/19047701>
- Busse JW, Morton E, Lacchetti C, Guyatt GH, Bhandari M. Current management of tibial shaft fractures: A survey of 450 Canadian orthopedic trauma surgeons. Acta Orthop [Internet]. 2008; 79(5):689-94. Available from: <http://www.ncbi.nlm.nih.gov/pubmed/18839377>
- Bhandari M, Guyatt GH, Tornetta P, Swiontkowski MF, Hanson B, Sprague S, *et al.* Current practice in the intramedullary nailing of tibial shaft fractures: an international survey. J Trauma [Internet]. 2002; 53(4):725-32. Available from: <http://www.ncbi.nlm.nih.gov/pubmed/12394874>
- Hooper GJ, Keddell RG, Penny ID. Conservative management or closed nailing for tibial shaft fractures. A randomised prospective trial. J Bone Joint Surg Br [Internet]. 1991; 73(1):83-5. Available from: <http://www.ncbi.nlm.nih.gov/pubmed/1991783>
- Tibia shaft imliln. Med J Babylon [Internet]. 2017; 7(4). Available from: http://www.medicaljb.com/library/paper/7_3_436.pdf
- JA Toivanen *et al.* Ann Chir Gynaecol. Cast Treatment and Intramedullary Locking Nailing for Simple and Spiral

- Wedge Tibial Shaft Fractures--A Cost Benefit Analysis - Journals - NCBI [Internet]. 2017, Available from: <https://www.ncbi.nlm.nih.gov/labs/articles/10905681/>
15. Podolsky A, Chao EY. Mechanical performance of Ilizarov circular external fixators in comparison with other external fixators. *Clin Orthop Relat Res* [Internet]. 1993; (293):61-70. Available from: <http://www.ncbi.nlm.nih.gov/pubmed/8339510>
 16. Thakur AJ, Patankar J. Open tibial fractures. Treatment by uniplanar external fixation and early bone grafting. *J Bone Joint Surg Br* [Internet]. 1991; 73(3):448-51. Available from: <http://www.ncbi.nlm.nih.gov/pubmed/1670447>
 17. Pal CP, Kumar H, Kumar D, Dinkar KS, Mittal V, Singh NK. Comparative study of the results of compound tibial shaft fractures treated by Ilizarov ring fixators and limb reconstruction system fixators. *Chinese J Traumatol* [Internet]. 2015; 18(6):347-51. Available from: <http://dx.doi.org/10.1016/j.cjtee.2015.08.006>
 18. Marsh JL, Slongo TF, Agel J, Broderick JS, Creevey W, DeCoster TA, *et al.* Fracture and dislocation classification compendium - 2007: Orthopaedic Trauma Association classification, database and outcomes committee. *J Orthop Trauma* [Internet]. 2017; 21(10 Suppl):S1-133. Available from: <http://www.ncbi.nlm.nih.gov/pubmed/18277234>
 19. Kim PH, Leopold SS. Gustilo-Anderson Classification. 2017. Available from: https://www.ncbi.nlm.nih.gov/pmc/articles/PMC3462875/pdf/11999_2012_Article_2376.pdf
 20. Oestern H-J, Tscherne H. Pathophysiology and Classification of Soft Tissue Injuries Associated with Fractures. In: *Fractures with Soft Tissue Injuries* [Internet]. Berlin, Heidelberg: Springer Berlin Heidelberg; 1984; p.1-9. Available from: http://www.springerlink.com/index/10.1007/978-3-642-69499-8_1
 21. Ramos T, Ekholm C, Eriksson BI, Karlsson J, Nistor L. The Ilizarov external fixator--a useful alternative for the treatment of proximal tibial fractures. A prospective observational study of 30 consecutive patients. *BMC Musculoskelet Disord* [Internet]. 2013; 14(1):11. Available from: <http://bmc-musculoskeletal-disord.biomedcentral.com/articles/10.1186/1471-2474-14-11>
 22. Johner R, Wruhs O. Classification of tibial shaft fractures and correlation with results after rigid internal fixation. *Clin Orthop Relat Res* [Internet]. 1983; (178):7-25. Available from: <http://www.ncbi.nlm.nih.gov/pubmed/6883870>
 23. Spiegelberg B, Parratt T, Dheerendra SK, Khan WS, Jennings R, Marsh DR. Ilizarov principles of deformity correction. *Ann R Coll Surg Engl* [Internet]. 2010; 92(2):101-5. Available from: <http://www.ncbi.nlm.nih.gov/pubmed/20353638>
 24. Jonathan A, May D, Paavana T, Royston S. Closed Tibial shaft fractures treated with the Ilizarov method: A ten year case series. *Injury* [Internet]. 2017; Available from: <http://dx.doi.org/10.1016/j.injury.2017.05.019>
 25. Hosny G, Fadel M. Ilizarov external fixator for open fractures of the tibial shaft. *Int Orthop* [Internet]. 2003; 27(5):303-6. Available from: <http://www.ncbi.nlm.nih.gov/pubmed/12811525>
 26. S Sidharthan, A Sujith, A Rathod RP. Management of High Energy Tibial Fractures Using Ilizarov Apparatus. *INTERNET Sci Publ* [Internet]. 2005; 3(1). Available from: <http://ispub.com/IJOS/3/1/6326#>
 27. Shtarker H, David R, Stoloro J, Grimberg B, Soudry M. Treatment of open tibial fractures with primary suture and Ilizarov fixation. *Clin Orthop Relat Res* [Internet]. 1997; (335):268-74. Available from: <http://www.ncbi.nlm.nih.gov/pubmed/9020228>
 28. Ramos T, Ekholm C, Eriksson BI, Karlsson J, Nistor L. The Ilizarov external fixator - a useful alternative for the treatment of proximal tibial fractures A prospective observational study of 30 consecutive patients, 2013;
 29. Leung K-S, Cheung W-H, Yeung H-Y, Lee K-M, Fung K-P. Effect of weightbearing on bone formation during distraction osteogenesis. *Clin Orthop Relat Res* [Internet]. 2004; (419):251-7. Available from: <http://www.ncbi.nlm.nih.gov/pubmed/15021163>
 30. Mullins MM, Davidson AW, Goodier D, Barry M. The biomechanics of wire fixation in the Ilizarov system. *Injury* [Internet]. 2003; 34(2):155-7. Available from: <http://www.ncbi.nlm.nih.gov/pubmed/12565025>
 31. Fleming B, Paley D, Kristiansen T, Pope M. A biomechanical analysis of the Ilizarov external fixator. *Clin Orthop Relat Res* [Internet]. 1989; (241):95-105. Available from: <http://www.ncbi.nlm.nih.gov/pubmed/2924484>
 32. Gessmann J, Citak M, Jettkant B, Schildhauer TA, Seybold D. The influence of a weight-bearing platform on the mechanical behavior of two Ilizarov ring fixators: tensioned wires vs. half-pins. *J Orthop Surg Res* [Internet]. 2011; 6(1):61. Available from: <http://www.josr-online.com/content/6/1/61>
 33. Dickson DR, Moulder E, Hadland Y, Giannoudis PV, Sharma HK. Grade 3 open tibial shaft fractures treated with a circular frame, functional outcome and systematic review of literature. *Injury* [Internet]. 2015; Available from: <http://dx.doi.org/10.1016/j.injury.2015.01.025>
 34. Sahtarker H, Gillson SC, Stoloro J, Kaushansky A, Volpin G. Ilizarov External Fixator As An Alternative Treatment For Tibial Shaft Fractures In Adolescents. *Orthop Proc* [Internet]. 2002; 84-B(SUPP III). Available from: http://bjjprocs.boneandjoint.org.uk/content/84-B/SUPP_III/305.5
 35. Inan M, Halici M, Ayan I, Tuncel M, Karaoglu S. Treatment of type IIIA open fractures of tibial shaft with Ilizarov external fixator versus unreamed tibial nailing. 2007; 617-23.
 36. Kettelkamp DB, Hillberry BM, Murrish DE, Heck DA. Degenerative arthritis of the knee secondary to fracture malunion. *Clin Orthop Relat Res* [Internet]. 1988; (234):159-69. Available from: <http://www.ncbi.nlm.nih.gov/pubmed/3409571>
 37. Kristensen KD, Kiaer T, Blicher J. No arthrosis of the ankle 20 years after malaligned tibial-shaft fracture. *Acta Orthop Scand* [Internet]. 1989; 60(2):208-9. Available from: <http://www.ncbi.nlm.nih.gov/pubmed/2728885>
 38. Milner SA, Davis TRC, Muir KR, Greenwood DC, Doherty M. Long-term outcome after tibial shaft fracture: is malunion important? *J Bone Joint Surg Am* [Internet]. 2002; 84-A(6):971-80. Available from: <http://www.ncbi.nlm.nih.gov/pubmed/12063331>
 39. Ramos T, Eriksson BI, Karlsson J, Nistor L. Ilizarov external fixation or locked intramedullary nailing in diaphyseal tibial fractures: a randomized, prospective study of 58 consecutive patients. 2014; 793-802.
 40. Zhang S, Wu X, Liu L, Wang C. Removal of interlocking intramedullary nail for relieve of knee pain after tibial fracture repair. *J Orthop Surg* [Internet]. 2017; 25(1):230949901668474. Available from: <http://www.ncbi.nlm.nih.gov/pubmed/28193138>
 41. Katsoulis E, Court-Brown C, Giannoudis PV. Incidence

and aetiology of anterior knee pain after intramedullary nailing of the femur and tibia. *J Bone Joint Surg Br* [Internet]. 2006; 88(5):576-80. Available from: <http://www.bjj.boneandjoint.org.uk/cgi/doi/10.1302/0301-620X.88B5.16875>

42. Bedi A, Le TT, Karunakar MA. Surgical treatment of nonarticular distal tibia fractures. *J Am Acad Orthop Surg* [Internet]. 2006; 14(7):406-16. Available from: <http://www.ncbi.nlm.nih.gov/pubmed/16822888>