



# International Journal of Orthopaedics Sciences

ISSN: 2395-1958  
IJOS 2017; 3(3): 841-844  
© 2017 IJOS  
www.orthopaper.com  
Received: 24-05-2017  
Accepted: 25-06-2017

**Nadir Shah**  
Assistant Professor,  
Department of Orthopaedics,  
Grant Government Medical  
College Mumbai, India

**Ayush Kumar Singh**  
Assistant Professor,  
Department of Orthopaedics,  
Grant Government Medical  
College Mumbai, India

**Arohi Sharma**  
Senior Registrar,  
Department of Orthopaedics,  
Grant Government Medical  
College Mumbai, India

**Eknath Pawar**  
Professor & HOD,  
Department of Orthopaedics,  
Grant Government Medical  
College Mumbai, India

**Safiuddin T Nadwi**  
Consultant Orthopaedic Surgeon,  
Wockhardt Hospital, Mumbai

**Ujwal Ramteke**  
Senior Registrar, Department of  
Orthopaedics, Grant  
Government Medical College  
Mumbai, India

**Amit Yadav**  
Senior Registrar,  
Department of Orthopaedics,  
Grant Government Medical  
College Mumbai, India

**Correspondence**  
**Ayush Kumar Singh**  
Assistant Professor,  
Department of Orthopaedics,  
Grant Government Medical  
College Mumbai, India

## A comparative study of fixation of pertrochanteric fractures with dynamic hip screw and proximal femoral nail

**Nadir Shah, Ayush Kumar Singh, Arohi Sharma, Eknath Pawar, Safiuddin T Nadwi, Ujwal Ramteke and Amit Yadav**

DOI: <https://doi.org/10.22271/ortho.2017.v3.i3l.124>

### Abstract

Trochanteric femoral fractures are among the most common injuries necessitating hospital admission. Regardless the type of fracture, trochanteric fractures can lead to substantial morbidity and mortality, especially in elderly patients [1, 2]. Surgery is the mainstay of the treatment for both displaced and non displaced trochanteric fractures, to allow early mobilization of the patient, depending on the stability of the reduction and fixation achieved [4]. Dynamic Hip Screw [DHS] as extramedullary and Proximal Femoral Nail [PFN] as intramedullary systems are established and standard in treatment of trochanteric femoral fractures [5, 6].

**Aim:** To compare the results of Dynamic Hip Screw and Proximal Femoral Nail in the treatment of intertrochanteric fractures.

**Materials & Methods:** In our study we compared DHS with PFN in a group of 60 patients admitted in a tertiary care hospital between August 2013 – December 2016. Patients with intertrochanteric fractures without having concomitant shaft femur or neck femur fractures were included. The preoperative morbidity was evaluated using Parker's mobility scale. Salvati and Wilson's scoring helped in measuring overall functional outcome at 16 & 24 weeks between the two study groups.

**Results:** The preoperative Parker's mobility scale was comparable between two study groups. Salvati and Wilson's score at 16 & 24 weeks was significantly better with PFN group.

The functional outcome based on SWS score was Fair in 39% of patients operated with DHS at 16 weeks while for PFN it was Fair to Good in 79% of patients. At 24 weeks it was Fair to Good in 84% patients operated with DHS while in case of PFN the score was Fair to Good in 59% of the patients & Excellent in 38% of the patients.

**Conclusion:** Our conclusion from this study supported the use of PFN for both stable and unstable pertrochanteric fractures over DHS due to its lesser operation time, lesser blood loss, early weight bearing, limited open reduction & better functional outcome.

**Keywords:** Fixation, pertrochanteric fractures, dynamic hip screw, proximal femoral nail

### Introduction

The incidence of pertrochanteric femoral fractures has increased significantly during recent decades and this tendency will probably continue in the near future due to rising age of the population [7, 8]. The goal of our study is to determine whether intramedullary implant can outweigh extramedullary DHS implant in unstable and stable intertrochanteric fractures. Other investigators have attempted to answer this question and there are number of prospective randomized clinical studies comparing a sliding hip screw, most often DHS with intramedullary nails. The advantages and disadvantages of the original design of the gamma nail have been well established in previous studies usually by comparing the results with the Dynamic Hip screw [9]. Less data is available about an alternative, the PFN. Most previous studies are retrospective and lack a control group [10].

### Materials & Methods

This is a comparative study of inter trochanteric femoral fractures treated by Dynamic Hip Screw (DHS) and Proximal Femoral Nail (PFN) in adults and elderly patients of both genders

at Grant Medical College, Mumbai between August 2013 – December 2016. During this period 42 male and 18 females were included in our study with an average age of 64.83 years. Patients were divided into two groups. Control group was treated with DHS (n=31) and study group (n=29) was treated with PFN. Patients with any other concomitant ipsilateral limb fracture were excluded. Pre trauma ambulatory status for all patients was recorded by a scoring method suggested by Parker *et al.* (Annexure1). Detailed history regarding mode, time, extent of injury was recorded. All the information regarding preoperative, Intraoperative & post operative condition and the follow up of the patient (Min 24 weeks at 4 weeks interval) were recorded. Clinical assessment was done according to Wilson –Salvati Score during follow –ups. After obtaining the data it was analysed statistically using independent and proportional T-tests. In all cases p value more than 0.05 was considered not significant and less than 0.05 was considered significant.

**Observation & Results**

There were 42 males and 18 females with mean age 66 and 63 years in the DHS and PFN group respectively. The mean PMS was 8.16 for DHS and 8.28 for PFN respectively. There were 10 cases of 3.1 AO type 1, 31 cases of 3.1AO type 2, 19 cases of 3.1AO type 3. The p value is insignificant for all pre fracture variables in either group.

**Table 1:** Pre –operative Data

	DHS (n=31)	PFN(n=29)	Test of Significance
Mean Age (in yrs)	66	63	t=0.994, p=0.325
Gender (M:F)	18:13	24:5	z=2.09, p=0.037
Associated Trauma	Nil	Nil	-
Mean PMS	8.16	8.28	t=0.509, p=0.613

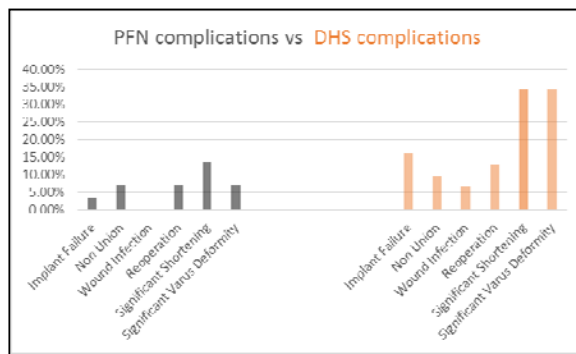
**Table 2:** Intraoperative Data

	DHS (n=31)	PFN(n=29)	Test of Significance
Mean Operative time (in min)	118	86	p=0.000
Mean Blood loss (in ml)	224	129	p=0.000
Open Reduction required	9/31	6/29	p=0.450
X-ray Exposure (f sec)	178	254	p=0.000

**Table 3:** Postoperative Data

	DHS (n=31)	PFN(n=29)	Test of Significance
Hospital Stay (in days)	18	18	p=0.992
Wound Infection	2	0	p=0.160
Death of Patient	-	-	-

**Significant post operative complications in our study (Bar Chart 4)**



**Table 5:** Follow up Evaluation by Salvati Wilson Score

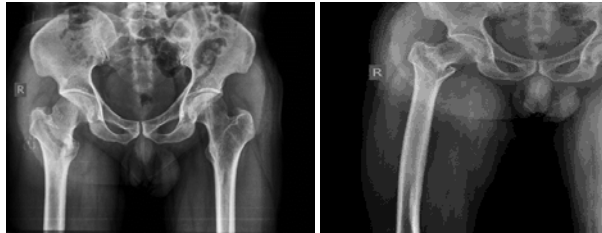Salvati & Wilson Score	DHS(n=31)		PFN(n=29)	
	SWS 16	SWS 24	SWS 16	SWS 24
<16	19	5	6	1
16-23	12	13	21	6
24-31	-	13	2	11
>31	-	-	-	11

**Discussion**

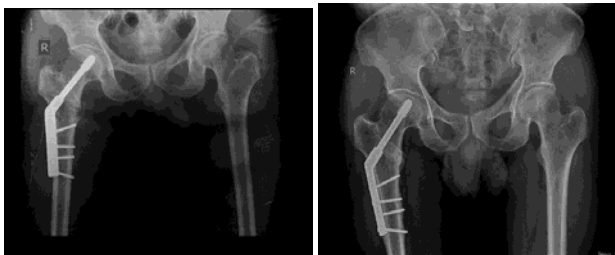The goal of our study is to review the role of intramedullary implants in comparison to sliding hip screw in management of trochanteric fractures. There are number of prospective randomized clinical studies comparing a sliding hip screw, most often the DHS, with intramedullary nails. These nails may challenge the previous role of compression screw as the standard method of fixation. The gender and the mean age of patient of either group in the present study was comparable, in that the p value is insignificant (Table 1). Parker’s mobility scale has been employed in the previous studies to evaluate social mobility before trauma as a marker of morbidity. In our study also based on this scale pre trauma mobility was comparable in both the groups and p value was insignificant (Table 1). Considering the fact that additional surgical exposure can theoretically prolong the operative time and thus the blood loss in DHS than PFN [10, 11, 12]. It can also be noted that the blood loss and operative time was more in DHS group and the p value for which was significant. (Table 2). Regarding hospital stay both are comparable as per our study. In our study there was one case of fixation failure in PFN during intraoperative period due to poor technical performance causing implant breakage which was reoperated and there were two cases of implant cut-out with failure in the DHS group. However no statistical difference was found regarding operative and late complications in both groups (CHART4) which is in agreement with other studies [11]. The overall functional outcome measured with Salvati & Wilson score<sup>70</sup> at 16 & 24weeks was better with PFN group and this was statistically significant. (Table 5). The functional outcome based on SWS score was Fair in 39% of patients operated with DHS at 16 weeks while for PFN it was Fair to Good in 79% of patients. At 24 weeks it was Fair to Good in 84% patients operated with DHS while in case of PFN the score was Fair to Good in 59% of the patients & Excellent in 38% of the patients.

In addition, the frequency and amount of persistent pain were comparable in both the groups but with a different anatomical location. The DHS patient had pain localized to lateral thigh/groin whereas those from PFN group complained mostly of mid to distal thigh pain. The results of our study showed that PFN is a better method of fracture fixation in unstable fractures specifically in 3.1 AO type fracture with regard to operation time, blood loss and SWS score which is in agreement with various prospective studies [11, 12]. As stated above the intramedullary devices are appealing because they appear to combine advantages of intramedullary fixation with those of sliding hip screw and can be inserted in limited open fashion.

Follow up X rays

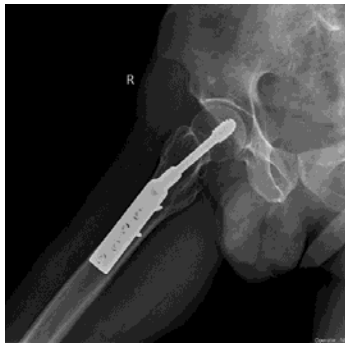

Preoperative case 1(DHS)

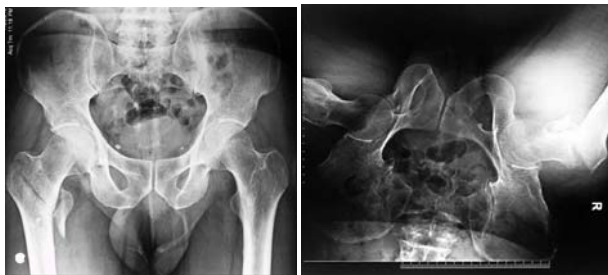

Postoperative

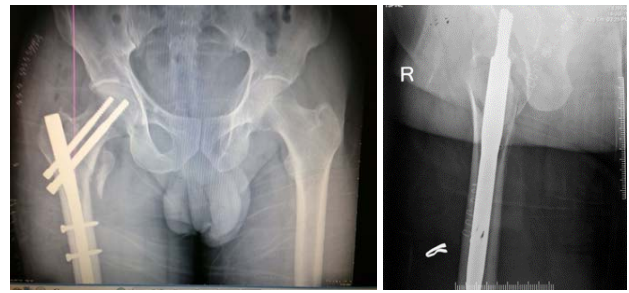
Postoperative 1 year



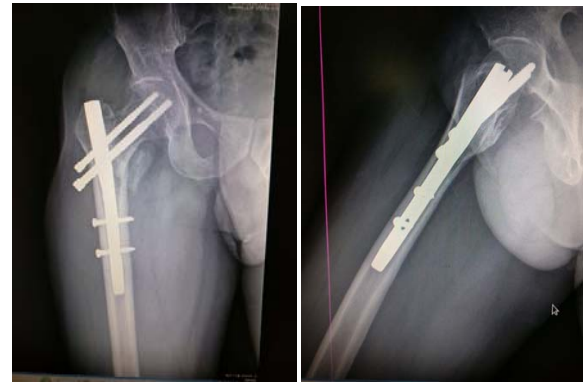Postoperative 1 year



Preoperative case2 (PFN)



Postoperative case 2



Postoperative 1year

### Conclusion

Our conclusion from this study supported the use of PFN for stable pertrochanteric 3.1 AO type 1 and unstable pertrochanteric fractures 3.1 AO type 2 & high subtrochanteric fractures 3.1 AO type 3 due to its lesser operative time, lesser blood loss, early weight bearing, limited surgical exposure and better functional outcome. The only disadvantage of PFN being that it has a steeper learning curve [12]. In current scenario DHS should be limited to stable pertrochanteric fractures as it a technically less demanding surgery.

### References

1. Zuckerman JD. Hip Fracture. N Engl J Med, 1996; 334:1519-25.
2. Koval KJ, Zuckerman JD. Hip Fracture: Evaluation and treatment of intertrochanteric fractures. J Am Acad Orthop Surg, 1994; 2:150-6.
3. Friedl W, Ruf W. Experimental studies of the effectiveness of the sliding principle in dynamic hip screw osteosynthesis and its value in managing unstable pertrochanteric femoral fractures. Chirur, 1987; 58(2):106-12.
4. Dosa G, Tausch F, Wahler G, Vecsei V. Management of Hip fractures using a dynamic hip screw. Magy Traumatol Orthop Helyreallito Seb 1989; 32(1):24-34.
5. Simmermacher RK, Bosch AM, Van der Werken C. The AO/ASIF –Proximal Femoral nail: a new device for the treatment of unstable proximal femoral fractures. Injury 1999; 30(5):327-32.
6. Taeger G, Schmid C, Zettl R, Schweiberer L, Nast-Kold D. Stable and unstable pertrochanteric femoral fractures Differentiated indications for the dynamic hip screw. Unfallchirurg 2000; 103(9):741-8.
7. Nuber S, Schonweiss T, Ruter A. Stabilisation of unstable trochanteric femoral fractures. Dynamic Hip screw with Trochanteric stabilisation plate vs Proximal Femoral Nail. Unfallchirurg, 2003; 106(1):39-47.

8. Pajarinen J, Lindahl J, Michelsson O, Savolainen V, Hirvensalo E. Pertrochanteric femoral fractures treated with a dynamic hip screw or a proximal femoral nail. A randomized study comparing post-operative rehabilitation. *J Bone Jt Surg Br*, 2005; 87(1):76-81.
9. Simmermacher RK, Bosch AM, Van der Werken C. The AO /ASIF –proximal femoral nail: a new device for the treatment of unstable proximal femoral fractures. *Injury* 1999; 30(5):327-32
10. Klinger HM, Baums MH, Eckert M, Neugebauer R. A comparative study of unstable per and intertrochanteric femoral fractures treated with Dynamic hip screw and Trochanteric buttress plate vs Proximal femoral nail. *Zentralbl Chir*, 2005; 130(4):301-6
11. Ahrengart L, Tbrnqvist H, Fornander P. A randomized study of the compression hip screw and Gamma Nail in 426 fractures. *Clin Orthop*, 2002; 401:209-22.
12. Domingo LJ, Cecilia D, Herrera A and Resines C. Trochanteric fractures treated with a proximal femoral nail. *Int Orthop*, 2001; 25(5):298-301.