



# International Journal of Orthopaedics Sciences

ISSN: 2395-1958  
IJOS 2017; 3(3): 696-700  
© 2017 IJOS  
www.orthopaper.com  
Received: 18-05-2017  
Accepted: 20-06-2017

**Dr. Deepak Shivanna**  
Professor, Dept. of Orthopaedics,  
BMCRI, Bengaluru, Karnataka,  
India

**Dr. Navneeth Kumar GK**  
Junior Resident, Dept. of  
Orthopaedics, BMCRI,  
Bengaluru, Karnataka, India

## A prospective study of functional outcome of primary intra-medullary nailing in type 3A and 3B open tibial diaphyseal fractures

**Dr. Deepak Shivanna and Dr. Navneeth Kumar GK**

DOI: <http://dx.doi.org/10.22271/ortho.2017.v3.i3j.107>

### Abstract

**Objectives:** In a developing country such as ours, patients with Type III open Tibial fractures often reach the hospital late (after initial 6 hours) of sustaining high-velocity trauma. Primary internal fixation becomes a formidable challenge in such patients. Due to the paucity of articles exclusively dealing with this topic, we did a study to determine the functional outcome of primary intramedullary nailing in these patients.

**Materials and Methods:** A prospective study was conducted with patients above 18yrs of age with Type 3A and 3B open Tibial Diaphyseal fractures presenting late after injury, initially treated with thorough wound debridement and lavage, followed by internal fixation with intra-medullary nailing. Patients were followed up at fixed intervals for a period of 1year.

**Results:** 25 patients were enrolled in the study, 23 males and 2 females, time elapsed from injury to surgery ranged from 7hrs to as long as 5 days, average -2.66 days. 23 patients had a RUST score of 12 at 1yr follow-up. Functional outcome with Ketenjian and Shelton Criteria was excellent- good in 21 patients. 2 cases (8%) developed non-union, 3 cases (12%) developed post-op infection (Osteomyelitis).

**Conclusion:** Thorough wound debridement and lavage, followed by primary intra-medullary nailing of Type 3A & 3B open Tibial diaphyseal fractures, have shown good results despite delay in presentation and surgery, in comparison to external fixation and secondary nailing.

**Keywords:** Type 3a & 3B open, Tibial Diaphyseal Fractures, intra-medullary nailing, RUST score, Ketenjian and Shelton Criteria, Non-union, Osteomyelitis.

### Introduction

The management of compound Tibial fractures continues to remain a major therapeutic problem in the modern world. Contamination of wound, major bone or skin loss often associated with these fractures make it a challenging task for its management.

External fixation is often the most commonly sort out option for temporary fracture fixation in these cases followed by definitive fixation at a later stage. External Fixators do solve the problem to a great extent, but it often leads to malunion, delayed union, loss of reduction and pin track infection<sup>[1]</sup>.

However, a thorough debridement and lavage of the wounds as soon as the patients present to the casualty and primary intramedullary nailing (i.e in Diaphyseal Fractures) done on emergency basis, has shown good to excellent results in these patients, in terms of Fracture Union and Soft tissue healing (absence of osteomyelitis)

It reduces hospital stay, and lowers morbidity. Furthermore it negates the need for a second surgery and its complications.

There are only a few articles that specifically deal with Primary Internal Fixation in Type 3A and 3B open Tibial diaphyseal fracture, presenting late to the hospital<sup>[2, 3]</sup>.

The primary concern in Type III open fractures is the impaired vascularity in the zone of injury, which compromises the body's immune defense mechanisms at the site of fracture. During the first two hours, the host defense works to decrease the overall bacterial load at the zone of injury. During the next four hours the number of bacteria remains fairly constant, as the bacteria that are multiplying and those that are being killed by the host defense are just about equal. These first six hours are thus called the golden period, because after this period,

### Correspondence

**Dr. Navneeth Kumar GK**  
Junior Resident, Dept. of  
Orthopaedics, BMCRI,  
Bengaluru, Karnataka, India

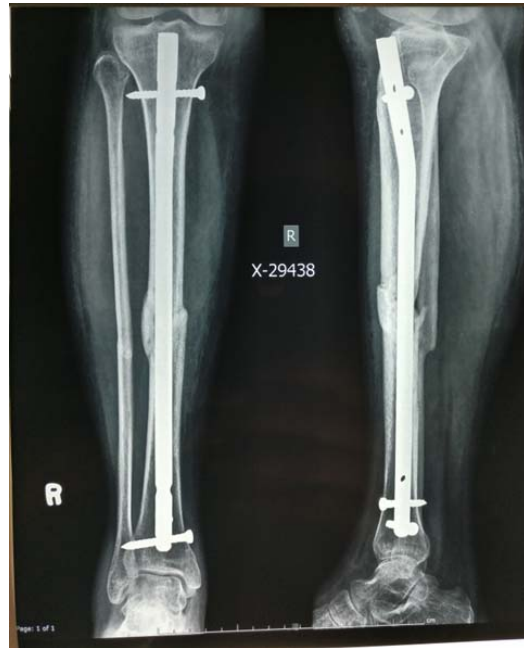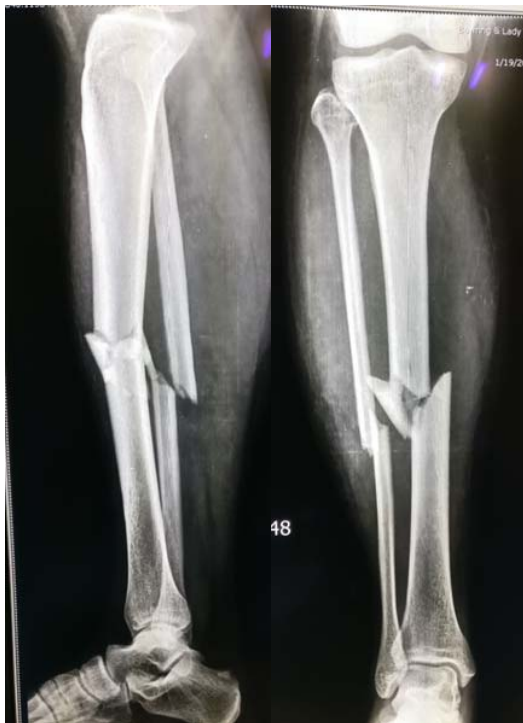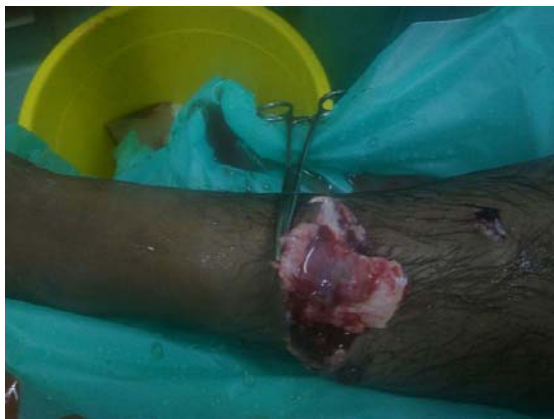invading organisms, in the presence of abundant necrotic tissues, replicate in logarithmic fashion to establish a clinical infection.

Internal fixation is advocated within 6-8h in majority of their cases, which is considered the golden period for any surgical intervention. Unfortunately, in developing countries due to lack of healthcare facilities, ignorance and poverty, patients often reach the hospital late after the few initial precious hours have passed<sup>[1]</sup>.

In this prospective study of 25 patients, we present our results of internal fixation in Type IIIA and IIIB compound fractures, which were fixed after 6 hours but within 24 hours of injury. (Only one case was operated, 5 days after injury)

**Materials and Methods**

In this prospective study between July 2015 to October 2016, 25 patients having Gustilo’s Type III Open fractures were included, of which 23 were males, and 2 were females. M:F ratio is 11.5 : 1. Only compound Type IIIA and IIIB Tibial Diaphyseal fractures operated after 6h but within 24h were included in this series (only one case was operated, 5 days after injury)



[Wound Photo and Radiograph (anteroposterior and lateral) of a 26-year-old male who sustained Type IIIIB open bending wedge fracture both bone leg. Intramedullary nailing was done 11 hours after injury. Radiograph of the same patient after seven months, showing union in progress]

In the emergency room, gentle wound toilet with copious amount (4-6 liters) of sterile saline was done and the wound was covered with sterile dressing. All patients received third generation Cephalosporin (Inj.Ceftriaxone-1g stat, then 1g BID) and Inj. Amikacin (500mg, IV stat, and BID later) for three days. Oral antibiotic was then continued for 5 days after stoppage of Injectables.

The injuries were caused by road traffic accidents in 20 patients (80%), workplace injury in 2 (8%), fall from height in 3 (12%).The different diaphyseal fracture patterns noted in our series were transverse fractures (n=14), oblique and spiral fractures (n=2), bending wedge fractures (n=7), segmental fractures (n=2).

All patients were taken up for surgical debridement and fixation, on emergency basis, on the same day of presenting to the hospital. Only one among the 25 patients had a delay in surgery (5 days) due to other co-morbidities like anemia and alcohol withdrawal. Further radical debridement involving exploration of the wound, excision of devitalized tissues and removal of foreign materials, was performed in emergency OT prior to nailing.

Unreamed Intramedullary Nailing<sup>[2]</sup> was done for all the fractures with Interlocking Tibial Nail of sizes 9 or 10. Primary Closure of wound after debridement was possible in 21 cases. Remaining 4 cases required a secondary plastic surgical intervention in the form of SSG (3 cases) and Flap Cover (1 Case) at a later date.

Of the 25 cases, three had approx. 1cm cortical bone gap at the fracture site, post-fixation and required dynamization, 6-8 weeks after the initial surgery.

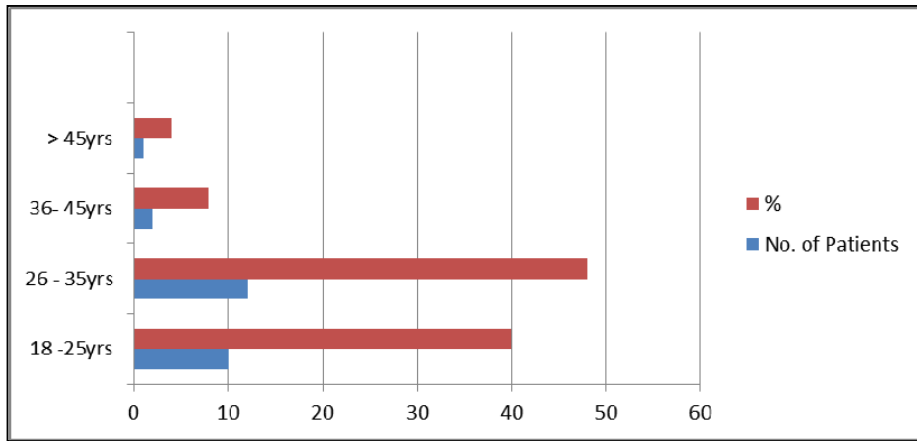
Active and passive physiotherapy of the knee and ankle joints was encouraged as soon as possible. However, mobilization of patients varied depending on the type of fixation, the requirement of plastic surgery and the presence of other injuries. An average follow up of 12 months (range- 8- 15 months) was available at the time of the final evaluation of the result.

**Statistics**

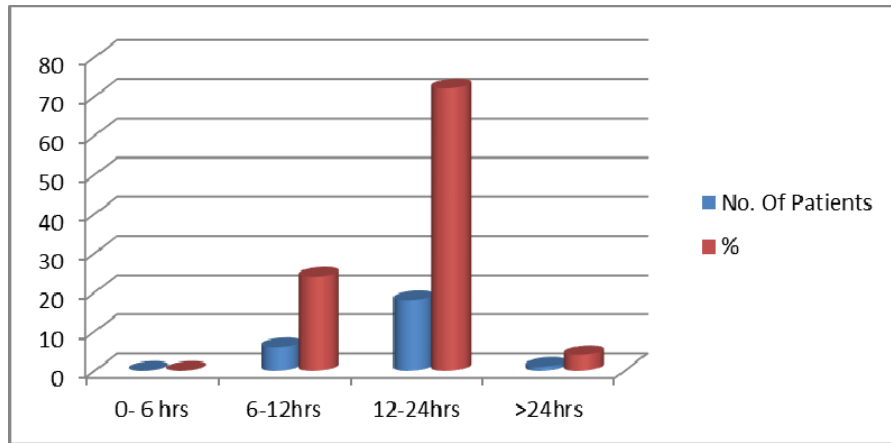
Majority of the patients were ages between 26-35yrs of age (n=12) and 18-25yrs of age (n=10). No of patients above 35yr

were comparatively less. The injury to surgery time ranged from 7hrs (earliest) to as long as 5 days, average being 2.66 days.

**Age wise Distribution**



**Injury- surgery Time**



**Results**

The results of our study was evaluated in terms of Radiological Union using RUST scores [4], Presence or Absence of Infection and overall functional outcome using the Ketenjian and Shelton Criteria [5, 6] modified by Yokoyama *et al.* at minimum of one year follow up.

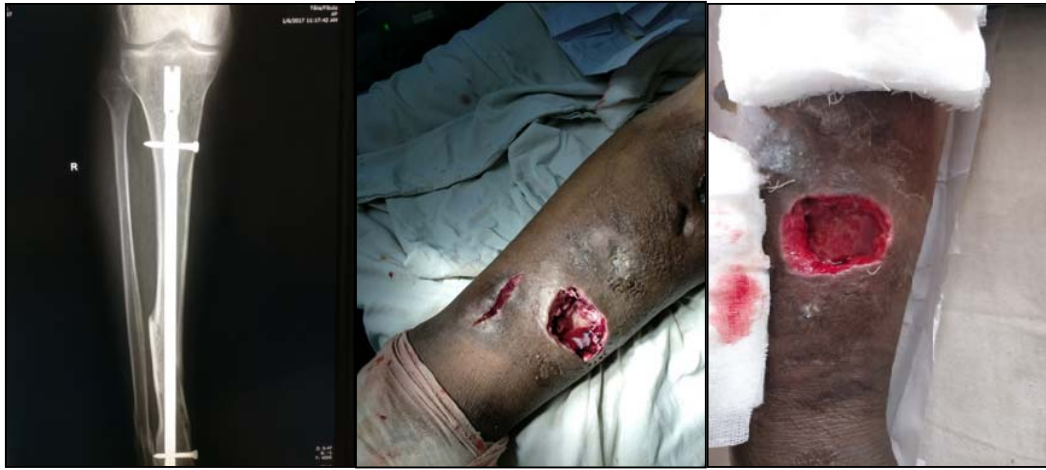**Table 1.** Overview of radiographic union scale in tibial fracture (RUST).

Score per cortex	Callus	Fracture Line
1	Absent	Visible
2	Present	Visible
3	Present	Invisible

[Images- Left- Ketenjian and Shelton Criteria modified by Yokoyama *et al.*, Right- RUST scoring]

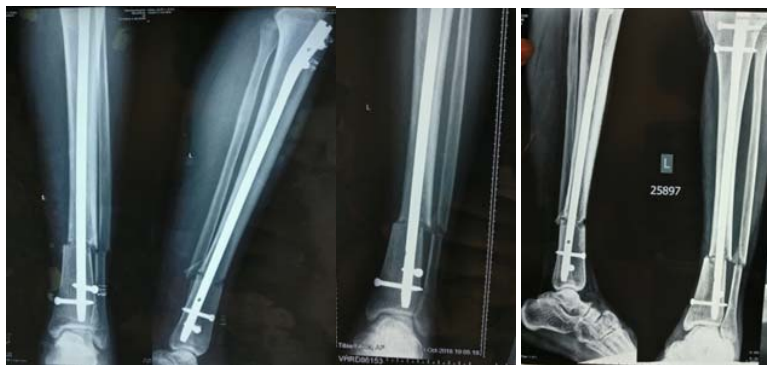<b>Excellent</b>
• No notable abnormality
<b>Good</b>
• Occasional pain with prolonged use
• Joint motion 75% of normal
• Trivial swelling
• Normal gait
<b>Fair</b>
• Pain with ordinary activity
• Joint motion 50% of normal
• Small amount of swelling
• Slight limp
<b>Poor</b>
• Constant pain
• Joint motion <50% of normal
• Any visible deformity
• Limp, gait on cane or crutches

21 cases in our study had Excellent to Good results on the Ketenjian and Shelton Criteria of Scoring, with no signs of infection and RUST score of 11-12 at 12 month follow-up. Two cases developed deep seated infection with discharging sinus. Deep infection was defined as purulent discharge from the tissue contiguous with the fracture site. But these cases had good radiological union with RUST score of 12. Both underwent implant removal and sinus tract excision and wound debridement. [Images of one of the 2 cases, who underwent implant removal and wound debridement, are shown below]



One case showed non-union at fracture site with RUST score of 5, but had no signs of infection, planned to undergo

secondary autogenous bone grafting at a later date. Serial follow up x-rays of this case is shown below



One other case had both non-union (RUST score- 4) and deep infection at fracture site with poor outcome on the Ketenjian and Shelton Criteria of Scoring. This patient also was a Diabetic and a chronic alcoholic with poor compliance. Patient follow up was lost after 11 months.

necessary plastic surgical interventions (i.e SSG or Flap Covers) at the earliest, if indications arise. The overall rate of deep infection in our study is only 12% (3 patients) which is comparatively lower to that reported in some of the earlier literatures [2, 10]. Primary Intra-medullary Nailing thus offers the distinct advantage of single step surgery with reduced hospital stay, faster rate of union (as it is a definitive fixation), lesser rates of infection, lower morbidity rates.

**Discussion**

Gustilo’s Type 3A and 3B Compound fractures of Tibia, are quite common in developing countries, and result from high velocity trauma like in RTAs or fall from height. Patients are often brought to hospitals late due to improper health care and transport facilities, poverty and ignorance. The commonly preferred option for management of these cases is wound debridement and External Fixator Stabilization of fractures with long term anti-biotic coverage. A more definitive secondary procedure of ex-fix removal and intramedullary nailing is done once the wound heals and two consecutive CRP values are negative. However Mc Graw *et al* [7], noted a high rate of infection and non-union, if nailing was done after removal of fixator. Furthermore the protracted hospital stay, repeated visits to hospital for follow up and dressing, high risk of osteomyelitis, pin tract infections, non- healing ulcers and social stigmas associated with external fixators, make this approach to management of Compound Tibial fractures an unpopular one. A few studies by Ketenjian and Shelton [6], Zadic [8] and Yokoyama [9] *et al.* have shown that there are definitive advantages of primary internal fixation provided infection could be prevented by careful and radical debridement and use of antibiotics.

**Conclusion**

The results of the study have showed good to excellent functional outcome in majority of patients (84%) who have undergone primary intra-medullary nailing. Hence we strongly advocate the use internal fixation in the management of Type 3A and 3B open Tibial Diaphyseal Fractures, within 24 hours of presenting to hospital. Thorough wound debridement and Early antibiotic coverage are key factors in the successful management was such fractures. If primary wound closure with minimal tension cannot be achieved during the initial surgery, then necessary plastic surgical intervention must be undertaken at earliest if not concomitantly with fracture fixation, to achieve good results. In conclusion, Primary Internal fixation of Compound Tibial Diaphyseal fracture, reduces hospital stay, achieves better functional results without hampering soft tissue healing and reconstruction.

**References**

1. Quamar Azam, MKA Sherwani, Internal fixation in compound type III fractures presenting after golden period, Indian J Orthop. 2007; 41(3):204–208.
2. Whittle AP, Russel TA. Treatment of open fractures of

- tibial shaft with the use interlocking nailing without reaming. *J Bone Joint Surg Am*, 1992; 74:1162–71.
3. Court-Brown CM, McQueen MM. Locked intramedullary nailing of tibial fractures. *J Bone Joint Surg Br*, 1991; 73:959–64.
  4. JM Leow, ND Clement. The radiographic union scale in tibial (RUST) fractures-reliability of the outcome measure at an independent centre. *Bone Joint Res*, 2016; 5:116–121
  5. Akhilesh Kumar, Narendra Singh Kushwaha. To Study Outcome of Intramedullary Nailing in Grade I and II (Gustilo- Anderson) Compound Diaphyseal Fractures of Tibia. *International Journal of Contemporary Medical Research*, 2016; 3 (8).
  6. Katenjian AY, Shelton ML. Primary internal fixation open fractures: A retrospective study of the use of metallic internal fixation in fresh open fractures. *J Trauma*. 1972; 12:756–63.
  7. McGraw JM, Lim EV. Treatment of open tibial-shaft fracture. *J Bone Joint Surg Br*. 1988; 70:900–11.
  8. Zadic FR. Primary internal fixation of compound fractures. *J Bone Joint Surg Br*. 1953; 35:146.
  9. Yokoyama K, Shindo M. Immediate internal fixation for open fractures of the long bones of the upper and lower extremities. *J Trauma*. 1994; 37:230–6.
  10. Gustilo RB, Mendoza RM. Problems in the management of type III (severe) open fractures: A new classification of type III open fractures. *J Trauma*. 1984; 24:742–6.