



# International Journal of Orthopaedics Sciences

ISSN: 2395-1958  
IJOS 2017; 3(3): 537-542  
© 2017 IJOS  
www.orthopaper.com  
Received: 16-05-2017  
Accepted: 17-06-2017

**Dr. Manojkumar HV**  
Professor Department of  
Orthopaedics, Bangalore Medical  
College and Research Institute  
Bengaluru, India

**Dr. Hemanth HP**  
Senior Resident, Department of  
Orthopaedics, Bangalore Medical  
College and Research Institute  
Bengaluru, India

**Dr. Ponnillavan Jayakanthan**  
Junior Resident, Department of  
Orthopaedics, Bangalore Medical  
College and Research Institute  
Bengaluru, India

**Dr. Bhaskar Jyoti Pegu**  
Junior Resident, Department of  
Orthopaedics, Bangalore Medical  
College and Research Institute  
Bengaluru, India

**Dr. Prathmesh MH**  
Junior Resident, Department of  
Orthopaedics, Bangalore Medical  
College and Research Institute  
Bengaluru, India

**Correspondence**  
**Dr. Hemanth HP**  
Senior Resident, Department of  
Orthopaedics, Bangalore Medical  
College and Research Institute  
Bengaluru, India

## Delayed presentation of displaced neck of femur fractures in patients under sixty years of age- A prospective functional outcome assessment study after osteosynthesis

**Dr. Manojkumar HV, Dr. Hemanth HP, Dr. Ponnillavan Jayakanthan, Dr. Bhaskar Jyoti Pegu and Dr. Prathmesh MH**

DOI: <http://dx.doi.org/10.22271/ortho.2017.v3.i3h.86>

### Abstract

**Introduction:** An intracapsular fracture of the neck of the femur in the young adult is a difficult injury to manage. Although internal fixation is the standard treatment for young adults, controversy remains concerning the mode of fixation, the approach to be used (closed vs open), method of reduction, time to fixation, post-operative protocols. Avascular necrosis can occur following this injury because of disruption of the femoral head blood supply. Some believe that emergent fracture reduction is necessary to minimize the risk of avascular necrosis.

**Objective:** In a developing country like ours with many cases presenting late to the hospital after injury, there are very few studies assessing the outcome in such cases. So we did a prospective study to assess the functional outcome in patients with neck of femur fractures presenting after 48hrs to the hospital.

**Methods:** This is a prospective study with patients below the age of sixty years with displaced neck of femur fractures (Garden's grade 3 and 4) presenting after 48 hrs treated with closed reduction and fixation with cannulated cancellous screws. Patients were followed up periodically for a minimum period of 3 years.

**Results:** 28 patients participated in the study of which 18 were males and 10 female patients. Average time to surgery was 2.5days +/-0.3days. Time to union is 15.8 +/- 4.2 weeks. AVN developed in 4(14.2%) and non-union in 3 (10.7%) cases. Functional outcome with Harris Hip score was excellent-good in 22 (78.5%) cases.

**Conclusion:** Accurate reduction with establishment of the smooth curve between the head and neck of femur and accurate placement of screws in the neck with guarded weight bearing protocols in cases with posterior comminution can give good results with this fracture irrespective of the delay in surgery.

**Keywords:** Osteosynthesis, neck of femur fracture, young age, delayed presentation, non-union, time to surgery

### Introduction

A hip fracture, especially a displaced femoral neck fracture, is probably the most devastating consequence of osteoporosis in the increasingly elderly population and a major challenge for health care and society. Femoral neck fractures constitute approximately 50% of all hip fractures and 70–75% of the femoral neck fractures are displaced (Garden III and IV) [1]. Fractures of the hip do occur in younger patients, usually as a result of high-energy trauma [2]. For the non-elderly patient with good bone quality, preservation of the natural hip anatomy and mechanics is a priority as their high functional demands and young age preclude their candidacy for replacement procedures<sup>3</sup>. It is the precarious vascular supply of the femoral head, in conjunction with the difficulties in achieving a stable fixation of the fracture, which can lead to the high incidence of complications with fracture healing. As a result of the disruption of the blood supply to the femoral head, this fracture may be associated with the development of avascular necrosis in 30% to 35% of patients [4, 5, 6]. Avascular necrosis may lead to collapse of the femoral head and subsequent osteoarthritis. Symptomatic avascular necrosis patients may require additional surgery such as osteotomy, bone-grafting, or

arthroplasty, and these procedures may be associated with additional complications and morbidity. The incidence of non-union which is yet another significant problem has been reported to range from 0% [6, 9, 10] to 45% [11]. The belief is that such cases should be regarded as “vascular emergencies” and operative interventions should be rendered within 6-8 hours [7, 8]. The main purpose of treatment is to restore function to the pre-injury state. In some cases, the problem is not diagnosed and patients with delayed fractures are referred to orthopaedic centres. A previous study showed that reduction of a displaced femoral neck fracture improves femoral head blood flow<sup>5</sup>; however, little information is available regarding the influence of the time to reduction and fixation on the outcome [6, 8]. A previous prospective investigation of elderly patients with subcapital hip fracture showed that delaying fracture fixation surgery for up to one week had no effect on the rate of avascular necrosis [4]. In developing country like ours with very little knowledge about this injury among the common man and persisting traditional bone setting practises delayed presentation of displaced neck of femur fractures in young adults is very common. So we did a prospective study to assess the functional outcome in such cases which were treated with osteosynthesis.

### Materials and Methods

Patients with neck of femur fracture admitted in our institute between 2012- 2016 were included in our prospective study. The ethical committee of our institute consented for the study. Inclusion criteria were: 1. Patients age <60 years. 2. Displaced neck of femur fractures (Garden’s Type 3 and 4). 3. Patients presenting to hospital after 48 hours after injury. Exclusion criteria were: 1. Pathologic fracture due to a bone tumour, osteomyelitis, or metabolic bone disease. 2. Patients with inflammatory or noninflammatory arthritis. 3. Ipsilateral femoral shaft fractures. 4. Patients treated with open reduction at the time of surgery. 4. Patient with multi-organ injuries, multiple fractures, history of previous femoral fracture/ hip surgery and with systemic diseases were excluded similarly. Informed written consent was obtained from the patient before taking the patient into the study.

### Operative technique

All patients were treated by closed reduction of the fracture on a fracture table. Minimal traction and rotation was applied first. Reduction was confirmed by using a C-arm on both anterior-posterior (AP) and lateral views. The junction point of the convex femoral head and neck had to produce an S-shaped curve in all planes according to the Lowell’s criteria. A Steinmann pin was inserted into the distal femur whenever necessary in order to provide better control during manipulation and traction. Fracture reduction and fixation was achieved using three cannulated screws. The screws were placed through the lateral approach placed parallel to each other in a large triangular configuration using an angle guide. All screws were placed at a minimum angle of 130° to the shaft of femur. The first screw was placed along the calcar, the second along the posterior cortex and the third in the superior part of the neck. It was considered to be inappropriate if the screws either crossed each other at an angle of more than 10° or if they were converging greater than 10°. If the placement was parallel or the angle was less than 10° to each other it was considered to be appropriate.

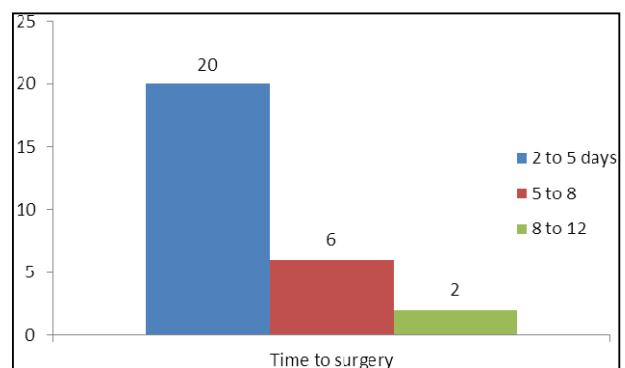
### Follow Up

On the first day postoperatively the patients were advised to do isometric quadriceps exercises. The patients were allowed active assisted mobilisation of the hip as soon as pain allowed and began touch toe weight-bearing. Partial weight-bearing was allowed at 12- 14 weeks and full weight-bearing when there was clinical and radiological evidence of union. The patients were followed up for at least three years. Nonunion was defined as clinical signs of instability at the fractured area or pain in the hip requiring further surgery. Radiologically resorption around the screws, persistence of or an increase in the fracture gap, sclerosis of margins of the fracture, change of the screws orientation in relation to the bone or change of orientation of two fractured fragments signalled towards non-union. AVN was defined as appearance of subchondral sclerosis or presence of segmental collapse as defined by the criteria of Ficat [12]. Patients were followed up with clinical and radiological assessment for a minimum period of 3 years. Functional outcome was assessed with Harris Hip score (HHS) with a score of < 70 considered poor result, 70-79- fair, 80-89- good and 90-100- excellent.

### Results

A total of 28 patients were included in the study of which 18 (64.28%) were males and 10 (35.7%) were females. Motor vehicle accidents in 20 (71.4%) and fall in 8 (28.5%) was the cause of the femoral neck fractures. Average time interval from injury to surgery was 2.5 days +/- 0.3 days (60 +/- 5 hrs). All patients were with displaced Garden’s grade 3 and 4 fractures. All patients underwent CRIF with Cannulated Cancellous screws. The average duration of follow-up before assessment of functional outcome was 36 months +/-2.3 months. The time to union was a mean of 15.8 weeks +/-2.8 weeks. AVN according to Ficat staging >2 was seen in 4 (14.2%) cases. Non-union was encountered in 3 (10.7%) cases. There was no infected case in our study. We didn’t encounter other complications like DVT. Guide wire breakage was encountered in one case and since it couldn’t be retrieved it was left in situ. Of the 4 AVN cases, 3 patients were symptomatic of which 2 cases with segmental involvement in pre-collapse stage were treated with core decompression which went on to heal. 1 patient with stage 3 AVN had to be treated with THR. All the 3 non-union cases were treated with Meyer’s procedure which utilises quadratus femoris muscle pedicle graft augmentation. 2 cases went on to unite successfully and 1 non-union case was treated with THR.

**The time period from injury to surgery is given below:**

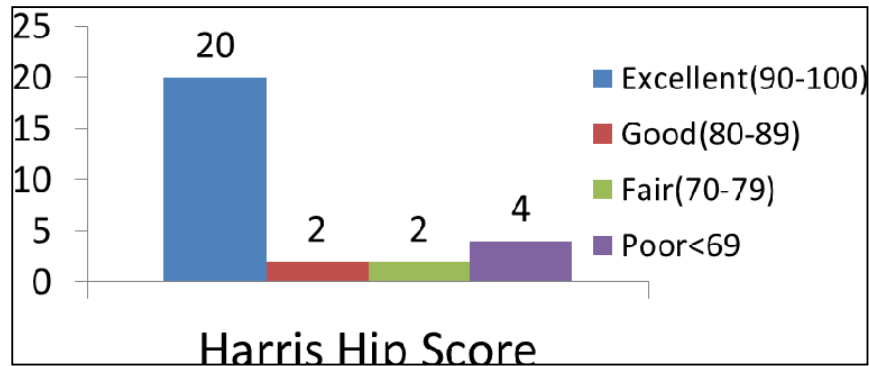


The characteristic of patients with delayed fixation is shown in table below

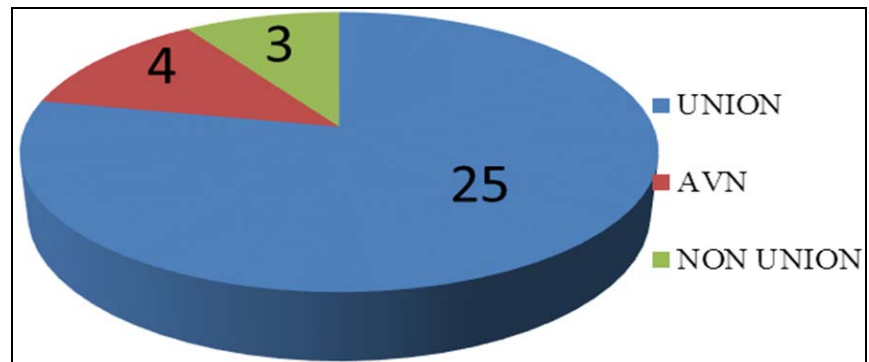
**Table 1:** Characteristics of patients with delayed fixation.

Number of Patients	28
Female	10
Male	18
Mean Age (Standard deviation) at time of injury (years)	36 +/- 12.3
Average time to surgery (hours)	60 +/- 7.2
Fracture fixation	
- Cannulated screws	28
Non-union	3
AVN	4

Functional Outcome: The functional outcome according to HHS is given below.



The results of the study are given in following pie-chart

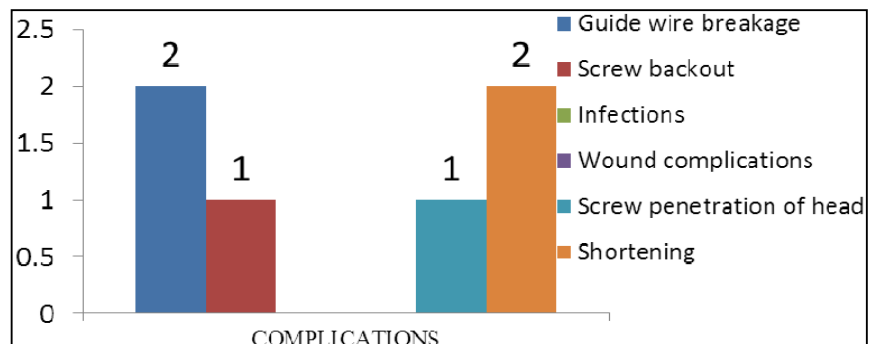


AVN classified according to Ficat’s classification

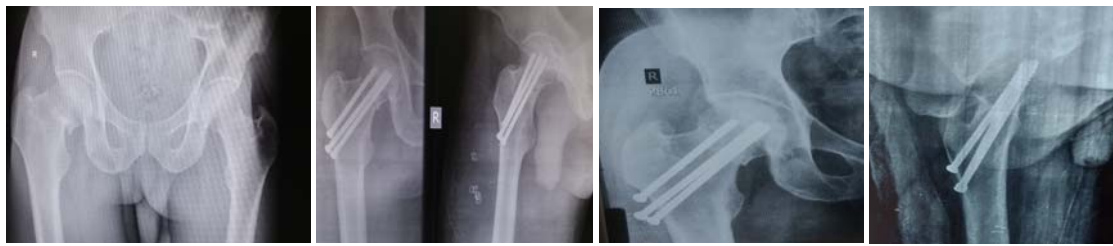**Table 2:** AVN (Ficat’s Classification)

Stage 1	0
Stage 2	2
Stage 3	2
Stage 4	0

The other complications encountered in the study are given in following bar diagram:



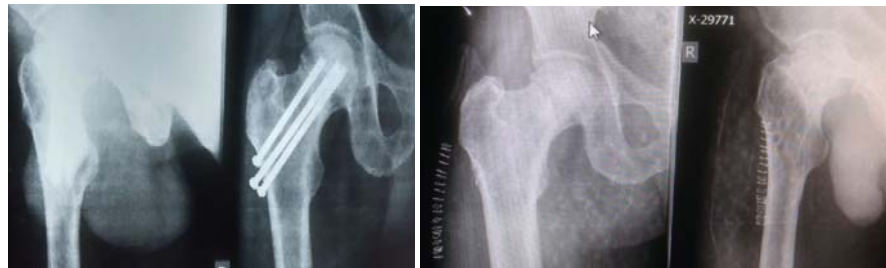### Case Examples



Pre-Op

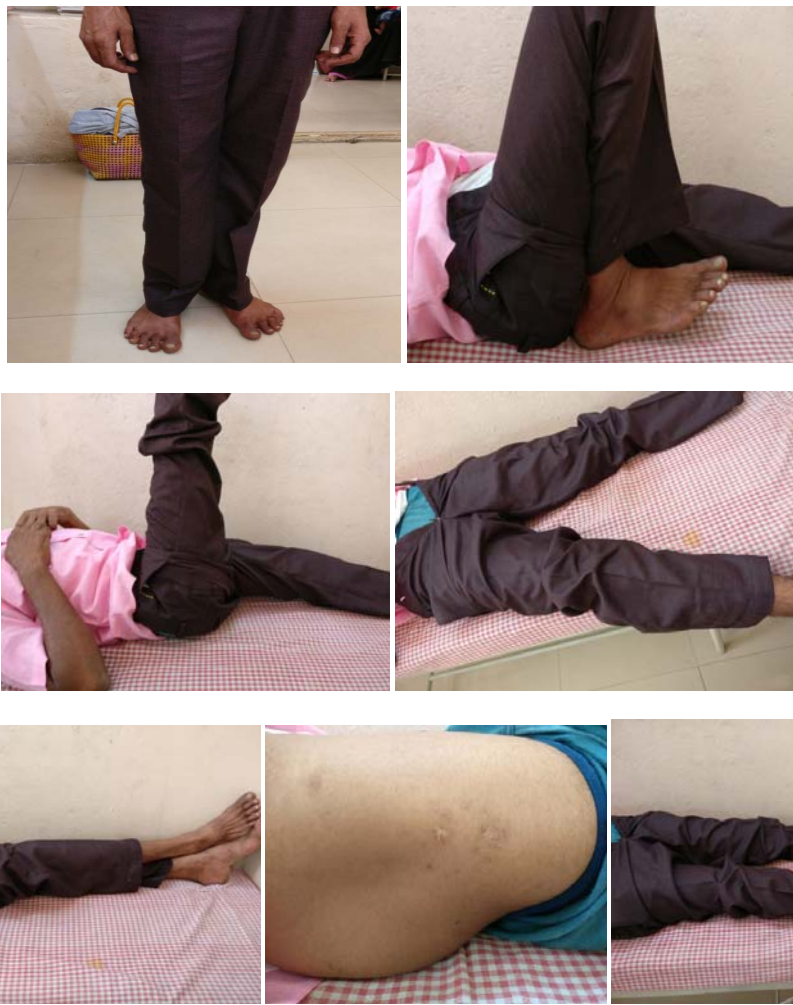Post Op

8 Weeks Follow Up



3 Years Follow Up

Post Implant Removal



### Discussion

The complex anatomy of the femoral neck and its unique blood supply makes early treatment and fixation of high importance [13]. It is fed by a variety of vessels, mainly branches of the medial and lateral femoral circumflex arteries

that branch off the femoral profunda artery that is in turn fed by the common femoral artery. These circumflex arteries encircle the proximal femur in the trochanteric area and branch off into retinacular vessels that pass proximally toward the head in three segments: small anterior, posteroinferior and

posterosuperior retinacular arteries. Additionally, the round ligament of the femur carries arterial supply to the anterosuperior femoral head distally from the acetabular branch of the obturator artery. The terminal arteries are intracapsular and can be easily disturbed with #NOF, their manipulation and changes in intracapsular pressure. Treatment goals for young patients suffering from femoral neck fractures include improvement of fracture outcome through preserving the femoral head, prevention of non-union and avascular necrosis, and return of patients to their previous functional status with a quick rehabilitation [14]. The rates of nonunion and AVN which have been reported after internal fixation vary widely. In various studies [8, 11, 15] nonunion has ranged from 4% to 59% and AVN from 10% to 86% irrespective of whether CRIF or ORIF was used [11, 16]. AVN of the head of the femur is a serious and unpredictable complication which can occur after displaced intracapsular #NOF due to disturbed blood supply of the femoral head. It is also postulated that AVN is more likely to occur in #NOF with delayed time to surgical fixation. The reason behind this was thought to be prolonged kinking of the vessels before reduction of the fracture fragments. It is imperative to anticipate the occurrence of AVN as it can lead to femoral head collapse and osteoarthritis which often necessitates further surgeries and results in inferior outcomes with this fracture. However, there is paucity of evidence-based literature indicating the most favourable time to fixation that minimizes AVN rates post-fixation. In a series of 27 patients belonging to a similar age group, Swiontkowski *et al* [8] achieved union of 100% when surgery was performed within eight hours of the injury. This high rate of union may have been influenced by the number (30%) of undisplaced Garden grade II fractures among their patients. However, 20% of the patients developed AVN. Zetterberg *et al* [17] and Bray [18] also suggested that the timing of surgery after injury was an important factor in influencing the outcome. Karaeminogullari *et al* had similar results when studying AVN and non-union rates in patients whose fractures were fixed before or after the 12 h mark from injury [19]. Before 12 h, ONFH and non-union rates were 12.5% and 25%, versus 14% and 27% after 12 h (not statistically significant). In our study involving delayed fixation i.e >48 hrs in displaced fractures managed only by closed reduction AVN and non-union incidence is 15.6% and 12.5%. The non-union incidence in our study may be less because of undertaking only closed reduction. Upadhyay *et al.* also found no discrepancy in AVN or non-union rates in patients even after 48 h [20]. The clinical illustrations are shown in the figures below.

### Conclusion

It is evident from the study that time to internal fixation of displaced intracapsular #NOF is less important in the prevention of complications like AVN than was initially thought. Patients treated more than 48 h post fracture showed no increased incidence of AVN and other complications. The only technical factor that has been consistently associated with outcomes is the quality of reduction achieved at the time of surgery. Accurate reduction with establishment of the smooth S shaped curve between the head and neck of femur and divergent placement of screws in the neck with guarded weight bearing protocols in cases with posterior comminution can give good results with this fracture irrespective of the delay in surgery. Early recognition of complications like non-union, AVN is essential in young adults and is imperative to

decrease morbidity in these patients. Small sample size and shorter follow up time are some of the limitations of the study.

### References

- Garden RS. Low-angle fixation in fractures of the femoral neck. *Journal of Bone and Joint Surgery Br.* 1961; 43:647.
- Swiontkowski MF. Intracapsular hip fractures. In: Browner BD, Jupiter JB, Levine AM, Trafton PG, editors. *Skeletal trauma. Fractures, dislocations, ligamentous injuries.* Philadelphia: WB. Saunders. 1992; 2:1369-442.
- Girard J, Glorion C, Bonnomet F, Fron D, Migaud H. Risk factors for revision of hip arthroplasties in patients younger than 30 years. *Clin Orthop Relat Res.* 2011; 469:1141-1147.
- Barnes R, Brown JT, Garden RS, Nicoll EA. Subcapital fractures of the femur. A prospective review. *J Bone Joint Surg Br.* 1976; 58:2-24.
- Swiontkowski MF, Tepic S, Rahn BA, Cordey J, Perren SM. The effect of fracture on femoral head blood flow. Osteonecrosis and revascularization studied in miniature swine. *Acta Orthop Scand.* 1993; 64:196-202.
- Tooke SM, Favero KJ. Femoral neck fractures in skeletally mature patients, fifty years old or less. *J Bone Joint Surg Am.* 1985; 67:1255-60.
- Roshan A, Ram S. The neglected femoral neck fracture in young adults: review of a challenging problem. *Clin Med Res.* 2008; 6(1):33-9.
- Swiontkowski MF, Winquist RA, Hansen ST. Fractures of the femoral neck in patients between the ages of twelve and forty-nine years. *J Bone Joint Surg Am.* 1984; 66(6):837-46.
- Dedrick DK, Mackenzie JR, Burney RE. Complications of femoral neck fracture in young adults. *J Trauma.* 1986; 26:932-7.
- Sadat-Ali M, Ahlberg A. Fractured neck of the femur in young adults. *Injury.* 1992; 23:311-3.
- Protzman RR, Burkhalter WE. Femoral-neck fractures in young adults. *J Bone Joint Surg Am.* 1976; 58:689-95.
- Ficat RP. Idiopathic bone necrosis of the femoral head. Early diagnosis and treatment. *J Bone Joint Surg Br.* 1985; 67:3-9.
- Seyfettinoglu F, Ersan O, Kovalak E, Duygun F, Ozsar B, Ates Y. Fixation of femoral neck fractures with three screws: results and complications. *Acta Orthop Traumatol Turc.* 2011; 45(1):6-13.
- Ragnarsson JJ, Boquist L, Ekelund L, Karrholm J. Instability and femoral head vitality in fractures of the femoral neck. *Clin Orthop Relat Res.* 1993; 287:30-40.
- Asnis SE, Wanek-Sgaglione L. Intracapsular fractures of the femoral neck: results of cannulated screw fixation. *J Bone Joint Surg [Am].* 1994; 76:1793-803.
- Gerber C, Strehle J, Ganz R. The treatment of fractures of the femoral neck. *ClinOrthop.* 1993; 292:77-86.
- Zetterberg CH, Irstam L, Andersson GBJ. Femoral neck fractures in young adults. *Acta Orthop Scand.* 1982; 53:427-35.
- Bray TJ. Femoral neck fracture fixation. *Clin Orthop.* 1997; 339:20-31.
- Karaeminogullari O, Demirors H, Atabek M, Tuncay C, Tandogan R, Ozalay M. Avascular necrosis and non-union after osteosynthesis of femoral neck fractures: effect of fracture displacement and time to surgery. *Adv*

Ther. 2004; 21(5):335-342.

20. Upadhyaya A, Jain P, Mishra P, Maini L, Gautum VK, Dhaon BK Delayed internal fixation of fractures of the neck of femur in young adults. A prospective, randomised study comparing closed and open reduction. J Bone Joint Surg. 2004; 86(7):1035-1040.