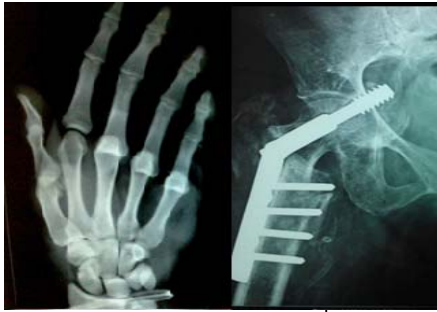



## International Journal of Orthopaedics Sciences

ISSN: 2395-1958  
IJOS 2017; 3(3): 445-452  
© 2017 IJOS  
www.orthopaper.com  
Received: 04-05-2017  
Accepted: 05-06-2017

**Dr. Hrushikesh R Saraf**  
M.S. Ortho, DNB Ortho,  
Orthopaedic Consultant at  
Shashwat Hospital, Pune,  
Maharashtra, India

**Dr. Shreepal Munot**  
M.S. Ortho, Assistant Consultant  
Shashwat Hospital, Pune,  
Maharashtra, India

### Role of teriparatide in fracture healing: A prospective study

**Dr. Hrushikesh R Saraf and Dr. Shreepal Munot**

**DOI:** <http://dx.doi.org/10.22271/ortho.2017.v3.i3g.74>

#### Abstract

**Background:** The biology of bone repair and healing is interesting and a huge number of studies have been done in this aspect with the potential technologies for enhancing fracture-healing. Teriparatide an anabolic agent a recombinant parathyroid hormone preparation that activates osteoblastic bone formation has been used in the treatment of postmenopausal osteoporosis. It has also been reported to be effective in accelerating the rate of fracture healing. The conclusion that PTH as an effective anabolic therapy for the enhancement of bone repair after fracture has been studied in animals and very few case studies. This prospective study was conducted to determine and establish the role of recombinant teriparatide in fracture healing in delayed union fractures, osteoporotic fractures, periprosthetic fractures.

**Materials and Methods:** The study was done on 20 patients with fractures selected on the basis of inclusion and exclusion criteria at Shashwat hospital, Pune during the period of September 2011 to September 2015. All patients were administered 20ug of teriparatide injections daily. The injections were given for 2 - 4 months depending on type of fracture and the time required for radiological evidence of union. Radiographs were taken every 4 weeks to see for callus and fracture union. The primary endpoint of fracture healing was taken as the time of cortical bridging in three of four cortices

**Results:** The fractures treated with 20ug of teriparatide exhibited early signs of union with abundant callus formation significant decrease in radiological union time and early rehabilitation of patients in all three groups.

**Conclusions:** This study shows that the daily systemic administration of recombinant teriparatide enhances fracture-healing by increasing bone mineral content, density and strength. It also produces a sustained anabolic effect throughout the remodeling phase of fracture-healing. It also emphasizes that teriparatide is a relatively safe drug. Economical compared to other options of fracture healing like bone grafting, second surgery and is less invasive and has better patient compliance.

**Keywords:** Teriparatide, fracture healing, callus, delayed union, periprosthetic, osteoporotic fractures

#### Introduction

Bone healing after a fracture is a special form of wound-healing. The bone regenerates rapidly and heals without a scar. The three stages of bone repair are: inflammatory (haematoma formation with induction of inflammation), reparative (callus formation with stabilization), and remodeling (balancing and returning to its near normal structure). When a bone is injured and sustains a fracture there is a release of inflammatory cells which cause the release of many variety of substances which include TNF $\alpha$ , growth factors, VEGF, IL-3/6, fibronectin, histamine, fibroblasts, endothelial cells, osteoblasts and many more which all in conjuncture help fill the void at the fracture site with inflammatory tissue. The second stage which is the reparative phase begins at about 2 weeks and involves a periosteal response with new blood vessel formation for the new bone and cells to survive and nourishment. This leads to the stabilization of the fracture site with the formation of connective tissue and soft callus, which is gradually turned into immature woven bone via intramembranous or endochondral bone formation. The final stage is the remodeling phase where the woven bone callus is eventually replaced by lamellar bone. In many cases the fracture healing is by endochondral bone formation pathway, but an intervention with a rigid fixation can lead to a primary cortical repair. In course of time the fracture undergoes osteoclast-mediated remodeling which leads to the restoration of its original geometry and structural integrity. Despite this inherent complex and co-ordinated nature of the repair process, many patients still require a longer duration of

#### Correspondence

**Dr. Hrushikesh R Saraf**  
M.S. Ortho, DNB Ortho,  
Orthopaedic Consultant at  
Shashwat Hospital, Pune,  
Maharashtra, India

time before a fracture is completely healed and returns to its original identity. This has promoted keen interests in the biology and its modifications in treatments that could stimulate and increase the rate of fracture healing and repair, providing decreased morbidity and an early return to an active lifestyle and work.

This fracture healing is assisted by many biological agents, one of them being the parathyroid hormone. Biochemically parathyroid hormone (PTH) is a protein polypeptide made up of amino-acids. It is a key regulator in the calcium and phosphate metabolism. The principal effect of PTH in the metabolism and maintaining the bone mineral equilibrium are to increase serum calcium levels which is by increasing the gastrointestinal calcium absorption, increases renal calcium and phosphate reabsorption, activates osteoclasts to release calcium from the skeleton in response to hypocalcemia, and play a role in the regulation of vitamin-D metabolism<sup>1</sup>. The teriparatide hormone is a synthetic molecule which has the first 34 fragments of the biological human parathyroid hormone and hence retains most of the biochemical activities of the human PTH<sup>[3]</sup>. When teriparatide is intermittently administered it has similar anabolic effects of PTH that stimulate bone formation and activate bone remodeling<sup>[2, 4]</sup>, enhancing the micro-architecture of the trabecular and cortical bone<sup>[5]</sup>. Some of the earlier studies and papers reported that teriparatide also increased bone mineral density and lowered the risk of vertebral and non-vertebral fractures<sup>[6, 7]</sup>. Teriparatide was the only anabolic molecule used in osteoporosis which had a approval by the Food and Drug Administration<sup>[8]</sup>.

The electron microscopic study of the structure of Parathyroid hormone have proved that the N-terminal portion of the PTH molecule with the first 34 amino acids called PTH(1-34) is the main structure responsible for most of its biological activity<sup>[9, 10]</sup>. The teriparatide molecule has a mass of 4117.8 daltons<sup>[11]</sup>. It is synthesized using a genetically altered strain of *Escherichia coli* and is manufactured in a solution form for subcutaneous injection<sup>[11]</sup>.

Teriparatide when administered intermittently has the ability to stimulate bone formation hence it seems reliable to consider that teriparatide might improve and enhance the bone quality and hence aid in fracture healing<sup>[12-15]</sup>. Some of the new studies about fragility fracture cases have been benefited with the administration of teriparatide<sup>[16, 17]</sup>. An increasing number of clinical studies have shown that the administration of PTH (1-34) is beneficial in the treatment of preventing fragility fractures in patients with osteoporosis, these studies have shown that even after discontinuing the treatment the positive effects are seen for many years<sup>[19-22]</sup>. The continued growth and positive effects have led to the development of particular PTH analogs (1-31, 1-34, or 1-84) and similar compounds of Parathyroid hormone in the region of dual coupled remodeling, and hence drastically providing increased patient benefit and compliance. Teriparatide increases cortical as well as trabecular bone density by increasing bone formation and also promotes resorption of the bone by osteoclasts<sup>[23-27]</sup>.

The biochemical action of Teriparatide is via the PTH-1 receptors which is present on the bone forming osteoblasts and bone marrow stromal cells to induce osteoblastic bone formation and increased mineralization<sup>[25]</sup>. As a result of this increased mineralisation there is reduction in the fragility fractures which is equal to or over, those seen by the use of antiresorptive agents<sup>[15]</sup>. The increase in the bone mineral density induced by teriparatide is considerable which ranges from 10% to 15% in 2 to 3 years in most of the studies<sup>[28-33]</sup>.

These studies most of which have been single case reports or animal studies and hence there is a controversy in the matter of the use of teriparatide in fracture preventing and healing. A few of the randomized controlled trials (RCTs) have shown that there was no significant difference between the group treated with teriparatide and the group treated with placebo<sup>[34, 35]</sup>. Considering all these factors the evidence of light on this subject of matter is very minimal and hence the action of teriparatide in fragility fracture healing remains an enigma and is controversial. In view of this we have designed a study to demonstrate and know the use and efficacy of teriparatide in enhancing fracture healing in different fracture groups that includes delayed union, osteoporotic, periprosthetic fractures.

### Materials and methods

The study was done on 20 patients with fractures selected on the basis of inclusion and exclusion criteria at Shaswat hospital, Pune during the period of September 2011 to September 2015. This study included both male and female patients.

Inclusion criteria were patients with 1) age more than 25 years 2) delayed union 3) periprosthetic fractures 4) osteoporotic fractures. Exclusion criteria were 1) Age less than 25 years 2) Compound fractures 3) Associated significant systemic comorbid illness 4) History of tumor or chemotherapy, bone metastases, metabolic bone disease, rheumatoid arthritis, chronic renal failure 5) pregnant and lactating women.

The patients which satisfied the inclusion criteria were selected and on arrival at the hospital detailed history and clinical examination was done. Routine blood investigations like CBC, ESR, RFT, RBS were done. Concomitant co morbidities were addressed and specific treatment given. X-rays were taken before starting the injection in at least two views preferably AP and Lateral views.

Patients were explained in detail about the injection its nature of action, the course of treatment and its side effects. Once the patients agreed to the treatment, informed valid written consent was taken. All patients were administered 20ug of teriparatide injections daily, first 2-3 injections were given under guidance and later patient advised to continue the same daily at home. Injection were given subcutaneously in the lower abdomen or thigh through a preloaded syringe which contain drug for 28 days. Injection can be taken any time in a day but patients were advised to take it usually at a same time daily. Any left over drug after 28 days discarded with the syringe. syringe kept in refrigerator at 2<sup>o</sup> to 8<sup>o</sup> C and never kept in freezer. Patients were informed to report to the hospital in case of any complications like nausea, vomiting, dizziness, cramps, weakness.

Injections were started immediately in periprosthetic and osteoporotic fractures and in delayed union once the diagnosis was established. Injections were given for 2-4months depending on type of fracture and radiological evidence of union. Radiographs were taken every 4 weeks to see for callus and fracture union. Patients were enquired about drug compliance, adverse effect and complications associated with daily injections. The primary endpoint of fracture healing was taken as the time of cortical bridging in three of four cortices. all patients were given daily calcium supplement of 1000 mg and vitamin D3 60,000 IU weekly. NSAIDs was given for pain relief. splints like slab, immobilisers, brace were given specific to a fracture. Isovolumetric exercises usually started immediately. isotonic and weight bearing started when radiological callus seen on radiogram minimum after 4 weeks.

**Results**

A total of 20 patients with 20 fractures treated were evaluated in this study (Table 11). The mean age of the patients were 60.7 years (delayed union 48.42 years, osteoporotic 76 years, periprosthetic group 57.16 years) and ranged from 40-83 years. A total of 10 males (50%) and 10 females (50%) were involved. Fractures involving various anatomical sites were evaluated. Fracture sites included humerus, radius, wrist, femur, tibia, and ankle. A total of 20 patients had daily injection of subcutaneous teriparatide. All of the patients were administered 20µg of teriparatide. The signs of healing were seen in all the patients at 3-4 weeks. The mean dosage of teriparatide injection time was 12.6 weeks. The minimum duration was 10 and the maximum duration was 16 weeks. We analysed the efficacy of teriparatide via radiological outcome. Radiological findings involved the use

of Xrays to assess for callus formation, bony bridging, reduction of fracture line and complete bony union.

The mean time to bony bridging after starting PTH (1-34) varied widely across different fracture groups. (table 2) For delayed union fractures, administration of teriparatide was associated with a mean time to bony bridging of 12 weeks. For periprosthetic fractures the average healing time was 12.6 weeks. 13.2 weeks for osteoporotic fracture group.

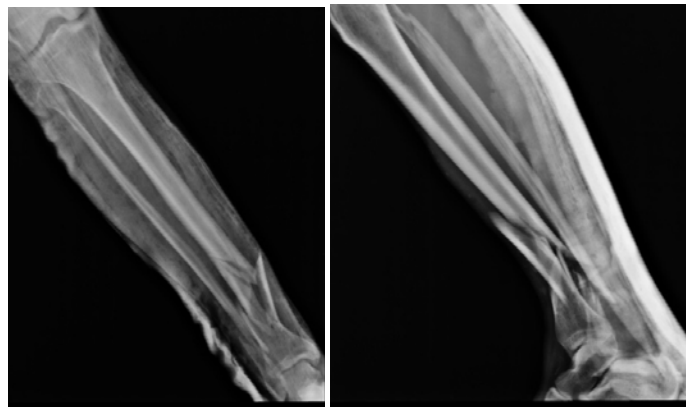
A total of 6 patients experienced mild side effect from teriparatide administration. 1 patients complained of dizziness while 3 patients reported mild side effects such as nausea, vomiting and 2 patients reported to have leg cramps. No other side effects were noted from the studies involving teriparatide administration. none of the side effects were that significant to cause discontinuation of teriparatide.

**Table 1**

S. No.	Id	Age	Sex	Diagnosis	When teriparatide Started	Duration of injection (in weeks)	Upper limb(ul)/ Lower limb (ll)	Comobrid	Complication
1		47	M	Delayed Union	16weeks	14	LL	-	-
2		78	F	Osteoporotic #	Immediately	16	LL	DM	Nausea
3		50	M	Periprosthetic #	Immediately	13	LL	-	-
4		79	F	Osteoporotic #	Immediately	12	LL	HTN	-
5		72	M	Osteoporotic #	Immediately	12	UL	HTN	Cramps
6		75	F	Osteoporotic #	Immediately	13	UL	-	-
7		42	M	Delayed Union	24weeks	12	LL	-	-
8		52	M	Delayed Union	24weeks	10	LL	-	Cramps
9		58	F	Delayed Union	22weeks	11	UL	HTN	-
10		52	M	Periprosthetic #	Immediately	14	UL	-	--
11		70	F	Osteoporotic #	Immediately	14	LL	DM/HTN	-
12		75	F	Osteoporotic #	Immediately	12	LL	-	-
13		40	M	Delayed Union	26weeks	14	UL	-	-
14		60	M	Delayed Union	21weeks	11	UL	-	Dizziness
15		40	F	Delayed Union	25weeks	12	LL	-	-
16		60	M	Periprosthetic #	Immediately	10	UL	HTN	Nausea
17		65	F	Periprosthetic #	Immediately	12	UL	-	-
18		56	M	Periprosthetic #	Immediately	14	LL	-	Nausea
19		60	F	Periprosthetic #	Immediately	13	LL	HTN	-
20		83	F	Osteoporotic #	Immediately	14	LL	-	-

**Table 2**

Group	No of patients	Age	Injection Started	Weeks
Osteoporotic	7	76	Immediately	13.2weeks
Delayed Union	7	48.42	22.57weeks	12weeks
Periprosthetic Fracture	6	57.16	Immediately	12.6weeks

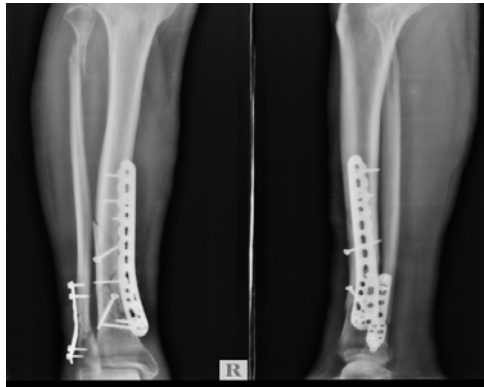


Pre op x-ray

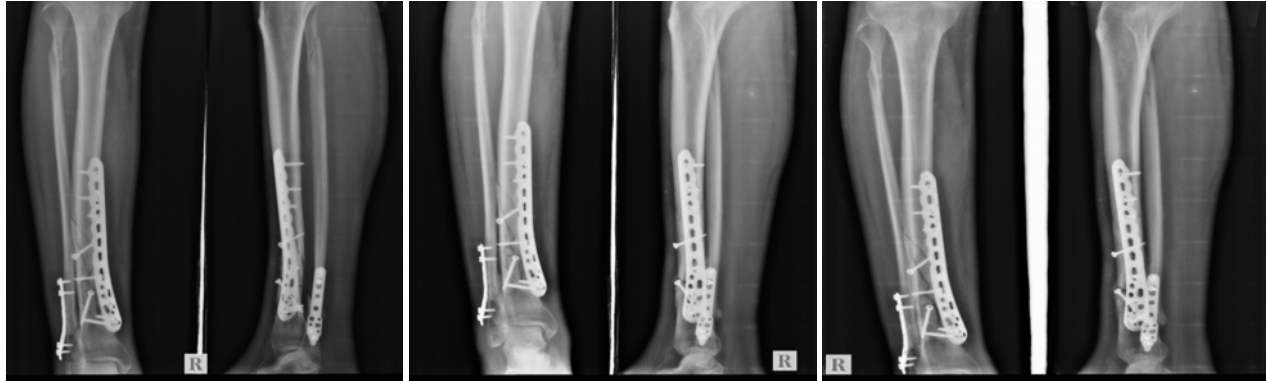**Case 1**

42 years/M

Patient had history of RTA 2 years back and sustained injury to right leg



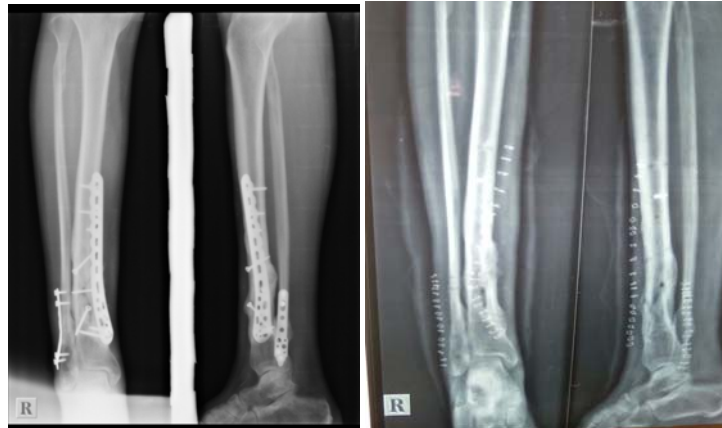Post op x-ray



4 weeks post op

12 weeks post op

24 weeks follow up



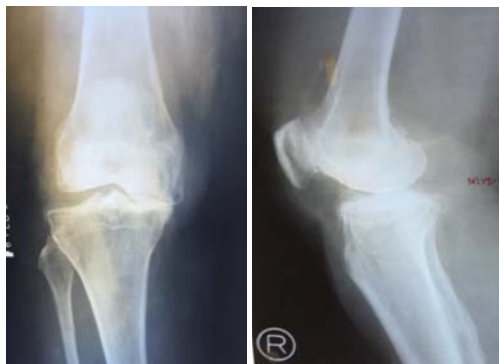After 3 months of therapy

After implant removal

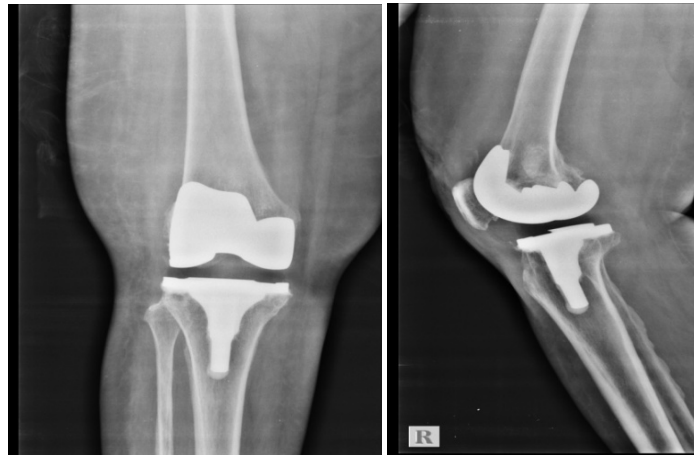
**Case 2**

Age: 78 yrs/F

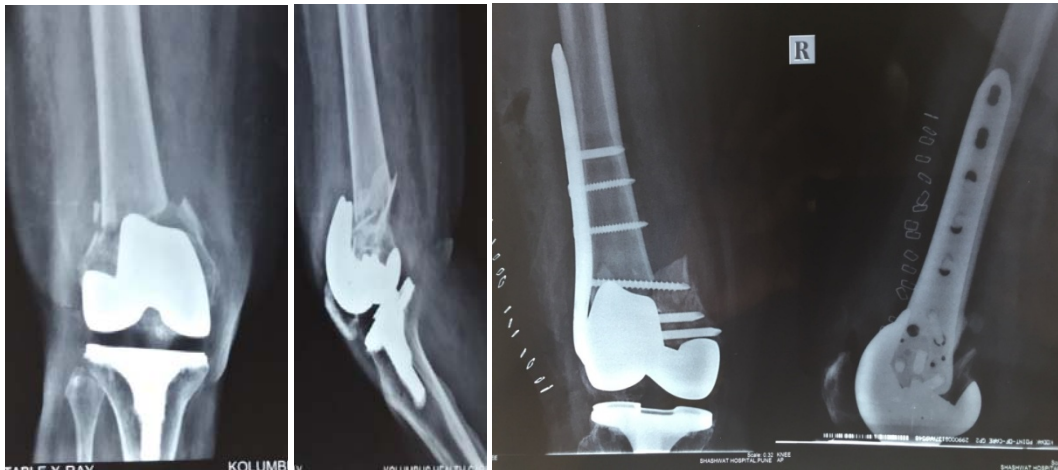Bilateral osteoarthritis knee for which bilateral TKR done 4 years back



Pre op x-ray

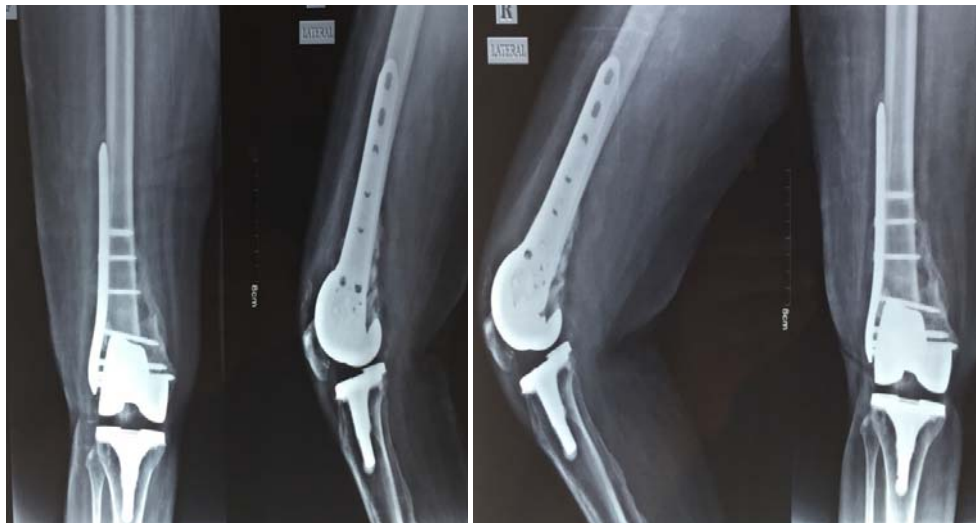

Post op x-ray

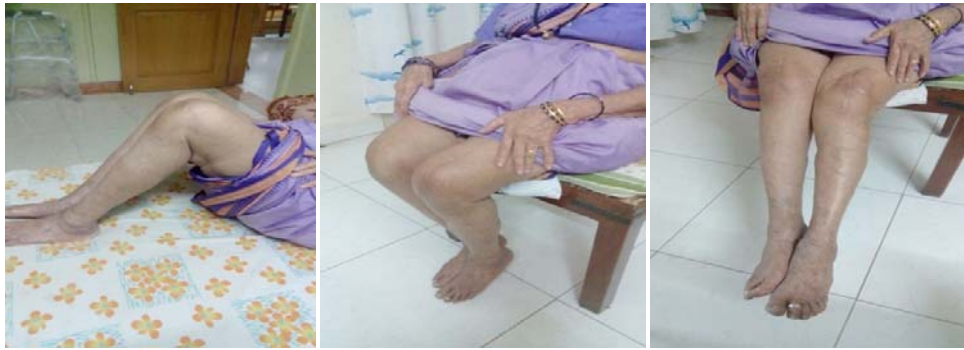

6 month back she had history of fall injury to right knee comminuted fracture and papery thin fracture fragments

ORIF with locking plate and screw



12 weeks after teriparatide inj 16 weeks after teriparatide inj



## Discussion

Fracture healing is considered as a very complex process that involves the coupled effect of resorption and formation. For elderly osteoporotic subjects, the bone is ductile, weak and undergoes plastic deformation well before fragility breaks can occur. The main action of the synthetic molecule teriparatide is to enhance and stimulate bone formation which is by increasing the osteoblastic activity. It does not stimulate bone resorption. This is known as the “anabolic window.” There a number of mechanisms for teriparatide to facilitate fracture healing, which include promoting proliferation and differentiation of mesenchymal stem cell, chondroprogenitors and osteoprogenitors, chondrocyte maturation, production of bone matrix proteins, and formation of osteoclasts. In the course of fracture healing, it can promote callus formation by incorporating and stimulating the proliferation and differentiation of osteoprogenitors and chondroprogenitors [36, 37]. It also promotes the early callus formation and callus remodeling by stimulating matrix proteins for the bones and formation of osteoclasts [37]. The Wnt/ $\beta$ -catenin signaling pathway which regulates the type II and X collagen involved in determining the size of the callus is also promoted and enhanced by the administration of teriparatide [38].

The effect of Teriparatide on fracture healing has been shown to be beneficial. Some of the literature and recent papers on the effect of teriparatide in primary union, delayed and non-union have resulted in enhancement in the time to clinical and radiological union. Chintamaneni *et al.* (2010) noted that the dramatic radiographic healing of a non-union sternal fracture was achieved only after intervention with teriparatide (Chintamaneni *et al.*, 2010).

One of the study analysed the effects of PTH (1-84) on fracture healing in 65 postmenopausal women with osteoporosis who had sustained a pelvic fracture. Although the PTH compound used was different (PTH 1-84 vs. PTH 1-34), the additional fifty amino acids in PTH 1-84 are inactive and the resulting bio-efficacy of the two compounds remain the same. Both are known to have similar anabolic effects although there is currently a paucity of comparative studies between the two (Verhaar and Lems, 2009). Peichl *et al.* (2011) found that administration of PTH 1-84 (100  $\mu$ g day-1) resulted in a shorter fracture union time in primary union compared to a control group (Peichl *et al.*, 2011). Pubic bone fracture treated with PTH 1-84 achieved fracture union in 7.8 weeks compared to 12.6 weeks a control group ( $p < .001$ ). By eight weeks all fractures in the treatment group ( $n = 21$ ) had healed in contrast to 4 fractures in the control group ( $n = 44$ ). (Healing rate, 100% [95% CI, 86.7-100.0%] compared with 9.1% [95% CI, 2.5-21.7%]). The treatment group also had statistically significant improved clinical and functional outcomes ( $p < .001$ ) as compared to the control group (assessed with both visual analogue scale for pain and a timed

up and go test).

In another prospective randomized double-blind clinical study by Aspenberg *et al.* (2010) the use of teriparatide (PTH 1-34) resulted in shorten time to fracture healing in conservatively treated distal radial fractures (Aspenberg *et al.*, 2010). Time to healing was significantly shorter in the treatment group ( $n = 34$ ) that received teriparatide 20  $\mu$ g day-1 (7.4 weeks,  $p = 0.006$ ) as compared to the control group (9.1 weeks,  $n = 34$ ). Surprisingly, the study acknowledges a lack of dose response relationship with intermittent administration of PTH 1-34. The treatment group ( $n = 34$ ) that received teriparatide 40  $\mu$ g day-1 showed shorter healing time compared to the control group. Youngwoo Kim *et al.* studied effect of teriparatide in femoral shaft fractures showed that the callus formation after teriparatide therapy was approximately 2 weeks more early than normal healing. Moreover, this callus formation progressed for 8 weeks and led to healing of the fracture. In delayed unions the treatment of choice is bone grafting but this procedure is not without complications of the fracture site as well the donor site morbidity. In our study we see that union was achieved in such fractures with only the use of teriparatide.

Teriparatide also is useful in the management of hypophosphatemic patients. These patients who have defective bone mineralization are benefitted by treatment with teriparatide.

The safety profile of Teriparatide continues to be excellent with only 8 of patients experiencing mild side effects ranging from nausea, vomiting and headache. In the study by Peichl *et al.* (2011) no adverse events or death were recorded among the 21 patients who took PTH 1-84 for 24 months (Peichl *et al.*, 2011). The long-term safety profile of teriparatide is however still unknown. The anabolic effects of teriparatide when given long-term and in supra-physiological doses were associated with an increased risk of osteosarcomas in Fisher rats (Vahle *et al.*, 2002). This risk is negated by the use of smaller doses in humans and is somewhat comparable to the general population risk, where only 1 case of osteosarcoma has been reported (Harper *et al.*, 2007) among more than 250,000-300,000 patients treated with teriparatide worldwide (Solomon *et al.*, 2009). Due to this risk profile of the hormone its use is cautioned in patients with significant history of primary or metastatic bone tumours, Paget's disease, unexplained high levels of ALP, history of radiation therapy involving the bones or metabolic bone disease excluding osteoporosis, pregnancy and breast feeding (Guide *et al.*, 2002). Some of the other side effects of teriparatide include dizziness, constipation, lethargy, muscle weakness and cramping in the legs which is due to raised serum calcium levels.

The local side effects at the site of injection include erythema, swelling, itch and pain. Teriparatide also can raise the serum

uric acid levels and precaution has to be taken in patients with renal impairment.

We acknowledge several limitations in our study. Considering that teriparatide has not commonly been used in fracture healing and its recent application for the same. The small sample size and the lack of control group were the other limitations.

### Conclusion

Teriparatide is a relatively safe drug with minimal adverse effects. Economical compared to other options of fracture healing like bone grafting, second surgery. Less invasive, more cost effective and better patient compliance. Enhances fracture healing by stimulating exuberant callus formation and has constant positive anabolic effect throughout the period of remodeling in fracture-healing. Teriparatide is an effective therapy to enhance the bone material density and prevent fragility fractures in elderly patients. However, studies across this field are not much and some more clinical studies are needed to determine the usefulness of teriparatide and the clinical indications for the use of teriparatide in the treatment of fracture healing.

### References

- Jüppner H, Kronenberg HM. Parathyroid hormone. In: Favus MJ, editor. Primer on the metabolic bone diseases and disorders of mineral metabolism. 5th ed. Washington, DC: American Society for Bone and Mineral Research. 2003, 117-24.
- Jilka RL. Molecular and cellular mechanisms of the anabolic effect of intermittent PTH, *Bone*, 2007; 40(6):1434-1446.
- Kneissel M, Boyde A, Gasser JA. Bone tissue and its mineralization in aged estrogen-depleted rats after long-term intermittent treatment with parathyroid hormone (PTH) analog SDZ PTS 893 or human PTH (1-34), *Bone*, 2001; 28(3):237-250.
- Kraenzlin ME, Meier C. Parathyroid hormone analogues in the treatment of osteoporosis, *Nature Reviews Endocrinology*, 2011; 7(11):647-656.
- Chen P, Jerome CP, Burr DB *et al.* Interrelationships between bone microarchitecture and strength in ovariectomized monkeys treated with teriparatide. *Journal of Bone and Mineral Research*. 2007; 22(6):841-848.
- Neer RM, Arnaud CD, Zanchetta JR *et al.* Effect of parathyroid hormone (1-34) on fractures and bone mineral density in postmenopausal women with osteoporosis. *The New England Journal of Medicine*, 2001; 344(19):1434-1441.
- Kaufman J-M, Orwoll E, Goemaere S *et al.* Teriparatide effects on vertebral fractures and bone mineral density in men with osteoporosis: treatment and discontinuation of therapy. *Osteoporosis International*. 2005; 16(5):510-516.
- Martin TJ, Quinn JMW, Gillespie MT, Ng KW, Karsdal MA, Sims NA. Mechanisms involved in skeletal anabolic therapies. *Annals of the New York Academy of Sciences*. 2006; 1068(1):458-470.
- Neer RM, Arnaud CD, Zanchetta JR, Prince R, Gaich GA, Reginster JY *et al.* Effect of parathyroid hormone (1-34) on fractures and bone mineral density in postmenopausal women with osteoporosis. *N Engl J Med* 2001; 344:1434-1441. [PMID:11346808 DOI: 10.1056/NEJM200105103441904]
- Hodsman AB, Bauer DC, Dempster DW, Dian L, Hanley DA, Harris ST *et al.* Parathyroid hormone and teriparatide for the treatment of osteoporosis: a review of the evidence and suggested guidelines for its use. *Endocr Rev*. 2005; 26:688-703. [PMID:15769903 DOI: 10.1210/er.2004-0006]
- Berg C, Neumeyer K, Kirkpatrick P. Fresh from the Pipeline: Teriparatide. *Nat Rev Drug Discov*. 2003; 2:257-258. [DOI:10.1038/nrd1068]
- Komatsubara S, Mori S, Mashiba T *et al.* Human parathyroid hormone (1-34) accelerates the fracture healing process of woven to lamellar bone replacement and new cortical shell formation in rat femora, *Bone*, 2005; 36(4):678-687.
- Komrakova M, Stuermer EK, Werner C *et al.* Effect of human parathyroid hormone hPTH (1-34) applied at different regimes on fracture healing and muscle in ovariectomized and healthy rats, *Bone*, 2010; 47(3):480-492.
- Gardner MJ, Van Der Meulen MCH, Carson J *et al.* Role of parathyroid hormone in the mechanosensitivity of fracture healing. *Journal of Orthopaedic Research*. vol. 2007; 25(11):1474-1480.
- Li YF, Zhou CC, Li JH *et al.* The effects of combined human parathyroid hormone (1-34) and zoledronic acid treatment on fracture healing in osteoporotic rats. *Osteoporosis International*, 2012; 23(4):1463-1474.
- Huang T-W, Yang T-Y, Huang K-C, Peng K-T, Lee MS, Hsu W-WR. Effect of teriparatide on unstable pertrochanteric fractures, *Bio Med Research International*. 2015, 8. Article ID 568390.
- Cheung AM, Tile L, Austin N *et al.* Use of teriparatide in patients with atypical femur fractures. *Journal of Bone and Mineral Research*. 2011, 26.
- Cheung AM, Adachi J, Khan A *et al.* Effect of teriparatide on healing of atypical femoral fractures: a systemic review. *Journal of Bone and Mineral*. 2015; 22(4):183-189.
- Neer RM, Arnaud CD, Zanchetta JR, Prince R, Gaich GA, Reginster JY *et al.* Effect of parathyroid hormone (1-34) on fractures and bone mineral density in postmenopausal women with osteoporosis. *N Engl J Med*. 2001; 344:1434-41.
- Lindsay R, Scheele WH, Neer R, Pohl G, Adami S, Mautalen C *et al.* Sustained vertebral fracture risk reduction after withdrawal of teriparatide in postmenopausal women with osteoporosis. *Arch Intern Med*. 2004; 164:2024-30.
- Prince R, Sipsos A, Hossain A, Syversen U, Ish-Shalom S, Marciniowska E *et al.* Sustained non vertebral fragility fracture risk reduction after discontinuation of teriparatide treatment. *J Bone Miner Res*. 2005; 20:1507-13.
- Kaufman JM, Orwoll E, Goemaere S, San Martin J, Hossain A, Dalsky GP *et al.* Teriparatide effects on vertebral fractures and bone mineral density in men with osteoporosis: treatment and discontinuation of therapy. *Osteoporosis Int*. 2005; 16:510-6.
- Dempster DW, Cosman F, Kurland ES *et al.* Effects of daily treatment with parathyroid hormone on bone microarchitecture and turnover in patients with osteoporosis: a paired biopsy study. *J Bone Miner Res*. 2001; 16:1846-53.
- Gabet Y, Kohavi D, Müller R *et al.* Intermittently administered parathyroid hormone 1-34 reverses bone

- loss and structural impairment in orchietomized adult rats. *Osteoporos Int*, 2005; 16(11):1436-43.
25. Compston JE. Skeletal actions of intermittent parathyroid hormone: effects on bone remodelling and structure. *Bone*. 2007; 40(6):1447-52.
  26. File E, Deal C. Clinical update on teriparatide. *Curr Rheumatol Rep*. 2009; 11(3):169-76.
  27. Bilezikian JP. Anabolic therapy for osteoporosis. *Int J Fertil Womens Med*. 2005; 50(2):53-60.
  28. McClung M. Parathyroid hormone for the treatment of osteoporosis. *Obstet Gynecol Surv*, 2004; 59(12):826-32.
  29. Hodsman AB, Fraher LJ, Watson PH *et al*. A randomized controlled clinical trial to compare the efficacy of cyclical parathyroid hormone versus cyclical parathyroid hormone and sequential calcitonin to improve bone mass in postmenopausal women with osteoporosis. *J Clin Endocrinol Metab*, 1997; 82:620-28.
  30. Sambrook PN. Anabolic therapy in glucocorticoid-induced osteoporosis. *N Engl J Med*. 2007; 357(20):2084-86.
  31. Kurland ES, Cosman F, McMahon DJ *et al*. Parathyroid hormone as a therapy for idiopathic osteoporosis in men: effects on bone mineral density and bone markers. *J Clin Endocrinol Metab*, 2000; 85: 3069-76.
  32. Rosen CJ, Bilezikian JP. Anabolic therapy for osteoporosis. *J Clin Endocrinol Metab*, 2001; 86:957-64.
  33. Lukaszewicz J, Karczmarewicz E, Pludowski P *et al*. EPOLOS Group: Feasibility of simultaneous measurement of bone formation and bone resorption markers to assess bone turnover rate in postmenopausal women: an EPOLOS study. *Med Sci Monit*, 2008; 14(12):PH65-70.
  34. Kanakaris NK, West RM, Giannoudis PV. Enhancement of hip fracture healing in the elderly: evidence deriving from a pilot randomized trial, *Injury*. 2015; 46(8):1425-1428.
  35. Johansson T. PTH1-34 (teriparatide) may not improve healing in proximal humerus fractures. *Acta Orthopaedica*. 2016; 87(1):79-82.
  36. Nakazawa T, Nakajima A, Shiomi K, Moriya H, Einhorn TA, Yamazaki M. Effects of low-dose, intermittent treatment with recombinant human parathyroid hormone (1-34) on chondrogenesis in a model of experimental fracture healing. *Bone*. 2005; 37(5):711-719.
  37. Nakajima A, Shimoji N, Shiomi K *et al*. Mechanisms for the enhancement of fracture healing in rats treated with intermittent low-dose human parathyroid hormone (1-34). *Journal of Bone and Mineral Research*. 2002; 17(11):2038-2047.
  38. Kakar S, Einhorn TA, Vora S *et al*. Enhanced chondrogenesis and Wnt signaling in PTH-treated fractures. *Journal of Bone and Mineral Research*. 2007; 22(12):1903-1912.