

ISSN: 2395-1958
IJOS 2017; 3(3): 236-240
© 2017 IJOS
www.orthopaper.com
Received: 14-05-2017
Accepted: 15-06-2017

Dr. Jagadeesh Babu Somesula
MS (Orthopaedics), Assistant
Professor, Dept. of Orthopaedics,
RVM Institute of Medical
Sciences and Research Centre,
Laxmakkapalli (v), Mulugu (M),
Siddipet Dist, Telangana, India

**Dr. Malleswara Rao Perumalla
Venkata Naga**
MS (Orthopaedics), Associate
Professor, Dept. of Orthopaedics,
NRI Institute of Medical
Sciences, Sangivalasa,
Visakhapatnam, Andhra
Pradesh, India.

Corresponding author
**Dr. Malleswara Rao Perumalla
Venkata Naga**
MS (Orthopaedics), Associate
Professor, Dept. of Orthopaedics,
NRI Institute of Medical
Sciences, Sangivalasa,
Visakhapatnam, Andhra
Pradesh, India.
E-mail: drmallipvn@yahoo.com

A prospective study of surgical management of distal radius fracture in adult with plate fixation

**Dr. Jagadeesh Babu Somesula and Dr. Malleswara Rao Perumalla
Venkata Naga**

DOI: <http://dx.doi.org/10.22271/ortho.2017.v3.i3d.47a>

Abstract

Distal end radius fracture is one of the most common injuries and management of these fractures is still a challenge for orthopaedic surgeon in achieving good functional results. The present study was undertaken to assess the functional outcome of distal radial fractures in adults treated by plate fixation. All the patients were operated with open reduction and internal fixation with volar plate and screws with or without K-wire fixation. The functional outcome was assessed by demerit-point system of Gartland and Werley score. 8 (40%) patients had excellent results, 11 (55%) had good results, 1 (5%) patient had fair results and no patient had poor results. Distal end radius fractures treated by fixation with volar plate and screws or K-wire gives good result in terms of union, functional recovery and prevent stiffness. Open reduction and internal fixation provides best chance for restoring joint congruity and therefore patients treated by this method have a lesser chance of developing secondary osteoarthritis with minimal complications and is a better option for surgical management of these fractures.

Keywords: distal radius fracture, internal fixation, open reduction, K-wire, screws, volar plates

1. Introduction

Distal end radius fractures constitute one of the most frequent injuries encountered by orthopaedic surgeons accounting for 17.5% of all adult fractures^[1].

The purpose of treatment of a distal radius fracture is to maintain normal length, strength, mobility and the function in hand and wrist. Restoration of radial length (distance from radial styloid process to the distal end of ulna), volar angulation, congruity of articular surface, and ulnar variance is important for good functional result. Failure to maintain an accurate anatomic reduction can lead to mal-union, degenerative arthritis, distal radio-ulnar and metacarpal instability and ulnar impaction syndrome with resultant pain, decrease in mobility, grip strength and function.

Several treatment methods such as pins and plaster technique, closed reduction and percutaneous pinning, intrafocal pinning, closed reduction and external fixation, limited open reduction, and open reduction and internal fixation with or without Kirschner (K) wires are available.

Volar locked plate osteosynthesis is considered as the "gold standard" in treatment of unstable distal radius fractures^[2]. The main objective of treatment is to re-establish anatomic integrity and function.

Therefore, the present study is aimed to evaluate the functional outcome of open reduction and internal fixation with volar Ellis T buttress plate and screws and dorsal plate fixation with / without K-wire augmentation in the treatment of distal end radius fracture in adults.

Material and Methods

The present study was conducted on 20 adult patients with distal radial fractures in the Department of Orthopaedics, Prathima Institute of Medical Sciences, Karimnagar, India during October 2012 to September 2014, who attended the outpatient or the emergency service of Prathima Institute of Medical Sciences, Karimnagar, Telangana, India. The inclusion criteria were adult patients with distal radial fractures, patients who gave their consent to undergo the procedure, patients presented within 3 weeks after injury, patients with mature skeleton.

The exclusion criteria included elderly patients, patients with neurovascular deficiency, patients medically unfit for surgery, patients with pathological fractures. Ethical Committee approval was taken from the College Ethical Board.

Thorough clinical history was taken from the patients and / or attendants to reveal the mode of injury and the severity of trauma. All patients were examined thoroughly for their general condition, and associated injuries were noted. All the findings were duly recorded in the patient proforma.

The patients were subjected to clinical and radiographic examination. After obtaining written informed consent for surgery the patients were operated after a pre-anaesthetic checkup. Standard radiographs in PA and lateral views were taken for confirmation of the diagnosis and also to know the type of fracture. Oblique views were also taken in a few patients who had complex comminuted fractures. The fracture fragments were analysed and classified according to the Frykman's [3] classification.

The duration from the date of injury to date of operation ranged between 2-10 days. All the patients were subjected to open reduction and internal fixation (ORIF) with volar Ellis T buttress plates and screws (85% cases) for volar displaced fractures. In cases which had a displaced radial styloid or fragments too small for other means of fixation, plating was augmented with Kirschner wires (15% cases), inserted either percutaneously or through limited dorsal approach.

Reduction was obtained by cortical inter digitation of the metaphyseal portion of the fractures and observing the effect of the reduction with image intensification. The volar plate was applied and fixed with screws. Once stable fixation was achieved and hemostasis secured, the wound was closed in layers and sterile compression dressing was applied. The tourniquet was removed and capillary refilling was checked in the fingers. The operated limb was supported with below elbow POP slab keeping wrist in neutral position.

Post-operative care and rehabilitation

Post-operative pain and inflammation were managed using anti-inflammatory analgesics. Dressings were changed on the 5th post-operative day. Immediate post-operative check X-rays were taken in both PA and lateral views. The reduction of the fracture was confirmed and any displacements were noted. The operated limb was supported with a below elbow splint. Wound was inspected on the 5th post-operative day. On 10th post-operative day sutures were removed. The splints were discarded and replaced by an elasto-crepe bandage. The patients were advised to carry out routine activities and were discharged after the 10th post-operative day. They were reviewed weekly for the first 6 weeks. Patients were assessed subjectively for pain at the fracture site, clinically for tenderness and any signs of infection. Pronation and supination of the forearm and active movement of the elbow and shoulder were advised throughout the period of healing. After 6th week, physiotherapy was started, which included

flexion-extension along with underwater exercises. The range of wrist movements was recorded and any deformity was assessed.

Radiographic assessment

Check X-rays were taken at 6 weeks to assess consolidation or collapse at the fracture site and to note any displacement. Arthritic changes were graded according to the system described by Knirk and Jupiter [4].

Regular follow up was done from 5 to 24 months. The results were assessed 3 months after the procedures using the demerit point system of Gartland and Werley [5] based on objective and subjective criteria, residual deformity and complications.

The objective evaluation is based on the following ranges of motion as being the minimum for normal function: dorsiflexion 45°; palmar flexion 30°; radial deviation 15°; pronation 50° and supination 50°.

Statistical analysis

The data was analyzed using simple statistical analysis for percentage calculation. Microsoft office (Word and Excel) professional 2007 software has been used to generate tables.

Results

The present study of 20 cases of distal radial fractures treated at Prathima Institute of Medical Sciences, Karimnagar, Telangana between October 2012 to September 2014. All cases were followed up periodically during the period 2012 to 2014.

In this series, 1 (5%) patient was between 21 – 30 years, 7 (35%) patients between 31 - 40 years, 11 (55%) patients between 41 - 50 years, 1 (5%) patient between 51 - 60 years. The age of the patients ranged from 30 – 51 years.

Out of 20 patients, 17 (85%) patients were treated with open reduction and internal fixation with volar plating, 3 (15%) with plate and K-wire fixation. 16 (80%) patients were males and 4 (20%) females between the age group of 30-51 years showing male predominance with M : F in the ratio 4 : 1 (Table 1). Left side (dominant wrist) was involved in 12 (60%) patients and the right side involvement was in 8 (40%) cases (Table 1).

Table 1: Sex incidence and side involvement

	Sex		Side involvement	
	Male	Female	Right	Left
No. of cases	16	4	8	12
Percentage (%)	80	20	40	60

Of 20 cases, injury occurred due to road traffic accident in 11 (55%) patients and fall on the out stretched hand in 9 (45%) patients (Table 2). 3 (15%) patients had associated fractures which included tibia shaft in 2 (10%) patients and clavicle fracture in 1 (5%) patient (Table 2).

Table 2: Mode of injury and associated injuries

	Mode of injury		Associated injuries	
	RTA	FOOH	Tibia shaft Fractures	Clavicle fracture
No. of cases	11	9	2	1
Percentage (%)	55	45	10	5

RTA-Road traffic accident, FOOH-Fall on outstretched hand

Of 20 cases, 2 (10%) of the fractures were of Type-I, 4 (20%) fractures each of Type III and IV, 1 (5%) of Type V, 2 (10%) each of Type VI and VII and 5 (25%) of Type VIII. There

were no cases of Type II fracture. Surgery was done between 2-6 days in all 20 (100%) patients as an elective procedure. Out of 20 patients, 17 (85%) patients were treated with open

reduction and internal fixation (ORIF) with volar Ellis T buttress plate and screws (Fig. 1A-C), 3 (15%) patients with

open reduction and internal fixation with plate and K-wires (Table 3).

Table 3: Type of fixation

Type of fixation	No. of cases	Percentage (%)
Open Reduction and Internal Fixation with plating	17	85
Open Reduction and Internal Fixation with plate & K-Wires	3	15

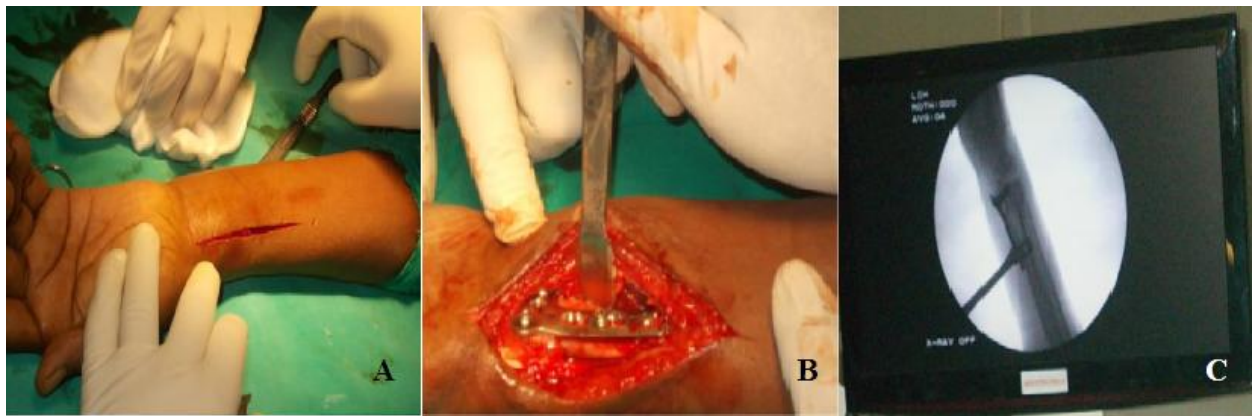


Fig 1: A- Skin incision, B- plate fixation with screws, C- C-arm picture after plate application

In this study, 13 (65%) patients had union within 2-3 months and 7 (35%) patients had union in 3-4 months. There were no cases of delayed union, mal-union or non-union. 3 (15%) patients had prominent ulnar styloid deformity. The

deformities are less common in patients treated with open reduction and internal fixation with volar plating compared to K-wire fixation and external fixation with or without percutaneous pinning.

Table 4: Range of motion

Movement (within normal functional range)	No. of cases	Percentage (%)
Dorsiflexion (min. 45°)	18	90
Palmar flexion (30°)	0	0
Pronation (50°)	18	90
Supination (50°)	14	70
Radial deviation(15°)	-	-
Ulnar deviation(15°)	-	-
Pain in distal radioulnar joint	-	-
Grip strength (60° or less than on opposite side)	1	5

In our study 18 (90%) patients had dorsiflexion within the normal functional range (minimum 45°), 0 (0%) had palmar flexion within the normal functional range (30°), 18 (90%) had pronation within the normal functional range (50°), 14 (70%) had supination within the normal functional range (50°), no patient had radial deviation within the normal functional range (15°), and all patients had ulnar deviation within the normal functional range (15°). 19 (95%) patients had grip strength more than 60% compared to the opposite side. 1 (5%) had significant loss of grip strength (>60% compared to the opposite side) (Table 4). No patient had pain in the distal radioulnar joint and stiffness of the wrist.

Out of 20 cases treated with open reduction and internal fixation with plate fixation, 1 (5%) patient had superficial wound infection. None of the patients had median nerve complications or arthritic changes as described by Knirk and Jupiter^[4]. There were no intra-operative complications.

Evaluation of functional results

The assessment of functional results were made using the demerit score system of Gartland and Werley^[5] based on objective and subjective criteria, residual deformity and complications. In this study, we achieved excellent results in 8 (40%) patients, good results in 11 (55%) patients and fair results in 1 (5%) patient. None of the patients had poor results

in terms of anatomical evaluation (Table 5).

Table 5: Evaluation of results

Results	Excellent	Good	Fair	Poor
No. of cases	8	11	1	-
Percentage (%)	40	55	5	-

Discussion

Distal radius fractures are extremely common injuries. It is remarkable that this common fracture remains one of the most challenging fractures to treat. The importance of anatomic reduction has been demonstrated by various clinical studies as well as laboratory assessment of the force and stress loading across the radiocarpal joint^[4, 6].

The operative method selected to achieve the treatment objectives requires a careful study of the individual fracture pattern, level of activity, quality of bone and general medical condition. Recognition of fracture patterns, screw fixation of fractures and maintenance of reduction is the key for successful management of more complex fractures of distal radius.

The present study was undertaken to assess the functional outcome of surgical management of distal radial fractures using open reduction and internal fixation with plate and screws with or without augmentation of K-wires. The

evaluated results were compared with those obtained by various other studies utilizing different modalities of treatment.

In the present study, distal radial fracture was more common in the 4th and 5th decade. In our series majority of the patients were males (80%) predominant over females (20%) as compared with the studies of John K. Bradway *et al.* [7], Louis Catalano III *et al.* [8], Kapoor *et al.* [9], Fusseti *et al.* [10], Kelesh and Ulrich [11] and Pattanashetty *et al.* [12]. This may probably be due to their involvement in outdoor activities and also heavy manual labour. Incidence of distal radius fracture in male may be more due to high energy injuries in female due to low energy injuries.

John K. Bradway *et al.* [7] had equal involvement of both wrists in their study. Louis Catalano III *et al.* [8] had increased involvement of the left wrist in their series similar to our study. But the series of Fusseti *et al.* [10] and Kapoor *et al.* [9], PattanaShetty *et al.* [12] had increased involvement of the right wrist contrary to the present study observations.

Mode of injury

In this study, mode of injury was road traffic accident in 11 (55%) patients and fall on the out stretched hand in 9 (45%) cases. Present study showed almost equal distribution of mode of injury. Kelesh and Ulrich [11] reported 45% injury due to fall on outstretched hand similar to our study. However, Kapoor *et al.* [9] and Pattanashetty *et al.* [12] reported road traffic accident as the most common mode of injury contrary to the present study.

Type of fracture

Based on Frykman's classification, the present study had 2 (10%) patients each of Type I, VI and VII fractures, 4 (20%) cases each of Type III, IV fractures, 5 (25%) of Type VIII and 1 (5%) of Type V.

The present study observations are comparable to Kapoor *et al.* [9] and Pattanashetty *et al.* [12] series as it was done in the same region and in a similar set up and had the same findings for age and sex incidence, involved wrist and mode of injury.

Type of fixation

In the present study, pre-operatively distal end of radius fracture treated with below elbow POP slab and elevation given till subsidence of edema then operative procedures were carried out. In the series of Louis Catalano III *et al.* [8] also had more cases (71%) treated with ORIF with buttress plate and screws and Pattanashetty *et al.* [12] in 100% cases. In this study 85% cases were treated with ORIF with volar plating and 15% cases plating with K-wires fixation. No patient had any residual deformity in the plating group. Excellent to good functional outcome results are more frequent with ORIF and plating technique [13] comparable to our anatomical results.

Kapoor *et al.* [9] in a randomised study on displaced intra-articular fractures of the distal radius concluded that ORIF provided the best anatomical restoration with patients least likely to develop arthritis. However, ORIF should be avoided in severe comminuted fractures as the fixation may not be stable and would likely result in poor functional outcome.

Our observations also emphasize that stabilizing the fracture fragments with a volar plate and screws is an effective method to maintain the reduction till union and therefore prevent collapse of the fracture fragments. This technique in the present study showed high percentage of excellent to good outcome results, minimum fair results with no poor results. Fitoussi *et al.* [10] in their study of 34 patients treated with

ORIF with buttress plate and screws concluded that the potential for restoration of normal alignment and stability of fixation are the main advantages of internal fixation with plates [14].

Complications

Present study encountered a complication rate of only 5% which was due to superficial wound infection. This patient was treated with appropriate antibiotics and regular sterile dressings. This study did not have any kind of complications. Kapoor *et al.* [9] reported 3.44% complication rate in 29 patients treated with open reduction with internal fixation in their series similar to the present study findings.

Functional outcome Results

The present series achieved 40% excellent results, 55% good, 5% fair and no poor result. Patients, who obtained excellent to good results had no residual deformities or pain. Range of motion was within the normal functional range and had no arthritic changes or other complications. Patient with fair result had slight pain in the distal radio-ulnar joint with minimum complications. Few of their movement were less than that required for normal function. The advantage of plating also includes decreased rate of complications compared to other treatment modality due to its strength and stability of construct that allows early wrist motion and enhances hand and finger movements. Our results are comparable to these findings.

Goutam Kumar and Dillip Kumar [15], Rizzo *et al.* [16], Ruch and Papadonikolakis [17], Simic *et al.* [18] studies reported that volar locked plating is a boon for unstable fractures because of its stiffer construct and lower rates of complications. In their studies distal end of radius fracture when treated with volar plate fixation has given significantly better outcome over other methods such as cast immobilization and K-wire fixation in terms of restoration of anatomy and function. This may be due to better stabilization of fracture fragments which allows early mobilization of joints.

Conclusion

We conclude that volar plating of distal radius fracture with or without K-wire fixation provides stable fixation of radius with excellent radiographic and functional results and minimal complications. This is a better option for surgical management of these fractures.

Distal radius fractures treated by plates and screws gives rigid fixation following which early mobilization of joints and hand can be done, thereby preventing stiffness.

References

1. Court-Brown CM, Cesar B. Epidermiology of adult fractures a review. *Injury*. 2006; 37:691-697.
2. Bacorn RW, Kurtzke JF. Colles' fracture; a study of two thousand cases from the New York State Workmen's Compensation Board. *J Bone Joint Surg Am*. 1953; 35-A:643-648.
3. Frykman Gosta. Fracture of the Distal Radius Including Sequelae -Shoulder -Hand-Finger Syndrome, Disturbance in the Distal Radio-Ulnar Joint and Impairment of Nerve Function. A Clinical and Experimental Study. *Acta Orthop. Scandinavica, Supplementum*. 1967, 108.
4. Knirk JL, Jupiter JB. Intra-articular fractures of the distal end of the radius in young adults. *J Bone Joint Surg Am*. 1986; 68(5):647-659.
5. Gartland JJ, Werley CW. Evaluation of healed Colles'

- fractures. *J Bone Joint Surg Am.* 1951; 33(4):895-907.
6. Leung F, Ozkan M, Chow SP. Conservative treatment of intra-articular fractures of the distal radius-factors affecting functional outcome. *Hand Surg.* 2000; 5(2):145-153.
 7. Bradway JK, Amadio PC, Cooney WP III. Open reduction and internal fixation of displaced, Comminuted intra-articular fractures of the distal end of the radius. *J Bone Joint Surg.* 1989; 71-A(6):839-847.
 8. Catalano LW III, Cole RJ, Gelberman RH, Evanoff BA, Gilula LA, Borrelli J Jr. Displaced intra-articular fractures of the distal aspect of the radius. *J Bone Joint Surg.* 1997; 79-A(9):1290-1302.
 9. Kapoor H, Agarwal A, Dhaon BK. Displaced intra-articular fractures of distal radius: a comparative evaluation of results following closed reduction, external fixation and open reduction and internal fixation. *Injury.* 2000; 31(2):75-79.
 10. Fusetti C, Meyer H, Borisch N. Complications of plate fixation in metacarpal fractures. *J Trauma.* 2002; 52(3):535-539.
 11. Kelesh G, Ulrich C. Intamedullary k-wire fixation of metacarpal fractures. *J Orthop Trauma.* 2004; 124:523-526.
 12. Pattanashetty OB, Shushrut Bhavi, Monish Bami, Deepesh Daultani, Yogesh Mapari. Outcome of fracture distal end of radius in adults treated by open reduction and internal fixation with buttress plate. *Kerala J Orthop.* 2013; 26(2):87-92.
 13. Vargaonkar G. Distal end radius fractures: evaluation of results of various treatments and assessment of treatment choice. *Chinese J Traumatology.* 2014; 17(4):214-219.
 14. Fitoussi F, Chow SP. Treatment of displaced Intra articular fractures of the distal end of Radius with Plates. *J Bone Joint Surg (A).* 1997; 79-A(9):1303-1311.
 15. Goutam Kumar S, Dillip Kumar C. Plate osteosynthesis for unstable distal radius fracture: A prospective, randomized study. *Internat J Orthop Sci.* 2017; 3(2):70-72.
 16. Rizzo M, Katt BA, Carothers JT. Comparison of locked volar plating versus pinning and external fixation in the treatment of unstable intraarticular distal radius fractures *Hand (NY).* 2008; 3:111-117.
 17. Ruch DS, Papadonikolakis A. Volar verses dorsal plating in the management of intraarticular distal radius fracture. *J Hand Surg Am.* 2006; 31:9-16.
 18. Simic PM, Robison J, Gardner MJ, Gelberman RH, Weiland AJ, Boyer MI. Treatment of distal radius fractures with a low-profile dorsal plating system: An outcome assessment. *J Hand Surg Am.* 2006; 31:382-386.