



International Journal of Orthopaedics Sciences

ISSN: 2395-1958
IJOS 2017; 3(2): 894-900
© 2017 IJOS
www.orthopaper.com
Received: 09-02-2017
Accepted: 10-03-2017

Dr. Nihar Anilkumar Patel
M.S. Ortho, B J Medical College
& Civil hospital Ahmedabad,
Gujarat, India

Arshaj Gaikwad
M.S. Ortho, B J Medical College
& Civil hospital Ahmedabad,
Gujarat, India

AV Gurava Reddy
DNB Ortho, Mch Ortho, FRCS,
B J Medical College & Civil
hospital Ahmedabad, Gujarat,
India

Ajit Jangale
M.S. Ortho, B J Medical College
& Civil hospital Ahmedabad,
Gujarat, India

Muralidhar Sagi
M.S. Ortho, B J Medical College
& Civil hospital Ahmedabad,
Gujarat, India

Correspondence

Dr. Nihar Anilkumar Patel
M.S. Ortho, B J Medical College
& Civil hospital Ahmedabad,
Gujarat, India

Histopathological and macroscopic evaluation of the ACL and its correlation to other variables in patients undergoing primary total knee arthroplasty: A prospective study of 50 cases

Dr. Nihar Anilkumar Patel, Arshaj Gaikwad, AV Gurava Reddy, Ajit Jangale and Muralidhar Sagi

DOI: <http://dx.doi.org/10.22271/ortho.2017.v3.i2j.99>

Abstract

More and more interest is evoked now a days regarding preservation of cruciate ligaments in total knee arthroplasty. This requires strong scientific evidence before undertaking such procedure. This study assessed gross and histopathological ACL changes in arthritic knees (n=50) undergoing total knee arthroplasty.

Method: Histopathological changes were assessed and graded as absent (0), mild (1), moderate (2), or marked (3). These were correlated to demographic and clinical factors and radiographic evaluations. **Result:** The ACL was intact in 6, frayed in 17, torn in 3 and linear striated in 24 knees. Hundred (100%) percent had histological changes. Overall, there were significant associations between greater age, higher BMI, female sex and histological changes. Increased age had significantly greater acellular zones and number of pathologic changes.

Conclusion: These correlations may aid decision-making when determining suitability for unicompartmental or bicruciate-retaining arthroplasties, though further studies should correlate these histological findings to mechanical and functional knee status.

Keywords: ACL, cruciate retaining, bicruciate-retaining arthroplasty, histology, TKA, anterior cruciate ligament

1. Introduction

It has been postulated that suboptimal functional performance following total knee arthroplasty may be due to the inability of certain prosthesis to reproduce the native knee kinematic complexity [1, 2]. Therefore, One might consider preserving as much of the native knee structures as possible. In particular, preservation of the anterior cruciate ligament (ACL) has been implicated in achieving close to normal kinematics and may play a key role in unicompartmental knee arthroplasty (UKA) and bicruciate-retaining knee arthroplasty [3, 4].

In UKA, the ACL preservation restores joint stability and soft-tissue balance and offers the potential to preserve close-to-normal kinematics. It has been suggested in laboratory studies that a deficient ACL may contribute to higher failure rates with sliding between the tibia and femur, resulting in increased polyethylene wear [5, 6]. In total knee arthroplasty (TKA), retaining both cruciate ligaments may provide better joint kinematics, improved motion and functional performance, stability, and enhanced proprioception [2, 7-12].

However, there has been much debate about the benefits of ACL retention in knee arthroplasty. There are concerns that this ligament in osteoarthritic knees may not be functional [9, 13]. Furthermore, although the ACL may appear normal macroscopically, this does not always correlate with histological integrity [14-16], and up to 97% may have histological changes [13-15, 17]. However, there is evidence that degeneration should not be a contraindication to ACL preservation, as long as the ligament remains functional [4]. Upon evaluation of the posterior cruciate ligament (PCL), degenerative patterns have been noted in osteoarthritis (OA), but retention is advocated for PCL sparing prostheses if the ligament retains its mechanical properties and neural elements [18].

Histologically, degenerative ligaments show varying degrees of chondroid metaplasia, myxoid degeneration, altered collagen fiber arrangement, and cystic changes [15, 19, 20]. These changes have been reported to correlate with demographic factors and with the extent of knee degeneration [15]. In the assessment of ligament functionality, identifying histological changes is becoming increasingly relevant with the expansion of UKA use and the introduction of bicruciate-retaining prosthesis. Specifically, it is important to evaluate these changes in patients who have intact ACLs, as these are the potential candidates for such surgeries. Therefore, the aims of the present study were to: 1) determine in the overall cohort: a) the number and types of gross (macroscopic) and histopathological ACL changes in arthritic knees undergoing TKA; b) assess effects of patient factors (age, body mass index, gender, and diabetes), clinical factors (range-of-motion), and radiographic findings (Kellgren–Lawrence grade [21]) on ACL histological changes; and 2) evaluate the above factors in patients who had intact ACL specimens. It was hypothesized that certain factors might serve as better predictors of ACL integrity for surgeons treating patients with these devices.

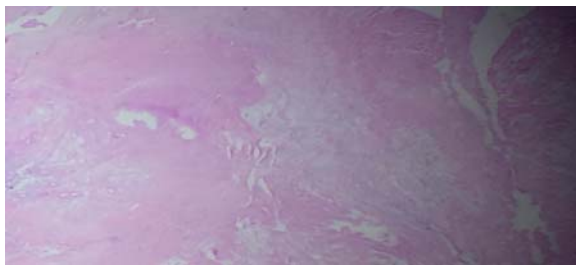


Fig 1: Specimens stained with hematoxylin and eosin denote myxoid changes. Note background pale staining with increased fibroblast nuclei. Image denotes high cellularity, more cellular than would be expected in a normal ligament, and nuclei have a very rounded morphology.

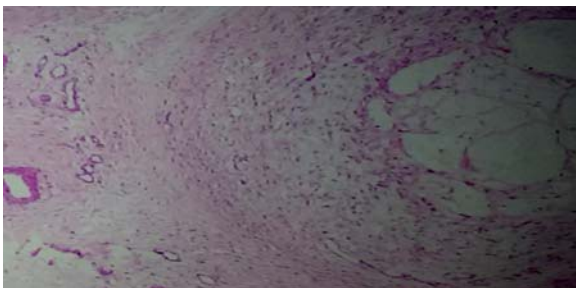


Fig 2: Specimens stained with hematoxylin and eosin denote cystic myxoid changes.

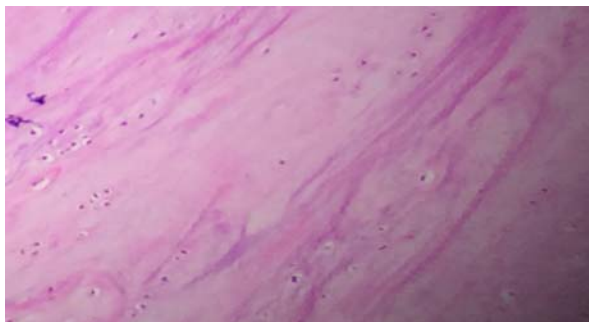


Fig 3: ACL specimens with Hematoxylin and Eosin staining. Note disorientation of collagen fibers. Area of chondroid metaplasia.

2. Materials & methods

From August 2016 to October 2016, 50 patients who underwent a primary TKA in Sunshine Hospital, Hyderabad were identified by me during my arthroplasty fellowship. Patients were included if they had primary osteoarthritis, as diagnosed clinically and radiographic ally. Those who had a diagnosis of osteonecrosis, rheumatoid arthritis, post traumatic arthritis, past history of knee surgery, absent ACL intraoperatively were excluded. There were 32 women and 18 men who had a mean age of 63 years (range 52 to 80 years) and a mean body mass index (BMI) of 31 kg/m² (range 21 to 40). The ACL was evaluated intra-operatively at primary TKA macroscopically and was classified as: 1) intact; 2) linear striations; 3) frayed; or 4) torn [22]. The specimens were sent for histopathological analysis (50 specimens).

Specimens were processed in their entirety, with transverse and longitudinal slices obtained at both the proximal one-third and ligament center. For histopathologic evaluation, samples were fixed in formalin, dehydrated, and paraffin-embedded. The 4 micrometer sections were cut and stained with Hematoxylin and Eosin. The following were evaluated: 1) myxoid change (material rich in proteoglycan, hydrophilic in nature with abundant water content); 2) cystic myxoid or microcyst formation (matrix pools without synovial lining, similar to myxoid change but more advanced); 3) chondroid metaplasia (rounded cells lying within lacunae containing proteoglycan, similar to cartilage); 4) acellular zones (loss of fibroblast nuclei); 5) vascular proliferation (increased capillaries); 6) fibroblast proliferation (increased fibroblast nuclei); 7) calcium pyrophosphate deposits; and 8) presence of gout. Using a modification of previous grading systems [15,23,24] each finding was graded as absent (0 points), mild (1 point), moderate (2 points), or marked (3 points) and was scored based on the extent of histological degenerative changes. A total histological degeneration score was generated by summing each individual microscopic change score, with minimum score of 0 and a maximum of 24 [24]. The samples were analyzed and scored by a histopathologist, who was blinded to any patient clinical or radiographic factors.

Demographic factors assessed were age, BMI, gender, a medical diagnosis of diabetes mellitus, and pre-operative range-of-motion. Association of these factors with ACL macroscopic and histological findings was performed. Radiographic Osteoarthritis grade was determined on anteroposterior and lateral radiographs using the Kellgren and Lawrence system [21], which consists of five grades: 0) no x-ray changes; 1) doubtful joint space narrowing; 2) minimal narrowing and osteophytes; 3) moderate narrowing with multiple osteophytes; and 4) severe narrowing. All patients had grade III (n = 16) or IV (n = 34) osteoarthritis.

Each factor was correlated with macroscopic and histological findings. The sum of histological changes for each patient was determined and a total degeneration score was calculated. Using multivariate regression analysis, the association between secondary endpoints and total degeneration scores was determined. Means and standard deviations of values were calculated, and SPSS version 16.0, Microsoft excel 2007 was used for statistical analysis. Assuming a Gaussian distribution, the significance of associations between the factors and ACL changes was evaluated using one-way analysis of variance (ANOVA) for continuous variables (such as patient BMI), Kruskal–Wallis tests for ordinal variables (such as extent of histological change), and Fisher's exact test for dichotomous categorical values (such as patient gender).

Correlation statistics were performed using Pearson's (p) correlation coefficient. Guiding values are as mentioned, Suggestive significance (P value: 0.05<P<0.10), moderately significant (P value: 0.01<P≤0.05) strongly significant (P value: P<0.01)

3. Results

Total 50 knees evaluated. Macroscopically, the ACL was intact in 6 knees (12%), linear striations in 24 knees (48%), frayed in 17 (34%), and torn in 3 (6%) (Fig 9). Histopathological changes were detected in all samples (50/50). None of the specimens had significant inflammation

and no necrotic cells were observed. The most common histological change was chondroid metaplasia (96%, 48 specimens), with 16, 25, and 7 specimens demonstrating grades 1, 2, and 3 changes (mild, moderate, and marked changes), respectively [15, 23, 24]. This was followed by myxoid (84%, 42 specimens), 4), vascular proliferation (64%, 32 specimens), and cystic myxoid changes (34%, 17 specimens) (Figs. 1–5, Table 1). The total histological grading score [24] ranged from 1 to 7. In each of the intact, linear striations, frayed, and torn groups, the most common change was chondroid metaplasia (see Table 2 for changes stratified per group).

Table 1: Summary of Histological Changes in relation to Histological Grades of Change.

| Grade of change | Type of change | | | | | | | | | | | | | | | |
|-----------------|----------------|----|---------|----|----------|----|--------|----|---------|----|--------|-----|---------|---|--------|---|
| | M (42) | | CM (17) | | CHM (48) | | AZ (6) | | VP (32) | | FB (4) | | CPP (0) | | GT (0) | |
| | N | % | N | % | n | % | N | % | N | % | N | % | N | % | N | % |
| 1. mild | 30 | 71 | 15 | 88 | 16 | 33 | 5 | 83 | 26 | 81 | 4 | 100 | 0 | 0 | 0 | 0 |
| 2.moderate | 12 | 28 | 2 | 11 | 25 | 52 | 1 | 16 | 5 | 15 | 0 | 0 | 0 | 0 | 0 | 0 |
| 3. marked | 0 | 0 | 0 | 0 | 7 | 14 | 0 | 0 | 1 | 3 | 0 | 0 | 0 | 0 | 0 | 0 |

N = number of specimens with histological changes. 0 = not found.

M-myxoid, CM- cystic myxoid, CHM- chondroid metaplasia, AZ- acellular zones, VP – vascular proliferation, CPP- calcium pyrophosphate, GT- gout

Table 2: Assessment of Histological Changes per Macroscopic Group

| Macroscopic group (n) | Histological Change, n (%) | | | | | | | |
|------------------------|----------------------------|---------|----------|---------|---------|---------|--------|--------|
| | M | CM | CHM | AZ | VP | FB | CPP | GT |
| Normal (6) | 2 (33%) | 2 (33%) | 6 (100%) | 0 (0%) | 4 (66%) | 0 (0%) | 0 (0%) | 0 (0%) |
| Linear striations (24) | 19 (79%) | 9 (37%) | 23 (95%) | 4 (16%) | 16 (%) | 2 (8%) | 0 (0%) | 0 (0%) |
| Frayed (17) | 14 (82%) | 6 (35%) | 16 (94%) | 1 (5%) | 10 (%) | 1 (5%) | 0 (0%) | 0 (0%) |
| Torn (3) | 3 (100%) | 0 (0%) | 3 (100%) | 1 (33%) | 2 (%) | 1 (33%) | 0 (0%) | 0 (0%) |

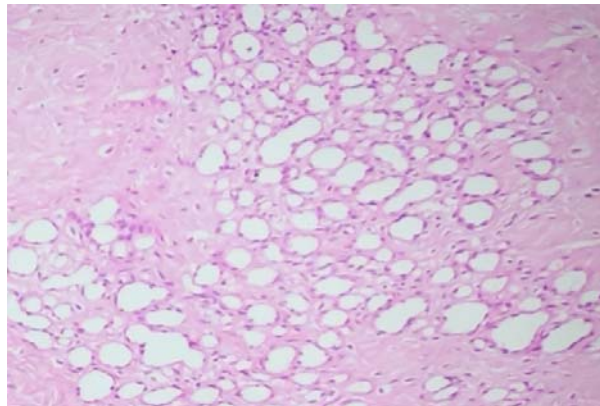


Fig 4: Specimens stained with hematoxylin and eosin denote vascular proliferation

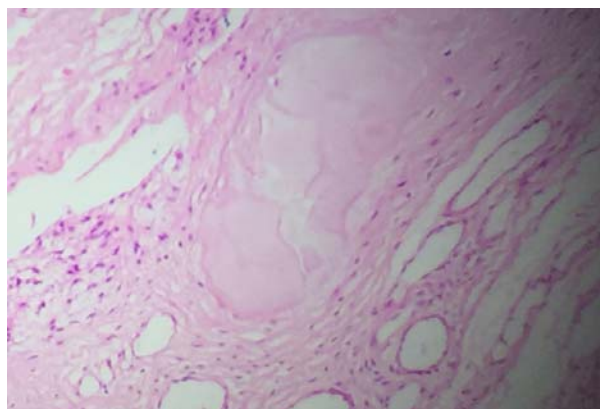


Fig 5: Specimens stained with hematoxylin and eosin denote acellular zones

Overall, when assessing demographic factors, with increasing age acellular zones, myxoid and vascular proliferation changes are increasing(fig 6) only acellular zones among them is reaching significance (p=0.029) older age was significantly associated with more number of changes(p=0.002) increasing age has no effect on other changes. (p>0.05). No change in macroscopic appearance is noted between age groups (p=1.0)

Higher BMI is more associated with myxoid, cystic myxoid and chondroid metaplasia (fig 7). Only cystic myxoid among these is significant (p=0.005) increasing BMI is not associated with significant difference in number of changes (p=0.4). No change in macroscopic appearance is noted between the groups (p=0.6) specimens from male patients had a high prevalence of acellular zones (0.3) and female has cystic myxoid (0.02) and chondroid metaplasia (0.0072) reaching significance.

Grade 3 OA is associated with more myxoid and chondroid metaplasia not reaching significance (p=0.4) grade 4 OA is associated with more cystic myxoid, acellular zones, vascular proliferation and fibrous changes but also not reaching significance (p=0.5). No significant difference is observed in macroscopic changes and OA grade (p=0.2) Preop ROM & diabetes did not significantly affect histological findings, number of changes and macroscopic appearance (p=0.6). When evaluating total degeneration score (TDS), BMI only reaches the significance (p=0.003) (fig 8). For gender (0.157), for age (0.9), diabetes (0.39), KL grade (0.33), preop ROM (0.5).

3.1 Intact ACLs

There were no significant associations between histological changes and age, BMI, gender, diabetes diagnosis, Kellgren–Lawrence grade, and range-of-motion in this group. (p=>0.1)

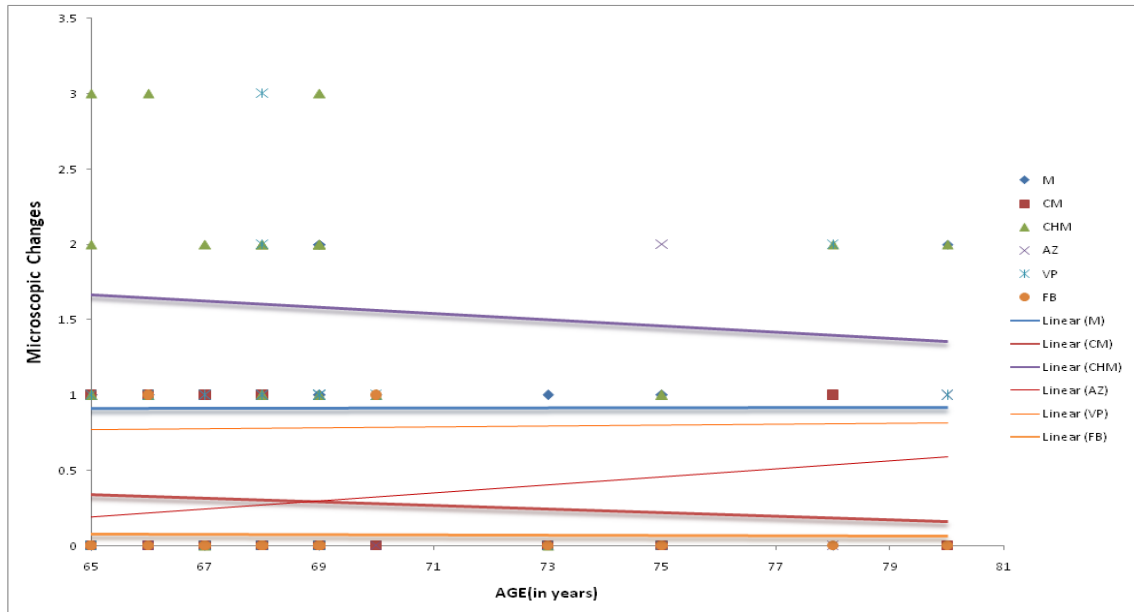


Fig 6: correlation between age and microscopic

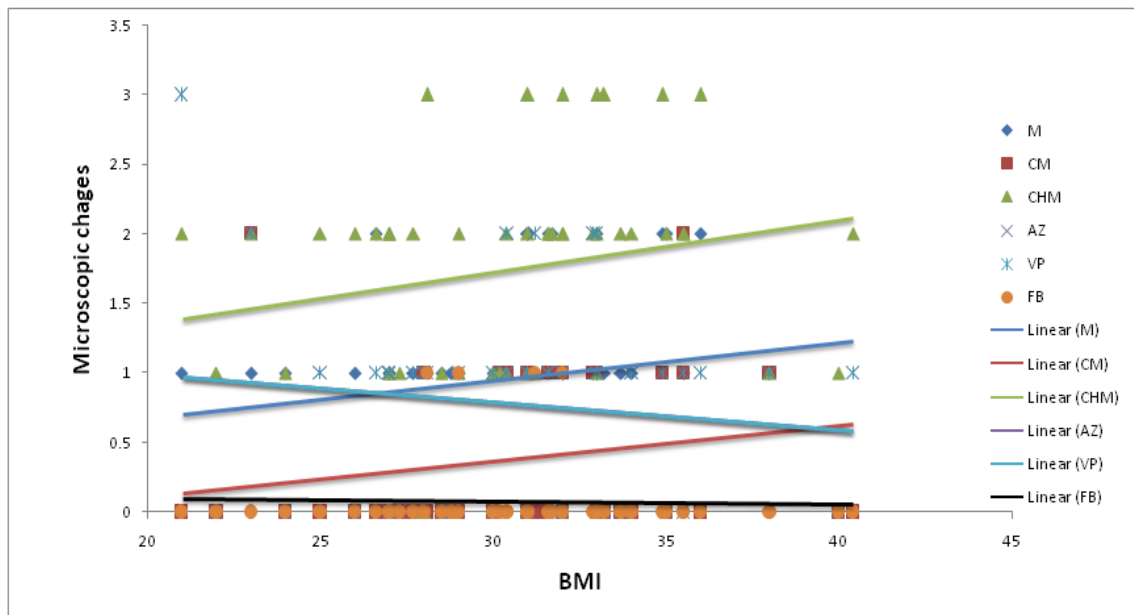


Fig 7: correlation between BMI and microscopic changes

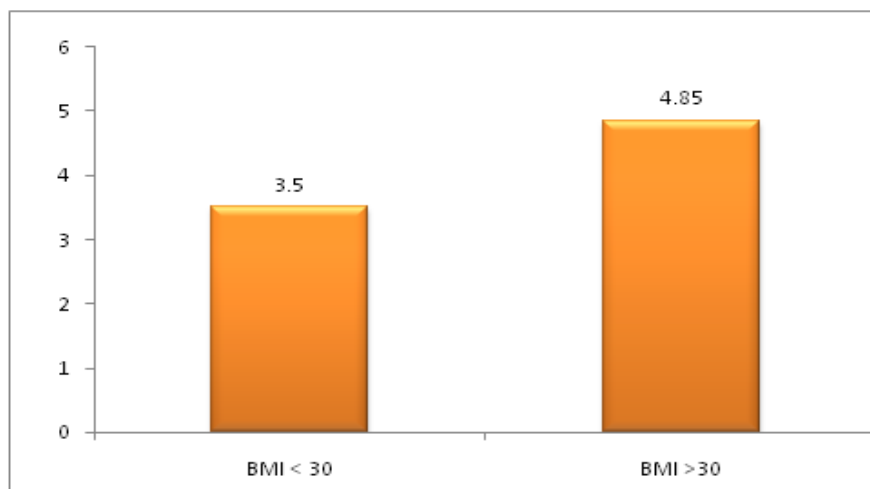


Fig 8: correlation between TDS and BMI

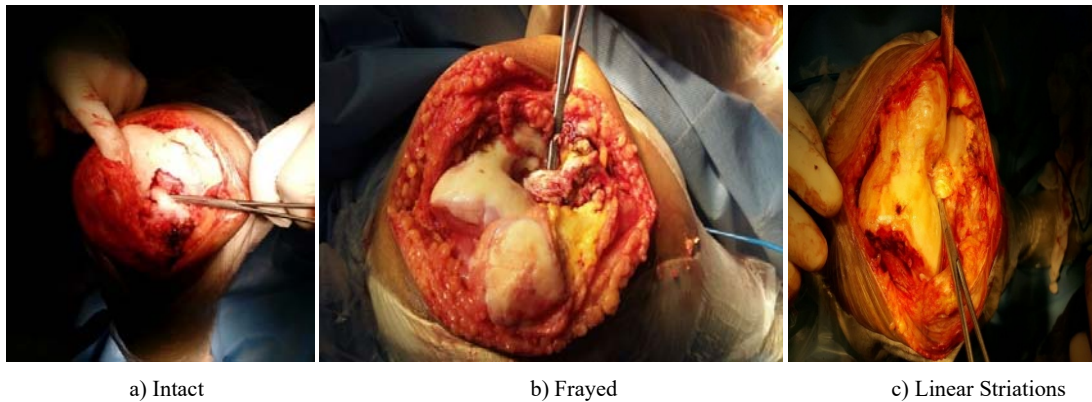


Fig 9: Macroscopic Appearance of ACL

4. Discussion

Anterior cruciate ligament retaining TKAs have been postulated to Demonstrate more normal kinematics and gait than conventional cruciate-retaining or substituting TKAs [13-16, 25]. However, various studies have shown that even when the ACL appears normal macroscopically, histological examination shows changes, as demonstrated in our study [13-15, 25]. Chondroid metaplasia change was the most common microscopic finding in ACL ligaments of these osteoarthritic patients, regardless of macroscopic appearance.

There were several study limitations. Inter-observer or intraobserver reliabilities were not specifically evaluated, however since the same experienced pathologist analyzed histological samples, the results observed were considered to be reliable. Although histological findings of the ACL were not correlated with mechanical properties, the study results reliably suggest that patients who are older and have late-stage osteoarthritis have more histological changes. Further biomechanical studies are now ongoing to assess the ACL mechanically intra operatively. In addition, future studies to aid decision-making might include a control cohort for comparison study. Although it may be difficult to justify obtaining specimens from healthy individuals, ACLs at autopsy from patients without OA may be of value to evaluate whether similar or other histological changes are also noted in elderly patients without OA, or if they are only implicated in osteoarthritis pathology. Furthermore, incorporating patients with high BMI, but no arthritis, may provide a useful comparison to assess if the cystic myxoid changes are pathognomonic to arthritis or simply increased body mass. Also, it may be valuable to assess the effect of symptom duration on secondary changes of the ACL, as one would anticipate that patients with a longer clinical history would be more likely to have changes of the ACL. It has also been hypothesized that women are more likely to have ACL tears than men, and our cohort had a significantly larger number of women, which may have affected the number of torn ligaments seen on macroscopic assessment. Stratifications by gender were performed for the histological changes, and further studies should perform similar gender stratifications for macroscopic ACL evaluation. Furthermore, future studies can incorporate the effect of varus or valgus changes and the degree of deformity, as well as different combinations of bicompartamental involvement, on ACL changes.

Several studies (table 3) have demonstrated histological disease in macroscopically intact ligaments. Trompeter *et al* [13] analyzed 55 consecutive ACLs at the time of TKA, with 31 macroscopically intact. However, upon histological analysis, 71% (22 ACLs) showed moderate-to-severe

histological disease. With increasing histological grade, they noted that the disruption of the parallel collagen fibers became more pronounced, with increased cellularity and fibroblast nuclei. There were also more prominent secondary degenerative changes, such as calcifications, cyst formation, and myxoid changes. Therefore, they concluded that a gross macroscopic evaluation may not be sufficient for assessing the functionality of the ACL, as a normal appearing ligament does not necessarily indicate histological integrity. In the present study, chondroid metaplasia was the most common histological change found but study by Michael *et al.* [36], shows mucoïd degeneration to be most common change. Tissue injury has been postulated to be the most likely etiological factor for the development of this degeneration [26], though loss of synovial lining has also been implicated [27]. Furthermore, this degeneration has been shown to lead to enlargement of the ACL, which can potentially cause pain due to mechanical impingement, and thus is a necessary aspect to consider in ACL-retaining arthroplasty cases [28-32]. However, Bergin *et al* [33] noted that ACL mucoïd change that was associated with ligament ganglia may be a distinct clinical entity and was not typically associated with ligament instability. Therefore, differentiation between mucoïd, change and degeneration is necessary, but this has not been extensively studied and needs further analysis [34, 35].

Moreover, this study demonstrated that ACL specimens in older patients had significantly more types of histological changes when compared to specimens from younger patients. There was a positive correlation between the mucoïd, acellular zones, vascular proliferative changes and increased age. Levy *et al* [15] correlated histological changes in the ACL and PCL to age and also found that more ligament degeneration was present in the higher age groups. The highest number of changes was reported in the 80 to 89 year age group (ACL 6.1 ± 3.7 ; PCL 5 ± 3.7). Similarly, Hasegawa *et al* [20] evaluated 120 human knee joints from 30 male and 35 female donors, who had a mean age of 66 years (range, 23 to 92) and found that ACL degeneration was present even in the absence of cartilage degeneration. However, they noted that there was no significant correlation between donor age and extent of mucoïd degeneration ($P = 0.18$), though results from cadaveric non-arthritis donors may be quite different from those obtained from degenerative knees at arthroplasty. Even in the absence of cartilaginous and macroscopic changes, the ACL has been shown to have histological degeneration with higher age groups, which may suggest an age cutoff for the consideration of these implants. However, this deserves further study.

Table 3: Summary of Studies Assessing Histological Changes of the ACL.

| Study | Year | Specimens (No.) | Mean Age (years) | % Showing Histological Change | Comments |
|--|------|-----------------|------------------|---|--------------------|
| Allain <i>et al</i> ^[14] | 2001 | 52 | 76 | 27 | OA knees at TKA |
| Cushner <i>et al</i> ^[20] | 2003 | 19 | 63 | 74 | OA knees at TKA |
| Mullaji <i>et al</i> ^[17] | 2008 | 45 | 64 | 82 in high-grade OA; 14 in low-grade OA | OA knees at TKA |
| Trompeter <i>et al</i> ^[13] | 2009 | 55 | 74 | 71 | OA knees at TKA |
| Hasegawa <i>et al</i> ^[21] | 2012 | 120 | 66 | 96 | Donor non-OA knees |
| Levy <i>et al</i> ^[15] | 2013 | 120 | 67 | 97 | Donor non-OA knees |
| Michael <i>et al</i> ^[36] | 2016 | 143 | 59 | 85 | OA knees at TKA |

Similarly, the association between age and ligament histology has been reported in the analysis of the PCL. In Levy *et al*'s ^[15] study, they noted that 94% of the PCL specimens had histological changes, with fiber disorientation being the most prevalent and severe. There was a correlation between aging and total histological PCL scores ($r=0.26$), which was weaker than the correlation noted with the ACL scores ($r=0.42$). Rajgopal *et al* ^[18] evaluated 100 specimens taken from patients who underwent PCL-retaining TKA, without compromising the integrity of the ligament. They noted that 15 specimens showed severe degeneration, of which 13 were from patients over 75 years. This correlates with the present study findings that older age is associated with greater degenerative changes. In addition, they observed that at 2 year TKA follow-up, patients had improvements in Knee Society Scores with no signs of instability or radiological loosening, and they concluded that despite histological abnormalities, retention of the PCL is a viable option to maintain good kinematics and stability. This also might have implications when performing ACL-retaining procedures.

When evaluating BMI, it was found that although higher BMI was associated with more cystic myxoid changes on histology, there was no significant association with the number of histological changes. This is in agreement with Levy *et al* ^[15], who showed that the histopathological assessment of the ACL did not differ significantly by BMI stratification. This study has demonstrated that patients who had a higher radiographic osteoarthritis grade ended towards a greater number of histological changes but total degeneration scores are not significantly varying. Various studies support these findings and demonstrated more extensive histological changes in the ACL with high-grade osteoarthritis when compared to low-grade osteoarthritis ^[13, 15, 17, 19, 20]. Mullaji *et al* ^[17] evaluated 45 ACLs in 43 patients undergoing TKA and found that severe degeneration of the ACL was more common in high-grade arthritis (82%) when compared to low-grade arthritis (14%; $P < 0.0001$). These findings are of particular importance to surgeons when considering bicruciate-retaining arthroplasty in the osteoarthritic knee and may also impact on the decision to perform a unicompartmental arthroplasty ^[17]. In addition, a cadaver study by Levy *et al* ^[15] evaluated the ACL in patients who did and did not have osteoarthritis (Kellgren–Lawrence grades 0 to 4), and they noted that inflammation, mucoid, cystic, and chondroid changes all significantly correlated with increasing OA grade ($P < 0.05$), and specimens with no arthritis had the lowest severity of changes. To evaluate if changes were secondary to age alone or osteoarthritis, the authors further assessed knees from cadavers over 60 years of age. They noted that 12% of ACLs in knees without OA had severe histological changes, compared to 28% in knees with OA. Therefore, we can postulate that ACL findings in patients who have OA differ significantly from those in patients who do not have the disease.

Johnson *et al* ^[22] conducted a study to evaluate the correlation between pre-operative clinical and MRI assessment of ACL integrity and intra-operative observation. They noted that Lachman's test alone had poor sensitivity for diagnosing ACL deficiency (33%). It was also observed that 14 percent of ACLs with indeterminate status on MRI were disrupted intra-operatively, and therefore, MRI alone may not be particularly beneficial or superior to clinical assessment. However, when the two tests were combined, the sensitivity and specificity were calculated to be 93% and 99%, respectively. Future studies correlating clinical evaluation, functionality, radiographic, and MRI changes to ACL integrity, in addition to the factor analysis done in the present study, might be helpful in providing surgeons with tangible and easily obtainable pre-operative information on which to make decisions.

This study has demonstrated several findings. Despite macroscopic appearance, most ACL samples were histologically abnormal, with chondroid metalasia being the most prevalent finding. It was also observed that increasing age, higher BMI, and female gender osteoarthritis significantly correlated with histopathological changes, which supports the initial hypothesis that certain factors may aid in predicting histopathology. However, no significant correlations were found when evaluating changes in the intact ACL specimens.

5. Conclusion

Histological ACL degeneration is commonly present at the time of TKA, even in visibly intact ligaments. If these changes are found to compromise ACL integrity, then the use of ACL-retaining implants may not actually confer appropriate knee kinematics and gait. Based on these results, certain patient groups with combinations of older age, higher BMI, and female gender may have greater histological ACL changes, although no associations were found in those with intact ACLs. The correlations generated might permit the use of a statistical approach in the decision as to remove or preserve an ACL. Based on the findings in this study, younger patients who have less severe OA may have a lower risk for ACL degeneration and thus may be better candidates for ACL-sparing arthroplasty. In addition, caution should be used in older patients who have higher BMIs and female gender when considering bicruciate-retaining and unicompartmental arthroplasties. However, correlations to imaging and mechanical studies are needed to further validate these findings and choice of implant.

6. References

- Nowakowski AM, Stangel M, Grupp TM *et al*. Investigating the primary stability of the transversal support tibial plateau concept to retain both cruciate ligaments during total knee arthroplasty. *J Appl Biomater Funct Mater*. 2012; 10(2):127.

2. Stiehl JB, Komistek RD, Cloutier JM *et al.* The cruciate ligaments in total knee arthroplasty: a kinematic analysis of 2 total knee arthroplasties. *J Arthroplasty.* 2000; 15(5):545.
3. Pritchett JW. Bicruciate-retaining total knee replacement provides satisfactory function and implant survivorship at 23 years. *Clin Orthop Relat Res.* 2015; 473:2327.
4. Sabouret P, Lavoie F, Cloutier JM. Total knee replacement with retention of both cruciate ligaments: a 22-year follow-up study. *Bone Joint J.* 2013; 95-B(7):917.
5. Engh GA, Ammeen D. Is an intact anterior cruciate ligament needed in order to have a well-functioning unicompartmental knee replacement? *Clin Orthop Relat Res.* 2004; (428):170.
6. Suggs JF, Li G, Park SE *et al.* Function of the anterior cruciate ligament after unicompartmental knee arthroplasty: an *in vitro* robotic study. *J Arthroplast.* 2004; 19(2):224.
7. Nakamae A, Ochi M, Deie M *et al.* Biomechanical function of anterior cruciate ligament remnants: how long do they contribute to knee stability after injury in patients with complete tears? *Arthroscopy.* 2010; 26(12):1577.
8. Bach Jr BR, Warren RF, Wickiewicz TL. The pivot shift phenomenon: results and description of a modified clinical test for anterior cruciate ligament insufficiency. *Am J Sports Med.* 1988; 16(6):571.
9. Butler DL, Noyes FR, Grood ES. Ligamentous restraints to anterior-posterior drawer in the human knee. A biomechanical study. *J Bone Joint Surg Am.* 1980; 62(2):259.
10. Hughston JC, Andrews JR, Cross MJ *et al.* Classification of knee ligament instabilities. Part I. The medial compartment and cruciate ligaments. *J Bone Joint Surg Am.* 1976; 58(2):159.
11. Andriacchi TP, Galante JO, Fermier RW. The influence of total knee-replacement design on walking and stair-climbing. *J Bone Joint Surg Am.* 1982; 64(9):1328.
12. Kuroyanagi Y, Mu S, Hamai S *et al.* *In vivo* knee kinematics during stair and deep flexion activities in patients with bicruciate substituting total knee arthroplasty. *J Arthroplast.* 2012; 27(1):122.
13. Trompeter AJ, Gill K, Appleton MA *et al.* Predicting anterior cruciate ligament integrity in patients with osteoarthritis. *Knee Surg Sports Traumatol Arthrosc.* 2009; 17(6): 595.
14. Allain J, Goutallier D, Voisin MC. Macroscopic and histological assessments of the cruciate ligaments in arthrosis of the knee. *Acta Orthop Scand.* 2001; 72(3):266.
15. Levy YD, Hasegawa A, Patil S *et al.* Histopathological changes in the human posterior cruciate ligament during aging and osteoarthritis: correlations with anterior cruciate ligament and cartilage changes. *Ann Rheum Dis.* 2013; 72(2):271.
16. Noyes FR, DeLucas JL, Torvik PJ. Biomechanics of anterior cruciate ligament failure: an analysis of strain-rate sensitivity and mechanisms of failure in primates. *J Bone Joint Surg Am.* 1974; 56(2):236.
17. Mullaji AB, Marawar SV, Simha M *et al.* Cruciate ligaments in arthritic knees: a histologic study with radiologic correlation. *J Arthroplast.* 2008; 23(4):567.
18. Rajgopal A, Vasdev N, Pathak A *et al.* Histological changes and neural elements in the posterior cruciate ligament in osteoarthritic knees. *J Orthop Surg (Hong Kong).* 2014; 22(2):142.
19. Cushner FD, La Rosa DF, Vigorita VJ *et al.* A quantitative histologic comparison: ACL degeneration in the osteoarthritic knee. *J Arthroplast.* 2003; 18(6):687.
20. Hasegawa A, Otsuki S, Pauli C *et al.* Anterior cruciate ligament changes in the human knee joint in aging and osteoarthritis. *Arthritis Rheum.* 2012; 64(3):696.
21. Kellgren JH, Lawrence JS. Radiological assessment of osteo-arthrosis. *Ann Rheum Dis.* 1957; 16(4):494.
22. Johnson AJ, Howell SM, Costa CR *et al.* The ACL in the arthritic knee: how often is it present and can preoperative tests predict its presence? *Clin Orthop Relat Res.* 2013; 471(1):181.
23. Stubbs G, Dahlstrom J, Papantoniou P *et al.* Correlation between macroscopic changes of arthrosis and the posterior cruciate ligament histology in the osteoarthritic knee. *ANZ J Surg.* 2005; 75(12):1036.
24. Hasegawa A, Nakahara H, Kinoshita M *et al.* Cellular and extracellular matrix changes in anterior cruciate ligaments during human knee aging and osteoarthritis. *Arthritis Res Ther.* 2013; 15(1):R29.
25. Nelissen RG, Hogendoorn PC. Retain or sacrifice the posterior cruciate ligament in total knee arthroplasty? A histopathological study of the cruciate ligament in osteoarthritic and rheumatoid disease. *J Clin Pathol.* 2001; 54(5):381.
26. Kumar A, Bickerstaff DR, Grimwood JS *et al.* Mucoïd cystic degeneration of the cruciate ligament. *J Bone Joint Surg Br.* 1999; 81(2):304.
27. Chudasama CH, Chudasama VC, Prabhakar MM. Arthroscopic management of mucoïd degeneration of anterior cruciate ligament. *Indian J Orthop.* 2012; 46(5):561.
28. Cho SD, Youm YS, Lee CC *et al.* Mucoïd degeneration of both ACL and PCL. *Clin Orthop Surg.* 2012; 4(2):167.
29. Fealy S, Kenter K, Dines JS *et al.* Mucoïd degeneration of the anterior cruciate ligament. *Arthroscopy.* 2001; 17(9):E37.
30. Motmans R, Verheyden F. Mucoïd degeneration of the anterior cruciate ligament. *Knee Surg Sports Traumatol Arthrosc.* 2009; 17(7):737.
31. Narvekar A, Gajjar S. Mucoïd degeneration of the anterior cruciate ligament. *Arthroscopy.* 2004; 20(2):141.
32. Melloni P, Valls R, Yuguero M *et al.* Mucoïd degeneration of the anterior cruciate ligament with erosion of the lateral femoral condyle. *Skelet Radiol.* 2004; 33(6):359.
33. Bergin D, Morrison WB, Carrino JA *et al.* Anterior cruciate ligament ganglia and mucoïd degeneration: coexistence and clinical correlation. *AJR Am J Roentgenol.* 2004; 182(5):1283.
34. Pandey V, Suman C, Sharma S *et al.* Mucoïd degeneration of the anterior cruciate ligament: management and outcome. *Indian J Orthop.* 2014; 48(2):197.
35. Hovis KK, Alizai H, Tham SC *et al.* Non-traumatic anterior cruciate ligament abnormalities and their relationship to osteoarthritis using morphological grading and cartilage T2 relaxation times: data from the Osteoarthritis Initiative (OAI). *Skelet Radiol.* 2012; 41(11):1435.
36. Michael Mont A, Randa Elmallah KMD, Jeffrey Cherian JMD, Samik Banerjee DO, Bhavleen Kapadia HMD, MD. Histopathological Evaluation of the Anterior Cruciate Ligament in Patients Undergoing Primary Total Knee Arthroplasty. *The Journal of Arthroplasty.* 2016; 31:284-289.