

ISSN: 2395-1958
IJOS 2017; 3(2): 714-719
© 2017 IJOS
www.orthopaper.com
Received: 13-02-2017
Accepted: 14-03-2017

Ashok Singhvi
Dr S.N Medical College Jodhpur,
Rajasthan, India

Hemant Jain
Dr S.N Medical College Jodhpur,
Rajasthan, India

Siddharth Jauhar
Dr S.N Medical College Jodhpur,
Rajasthan, India

Kishore Raichandani
Dr S.N Medical College Jodhpur,
Rajasthan, India

Segmental tibial fractures treated with unreamed interlocking nail – A prospective study

Ashok Singhvi, Hemant Jain, Siddharth Jauhar, Kishore Raichandani

DOI: <http://dx.doi.org/10.22271/ortho.2017.v3.i2h.73>

Abstract

Introduction: Fractures of tibia are common and major skeletal injuries. Treatment of such fractures in adults is a challenge to orthopaedic surgeons due to its poor soft tissue coverage and poor blood supply. The aim towards treatment for the segmental fracture tibia is union maintaining normal length, normal alignment without rotational deformity, normal joint movements and reduced hospital stay.

Method: In our department since 2012 to 2014, 51 segmental tibia fractures were treated with unreamed interlocking intramedullary nailing technique with one proximal and one distal locking screws. Postoperatively, early mobilization exercises and weight-bearing were begun. The functional results were assessed by measuring union period and knee range of movements at 6 months.

Results: Fracture healing was obtained in 49(96%) cases within the expected time period. 2(3.9%) patients had non union between proximal and middle segment. 46 (90%) were anatomic (valgus/varus<5°). 5(9.8%) patients had malunion with valgus more than 5°. Average range of movement observed at 4 months was 125° (70°-140°). Superficial infections were noted in 2 patients with compound fracture effectively treated with antibiotics.

Discussion and Conclusion: We conclude that unreamed interlocking nail fixation in segmental tibial fractures seems to be less time consuming, preserves blood supply, relatively simple and good method of treatment with good functional outcome and patient satisfaction provided proper selection of fracture is done.

Keywords: Segmental tibial fractures, interlocking nail, poor blood supply, major skeletal injuries

Introduction

Fractures of tibia are common and major skeletal injuries mostly associated with high velocity trauma and often accompanied by substantial damage of the surrounding soft tissue. Treatment of such fractures in adults is a challenge to orthopaedic surgeons due to its poor soft tissue coverage and poor blood supply. The aim towards treatment for the segmental fracture tibia is union maintaining normal length, normal alignment without rotational deformity, normal joint movements and reduced hospital stay. The present study has been taken to review the results of segmental fractures of tibia treated with unreamed intramedullary interlocking nailing.

Material and Methods

This study was conducted between June 2012 to May 2014 in the Department of Orthopaedics, Dr. S.N. Medical College and Associated Group of Hospitals, Jodhpur, Rajasthan. 51 patients were admitted in the Department of Orthopaedics with either open (37) or close segmental tibia fractures (14) and treated with interlocking nail. All patients were subjected to a detailed history and clinical examination with particular emphasis on mode of injury, time of injury, interval between injury and hospital admission and nature of treatment taken prior to admission. Clinical examination was including general, systemic, neurovascular and local examination of injured part. Depending on nature of injury relevant radiological examination was done.

Anterior posterior and lateral radiograph were done to diagnose fracture type. Routine preoperative investigation was done.

Open fractures were immediately irrigated, washed and temporarily immobilized with posterior POP above knee slab. Patient was operated within 48 hours of hospital admission.

Correspondence
Ashok Singhvi
Dr S.N Medical College Jodhpur,
Rajasthan, India

Inclusion Criteria

- All skeletally mature patients.
- Open segmental tibial fractures (grade I to grade II Gustilo Aderson type)
- Close segmental tibial fractures without soft tissue involvement.

Isometric quadriceps exercise and toes mobilization was started from second postoperative day. Regular weekly follow up was done to inspect wound condition and other complication for compound fractures and regular 2 week follow up for close fractures.

- Passive knee mobilization exercise was started when pain and swelling subside. Active range of motion (ROM) exercise was started after 3 days postoperatively in all

patients. Serial radiographs were taken at 4 week interval. Partial weight bearing was started after 21 days, Non weight bearing walking with the help of a walker started after 3 to 5 days and full weight bearing was started after 6 to 8 weeks depending upon the radiological appearance. Patients were followed up periodically on an outpatient basis on 2nd, 4th, 6th, 10th, 14th, 18th week and 6th month. Clinical and radiological assessment will be done for pain, deformity, shortening, range of motion of knee, ankle, subtalar joints and radiological union. final outcome will be assessed using Johner and Wruh's criteria.

Johner and Wruh's criteria ^[5] for evaluation of final results.

Sl no.	Criteria	Excellent	Good	Fair	Poor
1.	Non-union, infection, Amputations	None	None	None	Yes
2.	Neurovascular disturbances	None	Minimal	Moderate	Severe
3.	Deformity				
	Varus/valgus	None	2-5	6-10	>10
	Anteversion /Recurvation	0-5	6-10	11-20	>20
	Rotation	0-5	6-10	11-20	>20
4.	Shortening	0-5mm	6-10mm	11-20mm	>20mm
5.	Mobility				
	Knee	Normal	>80	>75	<75
	Ankle	Normal	>75%	>50%	<50%
	Subtalar	>75%	>50%	<50%	--
6.	Pain	None	Occasional	Moderate	Severe
	Gait	Normal	Normal	Insignificant limp	Significant limp
7.	Strenuous activities	Possible	Limited	Severely limited	Impossible
8.	Radiological Union	Consolidated	Consolidated	Union	Not consolidated

Results

In our series maximum numbers of patients (78.42 %) were in age group 21 to 50 years, with age ranging from 18 to 76 years. The mean age of patients under study was 40.6 years. Male: female ratio of our series was 3.25:1, with males being involved almost three and a half times more than females. In our series, 38 cases were open segmental fractures of tibia and 8 cases were closed fractures with compromised soft tissue.

Road traffic accident was the most common mode of injury in 44 cases (86.27 %), fall from height in 5 cases and assault in 2 cases. Right leg was involved in 32 cases, left knee in 19 cases. Most common associated injury was clavicle fractures in 10 cases. Other associated injuries seen were [Figure 1].The mean interval between injury and surgery was 1.5 (range, 1–2) days. Primary treatment elsewhere (n=6) was the most common cause of delay in surgery. Six patients required blood transfusion due to open injuries or simultaneous fractures of other bones. The mean hospital stay was 9.5 (range, 5–19) days. The mean interval between surgery and clinical union was 18.2 (range, 14–23) weeks. The mean follow-up period was 10 (range, 10-30) months.

Postoperative complications were observed as in [Figure 2].

Out of 51 cases, 48 had normal leg extension. 3 cases had extensor lag < 10° while no cases had > 10° extensor lag.

In our series out of 51 cases, 42 cases had either full or more than 140° range of motion, 8 had range of motion between 120° to 140°, 1 case had range of motion between 90° to 120°.All patients had range of motion more than 90° (acceptable).

No angulation was present in 45 cases. Angulation < than 10° was present in 5 cases, angulation in between 10° to 20° was present in 1 case.

According to Johner and Wruh's criteria results seen were as

shown in [Table 1].

Discussion

The commonest cause of the fracture being high velocity road traffic accidents. In our series 86.27% of the fractures groups were due to high velocity road traffic accidents.

Most of the authors used reamed interlocking nails viz. Olerud and Karlstrom (1972), Puno et al (1986), Klemm and Borner (1986), Ekland et al (1993) and Renner et al (1993) ^[6-11] used undreamed tibial nail while Court-Brown et al (1996) ^[12-15] did a comparative study of reamed and unreamed nails. "Reaming resulted in the destruction of all vessels of the medullary canal, rigid nailing with reaming leads to a higher incidence of infection as dead bone produced due to reaming (debris/endosteal necrosis) acts as a good culture medium for bacteria (Bintcliffe et al. 1984) ^[16, 17]. while medullary nail without reaming caused minor damage to the blood supply.

Court Brown CM et al. (1996) ^[12-15] made a prospective study in 50 cases and concluded that reamed is better than unreamed nailing in tibial closed fractures. Larsen et al. (2004) studied 45 patients and concluded that the average time to fracture healing was 16.7 weeks in reamed group and 25.7 weeks in the unreamed group. The difference was significant (P=0.004). Mohit Bhandari et al. (2008) ^[18] conducted a multicenter, blinded randomized trial of 1319 adults in whom a tibial shaft fracture was treated with either reamed or undreamed intramedullary nailing and demonstrated a possible benefit for reamed intramedullary nailing in patients with closed fractures. They found necrosis of the inner 50-70% of the cortex after reaming. In our study we used unreamed nail in 38 patients and reaming only in proximal segment (To make high and anterior entry which prevents anterior projection of small proximal fragment due to pull of

patellar tendon) in remaining 13 patients.

In our study 74.51% patients were having open injury, this is in agreement with the study shown by Woll and Duwelius [19] who have reported an incidence of 75% open fractures in this pattern of injury.

Many authors support and recommend fixation with intramedullary nailing [35] with advent of interlocking nail provide superior results [12, 13]

Similar to our study and observations Ekeland and Alho [20, 21] examined 43 patients with segmental tibial fractures out of which they reported one non union, one deep and one superficial infection and finally they concluded that the interlocking nail proved to be efficient mode of treatment for comminuted segmental and unstable tibial fractures.

In our series 2 patients (3.9%) had superficial wound infection of the proximal incision site. This responded to the usual oral antibiotics and daily dressings. One patient (1.96%) had deep infection. Regular dressing, oral antibiotics and guarded weight bearing was continued till the fracture united (18 weeks). two cases had superficial infection were Gustilo's grade II. The injury surgery interval in one of these cases was 7days and the other 2 were 4-5 days (because of associated head injury). This delay in the surgery was the probable cause of superficial infection in two cases and deep infection in one case. This indicates that early surgery with a proper antibiotics cover is a must when considering a case of compound tibial fracture for nailing.

We encountered 3 cases of delayed union in which, after waiting for about 16 weeks when abundant callus was not visible in the skiagram and the patient had persistent tenderness over the fracture site. Two of the cases had hypertrophic type of non-union. The reason in one of these cases was probably a deep infection due to improper hygiene and non-compliance of the patient to follow the weight bearing protocol and other instructions and also lack of

regular antibiotic intake. This indicates the importance of regular follow up and patients compliance.

The distal fracture is the usual site for the non-union, proposed reason for this being the direct injury to the soft tissue overlying this fracture and natural tendency to slow union in fractures at this location [22].

Although other authors reported no significant difference in union rate at proximal and distal fracture sites. this is consistent with our results as in our study we got non-union in two patients at proximal fracture site.

Most common postoperative complication was anterior knee pain in 5 patients. Occasional Pain in knee was a common problem in 32 patients, 5 patients had constant pain after activity. However the pain did not disturb the activities of daily living in majority of patients.

In our series out of 51 cases 47 (92.15%) had acceptable Johner and wruth's criteria for functional results (sum of excellent and good results). Excellent in 36 (70.59%), good in 11 (21.57%), fair in 3 (5.87%) and poor in 1 (1.97) Ekeland and Alho [20, 21] reported results excellent in 29, good in 13 and fair in 2 and poor in one out of 45 cases.

Conclusion

From the observation of present study it is concluded that the high-energy trauma associated with this pattern of injury poses many challenges to the surgeon due to the precarious blood supply of the intermediate segment and the serious damage to the surrounding soft tissues. The risk of non-union, delayed union, infection and additional procedures is high as seen in this series of patients. The preferred method of initial fracture stabilisation is the use of unreamed interlocking intramedullary tibial nail with immediate soft tissue cover whenever possible, this procedure require less surgical time, hospital stay, is cost effective and have minimum complications with good functional outcome.

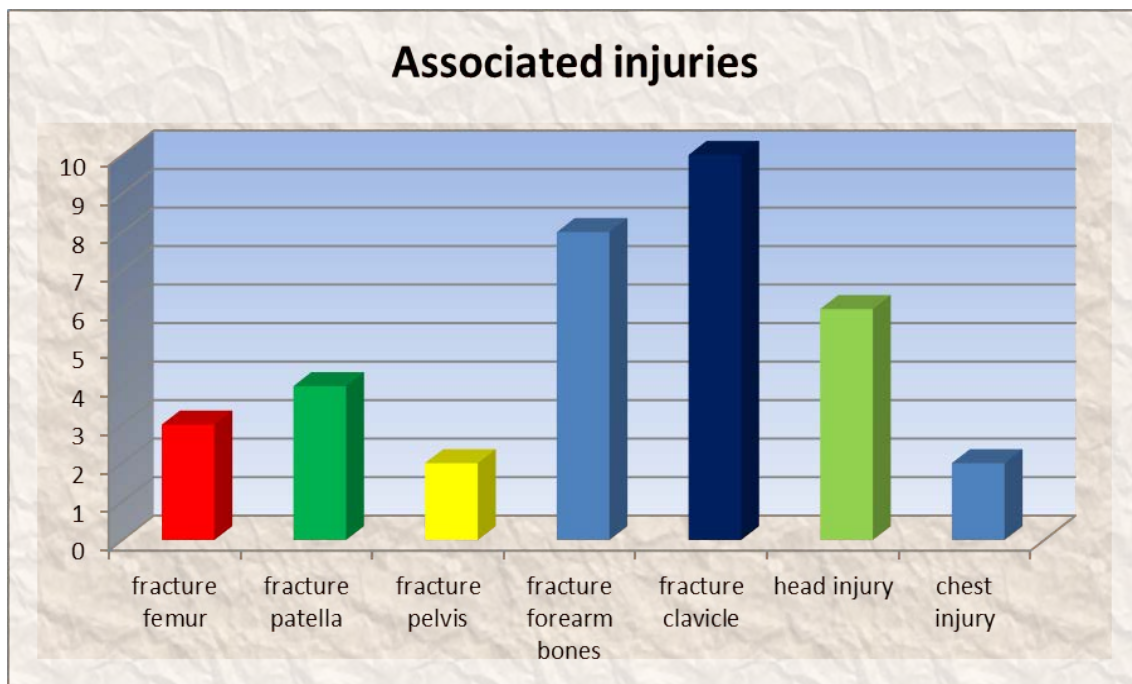


Fig 1: Associated injuries

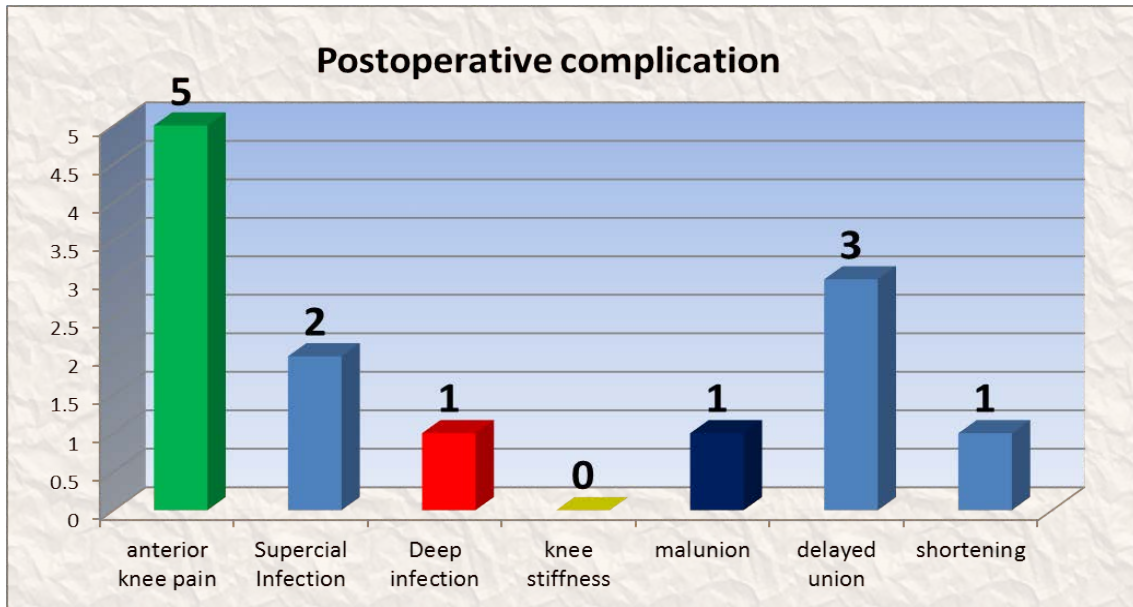
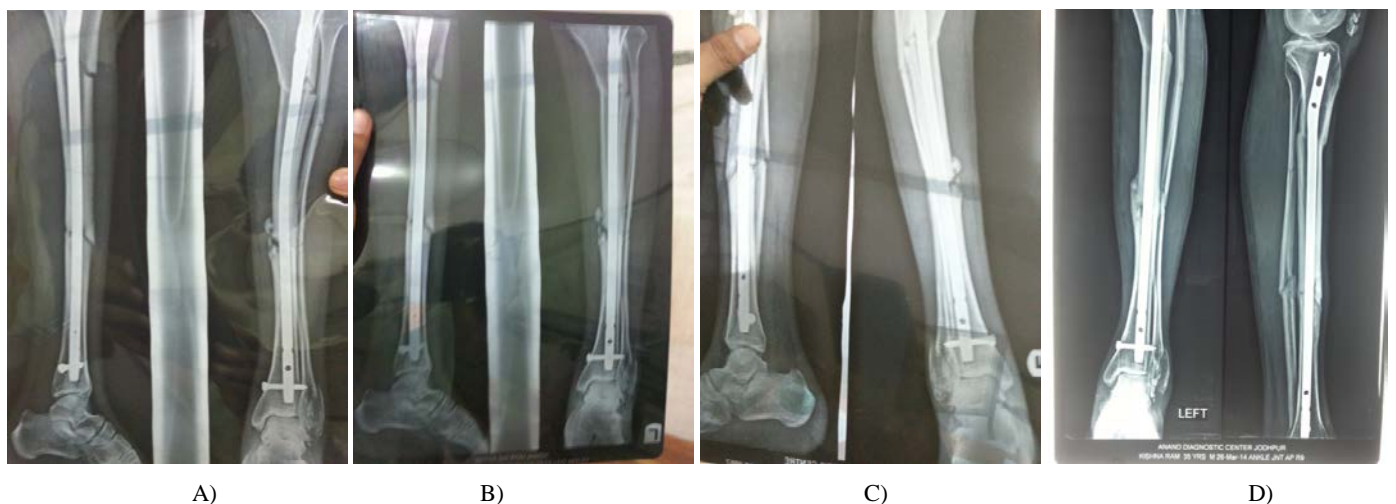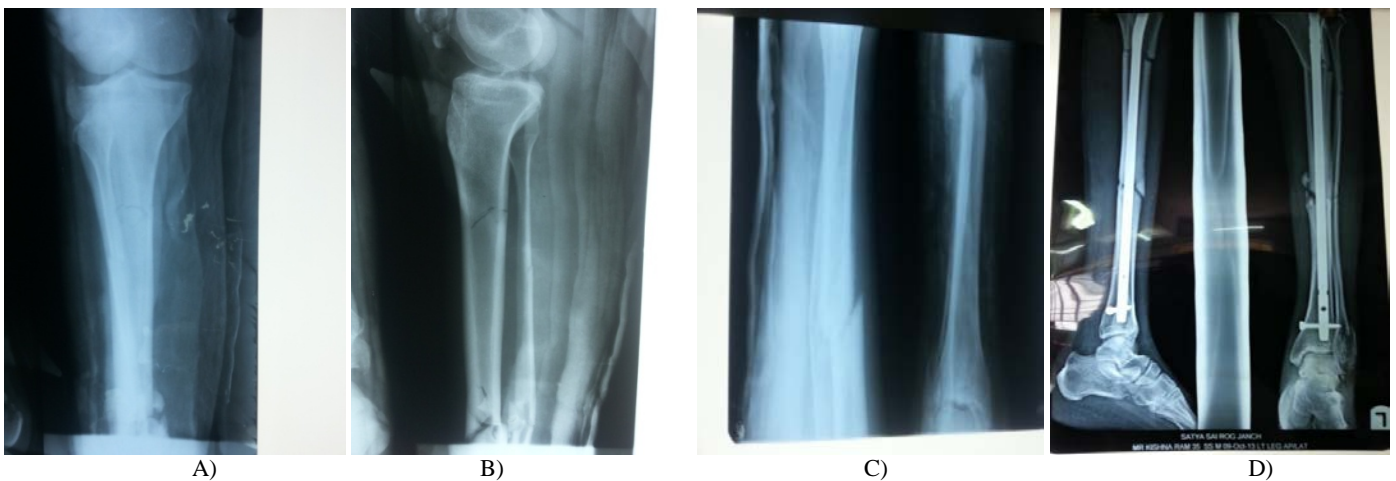


Fig 2: Post operative complication

Table 1: Johner and wruth's criteria⁵ for final results

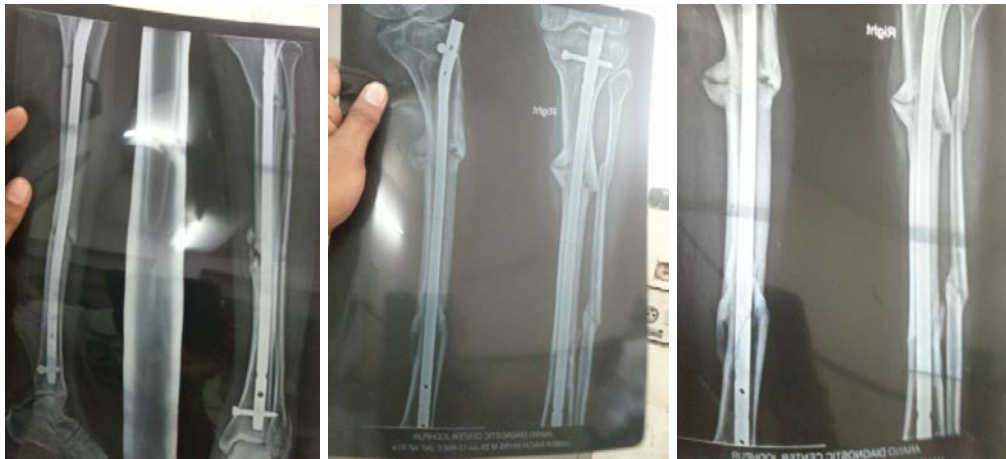No. of cases	Acceptable results		Unacceptable results	
	Excellent	Good	Fair	Poor
51	36	11	3	1
100%	70.59%	21.57%	5.87%	1.97%



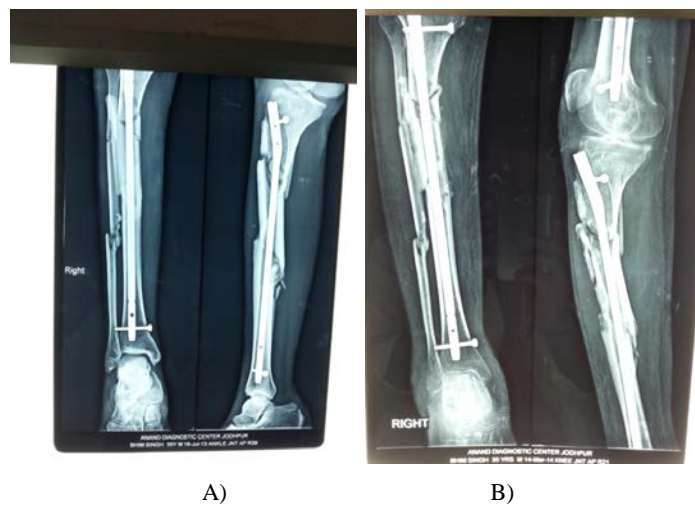
A), B), C) Pre-op radiographs of segmental fracture tibia. D) Immediate post-op radiograph E) One month follow up F) Two month follow up. G) Three month follow up H) 6 month follow up with radiological union.

Case 1

Complications



A) B) C)
Case 1: Radiographs showing hypertrophic nonunion at proximal fracture site.



A) B)
Case 2: Radiographs showing Infective nonunion at proximal fracture site.

Reference

1. Boylston BF, Milam R. Segmental fractures of the Tibia: an analysis of thirty cases. *Southern Medical Journal*. 1957; 50: 969- 975.
2. Thunold J, Varhaug JE, Bjerkeset T. Tibial shaft fractures treated by rigid internal fixation: the early results in a 4-year series." *Injury*. 1975; 7(2):125-133.
3. Bauer GCH, Eddwards P, Widmark PM. Shaft fracture of tibia. Etiology of poor results in a consecutive series of 173 fractures. *Acta Chir. Scand*. 1962; 124:286.
4. Edwards P. Fractures of the shaft of tibia: 492 - consecutive cases in adults - importance of soft tissue injury. *Acta. Orthop. Scan- Supple*. 1965; 76:1.
5. Wruh O, Johner R. Classification of tibial shaft fractures and correlation with results after rigid fixation. *Clinical Orthop*. 1983, 178.
6. Olerud S, Karlstrom G. Tibial fractures treated by AO compression osteosynthesis - Experience from 5 years material. *Acta. Orthop. Scan Supple*. 1972a; 140:1.
7. Olerud S, Karlstrom G. The spectrum of intramedullary nailing of the tibia, *Clin. Orthop* 198; 212:101.
8. Puno *et al*. Critical analysis of results of treatment of 201 tibial shaft tissue fractures. *Clin. Orthop*. 1986; 212:113.
9. Klemm, Borner. Interlocking nailing of complex fracture of femur and tibia. *Clin Orthop*. 1986; 212:89.
10. Ekeland A, Stromsoe K *et al*. Locked Intramedullary nailing for displaced tibial shaft fractures. *J Bone Joint Surg*. 1990, 805-809.
11. Renner N *et al*. Initial experience with undreamed tibial nail. *Helv. Chir. Acta* 1993; 59:665.
12. Court Brown CM *et al*. Closed intramedullary nailing - tibia- its use in closed & type I open fracture, *J.B.J.S*. 1990a; 72B:605,
13. Court Brown CM. *et al*. Locked intramedullary nailing of open tibial fractures. *J.B.J.S*. 1991; 73B:959.
14. Court Brown CM. *et al*. Infection after intramedullary nailing tibia. *J.B.J.S*. 1992; 74B:770,
15. Court Brown CM. *et al*. Reamed or undreamed nailing for closed tibial fractures - A prospective study in Tscherne C1 fractures - *JBJS* 1996; 78B:580,
16. Bintciiffe & Vickers: Tibial nailing - in open or shut cases. *JBJS* 1980; 62B:525,
17. Bintciiffe IW. The case of an open approach to tibial nailing. *Injury* 1984; 15(6):407.
18. Mohit Bhandari *et al*. Randomized Trial of Reamed and Unreamed Intramedullary Nailing of Tibial Shaft Fractures. *J Bone Joint Surg Am*. 2008; 90:2567-2578.
19. The segmental tibial fracture Woll TS, Duwelius PJ. *Clinical Orthopaedics and Related Research*. 1992; 281:204-207.
20. Interlocking intramedullary nailing in the treatment of tibial fractures. A report of 45 cases Ekeland A, Thoresen

BO, Alho A, Stromsoe K, Folleras G, Haukebo A. Clinical Orthopaedics and Related Research. 1988; 231:205-215.

21. Alho A, Benterud JG, Hogevoid HE *et al.* Comparison of functional bracing and locked medullary nailing treatment of displaced tibial fractures. Clin Orthop. 1992 277:243-50.
22. Intramedullary nailing in segmental tibial fractures Melis GC, Sotgiu F, Lepori M, Guido P. Journal of Bone and Joint Surgery - Series A. 1981; 63(8):1310-1318.