

ISSN: 2395-1958
IJOS 2017; 3(2): 720-722
© 2017 IJOS
www.orthopaper.com
Received: 14-02-2017
Accepted: 15-03-2017

Dr. Yash Rabari
PG Student Department of
Orthopaedics, Rural Medical
Collage, Loni, Maharashtra,
India

Dr. Ashish Somani
Associate Professor Department
of Orthopaedics, Rural Medical
Collage, Loni, Maharashtra,
India

Dr. Mohammad Akaram Saji
PG Student Department of
Orthopaedics, Rural Medical
Collage, Loni, Maharashtra,
India

Dr. DV Prasad
Professor Department of
Orthopaedics, Rural Medical
Collage, Loni, Maharashtra,
India

Dr. Ranjan Gupta
PG Student Department of
Orthopaedics, Rural Medical
Collage, Loni, Maharashtra,
India

Dr. Nawaz Sharif
PG Student Department of
Orthopaedics, Rural Medical
Collage, Loni, Maharashtra,
India

Correspondence
Dr. Yash Rabari
PG Student Department of
Orthopaedics, Rural Medical
Collage, Loni, Maharashtra,
India

Treatment of distal 1/3 tibia fractures: plating versus intramedullary nailing – A prospective comparative study

Dr. Yash Rabari, Dr. Ashish Somani, Dr. Mohammad Akaram Saji, Dr. DV Prasad, Dr. Ranjan Gupta and Dr. Nawaz Sharif

DOI: <http://dx.doi.org/10.22271/ortho.2017.v3.i2h.74>

Abstract

Background: Tibia is the most commonly fractured bone amongst all long bones of the body due to its position and lack of soft tissue protection. Treating tibia distal 1/3rd fracture is still a greater challenge. Fracture of distal shaft without involving articular surface are of common occurrence but the management of these unstable extraarticular distal tibia fractures remains challenging. The mechanism of injury and the prognosis of these fractures are different from pillon fractures, but their proximity to the ankle makes the surgical treatment more complicated than the treatment of tibial midshaft fractures.

Methods: There were 73 patients of fracture distal 1/3 tibia were enrolled during 2-May-2015 to 31-Dec-2016 in the study. They were randomly divided into two groups, there were 30 patient treated with distal tibia tip locking nail and distal 43 patient treated with distal tibia plate.

The patients were followed up every four weeks till radiological union was seen. At every follow up clinical examination was done to assess status of the surgical wound, pain, tenderness, range of motion of ankle, stability of the fracture and clinical union. X rays were taken in AP and Lateral views to look for signs of radiological union. The union is confirmed radiologically when plain X-ray showed bone trabaculae or cortical bone crossing fracture site on at least three surfaces on orthogonal radiograms. The functional outcome was assessed by. The American Orthopedic Foot and Ankle Society Score (AOFAS).

Results: There were total 73 patients among them 43 (58.9%) treated with open reduction and internal fixation with distal tibia plate and 30 (41.1%) treated with intramedullary tip locking nail. The mean age of patient treated with plat was 39.98 years (SD+9.64, Min-Max: 25-60) and treated with nail was 41.2 years (SD+10.28, Min-Max: 22-61).

Conclusion: Our study suggest platting is more effective method for extra articular closed distal 1/3 tibia fracture than intramedullary tip locking nail according to functional outcome with minimal postoperative complication

Keywords: Distal tibia, plate, nail

Introduction

Tibia is the most commonly fractured bone amongst all long bones of the body due to its position and lack of soft tissue protection^[1]. Treating tibia distal 1/3rd fracture is still a greater challenge^[1]. Fracture of distal shaft without involving articular surface are of common occurrence but the management of these unstable extraarticular distal tibia fractures remains challenging. The mechanism of injury and the prognosis of these fractures are different from pillon fractures, but their proximity to the ankle makes the surgical treatment more complicated than the treatment of tibial midshaft fractures. A variety of treatment methods have been suggested for these injuries, including nonoperative treatment, external fixation, intramedullary nailing and plate fixation^[2]. However, each of these treatment options is associated with certain challenges. Nonoperative treatment may be complicated by loss of reduction and subsequent malunion. Similarly, external fixation of distal tibia fractures may result in insufficient reduction, malunion, and pin tract infection. Intramedullary nailing can be considered the “gold standard” for the treatment of tibial midshaft fractures, but there are concerns about their use in distal tibia fractures. This is because of technical difficulties with distal nail fixation, the risk of nail propagation into the ankle joint, and the discrepancy between the diaphyseal and metaphyseal diameter of the intramedullary canal^[3].

Open reduction and internal plate fixation results in extensive soft tissue dissection and may be associated with wound complications and infections. The optimal treatment of unstable distal tibia without articular involvement remains controversial. There is no consensus on the best method of treatment. This include outcome of the patients treated with Distal tibia plate and Distal tibia tip locking nail in extra articular distal 1/3 tibia fracture as this are two main modalities of treatment.

Material and Methods

There were 73 patients of fracture distal 1/3 tibia were enrolled during 2-May-2015 to 31-Dec-2016 in the study. They were randomly divided into two groups, there were 30 patient treated with distal tibia tip locking nail and distal 43 patient treated with distal tibia plate. The inclusion and exclusion criteria were as mentioned below.

Inclusion criteria

- All extra articular closed fractures of distal 1/3 up to 43-A3 of AO classification distal tibia
- Patients of age 18 years and above
- Fresh fractures

Exclusion criteria

- Fracture of middle 1/3 and proximal 1/3 region of tibia
- Patients treated conservatively or any other method for other medical reasons.
- Open fractures.
- Pathological fractures.
- Patients who were lost to follow up or died before the fracture union.
- Patient with nerve injury.

The patients were first seen in the casualty. The history was taken followed by general and local examination of the patient. Neurovascular status was noted specially for nerve injury. X rays and other investigation were done. The fracture was temporarily immobilized with a below knee slab. Pre-operative planning and investigations were done and the patients were posted for open reduction and internal fixation with plate or closed reduction internal fixation with tiplocking nail.

Standard minimal invasive approach was used for tip locking nailing. Medial minimal invasive approach was used for distal tibia plating. Fracture classified according to AO classification of fracture distal tibia.

The patients were followed up every four weeks till radiological union was seen. At every follow up clinical examination was done to assess status of the surgical wound, pain, tenderness, range of motion of ankle, stability of the fracture and clinical union. X rays were taken in AP and Lateral views to look for signs of radiological union. The union is confirmed radiologically when plain X-ray showed bone trabaculae or cortical bone crossing fracture site on at least three surfaces on orthogonal radiograms. The functional outcome was assessed by The American Orthopedic Foot and Ankle Society Score (AOFAS).

Results

There were total 73 patients among them 43 (58.9%) treated with open reduction and internal fixation with distal tibia plat and 30 (41.1%) treated with intramedullary tip locking nail. The mean age of patient treated with plat was 39.98 years

(SD+-9.64, Min-Max: 25-60) and treated with nail was 41.2 years (SD+-10.28, Min-Max: 22-61).

The sex of the patient is not significant statistically. (Table.1) Road traffic accident was major mode of injury to distal tibia fracture. (Table-2)

The mean radiological healing time in patient operated with plat was 14.30 weeks (SD+-0.74) and in patient operated with nail was 13.43 weeks (SD+-0.63). The mean radiological healing time difference in patient operated with plat and in patient operated with nail was 0.87 week(t=5.25, df=71, P value =0.0001).

With open reduction and internal fixation with plat more excellent results were found than close reduction and internal fixation with tip locking nail according to functional outcome with AOFAS score assessment which is statistically significant. (Figure1)

Postoperatively in the plating group there were 4 cases complications and in the nailing group there were 12 cases with complications. Complications were more in the nailing group, which was statistically significant. (Figure.2)

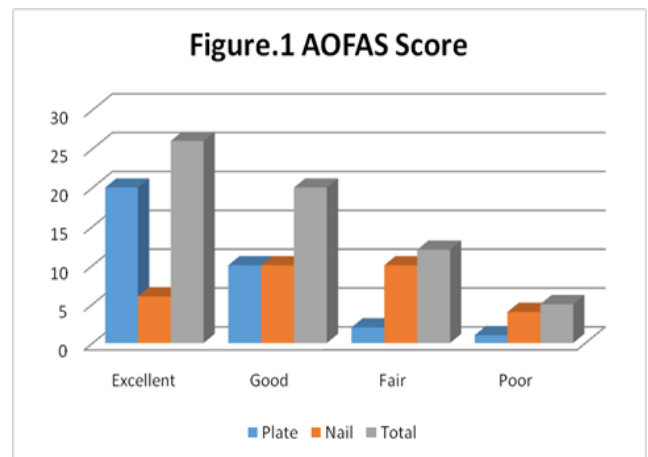
Table 1: Sex of the Patient

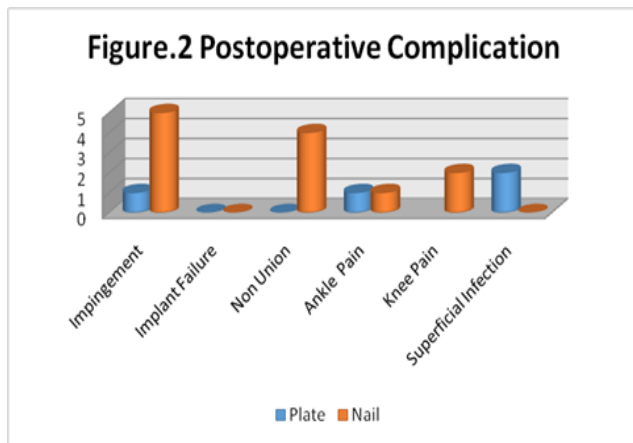
Sex	Plate	Nail
Male	38	27
Female	5	3
Total	43	30

Chi Square-0.27 P value-0.87

Table 2: Mode of Injury

Mode Of Injury	Plate	Nail	Total
Domestic	1	2	3
RTA	38	26	64
Sport	1	0	1
Assault	3	2	5





Discussion

Distal metaphyseal fractures are challenging fractures to treat given the number of complications arising out of various surgical modalities of treatment. These fractures are most often high energy fractures resulting from axial and rotational force on distal tibia [4-7]. There are multiple studies in the literature comparing various modalities of treatment for distal tibial fractures. The various treatment options include plating, Nailing, AO external fixation, Ilizarov fixation to conservative treatment. Although many studies are there already in the literature comparing the efficacy of each surgical methods the optimum treatment remains controversial.

Nonoperative treatment is also used in case of stable fractures with severe co morbidities but complications like delayed union, malunion and joints stiffness are very common [8,9].

Locking plate fixation gives good rigid construct, anatomical reduction and biomechanically superior to intramedullary nailing, however it results in results in extensive soft tissue dissection resulting in wound complications and infections. Hardware complications are more with locking plates warranting implant removal more frequently. With use of minimally invasive techniques the complications have significantly reduced [10-12].

Tip Locking Intramedullary nails are commonly used for treatment distal tibia fracture where the fracture is away from the plafond allowing two or more distal locking bolts. Though it is less invasive than plating, technically more challenging to achieve and maintain reduction because of anatomic characteristics of distal tibia [13-18].

Our study principally compares the results of distal tibial fractures treated with tip locking intramedullary nailing and plate. This study has shown plating to have lower rates of nonunion and malunion and lower rate of complication than in plating group but little more healing time than nail. Patients undergoing nailing anterior knee pain was seen in two patients. Four patients from nailing group had gone into nonunion for which additional surgery was done to achieve union. For four nonunions in nailing group, bone grafting was done. Two patients had superficial infection in plating group post operatively which was managed by wound debridement and antibiotic according to culture.

Conclusion

Our study suggest plating is more effective method for extra articular closed distal 1/3 tibia fracture than intramedullary tip locking nail according to functional outcome with minimal postoperative complication.

References

1. Paige W. Fracture of lower extremity: tibia pilon fracture. In: Terry C. James B (eds) Campbell's operative orthopaedics, eleventh edition, Philadelphia: Mosby Elsevier. 2010; 3118-19
2. Boris Zelle A, Mohit Bhandari, Michael Espiritu. Treatment of Distal Tibia Fractures without Articular Involvement: A Systematic Review of 1125 Fractures. J Orthop Trauma. 2006; 20:76-79.
3. Brad Petrisor A, Mohit Bhandari. Emil Schemitsch, Fracture of tibia and fibula, Rockwood & Green's Fractures in Adults, 6th Edition, Philadelphia, Lippincott Williams Wilkins. 2006, 2084- 85
4. Newman SD, Mauffey CP, Krikler S. Distal metaphyseal tibial fractures. Injury. 2011; 42:975- 84.
5. Richard RD, Kubiak E, Horwitz DS. Techniques of surgical treatment of distal tibial fractures. Orthop Clin North Am. 2014; 45:295-312.
6. Bedi A, Le TT, Karunakar MA. Surgical treatment of nonarticular distal tibia fractures. J Am Acad Orthop Surg. 2006; 14:406-16.
7. Vallier HA, Cureton BA, Patterson BM. Factors influencing functional outcomes after distal tibia shaft fractures. J Orthop Trauma. 2012; 26:178-83.
8. Othman M, Strzelczyk P. Results of conservative treatment of pilon" fractures. Ortop Traumatol Rehabil. 2003; 5:787-94.
9. Sarmiento A, Latta LL. 450 closed fractures of the distal third of the tibia treated with a functional brace. Clin Orthop Relat Res. 2004; 428:261-71.
10. Oh CW, Kyung HS, Park IH, Kim PT, Ihn JC. Distal tibial metaphyseal fractures treated by percutaneous plate osteosynthesis. Clin Orthop. 2003; 408:286-91.
11. Toms AD, McMurtie A, Maffulli N. Percutaneous plating of the distal tibia. J Foot Ankle Surg. 2004; 43:199-203.
12. Nork SE, Schwartz AK, Agel J, Holt SK, Schrick JL, Winkquist RA. Intramedullary nailing of distal metaphyseal tibial fractures. J Bone Joint Surg Am. 2005; 87:1213-21.
13. Robinson CM, McLauchlan GJ, McLean IP, Court-Brown CM. Distal metaphyseal fractures of the tibia with minimal involvement of the ankle. Classification and treatment by locked intramedullary nailing. J Bone Joint Surg (Br). 1995; 77:781-7.
14. Tan H. The clinical research of intramedullary nail fixation for distal tibial fractures. Hebei Med. 2012; 18:1394-7.
15. Ke DF, Zeng QT. Study on the clinical effects of interlocking intramedullary nailing in internal fixation of distal tibia fractures. China Foreign Med Treat. 2013; 28:25-6.
16. Toivanen JA, Vaisto O, Kannus P, Latvala K, Honkonen SE, Jarvinen MJ. Anterior knee pain after intramedullary nailing of fractures of the tibial shaft. A prospective, randomized study comparing two different nail-insertion techniques. J Bone Joint Surg Am. 2002; 84-A:580-5.
17. Court-Brown CM, Gustilo T, Shaw AD. Knee pain after intramedullary tibial nailing: its incidence, etiology, and outcome. J Orthop Trauma. 1997; 11:103-5.
18. Emami A, Mjoberg B, Karlstrom G, Larsson S. Treatment of closed tibial shaft fractures with unilateral external fixation. Injury. 1995; 26:299- 303.