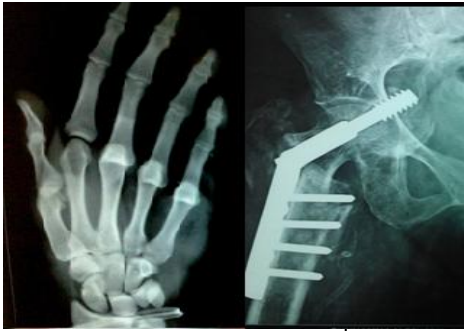

International Journal of Orthopaedics Sciences

ISSN: 2395-1958
IJOS 2017; 3(2): 646-649
© 2017 IJOS
www.orthopaper.com
Received: 02-02-2017
Accepted: 03-03-2017

Chaudhary P
Department of Orthopedics,
B.P. Koirala Institute of Health
Sciences, Dharan, Nepal

Shrestha BP
Department of Orthopedics,
B.P. Koirala Institute of Health
Sciences, Dharan, Nepal

Khanal GP
Department of Orthopedics,
B.P. Koirala Institute of Health
Sciences, Dharan, Nepal

Kalawar RPS
Department of Orthopedics,
B.P. Koirala Institute of Health
Sciences, Dharan, Nepal

Treatment of fracture of shaft of humerus in adults by intramedullary interlocking nail fixation- A series of 30 cases

Chaudhary P, Shrestha BP, Khanal GP and Kalawar RPS

DOI: <http://dx.doi.org/10.22271/ortho.2017.v3.i2g.62>

Abstract

Background: The optimal method of humeral shaft fracture fixation remains in debate. With the dramatic success of intramedullary fixation for fractures of the femur and tibia, there was speculation that IM-ILN might be more appropriate for humeral shaft fractures than DCP. There are very few studies comparing intramedullary interlocking nail and dynamic compression plating in fracture shaft of humerus and virtually no study in this part of world.

Objectives: The aim of the study was to assess the fixation of fracture shaft of humerus with interlocking nail and in terms of duration of operating time, amount of blood loss, rate of infection, pain at the fracture site, time to achieve union, functional outcome (DASH score), complications of surgery.

Methods and Methodology: This was respective interventional study. All patients with fractures of shaft of humerus that met the criteria for operative interventions (intramedullary interlocking nail) presenting to the department of Orthopaedics BPKIHS over a period of 3 years from July 2006 to August 2009 and giving informed consent were included in the study. The study enrolled 30 patients.

Results: Among 30 patients, 75% were male and 25% were female. The mean age of patients was 34.5 years. The usual mode of injury were road traffic accident followed by fall from height, work place injury. Most of the patients were right handed. The operating time was 100 mins with standard deviation of 11.24. The mean blood loss was 148.75 with standard deviation of 36.70. Post operative hospital stay was 4.5 days. The peroperative radial nerve palsy was 4%. Radiologically, four cortices union was only 50% in 24 weeks post operative time. Dash score gradually improved in subsequent follow up.

Conclusion: It is concluded that dynamic compression plating is better in our study for fracture shaft of humerus. Plate osteosynthesis remains the gold standard of fixation for humeral shaft fractures.

Keywords: Shaft of humerus, Interlocking nail, plate fixation

Introduction

Fractures of the humeral diaphysis comprise approximately 3% of all fractures [1]. The proportion of these fractures being treated conservatively reportedly varies from 33% [2] to 95% [3]. Intramedullary fixation of humeral diaphyseal fractures [4, 5, 6, 7], as well as compression plating [8, 2, 9]. Or external fixation in open fractures [10], are described. Lin reported a near 100% union rate in 73 fractures treated with either locked intramedullary nails or compression plates and screws [11]. He noted a significantly shorter operative time, less blood loss, and a lower complication rate with locked intramedullary nails. Chapman *et al.* found no difference in outcome or complication rate in an 84-patient, prospective, randomized study comparing Russell-Taylor locked intramedullary nails with 4.5-mm compression plates and screws [11]. Chapman *et al.* found no difference in outcome or complication rate in an 84-patient, prospective, randomized study comparing Russell-Taylor locked intramedullary nails with 4.5-mm compression plates and screws [11].

Correspondence
Dr. Pashupati Chaudhary
Additional Professor,
Department of Orthopaedics,
BPKIHS, Dharan, Nepal

The optimal method of humeral shaft fracture fixation remains in debate. With the dramatic success of intramedullary fixation for fractures of the femur and tibia, there was speculation that IM-ILN might be more appropriate for humeral shaft fractures than DCP. In this study, it is believed that the theoretical advantages of IM-ILN (which include less invasive surgery, an undisturbed fracture hematoma, and use of a load-sharing device) support its use in the humerus [12].

Humerus nailing has advantage in comminuted fracture and segmental fracture of shaft of humerus over humerus plating. Dynamic compression plating is gold standard for transverse stable fracture of shaft of humerus. Biomechanically intramedullary nailing can also be used in transverse fracture of shaft of humerus [1, 2, 3]. There are very few studies comparing intramedullary interlocking nail and dynamic compression plating in fracture shaft of humerus and virtually no study in this part of world.

Aims and Objectives

The aim of the study was to assess the fixation of fracture shaft of humerus with interlocking nail in terms of

- Duration of operating time
- Amount of blood loss
- Rate of infection
- Pain at the fracture site
- Time to achieve union
- Functional outcome (DASH score)
- Complications of surgery

Methods and Methodology

All patients with fractures of shaft of humerus that met the criteria for operative interventions intramedullary interlocking nailing presenting to the department of Orthopaedics BPKIHS in the study (Jun 2006 to August 2009) period and giving informed consent were included in the study.

Sample size: 30

Exclusion criteria

- Gustilo grade II and III open fractures shaft of humerus
- Periarticular fractures of humerus
- Fractures with associated neurovascular injury
- Bone and joint disease interfering with rehabilitation
- Primary nerve palsy
- Patients with active infection
- Candidates not giving informed consent
- Age less than with immature skeletal
- Pathological fractures

The average follow-up was 6 months to 1 year. Patients were followed up on 2nd week, 6th week, 12th week, and 24th week and assessed for evidence, pain at the fracture site using visual analogue score (VAS score), evidence of union, functional outcome using DASH score.

Statistical methods applied

Variables like age, sex, involved limb, dominant limb, duration of injury, type of fracture, duration of operating time, amount of blood loss, rate of infection, pain at the fracture site, time to achieve union, functional outcome of shoulder and elbow, complications of surgery were tested by appropriate parametric and non parametric statistical technique (e.g. T-test, Chisquare test) depending upon the natures of variables

Operative Procedure

Intramedullary Interlocking Nail

Patients was placed in the beach chair, semisitting position, with affected arm draped free. The image intensifier is brought in directly laterally on the injured side and the patient is brought on the edge of the table [Fig 1]. It is important to check and ensure a good X-ray of the entire humerus is possible. The surgeon stands at the top of the bed looking down on the shoulder and the assistant stands below on the other side of the image holding arm. A small incision was made at the anterolateral corner of the acromion, the deltoid was split and any visible subdeltoid bursa was excised [Fig 2]. The supraspinatus tendon was identified, and split for 1-2 cm in line with its fibres. The entry point was in greater tuberosity, just lateral to the articular margin. The canal was broached with either an awl or a starter reamer placed over guide wire. A long guide wire was then passed to the fracture site, only nail greater than 6 mm in diameter was cannulated. Reaming was done till chattering sound of cortex was heard, and then insert a nail 1 mm smaller in diameter than last reamer used. The length of nail was carefully chosen and checked twice, put in the medullary cavity. The nail was then locked with screws using zig proximally and free hand technique distally [Fig: 3a, b, c, d]. Any split in rotator cuff was repaired, incision was closed in layers. standard dressing was applied, no external splint was applied.

Results

Out of 30 patients participated in the study, 75% were male and 25% were female. The mean age of patients was 34.5 years.

The usual mode of injury were road traffic accident followed by fall from height, work place injury. Most of the patients were right handed. Mean surgery interval was 23.1 days. The operating time for nailing was 100 mins with standard deviation of 11.24. The mean blood loss in nail group was 148.75 with standard deviation of 36.70. Post operative hospital stay was mean stay of 4.5 days. The perioperative radial nerve palsy was 4%. Out of 30 patients 3 patients got superficial infection which was subsided with intravenous antibiotics. In 2 patients, there were iatrogenic fracture comminution. There was no tenderness at fracture site on attempted angulation till 12 weeks follow up.

Dash score gradually improved in 24 weeks follow up but 5 patients had stiffness of shoulder joint, most probably due to injury to rotator cuff [Fig: 5a, b]. Radiologically, four cortices union was only 50% in 24 weeks post operative time. Union was delayed due to distraction at the fracture site during nail insertion. There was implant failure in 1 patient [Fig: 4].

Discussion

In the study by Changulani M *et al.* [13] 86.9% were males and 13% females the mean age of the patients was 39 years. The mean age of patients was 45.3 years in the study conducted by S Raghavendra, Haresh P Bhalodiya [14]. The operating time is more in our study which is in contrary to the study done by Lin who had found shorter operating time. This may be due to poor expertise of surgeon, unavailability of trained person to operate image intensifier. The intraoperative blood loss is less most probably due to less invasive technique used which is comparable with study done by Lin [15]. Post operative hospital stay and post operative infection are comparable with done by S Raghavendra, Haresh Bhalodiya. Raghavendra S *et al* [14]. had found better outcome. Usually distraction at the fracture during insertion lead to delayed union of fracture in

Intramedullary interlocking nail. Raghvendra S *et al* study also had concluded delayed union.

Brumback RJ, Bosse MJ, Poka A *et al.* (1986) [17] reported a 94% union rate with rush pins and Enders although there was a significant rate of insertion site morbidity and backing out of the nails such that the excellent clinical success rate was much lower (62%).

Henley (1992) [18] reported a series of 49 patients with humeral shaft fractures treated with Ender nailing and had only one nonunion.

Imgman AM, Waters DA (1994) [19] concluded that closed locked intramedullary nailing for humeral shaft fractures can reliably provide secure fixation with acceptable risks.

Out of 30 patients participated in the study, 75% were male and 25% were female. The mean age of patients was 34.5 years.

The usual mode of injury were road traffic accident followed by fall from height, work place injury. Most of the patients were right handed. Mean surgery interval was 23.1 days. The operating time for nailing was 100 mins with standard deviation of 11.24. The mean blood loss in nail group was 148.75 with standard deviation of 36.70. Post operative hospital stay was mean stay of 4.5 days. The peroperative radial nerve palsy was 4%. Out of 30 patients 3 patients got superficial infection which was subsided with intravenous antibiotics. In 2 patients, there were iatrogenic fracture comminution. There was no tenderness at fracture site on attempted angulation till 12 weeks follow up.

Dash score gradually improved in 24 weeks follow up but 5 patients had stiffness of shoulder joint, most probably due to injury to rotator cuff [Fig:5a, b]. Radiologically, four cortices union was only 50% in 24 weeks post operative time. Union was delayed due to distraction at the fracture site during nail insertion. There was implant failure in 1 patient [Fig: 4].



Fig 1: Image intensifier

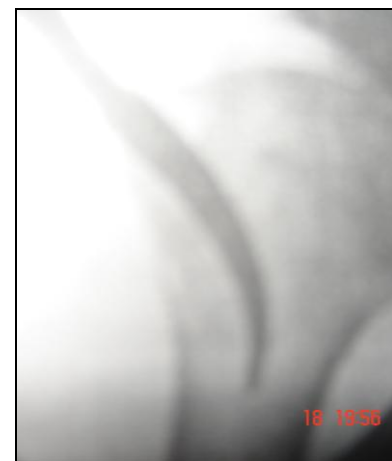


Fig 2: Anterolateral approach

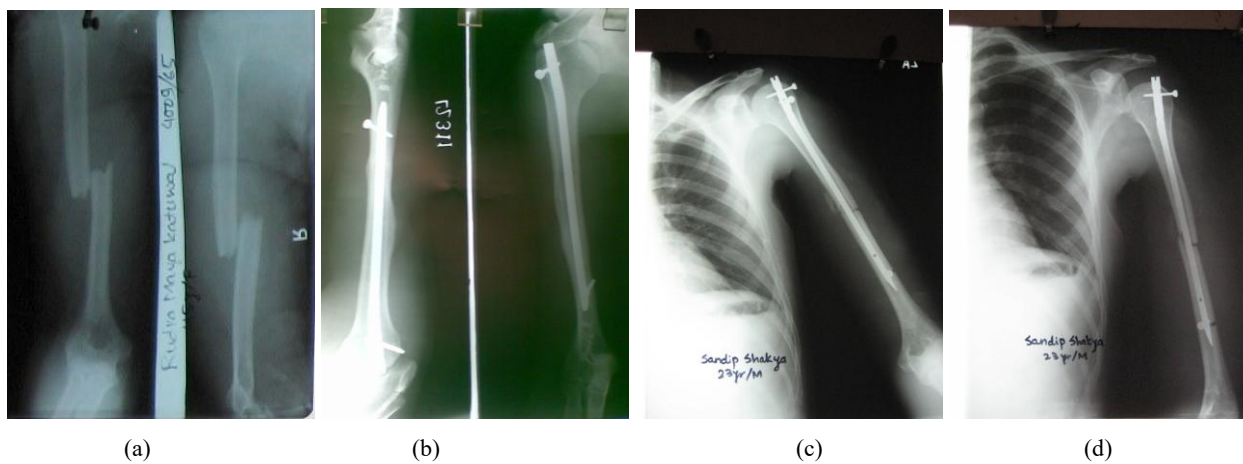


Fig 3: Pre operative and Post operative X-rays

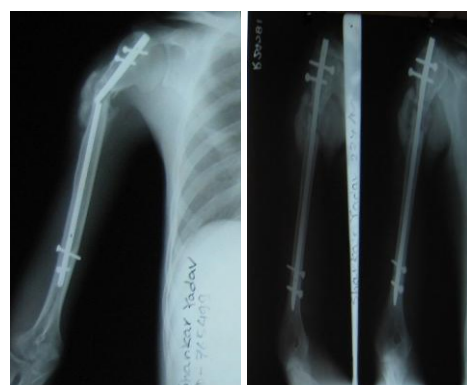
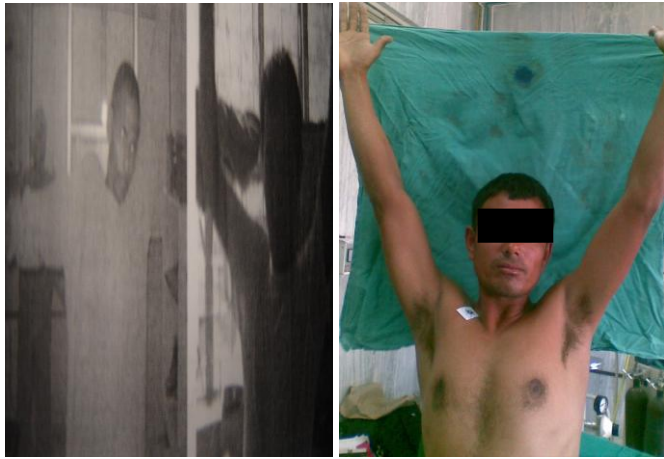
Fig 4: Post operative X-rays with implant failure



(a) (b)

Fig 5: Functional outcome

Conclusion

Intramedullary interlocking nailing is less invasive procedure with advantages of less blood loss for fracture shaft of humerus. There may be delay in union in nailing due to distraction at the fracture site which usually occurs during nail insertion. Poor outcome in intramedullary interlocking nailing is attributable to rotator cuff tear and shoulder impingement and lack of expertise of surgeon.

Locking humeral nails were introduced with hope that results from their use would parallel the clinical success seen with similar devices used for femoral and tibial fractures. Unfortunately, despite favourable initial reports, these devices have not enjoyed the unparalleled success of lower extremity locking nails. Further RCT is warranted.

References

1. Canale ST. Campbell's Operative Orthopaedics, 10th ed, 2003; III(54):3002-3016. Philadelphia: MOSBY.
2. Canale ST, Beaty Jh. Campbell's Operative Orthopaedics, 11th ed, Philadelphia: Mosby Elsevier; 2008; II(954):3389-3398.
3. Bucholz RW, Heckman JD, Court-Brown CM. Rockwood & Green's fractures in adults, 6th ed, Lippincott Williams & Wilkins. 2006; I(30):117-1159.
4. Schemitsch EH, Bhandari M. Fractures of the diaphyseal humerus. In: Browner BD, Jupiter JB, Levine AM, Trafton PG, eds. Skeletal trauma, 3rd ed. Toronto: WB Saunders. 2001, 1481-1511.
5. Praemer A, Furner S, Rice DP. Musculoskeletal conditions in the United States. Rosemont, IL: American Academy of Orthopaedic Surgeons, 1999.
6. Brinker MR, O'Connor DP. The incidence of fractures and dislocations referred for Orthopaedic services in a capitated population. J Bone Joint Surg Am. 2004; 86:290-297.
7. Gregory PR. Fractures of the humeral shaft. In: Bucholz RW, Heckman JD, eds. Rockwood and Green's fractures in adults, 5th ed. Philadelphia: Lippincott Williams & Wilkins; 2001, 973-996.
8. Fears RL, Gleis GE, Selingson D. Diagnosis and treatment of complications: Fractures of the diaphyseal humerus. In: Browner BD, Jupiter JB, Levine AM, Trafton PG, eds. Skeletal trauma, 2nd ed. Toronto: WB Saunders. 1998, 567-578.
9. Samiento A, Zagorski JB, Zych G *et al.* Functional bracing for the treatment of fractures of the humeral diaphysis. J Bone Joint Surg Am. 2008; 82:478-486.
10. Standard JP, Harris HW, McGwin G Jr *et al.* Intramedullary nailing of humeral shaft fractures with a locking, flexible. J Bone Joint Surg Am. 2003; 85:2103-2110.
11. Tytherleigh-Strong G, Walls N, McQueen NM. The epidemiology of humeral shaft fractures. J Bone Joint Surg Am. 1998; 80:249-253.
12. Sommer C, Gautier E, Muller M *et al.* First clinical results of the locking compression Plate (LCP). Injury. 2003; 34(2):B43-54.
13. Changulani M, Jain UK, Keswani T. Comparison of use of the humerus intramedullary nail and dynamic compression plate for the management of diaphyseal fractures of humerus, A randomised controlled study, International Orthopaedics, Springer-Verlag. 2006; 10.1007/s00264-006-0200-1
14. Radhavendra S, Bhalodiya HP. Internal fixation of fractures of the shaft of the humerus by dynamic compression plate or intramedullary nail: A prospective study. Indian J Orthop (serial online). 2007-2009; 41:214-8
15. Lin J. Treatment of humeral shaft fractures with humeral locked nail and comparison with plate fixation J Trauma 1998; 44:859.
16. Vander Griend RA, Tomasini J *et al.* Open reduction and internal fixation of humeral shaft fractures. J Bone Joint Surg Am. 1986; 68:430-433.
17. Brumback RJ, Bosse MJ, Poka A *et al.* Intramedullary stabilization of humeral shaft fractures in patients with multiple trauma. J Bone Joint Surg Am. 1986; 68:960-969.
18. Henley MB, Champman JR, Claudi BF. Closed retrograde Hackethal nail stabilization of humeral shaft fractures. J Orthop Trauma, 1992; 6:18-24.
19. Imgman AM, Waters DA. Locked intramedullary nailing of humeral shaft fractures implant design, surgical technique and clinical results, J Bone Joint Surg (Br). 1995; 77-B:84-89.