



## International Journal of Orthopaedics Sciences

ISSN: 2395-1958  
IJOS 2017; 3(2): 558-566  
© 2017 IJOS  
www.orthopaper.com  
Received: 21-02-2017  
Accepted: 22-03-2017

**Dr. Jaiveer Yadav**  
Department of Orthopaedics  
DDUH, Hari Nagar, New Delhi,  
India

**Dr. Vineet Kumar**  
Department of Orthopaedics  
DDUH, Hari Nagar, New Delhi,  
India

**Dr. SK Sharma**  
Department of Orthopaedics  
DDUH, Hari Nagar, New Delhi,  
India

### A comparative analysis of outcomes of treatment of fracture neck of femur with 9.5mm sliding hip screw and plate with an additional derotation screw versus three parallel cannulated hip screws

**Dr. Jaiveer Yadav, Dr. Vineet Kumar Arora and Dr. SK Sharma**

DOI: <http://dx.doi.org/10.22271/ortho.2017.v3.i2f.51>

#### Abstract

Fracture neck of femur has always attracted the mankind due to its peculiar nature of going into non union and osteonecrosis of femoral head even with best fixation method and adequate reduction. A novel way to treat fracture neck of femur is with small diameter dynamic hip screw and an additional derotation screw. 30 patients aged 18-60 years presenting to Deen Dayal Upadhyay Hospital with fresh (<3 weeks old) fracture neck of femur were randomized into two groups and were treated with two different modalities of fixation: Small diameter sliding hip screw and plate with an additional derotation screw (Mini DHS group) and three cannulated cancellous screws in an inverted triangle configuration (CCS group). Intraoperative duration of surgery and blood loss was noted. All the patients were followed up for a minimum period of 12 months. The clinical outcomes were evaluated using UCLA score. Post-operative radiographs were used to look for evidence of union, loss of the alignment of the fracture, trabecular continuity at fracture line, late segmental collapse and the presence of avascular necrosis. Between group comparisons were performed using chi square test and Student's T test.

**Conclusion:** Small diameter dynamic hip screw with an additional derotation screw is a good method to treat fracture neck of femur with increased incidence of union and less complications.

**Keywords:** Fracture neck femur, CCS, Mini DHS, non union, osteonecrosis

#### Introduction

Fracture neck of femur is one of the most common fracture encountered in clinical practice in old age. This fracture has always attracted the mankind due to its peculiar nature of going into non union and osteonecrosis of femoral head.

They are broadly classified into undisplaced or displaced types [1]. The treatment varies according to the fracture pattern, patient age, bone quality, and preexisting comorbidity [2, 3]. Closed or open reduction with internal fixation is the standard treatment for displaced and undisplaced fractures in patients of young age.

Arthroplasty procedures for young adults with displaced fractures are not ideal because of the patients young age and high level of activity. The implants for fixation in such fractures include cannulated screws, sliding hip screw, nails, and pins and double angle blade plate [4-6].

Many clinical, biomechanical and cadaveric studies have been done over the time comparing the outcome of fixation of fracture neck of femur with dynamic hip screw and multiple cancellous lag screws. While the dynamic hip screw has the disadvantage of tissue stripping and additional blood loss during the surgery but it gives a major edge of being the better method of fixation, better resistance to varus tilt and easy ideal placement of a single screw in the femoral head [3, 8-10]. An additional parallel 6.5 mm cancellous screw has been found to prevent rotation of proximal fragment during triple reaming with little consensus regarding additional fixation provided by the screw [10, 11]. The goal of this study is to evaluate and compare the clinical and radiographic outcomes following reduction and internal fixation of fracture neck of femur with Mini DHS and triple cannulated cancellous screws

#### Correspondence

**Dr. Jaiveer Yadav**  
Department of Orthopaedics  
DDUH, Hari Nagar, New Delhi,  
India

## Objective

To evaluate clinical and radiological outcomes of patients with fracture neck of femur treated by a small diameter(9.5mm) dynamic hip screw(Mini DHS) with a parallel 6.5mm cannulated cancellous screw and three parallel 6.5mm cannulated cancellous screws.

## Material and methods

This study was a prospective, randomized study which was conducted in the Department of Orthopaedics, Deen Dayal Upadhyay Hospital, Hari Nagar, Delhi from January 2013 to September 2015 It was conducted on patients with traumatic fractures neck of femur A total of 30 patients who were operated for fracture neck of femur were included in this study during this period. The patients were randomly grouped into two groups:

Group A (Mini DHS Group)

Group B (CCS Group)

For the selection of patients following inclusion and exclusion criteria was considered.

### Inclusion criteria

- Adult (>18 years of age)
- Fresh fracture neck of femur (all grades of Garden's and Pauwel's)
- Fractures within three weeks of injury

### Exclusion criteria

- Associated fracture of the same extremity
- Pathological fractures
- Patient having indications for hemiarthroplasty
- Patient not willing to participate in the study.
- Pregnant females
- Patients more than 60 years of age

### Preoperative assessment:

Patients included in the study underwent a preoperative analysis in which the various aspects regarding injury to patient were assessed. Following assessment was done:

1. Radiological assessment: Patients were assessed radiologically to find out the position and type of fracture and following X rays were done:

X ray Pelvis with both hip AP view

X ray of involved hip AP (15° internal rotation) and lateral view

All fractures were classified on the basis of Pauwel's classification into type I type II and type III or Garden's classification into type I, type II, type III and type IV.

2. Preoperative investigations: patients were investigated for the various parameters as given in proforma (Annexure 2)

Preanaesthetic check-up of the patient was done and fitness for surgery was taken. After getting proper informed consent (Annexure 3) from the patient, patient was taken up for surgery with either a Mini DHS with an additional derotation screw or three 559parallel 6.5mm cannulated cancellous screws.

## Implants and instrumentation

### 1. Mini DHS

- Thread diameter-9.5mm
- Core diameter-7.5mm
- Thread length-16mm
- Screw length-50mm to 110mm

- Side plate-2-4 holed
- Additional 6.5mm cannulated cancellous screw with 16mm/32mm thread length

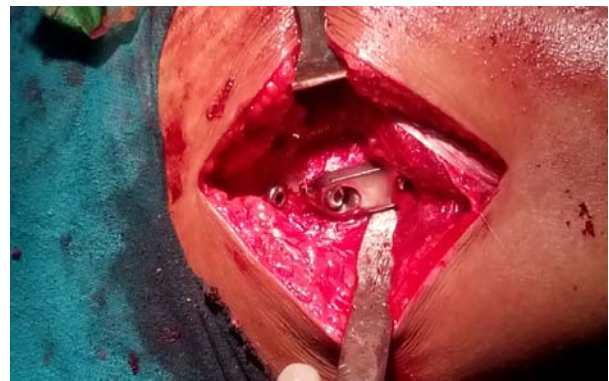### 2. Cannulated Cancellous Screw

- Thread diameter-6.5mm
- Thread length-16mm/32mm
- Screw length-50mm to 110mm

## Procedure

Patients were operated in a supine position on fracture table under image intensifier under spinal or general anaesthesia. Once the patient was under anaesthesia, closed reduction was attempted by Whitman's or Leadbetter's method. The quality of the reduction was judged on the basis of fluoroscopic imaging as per Garden's alignment index before proceeding with internal fixation. Only an anatomic reduction was accepted and none of our patients required open reduction and internal fixation After proper painting and draping incision was taken over lateral aspect of the affected thigh after palpating greater trochanter. Exposure was done in layers and bone was reached. Further procedure was different for both the groups and consisted of:

1. Group A (Mini DHS)-A 2mm K wire was inserted through the fracture site under image intensifier in both AP and Lateral views with central position in the femoral head. Another K wire was placed parallel and superior to it to prevent rotation of the proximal fragment during triple reaming. Reaming was done over the inferior guide wire with the help of triple reamer. Permanent fixation was achieved with the help of Mini DHS passed over the guide wire after assessing length of the screw with depth gauge. A 6.5 mm cannulated cancellous screw was placed over the second K wire. Two, three or four holed side plate was fixed with the help of screws according to the fracture configuration. Closure was done in layers and aseptic dressing was done.



After insertion of implant (Mini DHS with derotation screw)

2. Group B (CCS)-Three parallel 2 mm guide wires were inserted through the fracture site under image intensifier in both AP and Lateral views with the help of parallel guide in an inverted triangle configuration. Permanent fixation was achieved with the help of three 6.5mm cannulated cancellous screws with 16mm/32mm thread length passed over the guide wires, with thread length taken such that threads do not come at the fracture site to provide adequate compression at the fracture site. Closure was done in layers and aseptic dressing was done.

Patients were called back for follow-up after 1month, 3 months, 6 months and 1 year. Radiological and Clinical evaluation were carried out on each follow up visit.

In radiological evaluation, the degree of the union, loss of the alignment of the fracture, trabecular integrity at fracture line, late segmental collapse and the presence of avascular necrosis was observed.

In clinical evaluation of the latest status of the patients, pain, limitation of movement and shortness were noted. Patients were evaluated by UCLA (University of California, Los Angeles) hip evaluation score in terms of function.

The statistical analysis of normally distributed continuous variables between the groups was performed using Student’s t test. Nominal categorical data between the groups were compared using Chi-square test or Fisher’s exact test as

appropriate. P value<0.05 was considered statistically significant.

**Results and observations**

Thirty patients of fracture neck of femur were included as study sample. Patients were divided into two study groups randomly and were followed up for one year Mini DHS group (Group A) had 15 patients and CCS group (Group B) had 15 patients.

**Age and sex distribution:** In our study the mean age was 40 years in Group A and 37.47 years in Group B In our study 25 out of 30 patients were male. 80% of the patients in group A were male. 86.7% of the patients in group B were male.

Age Groups (Years)	Group A		Group B		P Value
	Frequency	%	Frequency	%	
18 – 30	4	5%	5	33.3%	0.629
31 – 40	6	40%	5	33.3%	
41 – 50	3	20%	4	26.7%	
51 – 60	3	20%	1	6.7%	
Total	15	100%	15	100%	
Mean ± SD	40 ± 11.08		37.47 ± 10.16		0.519

Sex	Group A		Group B		P Value
	Frequency	%	Frequency	%	
F	3	20%	2	13.3%	1.000
M	12	80%	13	86.7%	
Total	15	100%	15	100%	

**Mode of injury:** In our study 19 cases had injury as a result of road traffic accident, 11 cases had injury by fall.

Mode of injury	Group A	Group B	Total	Percentage
RTA	8	11	19	63.33%
Fall	7	4	11	36.66%
Total	15	15	30	100%

**Interval between injury and operation:** The mean delay between injury and operation was 11.67 days for group A and 11.27 days for group B.

Interval between injury and Operation	Group A		Group B		P Value
	Frequency	%	Frequency	%	
upto 1 week	3	20%	3	20%	0.904
>1 week - 2 weeks	8	53.3%	9	60%	
>2 weeks	4	26.7%	3	20%	
Total	15	100%	15	100%	
Mean ± SD	11.67 ± 4.58		11.27 ± 4.03		0.801

**Intraoperative blood loss:** Intraoperative blood loss was comparatively higher in group A. Patients of group A had an average blood loss of 141.33 ml. Patients of group B had an average blood loss of 126ml.

Intraoperative blood loss	Group A	Group B	P Value
	Mean ± SD	Mean ± SD	
In ml(millilitres)	141.33 ± 32.48	126.0 ± 45.79	0.299

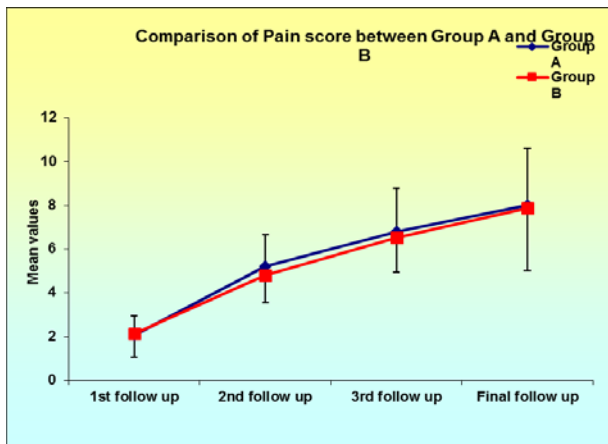
**Duration of surgery:** Mean duration of surgery was more for CCS group. Mean duration of surgery for group A (Mini DHS group) was 94 minutes, while for group B (CCS group) it was 104.67 minutes.

Duration of Surgery	Group A (n=15)	Group B (n=15)	P Value
	Mean ± SD	Mean ± SD	
Minutes	94.0 ± 6.87	104.67 ± 10.26	0.002

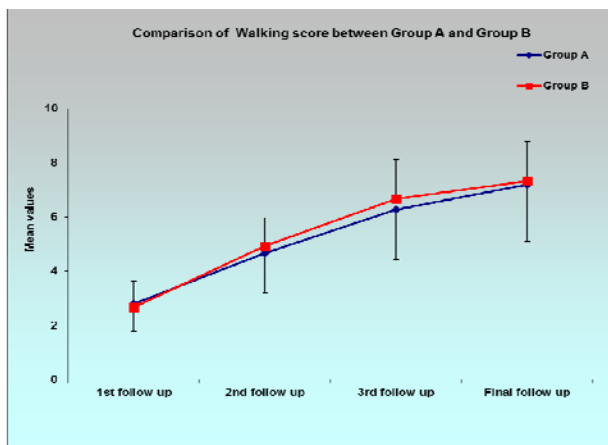
**Fracture union:** Mean duration for fracture union was 16.67 weeks for group A (Mini DHS group) and 17.33weeks for group B (CCS group).

Fracture Union (wks)	Group A (n=15)	Group B (n=15)	P Value
	Mean ± SD	Mean ± SD	
Weeks	16.67 ± 2.31	17.33 ± 2.61	0.617

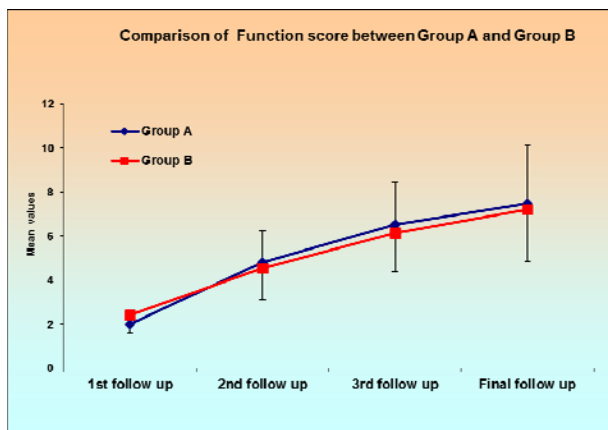
**Pain score:** Curve for pain scoring on UCLA score was almost identical for both the groups with group A having a slightly better score.



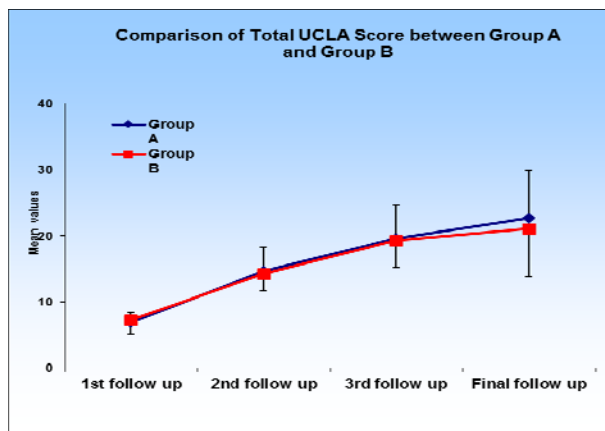
**Walking score:** Curve for walking score on UCLA score was identical for both the groups at each follow up and there was no statistically significant difference between the two groups.



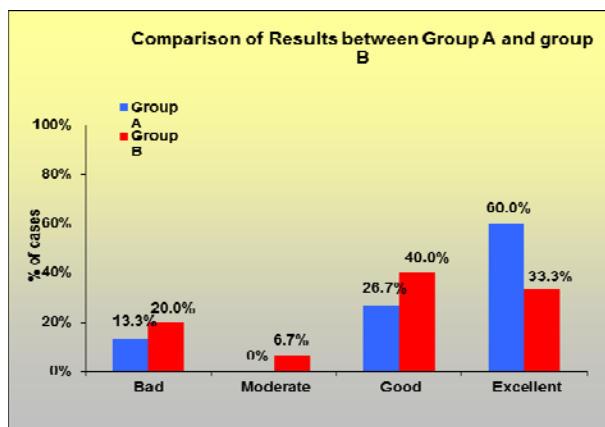
**Function score:** Functional scoring on UCLA score was almost similar for both the groups at each follow up and there was no statistically significant difference between the two groups



**Total ucla score:** Mean total UCLA score at was more for group A at 2<sup>nd</sup>, 3<sup>rd</sup> and final follow up. Difference between the mean total score was not statistically significant for both the groups.



**Final results:** 60% of the patients in group A had excellent results, while only 33.3% patients in group B had excellent results. 26.7% of the patients in group A had good results, while 40% patients in group B had good results. Final difference in the results was not statistically significant for both the groups.



**Discussion**

Fracture neck of femur is one of the most common fracture encountered in clinical practice. Implant for fixation of fracture neck of femur in young adults has been always a matter of debate. Our study also aimed at finding the implant of choice for fixation of fracture neck of femur in young adults but in old patients and patients with low physical demand the choice is arthroplasty.

Our study included 30 patients of fracture neck of femur fixed with either small diameter(9.5 mm) dynamic hip screw and an additional derotation screw (Mini DHS group) or three cannulated cancellous screws in an inverted triangle configuration ( CCS group). 15 patients each were included in Mini DHS and CCS group. All the patients were followed up for a minimum period of twelve months.

**Age and Sex distribution**

In our study age of the patients ranged from 18 years to 60 years with a mean age of 40 years in Mini DHS group and 37.47 years in CCS group. Most of the patients i.e 83.33% in our study were male. The femoral neck fractures are most often a result of high energy trauma among young people, with incidence of only 2% in patients under 50 years of age. The incidence increases with age, and after 50 years is doubled for each subsequent decade, and is 2-3 times higher in women than in men as depicted in a review conducted by Orlin Filipov [12] in 2014. The age group in our study

comprised only of young adults, characterized by high activity level in male patients as per the locality responsible for higher incidence of fracture neck of femur in male patients.

**Mode of injury**

In the present series, most common mode of injury was road traffic accidents which accounted for 63.33% of the total cases followed by fall which accounted for 36.66% of the total cases, which is similar to study by M P Singh *et al.* [13] in which mode of injury was RTA in 61.81% and fall in 38%.

**Interval between injury and operation**

In our study the mean delay between injury and operation was 11.67 days for group A and 11.27 days for group B. 17 out of 30 patients were operated between one to two weeks. Delay in getting fitness for anaesthesia accounting for the delay in most of the remaining cases. In a study conducted by Jain *et al.* [14] in 2002 delayed surgical treatment of subcapital hip fractures was associated with a higher rate of avascular necrosis, this complication did not significantly affect functional outcome.

**Intraoperative blood loss**

Intraoperative blood loss was comparatively higher in group A. Patients of group A had an average blood loss of 141.33 ml. Patients of group B had an average blood loss of 126ml. Increased intraoperative blood loss in Mini DHS group correlated well with other study by A S Sidhu *et al.* [15] comparing conventional DHS and CCS. Mini DHS despite small incision and less soft tissue stripping as compared to the conventional DHS, does not appear to provide any added advantage of less blood loss and soft tissue stripping as compared to cannulated cancellous screw fixation.

**Duration of surgery**

Mean duration of surgery for CCS group was more than Mini DHS group. Mean duration of surgery for Mini DHS group was 94 minutes, while it was 104.67 minutes for CCS group. The difference between duration of surgery for both the groups was statistically significant.

**Fracture union**

In our study the mean of total duration for fracture union was 16.67 weeks in Mini DHS group and 17.33 weeks for CCS group. The difference in total duration for fracture union in both the groups was not statistically significant.

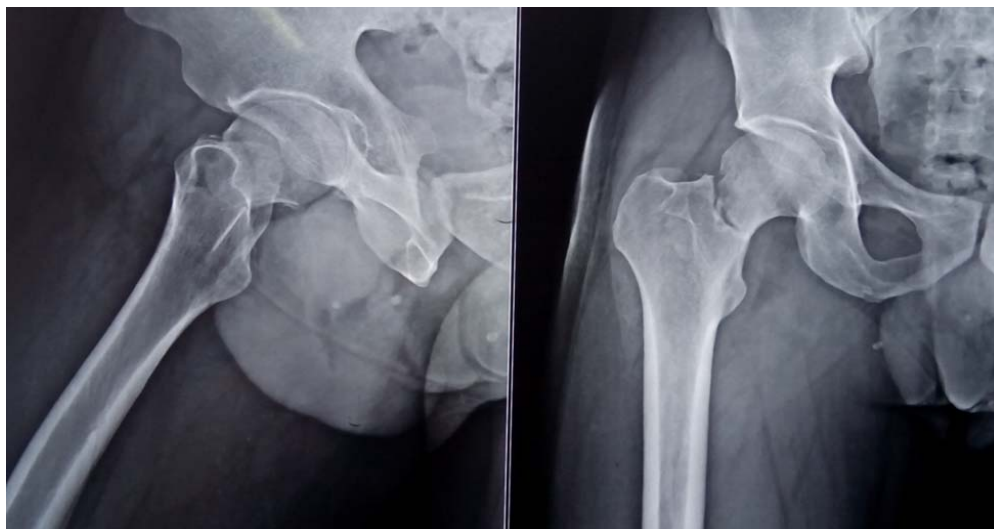**Functional outcome**

According to total UCLA score at final follow up 53.3% of the patients in Mini DHS group had excellent results, while only 33.3% patients in CCS group had excellent results. 26.7% of the patients in Mini DHS group had good results, while 33.3% patients in CCS group had good results. Mean UCLA score at final follow up was 22.67 for Mini DHS group and 21.07 for CCS group which corresponds to good result as per UCLA scoring. The difference between final functional outcomes in Mini DHS group and CCS group were not statistically significant and is comparable with the previous studies comparing conventional DHS and CCS by various authors i.e Lee Yih Shiunn *et al.* [16], A S Sidhu *et al.* [15], Razik *et al.* [17].

**Complications**

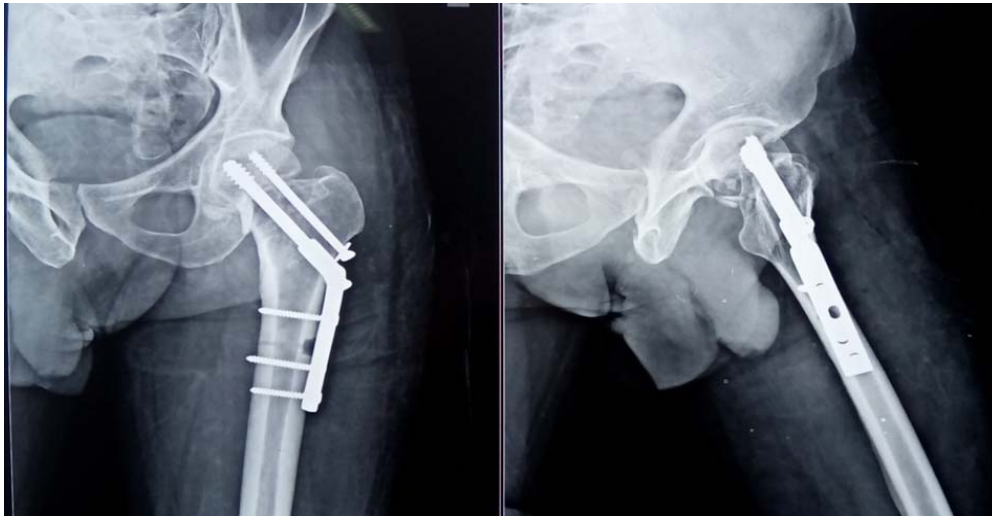
22 out of 30 patients had no complications in our study. 66.7% patients in Mini DHS group and 80% patients in CCS group had no complications. One patient in Mini DHS group had late onset infection after radiological union and one had top screw loosening but was not causing any discomfort to the patient and did not required any surgical intervention. As per our study the nonunion and implant failure was noted in three patients of each group i.e. 20% similar to the study conducted by Dendrick DK *et al.* [7] on 25 patients of fracture neck of femur. All the patients having nonunion were advised valgus intertrochanteric osteotomy. 3 out of 6 patients with nonunion were lost to follow up after one year. One of the patient went to another institute and bipolar hemiarthroplasty was done. Valgus osteotomy was done for the remaining two patients.

**Clinical Cases**

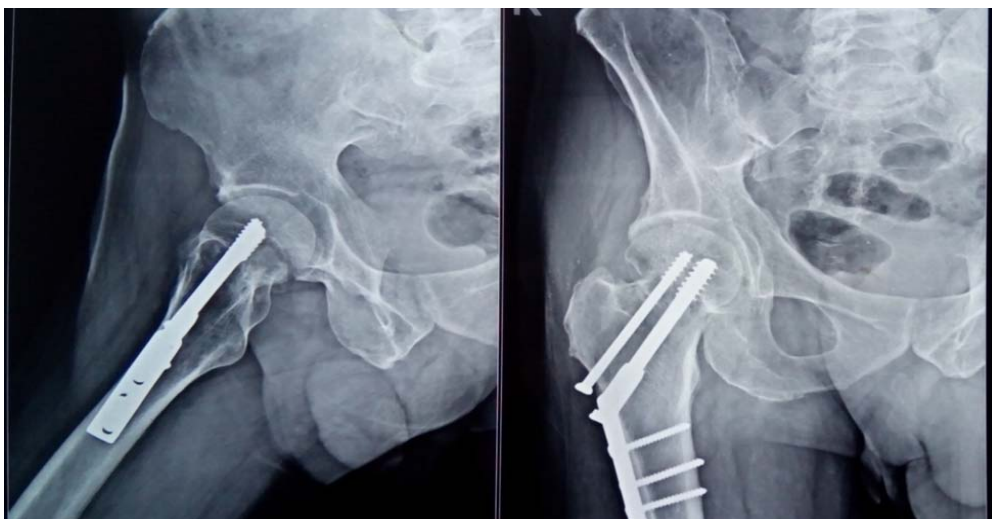


Preoperative radiographs

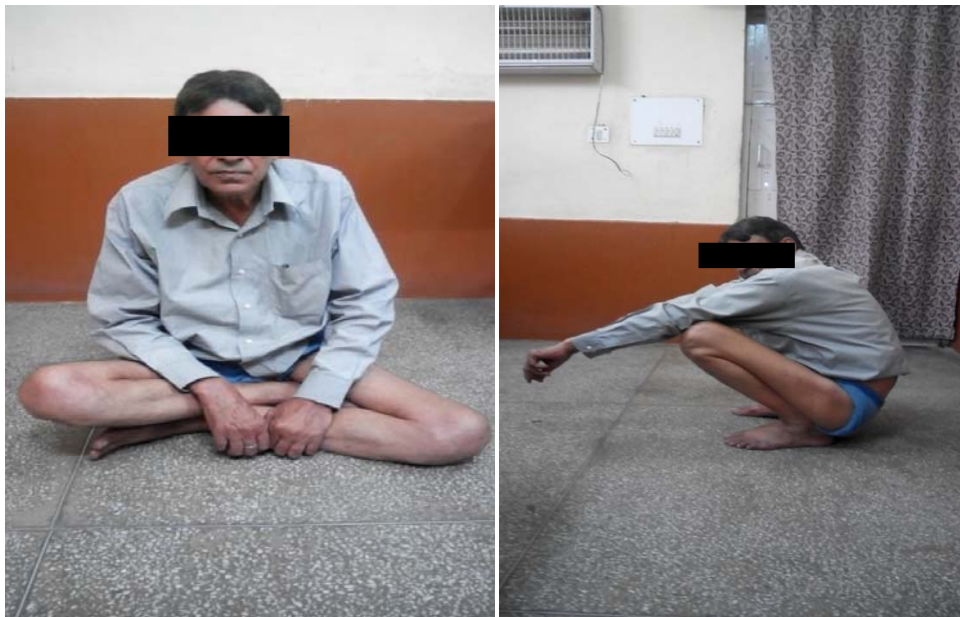



Post operative radiographs

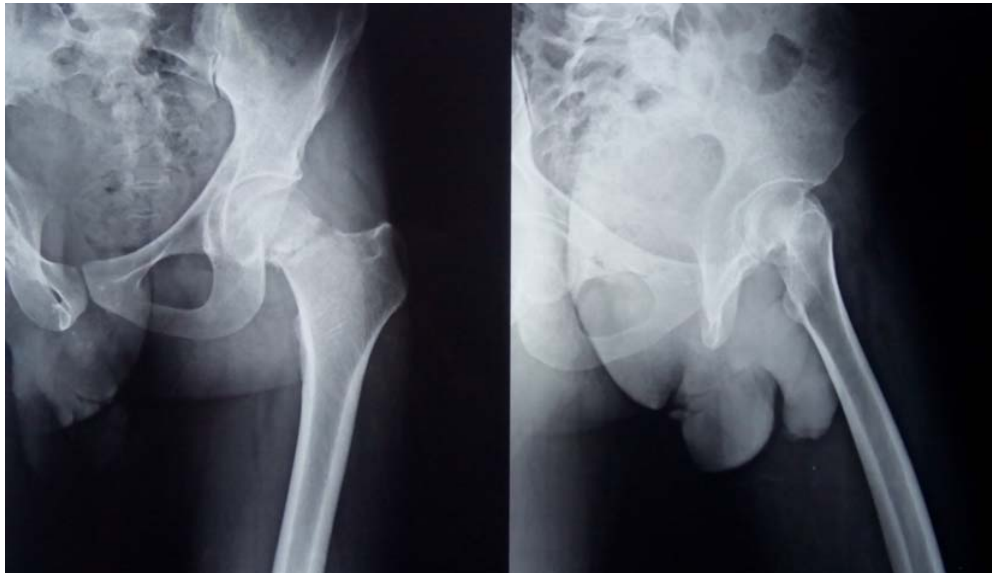


Radiographs at final follow up

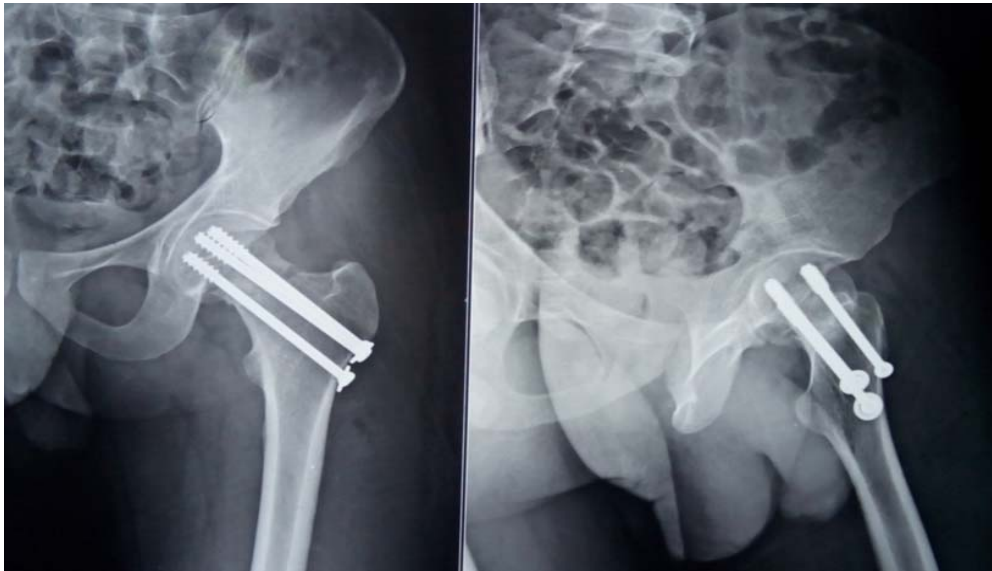

Squatting and sitting cross legged at final follow up

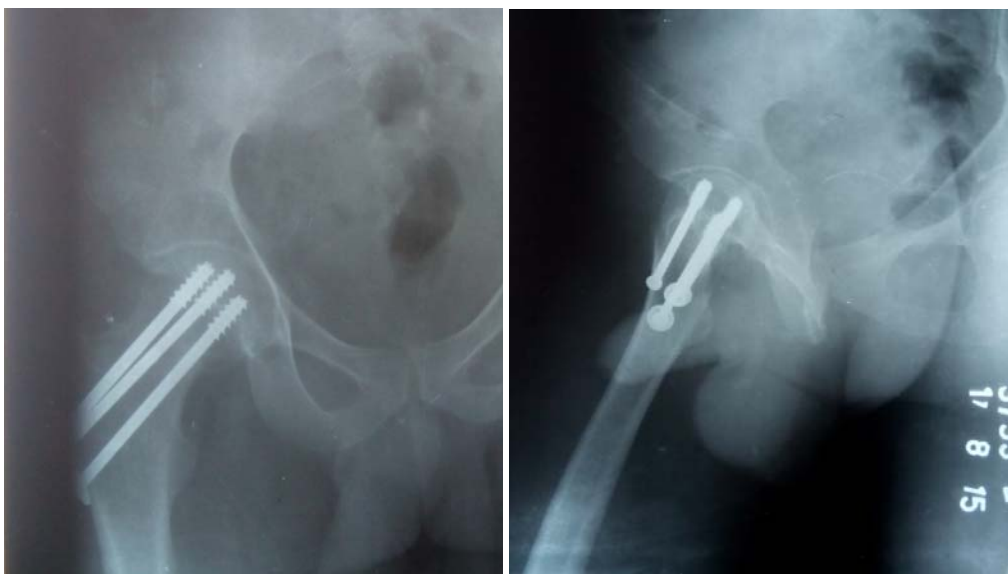**Case 1: (Group A):** 52 yrs old male had history of fall at home presented with Garden,s type IV fracture treated with small diameter dynamic hip screw postoperative period was uneventful was able to squat and sit cross legged at final follow up



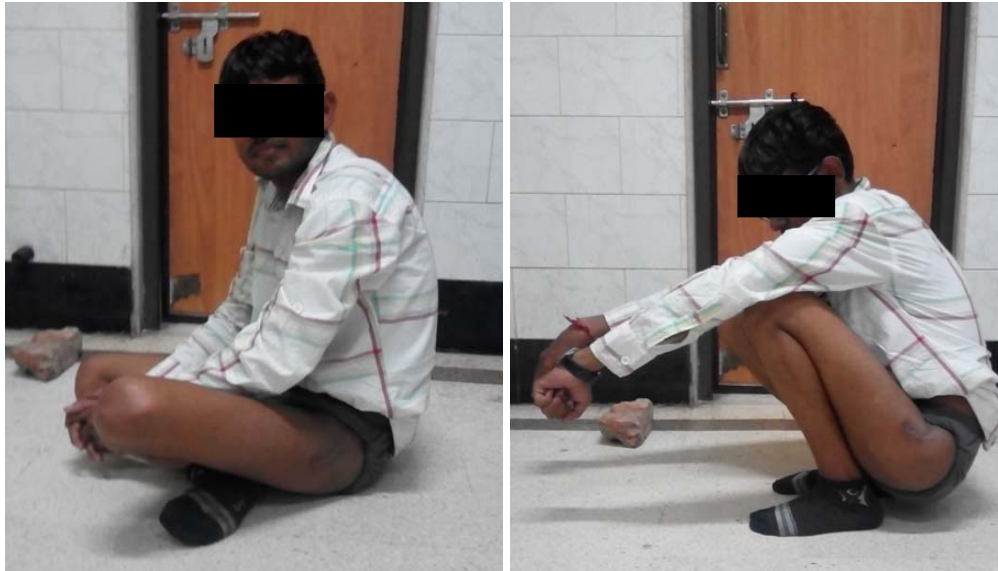Preoperative radiographs



Postoperative radiographs



Radiographs at final follow up



Squatting and sitting cross legged at final follow up

**Case 2(Group B):** 19 yrs old male with history of RTA presented with Garden, s type II fracture treated with three parallel cannulated cancellous screws, postoperative period was uneventful, was able to squat and sit cross legged at final follow up

**Conclusion:** In our study we prospectively compared the radiological and clinical outcomes between the two groups of patients who underwent fixation of fracture neck of femur with Mini DHS and an additional derotation screw versus three cannulated cancellous screws. The findings of the study showed Mini DHS with an additional derotation screw to be as good implant for fixation of fracture neck of femur as three cannulated cancellous screws. The present study showed there is no significant difference in radiological and clinical outcomes of fracture neck of femur fixed with either implant. In our study Mini DHS appeared to have an advantage of shorter duration of surgery and maintainance of normal neck shaft angle but disadvantages of using a larger incision and added blood loss as compared to CCS, while the time taken for radiological union remained almost similar in both the groups.

There were following limitations in our study:

- The number of patients included in this study were small for a proper statistical analysis.
- In addition the follow up period was shorter than many previous studies.
- We could not comment on any evidence of osteonecrosis because of time constraint.

Therefore further long term follow up studies in a large population are required to generalise our results. Admitting that further studies are needed we suggest Mini DHS with an additional derotation screw is a good alternative implant for fixation of fracture neck of femur.

## References

1. Caviglia HA, Osorio PQ, Comando D. Classification and diagnosis of intracapsular fractures of the proximal femur. *Clin Orthop Relat Res.* 2002; 399:17-27.
2. Bjørgul K, Reikerås O. Hemiarthroplasty in worst cases is better than internal fixation in best cases of displaced fracture neck of femur: a prospective study of 683 patients treated with hemiarthroplasty or internal fixation. *Acta Orthop.* 2006; 77(3):368-74.
3. Bjørgul K, Reikerås O. Outcome of undisplaced and moderately displaced fracture neck of femur. *Acta Orthop.* 2007; 78(4):498-504.
4. Raaymakers EL. Fractures of the femoral neck: a review and personal statement. *Acta Chir Orthop Trauma Cech.* 2006; 73(1):45-59.
5. Liporace F, Gaines R, Collinge C, Haidukewych GJ. Results of internal fixation of Pauwels type-3 vertical fracture neck of femur. *J Bone Joint Surg Am.* 2008; 90(8):1654-59.
6. Paus A, Gjengedal E, Hareide A, Jørgensen JJ. Dislocated fractures of the femoral neck treated with von Bahr screws or hip compression screw. Results of a prospective, randomized study. *J Oslo City Hosp.* 1986; 36(5-6):55-61.
7. Dedrick DK, Mackenzie JR, Burney RE. Complications of femoral neck fracture in young adults. *J Trauma.* 1986; 26(10):932-7.
8. Stephen Paget. *Ambroise pare and his times*, G.P. Putnam's sons, 1897, 1510-1590.
9. Senn N. Fractures of the neck of the femur with special reference to bony union after intra-capsular fracture. *Transactions of the American Surgical Association*, 1883; 1:333-41.
10. Lindequist S. Cortical screw support in fracture neck of femur. A radiographic analysis of 87 fractures with a new mensuration technique. *Acta Orthop Scand.* 1993; 64(3):289-93.
11. Deneke DA, Simonian PT, Stankewich CJ, Eckert D, Chapman JR, Tencer AF. Biomechanical comparison of internal fixation techniques for the treatment of unstable basicervical femoral neck fractures. *J Orthop Trauma.* 1997; 11(5):337-43.
12. Orlin Filipov. Epidemiology and social burden of the femoral neck fractures. *Journal of IMAB - Annual Proceeding (Scientific Papers)* 2014; 20(4):516-18.
13. Singh MP, Aditya Aggarwal N, Anil Arora, Ish Dhammi K, Jagjit Singh. Unstable recent intracapsular femoral neck fractures in young adults: Osteosynthesis and primary valgus osteotomy using broad dynamic compression plate. *Indian J Orthop.* 2008; 42(1):43-48.



14. Jain R, Koo M, Kreder HJ, Schemitsch EH, Davey JR, Mahomed NN. Comparison of early and delayed fixation of subcapital hip fractures in patients sixty years of age or less. *J Bone Joint Surg Am.* 2002; 84-A(9):1605-12.
15. Sidhu AS, Walia JPS, Brar BS, Mann HS, Sudhir Punia. A comparative study of 60 cases of intracapsular fracture neck femur treated with multiple cannulated screws and dynamic hip screw *Pb Journal of Orthopaedics,* 2012;13(1):49-52
16. Lee YS, Chen SH, Tsuang YH, Huang HL, Lo TY, Huang CR. Internal fixation of undisplaced femoral neck fractures in the elderly: a retrospective comparison of fixation methods. *J Trauma.* 2008; 64(1):155-62.
17. Razik F, Alexopoulos AS, El-Osta B, Connolly MJ, Brown A, Hassan S *et al.* Time to internal fixation of femoral neck fractures in patients under sixty years-does this matter in the development of osteonecrosis of femoral head? *Int Orthop.* 2012; 36:2127-2132.