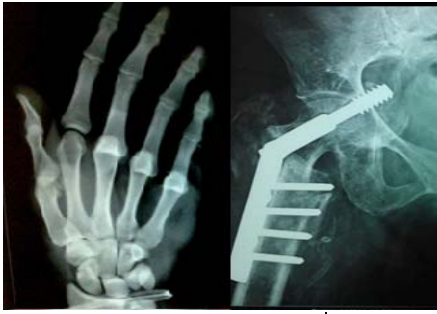



International Journal of Orthopaedics Sciences

ISSN: 2395-1958
IJOS 2017; 3(1): 842-846
© 2017 IJOS
www.orthopaper.com
Received: 17-11-2016
Accepted: 19-12-2016

Ali Towfik Elalfy
Orthopedic Surgery and Trauma
Department, Faculty of
Medicine, Zagazig University,
Assistant Professor of
Orthopedic Surgery Faculty of
Medicine - Zagazig University

Riad Mansour Megahed
Orthopedic Surgery and Trauma
Department, Faculty of
Medicine, Zagazig University,
Assistant Professor of
Orthopedic Surgery Faculty of
Medicine - Zagazig University

Evaluation of the results of arthroscopic double row rotator cuff repair of isolated lesions

Ali Towfik Elalfy and Riad Mansour Megahed

DOI: <http://dx.doi.org/10.22271/ortho.2017.v3.i11.121>

Abstract

Background: Rotator cuff tears are one of the most common soft tissue injuries. The incidence of full thickness tears of the rotators cuff ranges from 5% to 40% of all cuff tears, and increasing in frequency with age. The double row (DR) rotator cuff (RC) repair technique has been developed to optimize healing biology at RC tendon insertion, by increasing pressurized contact area and mean foot print pressure.

Patients and Methods: From 2012 to 2014 forty patients with full thickness rotator cuff tear were selected to undergo arthroscopic DR RC repair. All patients were examined clinically and neurologically after history taking. Plain radiography and MRI were done for all patients. All the operations were done under general anesthesia and in beech chair position. Evaluation of the results of this study based on, the University of California, Los Angeles (UCLA) score and Range of motion (ROM). Secondary outcome measures included a Visual Analogue Scale (VAS) for pain.

Results: At the end of two years follow up, the average UCLA score was improved from 12 preoperative to 29.8 postoperative. The average abduction was improved from 90 degrees preoperative to 145 degrees postoperative. Secondary outcome measures showed that average Visual Analogue Scale for pain was 2.8. And Visual Analogue Scale for patients satisfaction was 8.8 at the end of follow up.

Conclusion: Arthroscopic double row rotator cuff repair is a procedure with good post-operative functional outcome and low complications rate based on a short term follow-up.

Keywords: Double row, rotator cuff repair, and follow-up evaluation

Introduction

Rotator cuff tears are one of the most common soft tissue injuries, typically manifested by pain, weakness in shoulder elevation, and compromised function, the degenerative process constitute the most frequent cause of rotator cuff tears, the reported incidence of full thickness tears of the rotators cuff ranges from 5% to 40% of all cuff tears, and studies clearly show an increasing frequency of cuff failures with advancing age [1]. Recent advances in surgical technique and implants used for arthroscopic rotator cuff repair have gained an interest in the application of arthroscopic rotator cuff repair. However, there is a reported incidence of re-tear in about 25%-40% of cases [2]. Re-tear is disappointing to both the surgeon and the patient. Trials to prevent re-tears led to the introduction of the concept of footprint reconstruction which resulted in the use of double-row (DR) repair [3, 4]. Biomechanically, double-row techniques are superior to single-row with restoring the anatomic footprint, minimizing gap formation, and providing a greater load to failure at time equals zero. The recently described trans osseous equivalent fixation technique provides good footprint restoration, greater contact pressure across the bone-tendon interface and an increased load to failure when compared to double row repair [5]. Although the biomechanical data are promising, clinical studies are still evaluating the efficacy of double-row versus single-row techniques, especially with regard to tendon healing. The potential advantages may be offset by the added surgical time, required and potential increase in the cost [6].

Patients and Methods

This study includes forty patients operated between September 2012 and October 2014, arthroscopic double row rotator cuff repair was done for all patients included in the current study. All patients provided a written informed consent to share in the study and for operation.

Correspondence
Ali Towfik Elalfy
Orthopedic Surgery and Trauma
Department, Faculty of
Medicine, Zagazig University,
Assistant Professor of
Orthopedic Surgery Faculty of
Medicine - Zagazig University

There were 32 patients male and 8 patients females, the right side was affected in 30 patients which are right handed while 10 patients the left shoulder involved in whom 6 patients are left handed while the remaining 4 was right handed. The average age at the time of the operation was 40 (range: 24-55).

Inclusion Criteria

1. Adult patients (male and female) aged from (20-55) years old.
2. All patients provided written informed consent to share in the study.
3. Rotator cuff tears that did not respond to non-surgical treatment.
4. Isolated full-thickness rotator cuff tears.
5. Full passive range of motion of the affected shoulder.

Exclusion Criteria

- 1) Patients’ refusal to share in the study.
- 2) Stiff shoulder.
- 3) Massive, irreparable RC tears.
- 4) Rotator cuff arthropathy.
- 5) Subscapular is tears.
- 6) Fatty degeneration and atrophy of cuff muscles > 50%.
- 7) Associated lesions, as Bankert or slap.

Preoperative assessment

Detailed medical history and data were recorded. Complete physical examinations including neurological assessment. All specialized shoulder tests were performed. All scores were assessed and recorded preoperatively. The ROM was recorded using a standard goniometry. Forward flexion, internal rotation, and external rotation were measured with the shoulder in 90 degrees of abduction in the scapular plane while the ipsilateral forearm was in neutral rotation. Shoulder abduction was also recorded. Pre-operative imaging included standard plain radiographs (Anteroposterior in neutral, external, and internal rotation; and an axillary view) and MRI scans (without

gadolinium enhancement).

Surgical technique

All cases were operated with the patient in the beach chair position under general anesthesia .A standard shoulder arthroscopy instrument, a 30 arthroscope, and an arthroscopic pump set at 50 mm Hg of inflow pressure were used in all cases. Diagnostic arthroscopy was performed firstly through standard Posterior viewing and anterior working portals, then the arthroscope redirected into the sub acromial space. A lateral portal was also established. Excision of hypertrophied bursal tissue to clear the space was carried out, followed by sub acromial decompression using barrel burr (acromioplasty). The footprint on the greater tuberosity was debrided of soft tissue, thus exposing the underlying bone until bleeding surface.

Typically lateral portal (for instrumentation) and superior portal (for Anchor placement) were used for RC repair. The posterolateral accessory portal sometimes used for better visualization of the RC especially in bigger tears. During insertion of the anterior anchors external rotation of the shoulder is required and during application of posterior anchor, internal rotation is required for better showing of footprint A medial Bio-corkscrew anchors (Arthrex, Naples, Florida) introduced into the medial footprint and the Fiber Wire suture passed through the tendon with the Multifire Scorpion (Arthrex, Naples, Florida) Suture Passer. The medial row sutures were tied. Sutures were then passed over the lateral tendon with a Bird Beak fig (4b) suture passer (Arthrex, Naples, Florida) and were secured laterally with two Bio-swivel lock anchors (Arthrex, Naples, Florida).

Repairs were performed with the shoulder abducted up to 30 to minimize tension on the repair .Tensioning of the Fiber wire during second anchor insertion maximizes tendon compression and fixation of the tendon footprint on the tuberosity. A sliding arthroscopic knot is then tied over the recessed heads, locking the construct into place Final repair is viewed and stability of the repair technique is checked figure (4a).

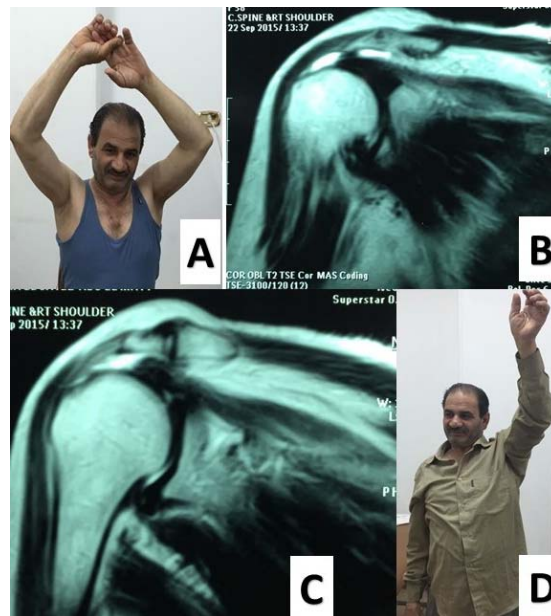


Fig 1: A) Preoperative photo with the patient raising the left arm aided by the right due to tear; B & C) MRI for the patient showing the tear; D) patient photo postoperative raising his left arm independently with good function

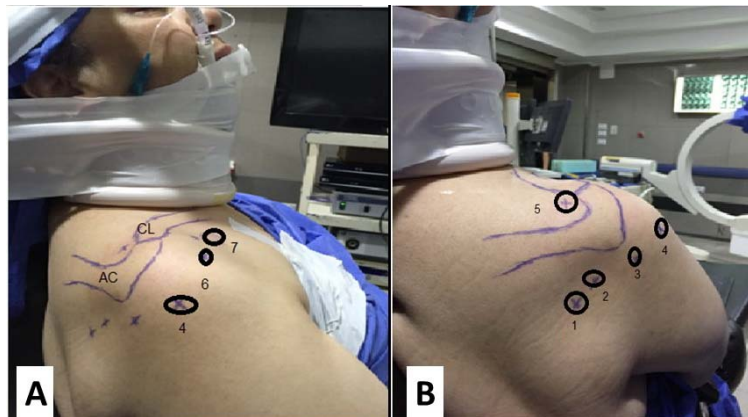


Fig 3: (a) side view of the arthroscopic portals (b) posterior view of the portals 1, 2-standered posterior portals 3-postero lateral portal 4- lateral portal 5-Navesier portal 6-antero-lateral portal 7-antero-superior portal, CL clavicle, AC acromion.

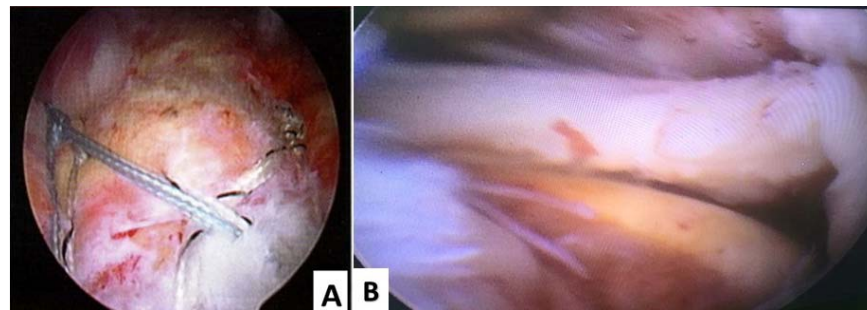


Fig 4: (a, b) arthroscopic view from lateral portal show double row repair.

Table 1: Range of motion pre and postoperative

ROM	Preoperative	Postoperative	p-value significance
	(N=40)	(N=40)	
Forward Flexion (Range)	130 (60 – 180)	160 (80 – 180)	0.001(S)
Abduction (Range)	90 (60 – 180)	150 (70 – 180)	0.001(S)
External Rotation at 90° abduction(Range)	60 (0 – 90)	77.50 (45 – 100)	0.001(S)
Internal Rotation at 90° abduction (Range)	49 (0 – 90)	60 (20 – 90)	0.374(NS)

S: significant- NS: non-significant- HS: high significant

Table 2: Pre and postoperative pain and UCLA score.

Clinical data	Preoperative		Postoperative		p-value significance
	(N=40)		(N=40)		
	No.	%	No.	%	
Pain (Range)					
	8 (5 – 10)		3 (0 – 10)		<0.001 (HS)
UCLA score					
(Range)	12.50 (8 – 20)		29 (25 – 35)		<0.001 (HS)
Poor	25	62.5%	0	0%	
Fair	15	37.5%	4	10%	
Good	0	0%	20	50%	
Excellent	0	0%	16	40%	

Post-operative care

All patients were given instructions regarding the use of sling, daily activities, axillary hygiene, movements, and functional activities to be avoided, all patients used an abduction sling for four weeks then started a rehabilitation program. Patients were followed up every 2 weeks for the first 2 months and then once a month until the sixth month after surgery. The following scores were used at 24 month post-operative: UCLA score, VAS for pain, VAS for patient satisfaction in addition to the range of motion assessment.

Results

All patients were available for the follow-up evaluation 24 months post-operative. Primary outcome measures included the University of California, Los Angeles (UCLA) score [7], and Range of motion (ROM). All patients were reviewed pre- and post-operatively Visual Analogue Scale (VAS) for pain, another VAS for patient satisfaction from the operative procedure. Operative time, length of stay in hospital, pre-operative duration of symptoms, pattern and size of RC tear, and complications were recorded.

The average age of patients was 40 (24-55) years old average pre-operative duration of symptoms was 8 months (3-24) month. Average post-operative hospital stay was 30 hours (Range 24-48).

All RC tears of patients included in the study were full-thickness tears. Measured intra-operatively using a graded Arthroscopic probe, the mean size of tears was 2.7 ± 1.7 cm 30 cases were medium size tears 10 cases were large size tears while the largest tear measured 4 cm, The smallest tear measured 0.5 to 1cm. Tear shapes were U-shaped in 14 cases or crescent-shaped in 18 cases, while 8 tears were L-shaped. At 24 months post-operative, measures revealed that average UCLA score was 12.10 ± 3.16 , average forward flexion was 130, average external rotation was 60 and average abduction was 90, average internal rotation was 49, and average VAS for pain was 8 (Table 2).

Comparing the results of the primary outcome measures pre-operative and at the time of follow-up evaluation 24 months post-surgery showed significant improvement in average UCLA score see (table 2), Comparing pre-operative range of motion and the range of motion at the time of follow-up evaluation, the average forward flexion, average abduction, and average external rotation improved significantly see (Table 1). However, average internal rotation did not improve significantly at the time of follow-up evaluation. Comparing the pre-operative results of the secondary out-come measures and at the time of follow-up showed that average VAS for pain improved significantly, only one patient experienced superficial infection which was successfully treated with antibiotics.

Discussion

For improving healing, rotator cuff repair techniques have evolved to create a stronger biomechanical construct. Double-row RC repair techniques added a row of suture anchor fixation lateral to the conventionally placed medial row that had been the standard fixation technique for arthroscopic rotator cuff repairs. Biomechanical studies showed increased load to failure, improved contact areas and pressures and decreased gap formation at the tendon-bone interface with double-row constructs [1-3].

Sugaya et al [8], published their results of a prospective outcome study of 106 patients who underwent double-row suture anchor repair of full-thickness rotator cuff tears In 86 patients with good postoperative follow-up, functional results were assessed with the UCLA and American Shoulder and Elbow Society (ASES) tools at a mean of 31 months. Structural integrity of the repair was evaluated at a mean of 14 months postoperatively significant improvement in clinical outcome scores was noted at final follow-up. The overall re-tear rate was 17%, which occurred in patients with large and massive tears (40% recurrence). Correspondingly inferior functional strength and overall out-come scores were observed in the subgroup with large tear (3 to 5 cm or massive tear ≥ 5 cm) [8].

Park *et al* [9] recently compared clinical results of single-row versus double-row rotator cuff repair. Forty patients underwent single-row repair, and the next 38 patients underwent double-row fixation. At 2 years postoperatively, ASES Constant, and Shoulder Strength Index outcome scores were significantly improved in both groups, but no significant difference was found between the groups. When the comparison was subdivided based on tear size, functional outcome scores were significantly better with double-row fixation for large or massive tears (>3 cm). They concluded that double-row repair techniques may have a clinically relevant role in the treatment of large to massive rotator cuff tears However, the conclusions

are limited by small experimental groups, lack of randomization, lack of a standardized surgical protocol for single-row repair, and absence of structural evaluation of the repair integrity in the experimental design [9].

Anderson et al [10] published a case Series of 48 patients (52 shoulders who underwent double-row suture anchor repair of full-thickness rotator cuff tears. The average tear size was 2.47 cm. Postoperative evaluation included functional assessment clinical examination, strength testing, and ultrasonography. At a mean follow-up of 30 months, ultrasonography revealed a 17% rate of re-tear or persistent defect.

Patients with intact repairs had significantly improved strength in elevation and external rotation [10].

Park et al; and Carbonel et al. showed significant improvement of the results in patients who underwent double-row repair compared to those who underwent single-row repair, when used in patients with large to massive tears (3cm). On the other hand, there was no difference between the repair techniques in patients with small to medium tears [9-11]. Huijsmans et al showed the results of double-row rotator cuff repair using a modified interlocking suture technique in 264 patients, 238 of whom were available for follow-up. At final follow-up, 90% of patients had (good to excellent) functional outcomes, and 82.9% had an intact repair as assessed on ultrasonography [12].

The data looks to support expected healing with either single-row or double-row repairs for small and Medium-sized tears. The potential benefit of double-row repairs may lie in improved outcomes with large and massive tears. Larger prospective randomized studies that include clinical assessments and that take tear size into account are necessary to determine the true efficacy of double-row repair techniques. The outcome of our study was that DR RC repair showed significantly improved functional scores at 24 months post-operative. The average UCLA score was 31, average forward flexion was 165, average abduction was 145, average external rotation was 78 Average internal rotation was 55, VAS for pain was 2.8; which nearly similar to the results of the previously mentioned studies.

The complications in our study were no re-tear symptoms as pain or weakness were reported until the time of the follow-up evaluation (24 months). Only one case of superficial infection was successfully treated with antibiotics No other musculoskeletal complications, including neurological injuries, deep infections and anchor pull-outs, were reported points of strength of our study as 100% follow up; and range of motion assessment.

The limitations of this study was first: the deficiency of follow-up MRI scans to assess the integrity of the RC repairs were used. This was not possible because of the associated high costs and the patients refused due to feeling of good functions. The second limitation was short follow-up; however, as soft-tissue healing can be considered to be complete by 12 months would be a sufficient follow-up period. Re-tears not occurred in this study maybe due to the small number of cases included in this study and short follow up.

Conclusion: Arthroscopic double row rotator cuff repair is a procedure with good post-operative results and low complications rate based on a short term follow-up.

References

1. Wirth MA, Basamania C, Rockwood CA. Nonoperative management of full thickness tears of the rotators cuff. *Orthop Clin North Am.* 1997; 28:59-67.
2. Burkhart SS, Lo IK. Arthroscopic rotator cuff repair; *J Am Acad Orthop Surg.* 2006; 14(6):333-46.

3. Accousti KJ, Flatow EL. Technical pearls on how to maximize healing of the rotator cuff. Instructional course lectures. 2007; 56:3-12.
4. Lafosse L, Boyle S. Arthroscopic Latarjet procedure. *J Shoulder Elbow Surg*, 2010; 19:2-12.
5. Imam MA, Ashraf A. Outcomes following arthroscopic transosseous equivalent suture bridge double row rotator cuff repair: a prospective study and short-term results; *SICOT J*, 2016; 2:7. doi: 10.1051/sicotj/2015041.
6. Ferry AT, Provencher MT, Yanke AM. Double-Row Rotator Cuff Repairs: Biomechanical Rationale and Surgical Techniques, *Techniques in Shoulder & Elbow Surgery*. 2008; 9(1):1-9.
7. Kirkley A, Griffin S, Dainty K. Scoring systems for the functional assessment of the shoulder. *Arthroscopy*. 2003; 19(10):1120-1109.
8. Sugaya H, Maeda K, Matsuki K, Moriishi J. Repair integrity and functional outcome after arthroscopic double-row rotator cuff repair: A prospective outcome study; *Bone Joint Surg Am*. 2007; 89:953-96.
9. Park JY, Lhee SH, Choi JH, Park HK, Yu JW, Seo JB. Comparison of the clinical outcomes of single- and double-row repairs in rotator cuff tears. *Am J Sports Med*. 2008; 36:1310-1316.
10. Anderson K, Boothby M, Aschenbrenner D, van Holsbeeck M. Outcome and structural integrity after arthroscopic rotator cuff repair using 2 rows fixation: Minimum 2-year follow up. *AJ Sports Med*. 2006; 34:1899-1905.
11. Carbonel I, Martinez AA, Calvo A, Ripalda J, Herrera A. Single-row versus double-row arthroscopic repair in the treatment of rotator cuff tears: a prospective randomized clinical study. *Int Orthop*. 2012; 36(9):1877-1883.
12. Huijsmans PE, Pritchard MP, Berghs BM, van Rooyen KS, Wallace AL, Beer JF. Arthroscopic rotator cuff repair with double-row fixation *Bone Joint Surg Am*. 2007; 89:1248-1257.