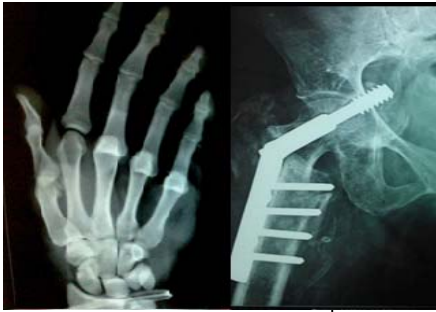



International Journal of Orthopaedics Sciences

ISSN: 2395-1958
IJOS 2017; 3(1): 587-590
© 2017 IJOS
www.orthopaper.com
Received: 26-11-2016
Accepted: 27-12-2016

Chaudhary P
Additional Professor,
Department of Orthopaedics,
BPKIHS, Dharan, Nepal

Khanal GP
Department of Orthopaedics,
B.P. Koirala Institute of Health
Sciences, Dharan, Nepal

Rijal R
Department of Orthopaedics,
B.P. Koirala Institute of Health
Sciences, Dharan, Nepal

Maharjan R
Department of Orthopaedics,
B.P. Koirala Institute of Health
Sciences, Dharan, Nepal

Paneru S
Department of Orthopaedics,
B.P. Koirala Institute of Health
Sciences, Dharan, Nepal

Kalawar RPS
Department of Orthopaedics,
B.P. Koirala Institute of Health
Sciences, Dharan, Nepal

Pokharel B
Department of Orthopaedics,
B.P. Koirala Institute of Health
Sciences, Dharan, Nepal

Gupta MK
Department of Orthopaedics,
B.P. Koirala Institute of Health
Sciences, Dharan, Nepal

Correspondence
Dr. Pashupati Chaudhary
Additional Professor,
Department of Orthopaedics,
BPKIHS, Dharan, Nepal

Cervical myelopathy treatment options at BPKIHS-A tertiary care center

Chaudhary P, Khanal GP, Rijal R, Maharjan R, Paneru S, Kalawar RPS, Pokharel B and Gupta MK

DOI: <http://dx.doi.org/10.22271/ortho.2017.v3.i1.86>

Abstract

Background: The goal of surgery for cervical spondylotic myelopathy (CSM) is to open the space for the spinal cord. There are many successful surgical techniques for treating CSM. The goal of surgery is to open the space for the spinal cord, or "decompress" the spinal canal. The decompression is performed either from the front of your neck (anterior) or the back (posterior). Each approach has its advantages and disadvantages.

Aim and Objective: To manage the cervical myelopathy by different surgical techniques presented to department of Orthopaedics, BPKIHS, Dharan.

Materials and methods: This is retrospective interventional study done at the department of Orthopaedics, BPKIHS, Dharan, Nepal over a period of 2 years from March 2012 to April 2014. A total of 15 patients with cervical myelopathy were treated by different surgical technique. The patient's age ranged from 50 to 65 years and the mean follow-up was 12 weeks.

Results: The study comprised of 55 patients with cervical spine injuries were treated by pedicle screw. The age incidence in this series ranged from 20 years to 60 years. 40 patients were males and 20 was female.

Discussion: The primary goal of surgery for CSM, regardless of approach, is to stabilize the spine and prevent neurologic problems from getting worse. The goal is not necessarily to restore normal function. A secondary goal is potentially improving the associated neck pain, motor (weakness), sensory (numbness/tingling), and gait (walking) disturbances. Final outcomes from the surgery vary. Typically, one-third of patients improve, one-third stay the same, and one-third continue to worsen over time, with respect to their pre-surgical symptoms. Elderly patients have higher rates of complications from surgery. So do overweight patients, diabetics, smokers, and patients with multiple medical problems.

Conclusion: People with CSM are recommended for surgery to make sure that their symptoms do not get worse.

Keywords: Cervical pedicle screw, lower cervical spine, lateral mass

1. Introduction

Cervical Myelopathy refers to the narrowing of the spinal canal of the vertebral column in the neck from osteoarthritis and the damage to the spinal cord that may result from this. It is an important disease of the aged. It develops insidiously and is often either not noted for some time or ascribed to other, more harmless conditions. Cervical Myelopathy are usually over 50 years of age and progressive loss of function, Pin-and-needles in the hands, Stiff ness and insecure gait in the legs, significant impairment of function may result. Early recognition is important.

Cervical Myelopathy commonly caused by arthritis in the neck or degenerative changes in the discs. Symptoms include painful stiff neck, radiculitis, clumsiness while walking, Can lead to permanent nerve or spinal cord damage if untreated. The goal of surgery for cervical spondylotic myelopathy (CSM) is to open the space for the spinal cord (decompress) the spinal canal. The decompression is performed either from the front of your neck (anterior) or the back (posterior). Each approach has its advantages and disadvantages

1.1 Surgical treatment

Surgery is the most reliable way of removing the compression on the spinal cord.

This compression is in its essence physical and can therefore be dealt with best by physical i.e. surgical means. Factors which would mitigate towards an operation would be: severe disability, a relentlessly progressive course (40%– 75%), a rapid deterioration of the myelopathy, a significant instability between two vertebrae on plain flexion – extension X-ray films: a shift of more than 3 mm, particularly if this can be shown to have increased with time would suggest surgical instability, a more marked narrowing of the canal on imaging (> 30% narrowing), a “banana” shaped deformity of the cord on MRI, a marked increased signal in the cord on MRI, markedly abnormal somato-sensory evoked potentials, the absence of contra-indication, like significant co-morbidity and substantial remaining life-expectancy.

1.3 Aim and Objectives

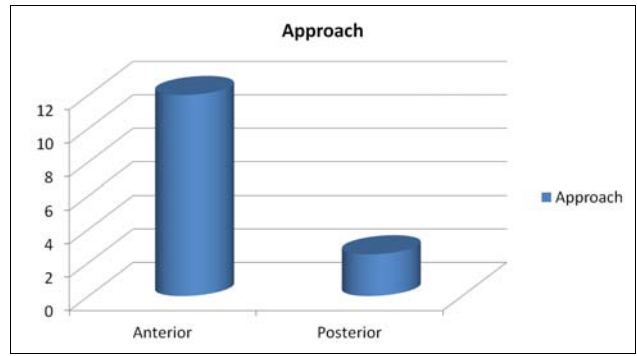
To manage the cervical myelopathy by different surgical techniques presented to department of Orthopaedics, BPKIHS, Dharan

2. Materials and methods

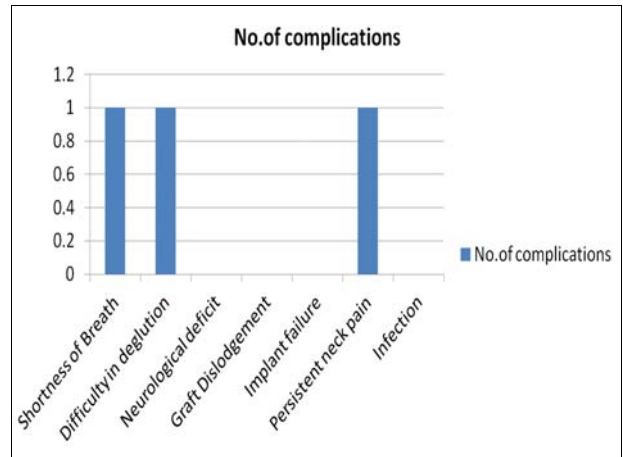
This is a retrospective interventional study done at the department of Orthopaedics, BPKIHS, Dharan, Nepal over a period of 2 years from March 2012 to April 2014. A total of 15 patients with cervical myelopathy were treated by different surgical techniques. The patient’s age ranged from 50 to 65 years. The mean follow-up was 12 weeks. A total of 15 patients with cervical myelopathy were treated by different surgical technique. The patient’s age ranged from 50 to 65 years. The mean follow-up was 12 weeks.

3. Results

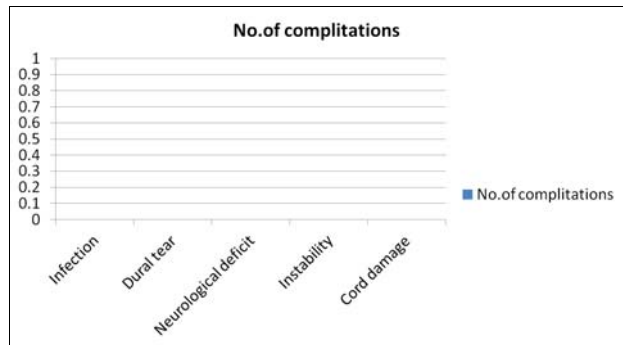
The study comprised of 15 patients with cervical spine injuries were treated by pedicle screw. The age range was 50-65 years. 9 males and 6 females were included in the study. 12 were operated with anterior approach and 3 from posterior approach. Few complications noted in anterior approach but none in posterior approach



Complications, Anterior Approach



Complications, Poateral Approach



Intra-Operative/ Post -operative Pics

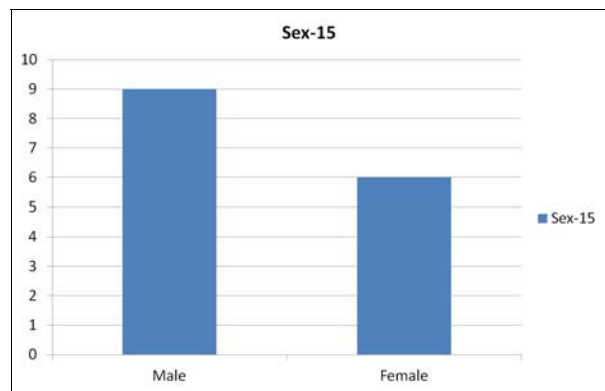
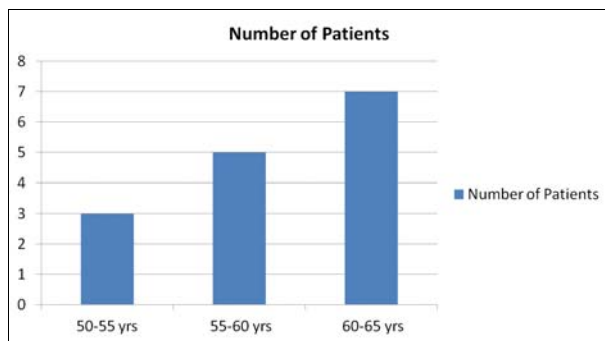
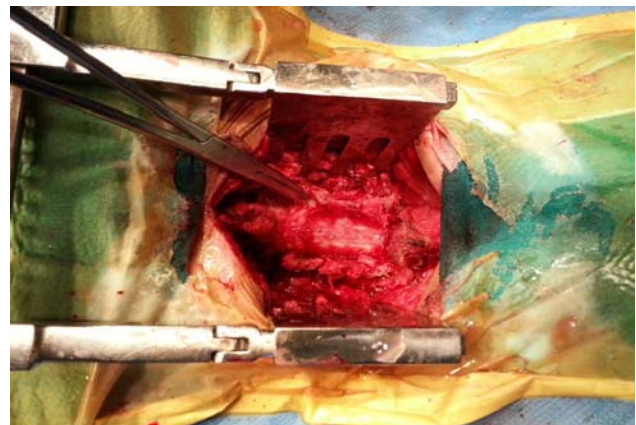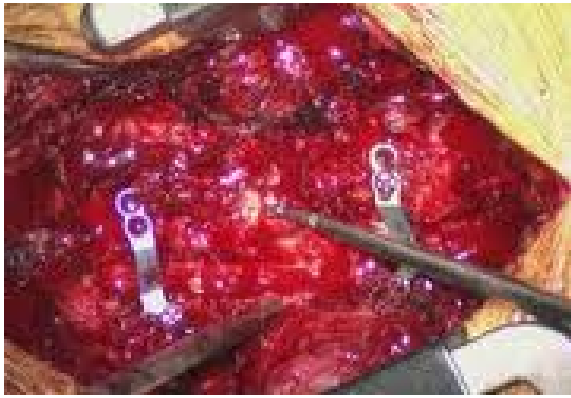




Fig 1

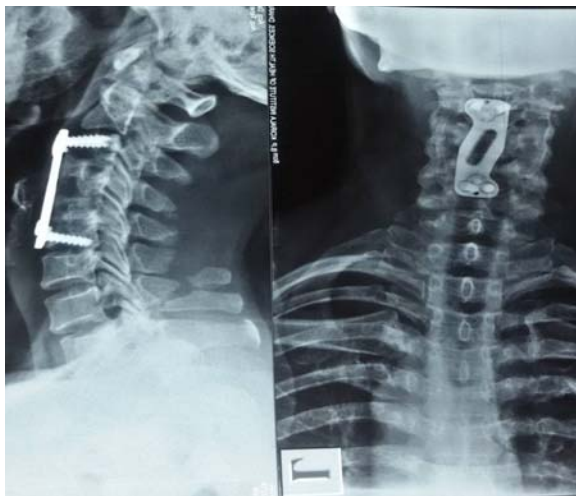
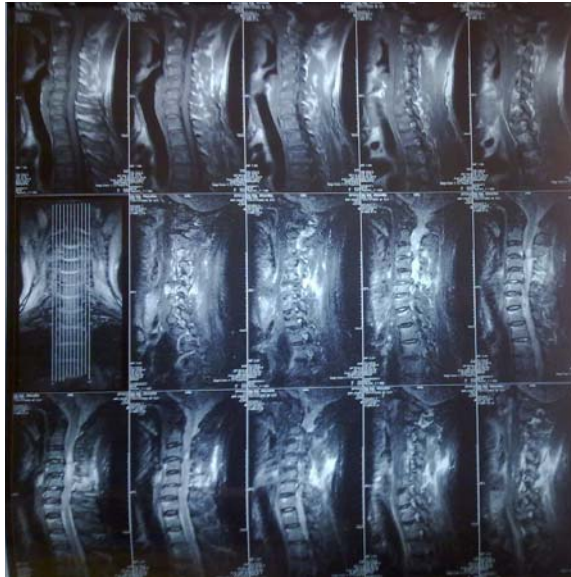
Fig 2

4. Discussion

Choosing the right patient for a surgical procedure is as important as the expert performance of the operative technique itself. "Going after the pathology" dictates whether an anterior or posterior approach should be utilized. However, for patients in whom there is a loss of the normal lordotic curvature and cervical canal stenosis, posterior decompression alone can lead to progression of kyphosis and does not improve myelopathy. The need for extensive anterior or posterior decompression

alone can lead to postoperative instability and progressive myelopathy, as well.

Several studies have shown that anterior cervical corpectomy or discectomy at more than one level is associated with decreased fusion rates and structural construct dislodgement. Presumably, this is because the number of surfaces requiring fusion increases with the number of levels of discectomy, thereby reducing the probability of adequate fusion. Circumferential cervical fusion has been shown to be beneficial in ameliorating the increased incidence of failure with anterior corpectomy and fusion involving more than two levels and in decreasing anterior strut-graft dislodgement. Therefore, anterior decompression of more than three levels should be accompanied by posterior stabilization.

Degenerative disease with instability adjacent to prior fusions has been an increasingly recognized phenomenon. This has been reported to occur in 3% of patients undergoing spinal fusion, with the adjacent disease most often occurring at C5–6 and C6–7. In our series we had three patients who required extension of a prior fusion due to adjacent-level disease. The use of dynamic anterior plates has decreased the incidence of strut-graft dislodgement seen with static anterior plates and buttress plates without posterior fusion; therefore, we exclusively use dynamic plating.

We prefer to place lateral mass screws in the cervical spine from C2–C6 with bicortical purchase and pedicle screws in C7 and the upper thoracic spine. For C7 and upper-thoracic screws.

We prefer to perform circumferential cervical fusion in one stage whenever possible. Nevertheless, in select patients with comorbidities that would put them at significant risk with increase in operative length, it is safer to stage the procedure. We do not routinely recommend the use of external halo stabilization after circumferential fusion unless there is significant concern regarding the stability of the fusion due to a history of previous non-fusion, severe deformity, or a fusion spanning several levels is performed where significant strain will be placed on the hardware. Epstein reported the use of halo stabilization in all patients, likely due to the use of posterior interlaminar wiring as opposed to screw and rod instrumentation. Halo immobilization is uncomfortable for patients, has associated complications and morbidity, and, in our opinion, is unnecessary in most cases.

The primary goal of surgery for CSM, regardless of approach, is to stabilize the spine and prevent neurologic problems from getting worse. It is not necessary to restore normal function. A secondary goal is potentially improving the associated neck pain, motor (weakness), sensory (numbness/tingling), and gait (walking) disturbances. Final outcomes from the surgery vary. Typically, one-third of patients improve, one-third stay the same, and one-third continue to worsen over time, with respect to their pre-surgical symptoms. Higher rates of complications: Elderly patients, overweight patients, diabetics, smokers, and patients with multiple medical problems.

The study comprised of 15 patients with cervical spine injuries were treated by pedicle screw. The age range was 50-65 years. 9 males and 6 females were included in the study. 12 were operated with anterior approach and 3 from posterior approach. Few complications noted in anterior approach but none in posterior approach

5. Conclusion

People with CSM are recommended for surgery to make sure that their symptoms do not get worse. Surgery is relatively safe and effective. No need to be unreasonably scared.

6. References

1. Baba H, Furusawa N, Imura S. Late radiographic findings after anterior cervical fusion for spondylotic myeloradiculopathy. *Spine*. 1993; 18:2167-2173. doi: 10.1097/00007632-199311000-00004.
2. Deutsch H, Haid RW, Rodts GE. Postlaminectomy cervical deformity. *Neurosurg Focus*. 2003; 15:E5
3. Dvorak J, Sutter M, Herdmann J. Cervical myelopathy: clinical and neurophysiological evaluation. *Eur Spine J*. 2003; 12(2):S181-S187. doi: 10.1007/s00586-003-0631-y.
4. Edwards CC, Riew KD, Anderson PA. Cervical myelopathy: current diagnostic and treatment strategies. *Spine J*. 2003; 3:68-81. doi: 10.1016/S1529-9430(02)00566-1.
5. Eleraky MA, Llanos C, Sonntag VK. Cervical corpectomy: report of 185 cases and review of the literature. *J Neurosurg Spine*. 1999; 90:35-41.
6. Epstein NE. Anterior cervical discectomy and fusion without plate instrumentation in 178 patients. *J Spinal Disord*. 2000; 13:1-8. doi: 10.1097/00002517-200002000-00001.
7. Epstein NE. Circumferential cervical surgery for ossification of the posterior longitudinal ligament: a multianalytic outcome study. *Spine*. 2004; 29:1340-1345. doi: 10.1097/01.BRS.0000127195.35180.08
8. Freeman BJ, Licina P, Mehdian SH. Posterior lumbar interbody fusion combined with instrumented posterolateral fusion: 5-year results in 60 patients. *Eur Spine J*. 2000; 9:42-46. doi: 10.1007/s005860050007
9. Gertzbein SD, Betz R, Clements D. Semirigid instrumentation in the management of lumbar spinal conditions combined with circumferential fusion. A multicenter study. *Spine*. 1996; 21:1918-1925. Discussion 1925-1926.
10. Gertzbein SD, Holloper MR, Hall S. Pseudarthrosis of the lumbar spine. Outcome after circumferential fusion. *Spine*. 1998; 23:2352-2356, discussion 2356-2357.
11. Grob D, Scheier HJ, Dvorak J. Circumferential fusion of the lumbar and lumbosacral spine. *Arch Orthop Trauma Surg*. 1991a; 111:20-25. doi: 10.1007/BF00390187.
12. Grob D, Scheier HJ, Dvorak J. Circumferential fusion of the lumbar and lumbosacral spine: comparison of two techniques of anterior spinal fusion. *Chir Organi Mov*. 1991b; 76:123-131.
13. Herman JM, Sonntag VK. Cervical corpectomy and plate fixation for postlaminectomy kyphosis. *J Neurosurg*. 1994; 80:963-970
14. Hilibrand AS, Carlson GD, Palumbo MA. Radiculopathy and myelopathy at segments adjacent to the site of a previous anterior cervical arthrodesis. *J Bone Joint Surg Am*. 1999; 81:519-528.
15. Huang RC, Girardi FP, Poynton AR. Treatment of multilevel cervical spondylotic myeloradiculopathy with posterior decompression and fusion with lateral mass plate fixation and local bone graft. *J Spinal Disord Tech*. 2003; 16:123-129. doi: 10.1097/00024720-200310000-00001.
16. Kadanka Z, Bednarik J, Vohanka S. Conservative treatment versus surgery in spondylotic cervical myelopathy: a prospective randomised study. *Eur Spine J*. 2000; 9:538-544, discussion 545-546
17. Mayr MT, Subach BR, Comey CH. Cervical spinal stenosis: outcome after anterior corpectomy, allograft reconstruction, and instrumentation. *J Neurosurg Spine*. 2002; 96:10-16. doi: 10.3171/spi.2002.96.1.0010.
18. Nurick S. The natural history and the results of surgical treatment of the spinal cord disorder associated with cervical spondylosis. *Brain*. 1972; 95:101-108. doi: 10.1093/brain/95.1.101.
19. Schnee CL, Freese A, Weil RJ, Marcotte PJ. Analysis of harvest morbidity and radiographic outcome using autograft for anterior cervical fusion. *Spine*. 1997; 22:2222-2227. doi: 10.1097/00007632-199710010-00005.
20. Schultz KD, McLaughlin MR, Haid RW. Single-stage anterior-posterior decompression and stabilization for complex cervical spine disorders. *J Neurosurg Spine*. 2000; 93:214-221.
21. Sebastian C, Raya JP, Ortega M. Intraoperative control by somatosensory evoked potentials in the treatment of cervical myeloradiculopathy. Results in 210 cases. *Eur Spine J*. 1997; 6:316-323. doi: 10.1007/BF01142677.
22. Singh K, Vaccaro AR, Kim J. Biomechanical comparison of cervical spine reconstructive techniques after a multilevel corpectomy of the cervical spine. *Spine*. 2003; 28:2352-2358, discussion 2358
23. Slosar PJ, Reynolds JB, Schofferman J. Patient satisfaction after circumferential lumbar fusion. *Spine*. 2000; 25:722-726. doi:10.1097/00007632-200003150-00012.
24. Smith-Hammond CA, New KC, Pietrobon R. Prospective analysis of incidence and risk factors of dysphagia in spine surgery patients: comparison of anterior cervical, posterior cervical, and lumbar procedures. *Spine*. 2004; 29:1441-1446. doi: 10.1097/01.BRS.0000129100.59913.EA.
25. Steinmetz MP, Miller J, Warbel A, Krishnaney AA, Bingaman W, Benzel EC. Regional instability following cervicothoracic junction surgery. *J Neurosurg Spine*. 2006; 4:278-284.