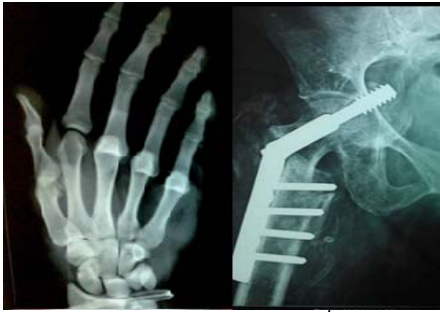



## International Journal of Orthopaedics Sciences

ISSN: 2395-1958  
IJOS 2017; 3(1): 431-434  
© 2017 IJOS  
www.orthopaper.com  
Received: 02-11-2016  
Accepted: 03-12-2016

**Dr. Namdev Parshuram June**  
Assistant Professor, Department  
of Orthopedics, Swai Ramanand  
Teerth Rural Medical College  
and Hospital, Ambajogai,  
Maharashtra, India

**Dr. Ajay MB**  
Consultant Orthopedic Surgeon,  
Puttur, Karnataka, India

### Functional and radiological outcome of operative management of fractures of distal end of radius with locking compression plates

**Dr. Namdev Parshuram June and Dr. Ajay MB**

**DOI:** <http://dx.doi.org/10.22271/ortho.2017.v3.i1f.62>

#### Abstract

**Introduction:** Closed reduction and cast immobilization has been the mainstay of treatment of these fractures but malunion of fracture and subluxation/dislocation of distal radioulnar joint resulting in poor functional and cosmetic results is the usual outcome. The residual deformity of the wrist adversely affects wrist motion and hand function by interfering with the mechanical advantage of extrinsic hand musculature.

**Methodology:** This prospective study was conducted in patients on intra-articular distal end of radius fractures treated with volar locking plate in department of orthopedics. Twenty adult patients were included in this study.

**Results:** LCP with combination holes gives surgeons the opportunity to combine the principles of internal fixation and dynamic compression.

**Conclusion:** Recent studies indicates that the pitfalls faced due to a LCP system have nothing to do with the implant but is attributed to the nonobservation of important basic principles of the concept of biological osteosynthesis.

**Keywords:** Radius, functional outcome, compression plate

#### Introduction

Fractures of the distal end of radius are the most common fractures of the upper extremity. It constitutes about 75% of all forearm fractures. The classic fracture described by SIR ABRAHAM COLLES in 1814 - low energy, extra articular, osteoporotic distal radius fracture - often does well with closed reduction and cast immobilization. High velocity injuries have resulted in severely comminuted and unstable fractures with intra articular components.

Many methods like closed reduction and casting, pins and plaster, percutaneous pinning, external fixation with ligamentotaxis, internal fixation, combined internal and external fixation and arthroscopically assisted reduction have come up<sup>[1]</sup>.

In a young, active individual with a severely comminuted fracture, acceptable closed reduction may be achieved easily but difficult to maintain. When reduction is lost, a shortened, dorsally angulated carpus with subsequent poor function and early osteoarthritis secondary to articular incongruity may occur.

Closed reduction and cast immobilization has been the mainstay of treatment of these fractures but malunion of fracture and subluxation/dislocation of distal radioulnar joint resulting in poor functional and cosmetic results is the usual outcome. The residual deformity of the wrist adversely affects wrist motion and hand function by interfering with the mechanical advantage of extrinsic hand musculature. It may cause pain, limitation of forearm motion and decreased grip strength as a result of arthrosis of the radiocarpal and distal radioulnar joints<sup>[2]</sup>.

As open reduction and plating ensures more consistent correction of displacement and maintenance of reduction, this study evaluates the anatomical and functional outcome of open reduction and plate fixation in the management of unstable fracture distal end of radius in twenty patients.

Internal fixation of metaphyseal bending fractures has become increasingly popular primarily due to

- Directly control and maintain physiologic palmar tilt.
- Prevent collapse with external fixation.
- Avoid bridging the radiocarpal joint.

#### Correspondence

**Dr. Ajay MB**  
Consultant Orthopedic Surgeon,  
Puttur, Karnataka, India

The distal fragment typically has sufficient size and integrity to provide adequate purchase and may be approached from either a dorsal or a volar approach. Palmar plating is preferred, as the screws directly buttress against collapse and loss of palmar tilt.

There are two types of plates for fractures of distal radius

- a) Conventional plates.
- b) Fixed angle locking compression plates.

When using conventional plates, comminution must be less, they poorly hold the cancellous bone fragments, toggle of screws in the distal holes of the plate leads to settling and loss of reduction.

With conventional plates and screws stability is achieved by compression of plate to bone by bicortical screws. With fixed angle locking plates the locking screws support subchondral bone and resist axial forces. Compression of locking compression plate to bone is unnecessary and preserves periosteal blood supply. Fixed angle construct provides additional strength to fixation by constructing a scaffold under the distal radial articular surface<sup>[3]</sup>.

Volar fixed angle locking plates are an effective treatment for unstable extra articular distal radius fractures allowing early post-operative rehabilitation. Because of angular stability of locking compression plates, reduction can be maintained over times so that secondary displacement is no longer a problem. Primary stability achieved with locking screw in a plate prevents secondary displacement irrespective of the bone enabling good results in osteoporotic bones and young patients.

### Methodology

This prospective study was conducted in patients on intra-articular distal end of radius fractures treated with volar locking plate in department of orthopedics. Twenty adult patients were included in this study.

### Inclusion Criteria

Adults (aged over 18years), both male and female with unstable, comminuted or intra articular fractures of distal end radius Patients willing for treatment and given- informed written consent.

### Exclusion Criteria

- ✓ Patients aged below 18years
- ✓ Patients medically unfit for surgery
- ✓ Compound fractures associated with vascular injuries
- ✓ Patients not willing for surgery

### Prediction of instability

- 1) The age of the patient: patients over 80 years of age with a displaced fracture of the distal radius are three times more likely to have instability than those less than 30 years of age. This is even more striking in patients with minimally or undisplaced fractures when the risk of instability increases tenfold in older patients. Fractures in elderly patients with osteopenic bones may also displace at a later stage.

- 2) The initial displacement of the fracture: The greater the degree of initial displacement (particularly radial shortening), the more energy is imparted to the fracture resulting in a higher likelihood that closed treatment will be unsuccessful.
- 3) The extent of metaphyseal comminution as evidenced by either plain radiographs or computerized tomography.
- 4) Displacement following closed treatment is a predictor of instability, and repeat manipulation is unlikely to result in a successful radiographic outcome.

### Indications for operative intervention

- ✓ Predicted or established metaphyseal instability
- ✓ Comminuted displaced intra-articular fracture
- ✓ Open fractures
- ✓ Associated carpal fractures
- ✓ Associated neurovascular injury/ tendon injury
- ✓ Bilateral fractures
- ✓ Impaired contralateral extremity

### Pre-operative evaluation

#### Immediate Management

Following admission to the hospital, a careful history was elicited from the patients and / or attendants to reveal the mechanism of injury and the severity of trauma.

All patients were thoroughly examined. Their general condition associated systemic diseases and associated injuries were noted. All the findings were duly recorded in the patient proforma.

All patients presented with the involved elbow flexed and the wrist supported by the other hand. Careful inspection of the deformity, swelling and ecchymosis were done.

Clinically tenderness, bony irregularity, crepitus and the relative position of radial and ulnar styloid process were elicited. Movements of the wrist and forearm were checked and found to be painful and limited. Distal vascularity was assessed by radial artery pulsations, capillary filling, pallor and paraesthesia over finger tips.

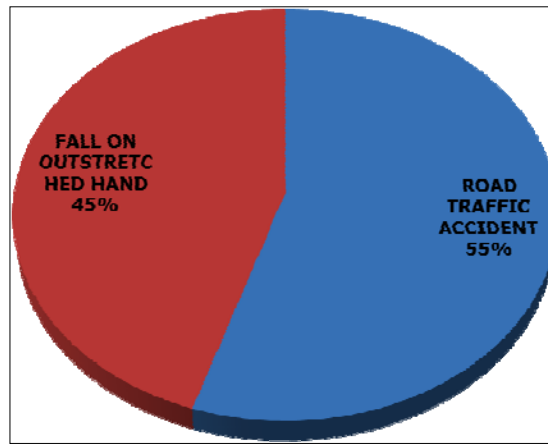
The involved forearm was immobilized in a below elbow POP slab and kept elevated. Pain and inflammation were managed using analgesics like diclofenac sodium 50mg twice daily.

### Radiographic examination

Standard radiographs in PA and lateral views were taken for confirmation of the diagnosis and also to know the type of fracture. Oblique views were also taken in a few patients who had complex comminuted fractures. The fracture fragments were analysed and involvement of radiocarpal and distal radioulnar joints were assessed and classified according to the fernandez classification.

### Results

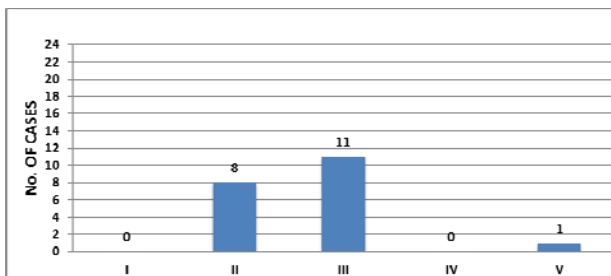
There were 14 (70%) males and 6(30%) females between the age group of 20-72 years with mean of 43.9 years. 14 (70%) patients had right side involvement (dominant wrist) and 6(20%) had left side involvement. Of the 20 cases, injury occurred due to road traffic accident in 11 (55%) patients and fall on the out stretched hand in 9(45%) patients.



Graph 1: Mode of Injury

Table 1: Fernandez Distribution Of Cases

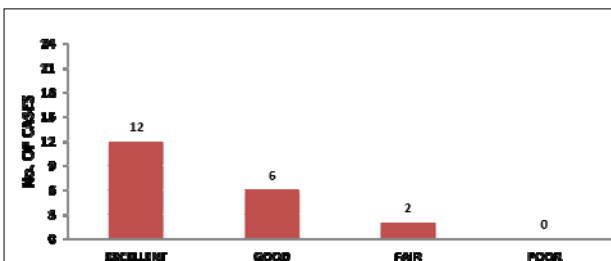
Type	N0: Of Cases	Percentage
I	0	0
II	8	40
III	11	55
IV	0	0
V	1	5
<b>Total</b>	<b>20</b>	<b>100</b>



Graph 2: Fernandez Distribution of Cases

Table 2: Gartland Werley Demerit Scores

(a) Excellent	(b) 12
(c) Good	(d) 6
(e) Fair	(f) 2
(g) Poor	(h) 0



Graph 3: Gartland Werley Demerit Scores

**Discussion**

The present study was undertaken to assess the functional outcome of operative management of distal radial fractures using a locked compression plate. Numerous studies have shown that extra-articular fractures as well as impacted fractures stable with minimal shortening can be managed conservatively. However, more often than not, distal radius fractures involve the radiocarpal joint and/or the distal radioulnar joint. These require an anatomical reduction of the

joint surface to reduce the incidence of post-traumatic arthritis and to guarantee a successful treatment outcome. In contrast, the results of conservative treatment of intra-articular fractures, especially in young individuals have been poor. Thus, intra-articular fractures that cannot be reduced by conservative methods and are comminuted, displaced and unstable, require operative treatment.

Following a distal radial fracture, the attainment and maintenance of anatomical reduction of the articular surface is crucial to the preservation of wrist function. Trumble *et al* [4] stated that the degree to which articular step off, gaping between fragments and radial shortening can be improved with surgery correlates strongly with improved outcome. Hence, a treatment method that is more likely to achieve these goals will result in better function.

There have been prospective studies in which external fixation with percutaneous pin fixation has been compared with open reduction and plate fixation. In a multicenter randomized control trial, Kreder *et al* [5] noted that indirect reduction and percutaneous fixation was associated with a more rapid return of function and a better functional outcome in comparison with open reduction and internal fixation. However, in practice, as the fracture becomes more comminuted, the chance of a successful indirect reduction decreases and the need for additional procedures increases. Improvement in the design of both internal and external fixation devices has occurred recently. Locking plate fixation providing angular stability and the ease of volar application has been documented [6, 7]. The concept of fragment-specific fixation with use of mini-plates and smaller implants is also being explored [8, 9]. The operative method selected to achieve the treatment objectives requires a careful study of the individual fracture pattern, level of activity, quality of bone and general medical condition.

**Conclusion**

Compared to the previous studies conducted on different modalities of surgical management of distal radius fractures, locking compression plate has proven to be effective with minimal to nil complications. Locking compression plates provide good to excellent results and are effective in the correction and maintenance of the distal radial anatomy. By using these plates, joint motion and daily functioning recovered in a short time.

**References**

1. Chen Neal C, Jupiter Jesse BMO. Management of distal radial fractures. *The J Bone & Joint Surg.* 2007; 89-

- A(9):2051-2062.
2. Cooney WPIII, Dobyns JH, Linscheid RL. Complications of Colles' fractures. *J Bone Joint Surg.* 1980; 62-A:613.
  3. Bradway JK, Amadio PC, Cooney WP III. Open reduction and internal fixation of displaced, comminuted intra-articular fractures of the distal end of the radius. *J Bone Joint Surg.* 1989; 71-A(6):839-847.
  4. Musgrave DS, Idler RS. Volar fixation of dorsally displaced distal radius fractures using the 2.4mm locking compression plates. *J Hand Surg (Am).* 2005; 30:743-9.
  5. Klos K, Rausch S, Löffler M, Fröber R, Hofmeier K, Lenz M *et al.* A biomechanical comparison of a biodegradable volar locked plate with two titanium volar locked plates in a distal radius fracture model. *J Trauma.* 2010; 68(4):984-91.
  6. Rikli DA, Regazzoni PF. Fractures of the distal end of the radius treated by internal fixation and early function. *J Bone Joint Surg Br.* 1996; 78(4):588-592.
  7. Colles A. On the fracture of the carpal extremity of the radius. *Edinburgh Medical Surgical Journal.* 1814; 10:182-186.
  8. Strohm PC, Müller CA, Helwig P, Mohr B, Südkamp NP. Is the locking, 3.5mm Palmar T-Plate the implant of choice for displaced distal radius fractures? *Z Orthop Unfall.* 2007; 145(3):331-7.
  9. Brunelli F, Pagliei A, Smussi C. Anatomy of the distal radius. In Saffar P, Cooney WPIII eds. *Fractures of the distal radius.* London: Martin Dunitz Ltd, 1995, 1-11.