

International Journal of Orthopaedics Sciences

ISSN: 2395-1958
IJOS 2017; 3(1): 459-462
© 2017 IJOS
www.orthopaper.com
Received: 08-11-2016
Accepted: 09-12-2016

Dr. Yash Rabari
Rural Medical Collage Loni,
Pravara Institutes of Medical
Sciences, Loni Bk, Taluka-
Rahata, Dist.-Ahmednagar,
Maharastra, India

Dr. D.V. Prasad
Rural Medical Collage Loni,
Pravara Institutes of Medical
Sciences, Loni Bk, Taluka-
Rahata, Dist.-Ahmednagar,
Maharastra, India

Dr. Krunal Thadeshwar
Rural Medical Collage Loni,
Pravara Institutes of Medical
Sciences, Loni Bk, Taluka-
Rahata, Dist.-Ahmednagar,
Maharastra, India

Dr. Dinesh Dhaytadak
Rural Medical Collage Loni,
Pravara Institutes of Medical
Sciences, Loni Bk, Taluka-
Rahata, Dist.-Ahmednagar,
Maharastra, India

Dr. Parminder Singh
Rural Medical Collage Loni,
Pravara Institutes of Medical
Sciences, Loni Bk, Taluka-
Rahata, Dist.-Ahmednagar,
Maharastra, India

Dr. Ajinkya Jadhao
Rural Medical Collage Loni,
Pravara Institutes of Medical
Sciences, Loni Bk, Taluka-
Rahata, Dist.-Ahmednagar,
Maharastra, India

Correspondence
Dr. Yash Rabari
Rural Medical Collage Loni,
Pravara Institutes of Medical
Sciences, Loni Bk, Taluka-
Rahata, Dist.-Ahmednagar,
Maharastra, India

Schwannomas- The problem in delay diagnosis

Dr. Yash Rabari, Dr. D.V. Prasad, Dr. Krunal Thadeshwar, Dr. Dinesh Dhaytadak, Dr. Parminder Singh, Dr. Ajinkya Jadhao

DOI: <http://dx.doi.org/10.22271/ortho.2017.v3.i1f.68>

Abstract

Schwannoma is a benign peripheral nerve sheath tumor which arises from Schwann cells which support the peripheral nerve fibers. Malignant transformation is known to be exceptionally rare. The lesion is usually solitary, but multiple tumors in a limb have been reported. Schwannomas most commonly occur in the head and neck involving the brachial plexus and spinal nerves. The lower limbs are affected less often. Schwannomas usually grow slowly and present as a painless swelling over several years without specific symptoms. The diagnosis of a Schwannoma in a lower limb is often delayed for several years because it is frequently misdiagnosed as a benign solitary mass such as a ganglion, fibroma or myxoma.

Keywords: Schwannoma, solitary, tumors

1. Introduction

Schwannoma is a benign peripheral nerve sheath tumor which arises from Schwann cells which support the peripheral nerve fibres. Malignant transformation is known to be exceptionally Rare ^[1, 2]. The lesion is usually solitary, but multiple tumors in a limb have been reported ^[3]. Schwannomas most commonly occur in the head and neck involving the brachial plexus and spinal nerves. The lower limbs are affected less often ^[4]. Schwannomas usually grow slowly and present as a painless swelling over several years without specific symptoms. The diagnosis of a Schwannoma in a lower limb is often delayed for several years because it is frequently misdiagnosed as a benign solitary mass such as a ganglion, fibroma or myxoma ^[5, 6]. A Schwannoma is well encapsulated and eventually displaces the fascicles of the nerve, whereas a neuro-fibroma envelops them. For this reason, it is generally believed that a Schwannoma can easily be enucleated from the nerve without producing a neurological deficit. However, even with meticulous dissection, several Schwannomas may not be separated or enucleated and this increases the risk of transient or permanent neurological damage ^[7-9]. The threshold for iatrogenic injury during surgical dissection tends to be lower in the extremities than in the trunk. In particular, a major neurological deficit such as motor weakness is critical in the lower limb. This study was conceived to (1) evaluate surgical outcomes of histopathologically confirmed Schwannomas originating from major peripheral nerves of the lower limb and upper limb with motor function, focusing on any temporary or permanent neurological deficits; and (2) determine predictable factors for permanent neurological deficits following surgical excision

2. Case Series

Case 1

A 65-year old male presented with a slowly enlarging mass in his right thigh anterolateral region with progressive pain over time. The neurological examination was normal. The Tinel sign was not present. The mass was mobile in a transverse plane and immobile along the parallel axis. MRI of the right thigh revealed a mass with a size of 26 x 17 mm, located on the femoral nerve course, lateral aspect of thigh in the region of vastus lateralis muscle which was hyperintense to hypointense on T2W and STIR and isointense on T1W and does not show blooming on GRE images. On post contrast study these lesion show intense homogenous enhancement.

The operation was performed with microsurgical dissection. The tumor had a capsule, and not all the nerve fibers were englobed. It was removed without damage to the surrounding

nerve. The histopathological diagnosis was schwannoma. The postoperative course was uneventful without any complications.

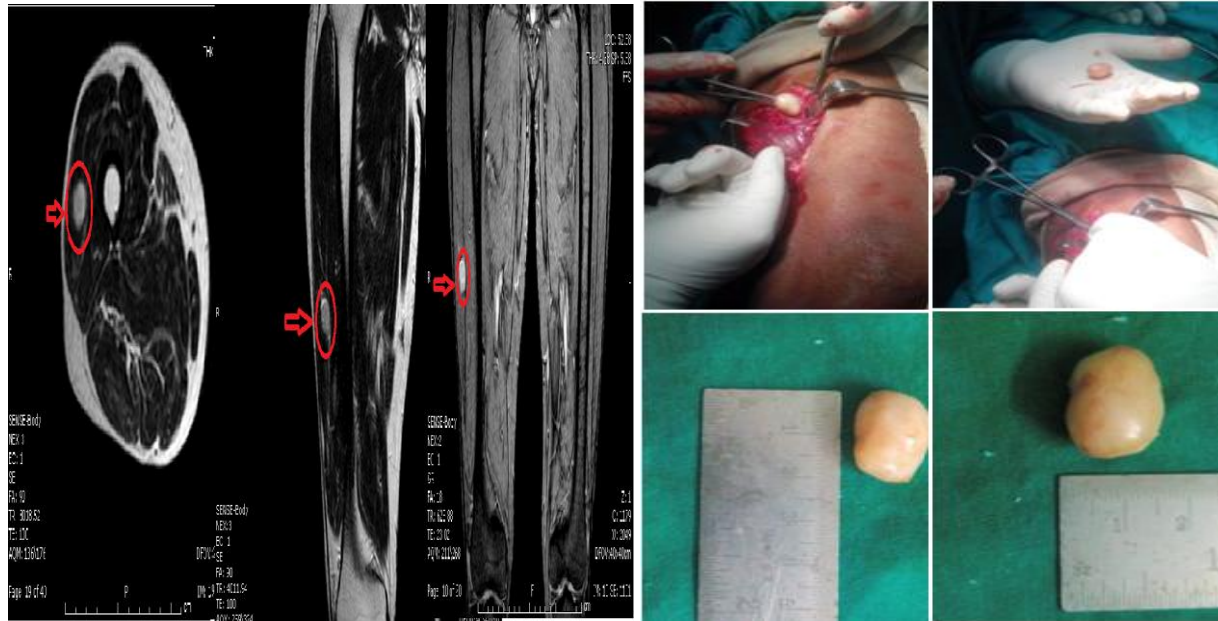


Fig 1-Fig 2: Radiological and Surgical Images of Femoral Nerve Schwannoma

Case 2

A 65-year old male presented with a slowly enlarging mass in his left popliteal region with Progressive pain over time. The neurological examination was normal. The Tinel sign was not present. The mass was mobile in a transverse plane and immobile along the parallel axis. MRI of the right thigh revealed a small oval mass lesion with altered signal intensity measuring 1.53 x 1.3 x 1.51 cm seen in the postero-lateral aspect of left knee joint along the course of the common peroneal nerve, between the tendon of the biceps

femoris and lateral head of gastrocnemius and appearing as hyperintens to muscle on T2W, STIR, SPIR, GRE and hypointense on T1W images. On post contrast study these lesion show intense homogenous enhancement. The operation was performed with microsurgical dissection. The tumor had a capsule, and not all the nerve fibers were englobed. It was removed without damage to the surrounding nerve. The histopathological diagnosis was schwannoma. The postoperative course was uneventful without any complications.

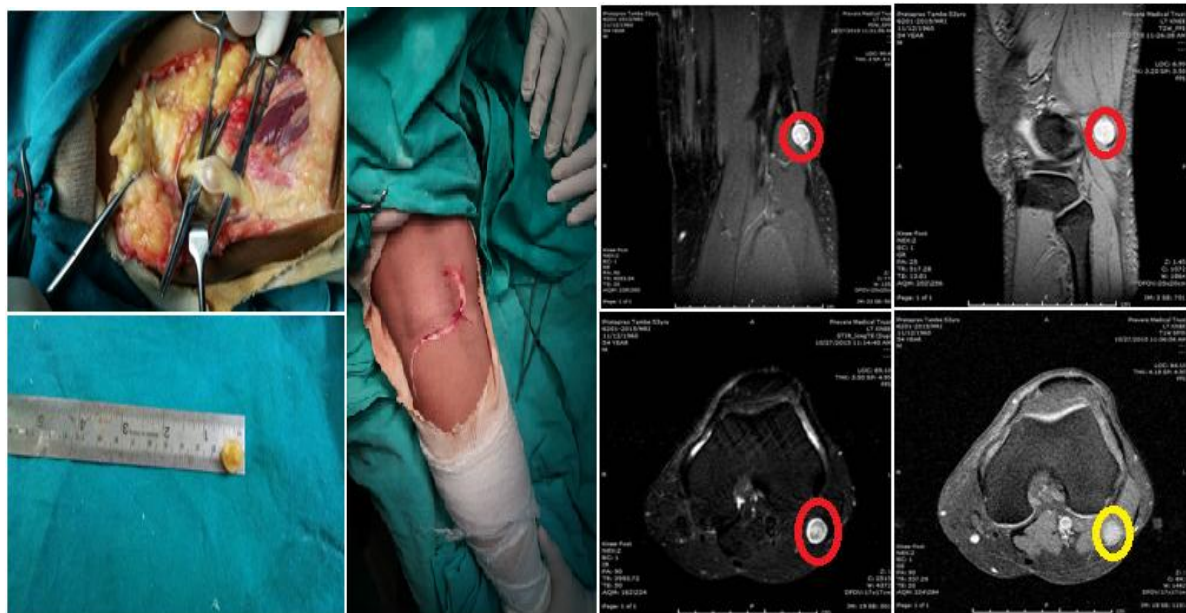

Fig 3-Fig 4: Radiological and Surgical Images of Peroneal Nerve Schwannoma

Case 3

A 42-year old female presented with a slowly enlarging mass in his right leg anteromedial region with progressive pain over time. The neurological examination was normal. The Tinel sign was not present. The mass was mobile in a transverse

plane and immobile along the parallel axis. MRI of the right leg revealed a mass with a size of 19x25x16 mm, located on the posterior compartment of lower leg within soleus muscle, along posterior tibial neurovascular bundle. Lesion lies approximately 14cm above the level of planter surface of

calcaneum. It was hyperintense to hypointense on T2W and STIR and isointense on T1W and does not show blooming on GRE images. On post contrast study these lesions show intense homogeneous enhancement with a small central area of necrosis. Posterior neurovascular bundle is displaced slightly medially by the lesion.

The operation was performed with microsurgical dissection. The tumor had a capsule, and not all the nerve fibers were engulfed. It was removed without damage to the surrounding nerve. The histopathological diagnosis was schwannoma. The postoperative course was uneventful without any complications.

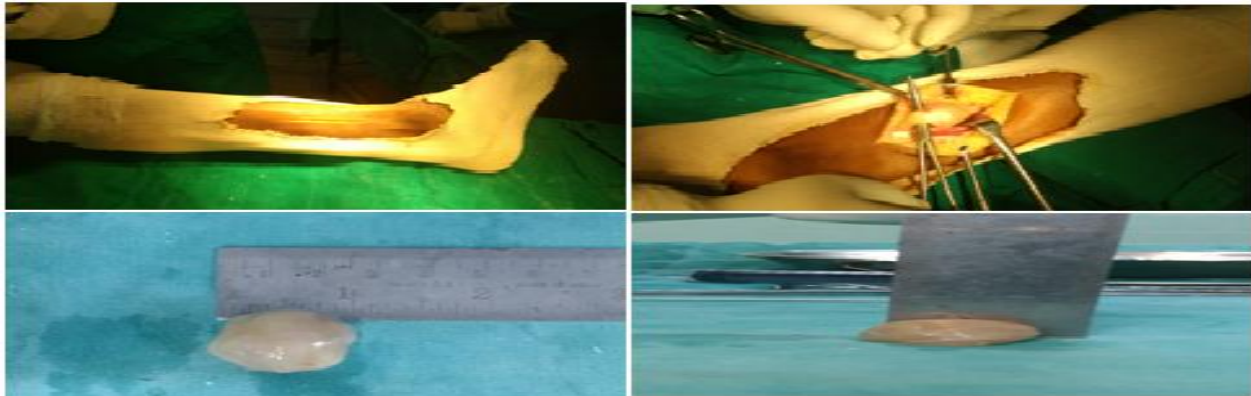


Fig 5: Surgical Images of Tibial Nerve Schwannoma

Case 4

A 30-year old female presented with a slowly enlarging mass in her right elbow at lateral side on lateral epicondyle with progressive pain over time. The neurological examination was normal. The Tinel sign was present. The mass was immobile in all plane. MRI revealed a mass with a size of 20x15 mm, located at lateral epicondyle of humerus completely encircling adjacent neurovascular bundle and radial nerve. The lesion abutts is separate from adjacent musculature. It was hyperintense to hypointense on T2W and STIR and isointense on

T1W and does not show blooming on GRE images. On post contrast study these lesions show intense homogeneous enhancement.

The operation was performed with microsurgical dissection. The tumor had a capsule, and not all the nerve fibers were engulfed. It was removed without damage to the surrounding nerve. The histopathological diagnosis was schwannoma. The postoperative course was uneventful without any complications.

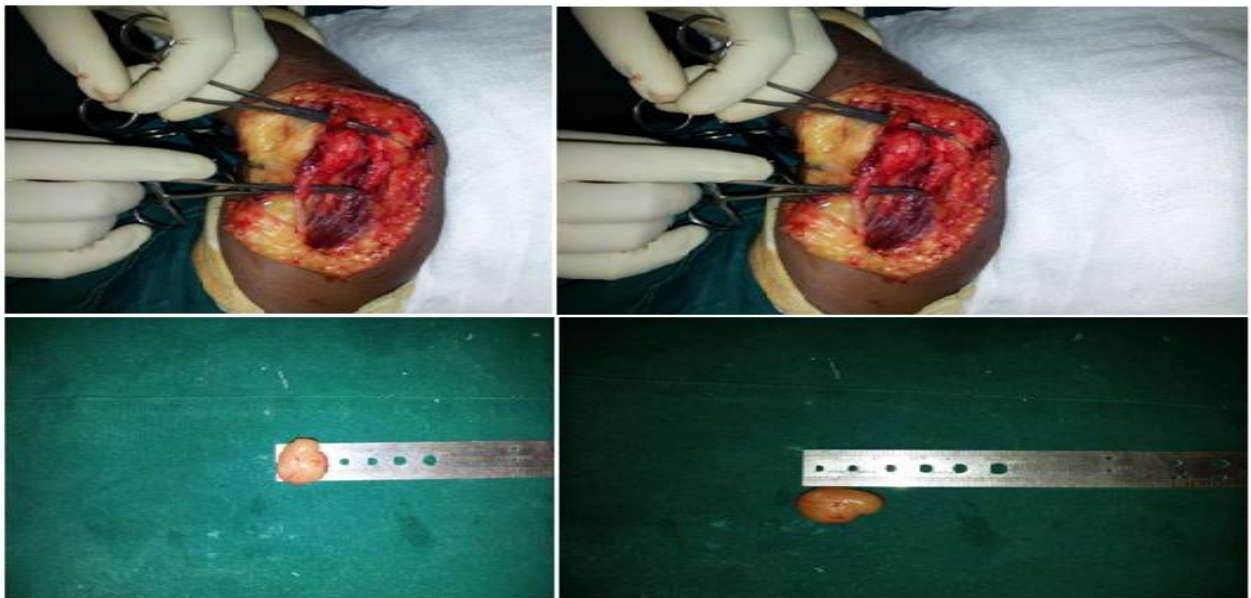


Fig 6: Surgical images of Radial Nerve Schwannoma

3. Discussion

The diagnosis of schwannoma in a limb is usually straightforward. A painful lump with a positive Tinel sign are the key features, but only one of the Five patients in our study were diagnosed within 4 year and the longest delay was 9 years. Ghaly [5] described a patient suffering with pain in the foot for ten years before diagnosis of a schwannoma of the posterior tibial nerve in the calf. Gominak and Ochoa [10] described two patients presenting with pain in the foot for four and five years respectively, before diagnosis of a schwannoma

in the sciatic nerve in the thigh. Smith and Amis [11] described a patient who presented with pain in the foot for eight years before recognition of a schwannoma of the posterior tibial nerve at the ankle.

A benign tumor of the sheath of a peripheral nerve is one explanation for longstanding neuropathic pain in the upper limb and lower limb. A lump may not be palpable in the early phases and we therefore recommend an examination of the entire length of the upper or lower limb, by palpation and percussion. The Tinel sign obtained is helpful in diagnosis

which should be confirmed by MRI or ultrasound examination.

We suggest that there were two reasons for the delay in diagnosis. First, a deep-seated swelling may escape detection by palpation in the upper limb or the lower limb [5]. All 5 patients had a palpable lump but only one was aware of a swelling. Careful examination for a lump is therefore essential. When a lump is not palpable, a Tinel sign may be the only clue to diagnosis. Secondly, neuropathic pain expressed in the absence of a palpable lump may mislead the clinician, so that radiculopathy or entrapment neuropathy may be suspected.

MRI is the investigation of choice to confirm the presence of a schwannoma. It shows a well-circumscribed and encapsulated mass with a heterogeneous signal and no surrounding oedema. The mass is eccentrically placed in relation to the axis of the nerve. Ultrasound scanning is also effective. Final diagnosis is done by histopathology investigation.

Treatment is by excision of the tumor without damaging the conducting elements of the nerve. Adequate exposure of normal nerve proximal and distal to the tumor is essential. A plane is developed between the nerve bundles and the capsule of the tumor which is then removed whole. A small fascicle entering the proximal pole may require removal with the tumor. Intra-operative nerve stimulation allows separation of conducting from non-conducting tissue.

It was found that the risk of developing neurological deficits was more likely to be high in patients with larger tumors. Some authors reported that tumor size may be a risk factor for neurological deficits [8, 12]. Park *et al.* observed that larger tumors tended to have more fascicles entering the tumor substance and were at greater risk of major neurological deficits after surgery [13]. On the basis of these findings, it is recommended that large-sized Schwannomas be managed meticulously with caution during surgery. Also, it would be expected that early surgical excision would have a better clinical outcome when a Schwannoma is detected in the major peripheral nerve of the lower limb. On the other hand, Oberle *et al.* reported that postoperative neurological deficits were associated with longer history [8]. In the study of Sawada *et al.*, a positive preoperative Tinel's sign showed a significant relationship with neurological complications [9]. However, there were no preoperative symptoms or signs which were predictable factors for final neurological outcomes except tumor size in our series. This may be due to the limited number of cases of the study.

We acknowledge that our study had some limitations. First, because of the rarity of this tumor, the number of cases was small and therefore, it was difficult to draw definitive conclusions. Second, this study was performed as a retrospective study of surgical excision of Schwannoma at different times. Some confounding factors from the study design may have affected the results. However, we believe that our results suggest important information to surgeons who intend to attempt surgical excision of Schwannomas derived from the major peripheral nerve. Identification of predictable factors related to neurological deficits may lead to strategies that can minimize surgical complications.

4. Conclusion

A Schwannoma arising from a major peripheral nerve in the limb could be the major neurological problem due to delay in diagnosis.

A Schwannoma could be excised with an acceptable risk of nerve injury, although a transient neurological deficit occurred relatively often. However, new and/or permanent neurological

deficits can develop in some patients following surgery. Therefore, all patients undergoing surgical excision of a Schwannoma arising from a major peripheral nerve of the 1 limb must be informed about this complication.

Meticulous attention to detail is required for large-sized Schwannomas because these tumors seem to have a higher risk of fascicular injury during dissection.

5. References

1. Knight DM, Birch R, Pringle J. Benign solitary Schwannomas: a review of 234 cases. *J Bone Joint Surg Br.* 2007; 89:382-387
2. Nawabi DH, Sinisi M. Schwannoma of the posterior tibial nerve: the problem of delay in diagnosis. *J Bone Joint Surg Br.* 2007; 89:814-816
3. Phalen GS. Neurilemmomas of the forearm and hand. *Clin Orthop Relat Res.* 1976; 114:219-222
4. Birch R, Bonney G, Wynn Parry CB. The peripheral nervous system and neoplastic disease. In: *Surgical disorders of the peripheral nerves.* Churchill Livingstone, Edinburgh, 1998, 335-352
5. Ghaly RF. A posterior tibial nerve neurilemoma unrecognized for 10 years: case report. *Neurosurgery* 2001; 48:668-672.
6. Rockwell GM, Thoma A, Salama S. Schwannoma of the hand and wrist. *Plast Reconstr Surg.* 2003; 111:1227-1232.
7. Donner TR, Voorhies RM, Kline DG. Neural sheath tumors of major nerves. *J Neurosurg.* 1994; 81:362-373.
8. Oberle J, Kahamba J, Richter HP. Peripheral nerve schwannomas—an analysis of 16 patients. *Acta Neurochir (Wien).* 1997; 139:949-953
9. Sawada T, Sano M, Ogihara H, Omura T, Miura K, Nagano A. The relationship between pre-operative symptoms, operative findings and postoperative complications in Schwannomas. *J.* 2006.
10. Gominak SC, Ochoa JL. Sciatic schwannoma of the thigh causing foot pain mimicking plantar neuropathy. *Muscle Nerve.* 1998; 21:528-30
11. Smith W, Amis J. Neurilemmona of the tibial nerve: a case report. *J Bone Joint Surg [Am].* 1992; 74-A:443-4
12. Ogose A, Hotta T, Morita T, Otsuka H, Hirata Y. Multiple Schwannomas in the peripheral nerves. *J Bone Joint Surg Br.* 1998; 80:657-661
13. Park MJ, Seo KN, Kang HJ. Neurological deficit after surgical enucleation of Schwannomas of the upper limb. *J Bone Joint Surg Br.* 2009; 91:1482-1486