

ISSN: 2395-1958
IJOS 2017; 3(1): 381-387

www.orthopaper.com
Received: 28-11-2016
Accepted: 29-12-2016

Dr. Gaurav Gupta
Junior Resident, Department of Orthopedics, National Institute of Medical Science & Hospital, Jaipur, India

Dr. Rakesh Bhargava
Professor & Hod, Department of Orthopedics, National Institute of Medical Science & Hospital, Jaipur, India

Dr. Abdul Rahim
Assistant Professor, Department of Orthopedics, National Institute of Medical Science & Hospital, Jaipur, India

Dr. Gaffar Khan
Junior Resident, Department of Orthopedics, National Institute of Medical Science & Hospital, Jaipur, India

Correspondence
Dr. Gaurav Gupta
Junior Resident, Department of Orthopedics, National Institute of Medical Science & Hospital, Jaipur, India

A prospective study of management of closed diaphyseal fractures of radius and/or ulna in children with intramedullary titanium elastic nail system

Dr. Gaurav Gupta, Dr. Rakesh Bhargava, Dr. Abdul Rahim and Dr. Gaffar Khan

DOI: http://dx.doi.org/10.22271/ortho.2017.v3.i1f.58

Abstract
Background & Aim: Intra-medullary elastic nailing system is an ideal device for the treatment of pediatric forearm fractures. It is simple, safe, minimally invasive technique and has a fewer complications.
The aim of the study was to evaluate and report our experiences regarding union rates, clinical and functional outcome and complications associated with this treatment modality in BBF between age group of 5 to 15 years.
Material & Methods: 40 cases of pediatric diaphyseal both bone forearm in children of age group 5 to 15 years operated at National Institute of Medical Science and hospital, Jaipur meeting the inclusion and the exclusion criteria (as given below) managed between January 2015 to December 2015 with TENS were prospectively reviewed. The final functional and clinical outcome & complications were assessed at 6 month of follow up by Andersons *et al* criteria.
Results: Of all 40 patients had undergone close reduction in which 2 required open reductions. All fractures united at a mean of 7.95 weeks (range 6-10 weeks) with achievement of full R.O.M at elbow and wrist in majority with reported restriction in 3 cases. There were no major complications but encountered minor complications in 18 patients such as pain (22.5%), hardware skin irritation (12.5%), and pin track infection (10%). The final functional outcome evaluated by Andersons *et al* criteria showed 90% excellent results and remaining showed good outcome.
Conclusion: TENS is an ideal device for the treatment of pediatric forearm fractures as it is a simple, safe, minimally invasive technique and has fewer complications. It also does not interfere with growth of the forearm and provides early union due to non interference of fracture hematoma and minimal periosteal stripping. It provides shorter hospital stay, rapid return to daily activity & school, avoids long & uncomfortable immobilization & cosmetically acceptable

Keywords: Children and adolescents, TENS implants, forearm injuries, fracture fixation, intramedullary nailing, orthopedic surgical procedures, pediatric, radius and ulna

Introduction
Over the past 20 years, pediatric orthopedists have tried a variety of methods to treat pediatric long bone fractures to avoid prolonged immobilization and complications [1, 2]. Ender's nails are stainless steel implants that proved to be inadequate for adult femoral and tibial fractures but may be effective for pediatric fractures although they may be not elastic enough as their modulus of elasticity is higher than titanium nails [3].
TENs are more elastic, thus limiting the amount of permanent deformation during nail insertion; they promote healing by limiting stress shielding in addition to their biocompatibility without metal sensitivity reactions [4].

Materials and Methods
It was planned to conduct a time bound prospective study of 40 pediatric closed forearm diaphyseal fractures of radius and/or ulna in children between 5-15 year age group treated with TENS admitted at National Institute of Medical Science & Hospital, Jaipur; meeting the inclusion and the exclusion criteria (as given below) during the study period from January 2015 to December 2015 were the subjects for the study.

Inclusion criteria

- Age : 5-15 years
- Displaced diaphyseal fracture ulna and/or radius. (Angulated >20° and displaced >50%)
- Segmental diaphyseal fracture ulna and/or radius.
- Simple transverse fractures ulna and/or radius.
- Oblique fractures ulna and/or radius.
- Failed close reduction.

Exclusion criteria

- Open fractures with or without neurovascular injury.
- Pathological fractures
- Re-fractures
- Malunited fractures
- Floating elbow.
- Fractures associated with proximal and distal radio-ulnar instability.
- Patients with local tissue condition making surgery inadvisable.
- Patients with co morbid medical conditions not fit for surgery.

As soon as the patient was brought to casualty, patient's airway, breathing and circulation were assessed. Then a complete survey was carried out to rule out other significant injuries. Plain radiographs of AP and lateral views of – the involved extremity including one joint above and one joint below was taken to assess the extent and geometry of fracture. On admission to ward, a detailed history was taken, relating to the age, sex, and occupation, mode of injury, past and associated medical illness Routine blood investigations were done for all patients. Patients were operated as early as possible once the general condition of the patient was stable and patient was fit for surgery.
The diameter of the individual nail is selected as per Flynn *et al*. [5] formula.

Pre-operative planning of Nail size
Nail length
Lay one of the selected nails over the radius/ulna, and determine that it is of the appropriate length by fluoroscopy.

Preoperative preparation of patients
Patients were kept nil by mouth overnight before surgery, written informed consent taken form patient and relatives. AST, XST, part-preparation of extremity done. A systemic antibiotic, usually a 3rd generation cephalosporin was administered 1 hour before surgery.

Titanium Elastic Nail System Instrumentation Set
1. Titanium elastic nails
2. Bone awl
3. Inserter
4. Beveled tamp
5. Hammer
6. Steffe cutter

Pre-requisites for ESIN for stable internal fixation:

- Nail diameter should measure 40% of the narrowest diameter of the diaphysis, Pre-bent & contoured with long bend nail taken such that apex of the convexity is at the level of fracture to provide optimal three point fixation.
- Under anesthesia, closed reduction and internal fixation with TENS nails done under c-arm guidance.
- Always use same diameter nails to prevent loss of reduction towards the side of stronger nail.
- The entry point of both nails taken from lateral side distally for radius proximal to physis and proximally 2 cm laterally and below olecranon tip avoiding physis.
- When inserted, nails should have maximum cortical contact at the fracture site in the opposite directions.

Postoperative Care

- Patients were kept NBM pre-operatively.
- IV fluids / blood transfusions, analgesics were given as needed.
- Post-op i.v & oral antibiotics administered.
- Sutures were removed on the 2nd week.
- Post-operatively, patients are immobilized with long arm slab for 4 weeks with active fingers moments were allowed.

Follow Up
Assessment was done at 6th week, 3 month and 6 month. At each follow up patients are assessed clinically (R.O.M at elbow and wrist), radio logically (union and alignment) and the complications are noted.

Clinical Assesment
Range of motion at elbow and wrist at every follow up.

Complications
Minor complications
a) when they resolved without additional surgery
b) Not resulting in long term morbidity.

Major complications
a) when further operation was required
b) Long term morbidity ensued.

Final functional outcome was measured on 6 months on the basis of grading system by Andersons *et al*. [10].

Table 1: Anderson's criteria for assessment of functional outcome

Result	Union	Flexion and extension at wrist joint	Supination and pronation
Excellent	Present	<10° loss	<25% loss
Good	Present	<20° loss	<50% loss
Fair	Present	<30° loss	>50% loss
Poor	Non-union with or without loss of motion		

Excellent: when there was anatomical or near anatomical alignment, no leg length discrepancy with no preoperative problems.

Satisfactory: when there was acceptable alignment and leg length with resolution of preoperative problems.

Poor: in the presence of unacceptable alignment or leg length with unresolved preoperative problems.

Observations and Results
Study design: An outcome surgical study of 30 patients with Diaphyseal fractures of BBF is undertaken to study the outcome of Titanium elastic nail fixation for long bone fractures in children.

Table 1: Age Distribution

Age (years)	Number	Percentage
0-5	4	10%
5-10	27	67%
10-15	9	23%

Table 1: Shows the distribution in the age of the patient. Patient with age below 5 years and above 15 years were excluded from the study with mean 8.62 and standard deviation 2.63.

Table 2: Gender Distribution

Gender	No.	Percentage
Male	26	65%
Female	14	35%

Table 2: Shows the distribution and frequency in the gender of the patient.

Table 3: Side Distribution

Side	No.	Percentage
Right	23	57.7%
Left	17	42.5%

Table 3: The right side was affected more as compared to the left side. Since, most of the patients were right side dominant patients hence; this required a significantly good functional outcome postoperatively.

Table 4: Distribution of Mode of Injury

Mode of Injury	No.	Percentage
Fall on Outstretched Hand	23	57.5%
Sports Injury	8	20%
Fall from Height	6	15%
RTA	3	7.5%

Table 4: Most common mode of injury was fall on the outstretched hand with the least number of injuries occurring due to road traffic injuries associated with 12.5% head injury patients.

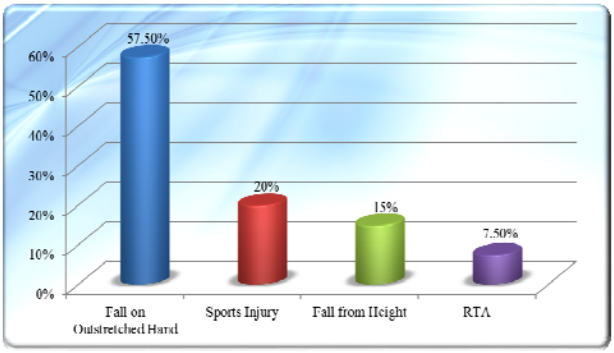

Graph 1: Distribution of Mode of Injury

Table 5: Pattern of Fracture

Pattern of Fracture	No.	Percentage
Simple Oblique #	30	37.5%
Transverse #	50	62.5%

Table 5: All fractures were of the middle 1/3 with the fracture geometry being transverse in 50 cases and simple oblique in the remaining 30 cases.

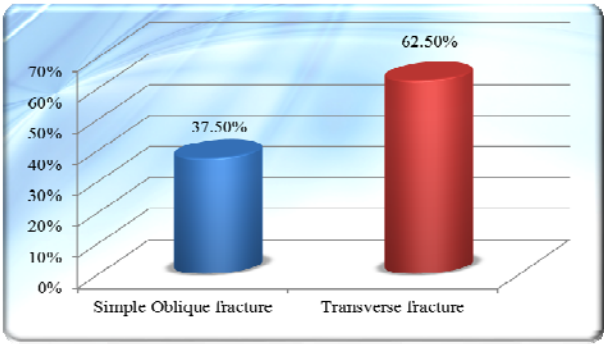

Graph 5: Pattern of Fracture

Table 6: Injury Surgery Interval

Injury Surgery Interval (days)	No.	Percentage
0-2	37	92.5%
2-4	2	5%
4-6	1	2.5%
>6	0	0%

Table 6: Intra-operative specifications: table no 6 showing the mean injury surgical interval was 1. 5 days with standard deviation of 0.905 and in all the cases 2 titanium elastic nails were inserted.

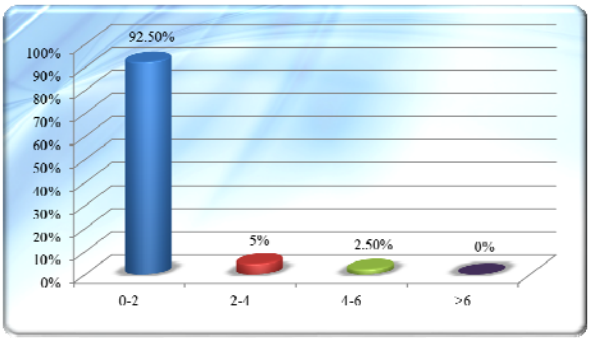

Graph 6: Injury Surgery Interval(days)

Table 7: Reduction

Reduction	No.	Percentage
Close	38	95%
Open	2	5%

Table no 7: In all cases except 2 we were able to reduce the fracture without opening the fracture site. In the remaining 2 the fracture site had to be opened as closed reduction was not possible.

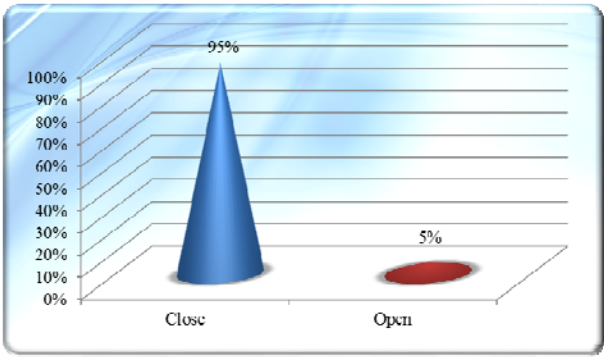

Graph 7: Intra-Operative: Type of Reduction-Open/Close

Table 8: Time of Union (weeks)

Time of union (weeks)	No.	Percentage
0-3	0	0%
3-6	13	32.5%
6-9	15	37.5%
>9	12	30%

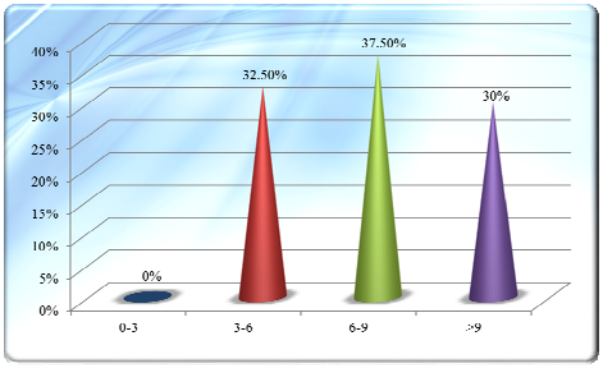

Graph 8: Time of Union (weeks)

Table 9: Time of Implant Removal (weeks)

Time of implant removal (weeks)	No.	Percentage
<20	0	0%
20-22	20	50%
22-24	20	50%
>24	0	0%

Table 9: Postoperative specifications: Table 8 and 9 showing mean time, required for union of the fracture was found to be 7.95 weeks and the mean time of implant removal was at 22.65 weeks with standard deviation 1.6 and 0.73 respectively.

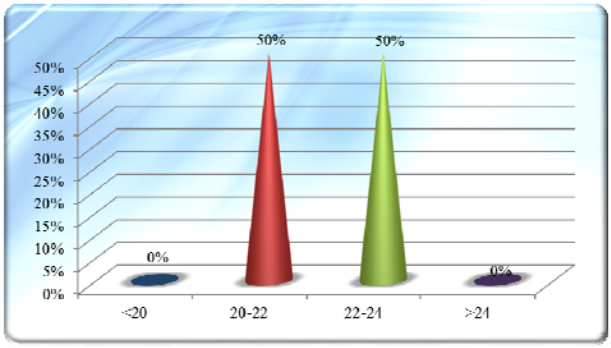

Graph 9: Time of Implant Removal (weeks)

Table 10: Comparison of unaffected and affected Limb among Elbow

		Mean	Std. Deviation	Mean differences	P value
Flexion	Normal	149.75	1.104	3.25	0.001 (S)
	6 month	146.50	5.335		
Extension	Normal	0.00	0.000	0.37	0.07
	6 month	0.37	1.33		
Pronation	Normal	76.25	2.715	1.87	0.08
	6 month	74.37	6.11		
Supination	Normal	86.12	2.115	1.37	0.15
	6 month	84.75	5.656		

Test applied: unpaired t test S=Significant

Table 10: Comparison of the range of motion of the affected elbow with the normal elbow at the end of 6 months postoperative. Shows the loss of flexion is statistically significant. Remaining change in the range of motion is not statistically significant.

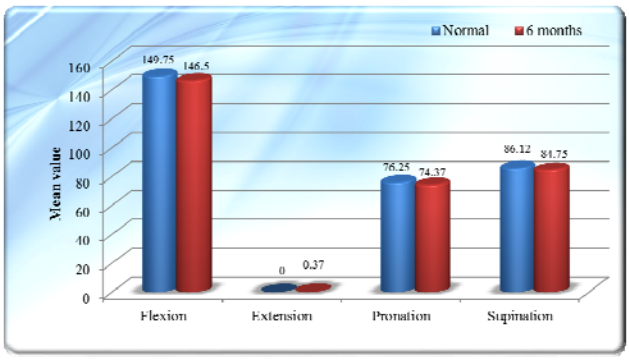

Graph 10: Comparison of ROM -unaffected and affected Limb among Elbow

Table 11: Comparison of ROM- unaffected and affected Limb among Wrist

		Mean	Std. Deviation	Mean differences	P value
Flexion	Normal	75.00	0.000	---	---
	6 month	75.00	0.000		
Extension	Normal	75.00	0.000	0.62	0.05
	6 month	74.38	2.022		
Radial	Normal	20.00	0.000	---	---
	6 month	20.00	0.000		
Ulnar	Normal	36.13	2.115	0.25	0.63
	6 month	35.88	2.503		

Test applied: unpaired t test S=Significant

Table 11: Showing the change in the range of motion of the wrist joint. There is no statistically significant change in the range of motion of wrist.

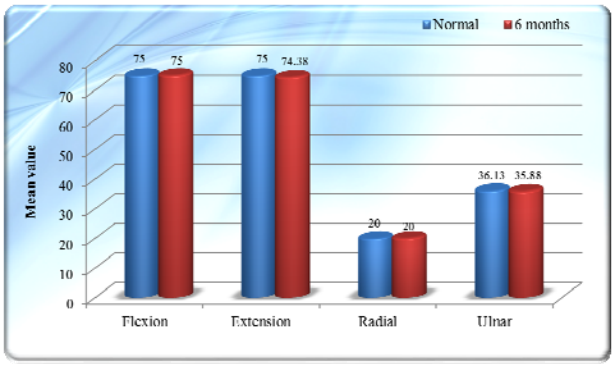

Graph 11: Comparison of ROM -unaffected and affected Limb among Wrist.

Table 12: Comparison of mean differences (Normal vs. Affected) of Elbow with Complication

		Flexion	Extension	Pronation	Supination
Pain	Pearson Correlation	0.151	0.157	0.260	0.391
	P value	0.352	0.333	0.105	0.01 (S)
Nail	Pearson Correlation	0.306	0.421	0.430	0.659
	P value	0.055	0.007 (S)	0.006 (S)	0.000 (S)
Others	Pearson Correlation	-0.087	-0.184	-0.062	-0.104
	P value	0.595	0.257	0.703	0.523
Results	Pearson Correlation	0.306	0.664	0.430	0.742
	P value	0.055	0.000 (S)	0.006 (S)	0.000 (S)

Table 12: showing the correlation between the complications and change in the range of motions at the elbow. It shows that the change in the range of motion is correlated to the complications with statistically significant correlation seen with the complications of the nail entry site as compared to the other complications.

Table 13: Complications

Complications	No.	Percentages
Pain	9	22.5%
Pin Tract Infection	4	10%
Hardware Skin Irritation	5	12.5%
Deformity	0	0%
Mal Union/ Non Union	0	0%
Others(limb length discrepancy etc)	0	0%

Table 13: showing 9 patients complained of having dull pain whereas 9 patients had nail related problems. This changed the final outcome in terms of the change in the range of motion.

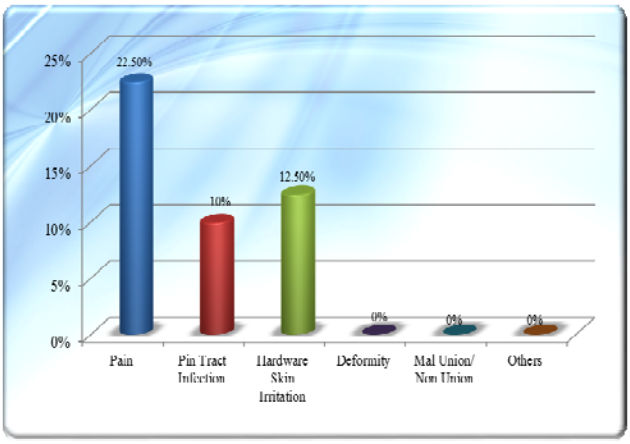

Graph 12: Showing Complications Rate

Table 14: Comparison of mean differences (normal vs affected) of wrist with complication

Complication		Flexion	Extension	Radial deviation	Ulnar deviation
Pain	Pearson Correlation	.[a]	0.176	.[a]	-0.124
	P value	.	0.277	.	0.447
Nail	Pearson Correlation	.[a]	0.356*	.[a]	-0.076
	P value	.	0.024	.	0.639
Others	Pearson Correlation	.[a]	-0.101	.[a]	-0.087
	P value	.	0.535	.	0.595
Results	Pearson Correlation	.[a]	-0.089	.[a]	-0.076
	P value	.	0.585	.	0.639

a. Cannot be computed because at least one of the variables is constant.

Table 14: Showing The Change in the Range of Motion Of The Wrist was not statistically significantly correlated to the complications.

Table 15: Results evaluated by Anderson's Criteria

Functional outcome	No.	Percentages
Excellent	36	90%
Good	4	10%
Fair	0	0%
Poor	0	0%

Table 15: Showing The Final Clinical Outcome As Assessed By The Andersons Criteria At The End Of The Follow-Up (6 Months Post-Operatively).

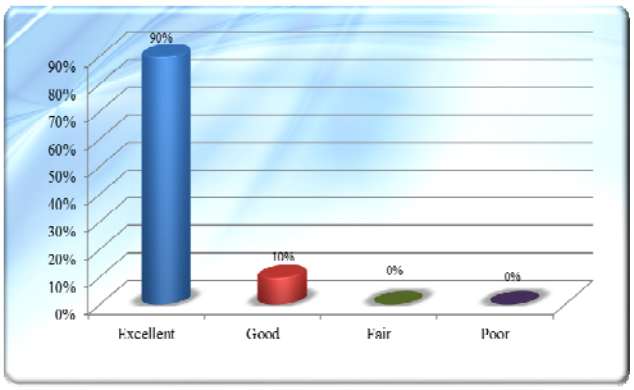

Graph 13: Results evaluated by Anderson's Criteria

Discussion

Age/Sex incidence

In the present study (see table no.16) there was 26 male and 14 female patients with 4(10%) of the patients were 5 years, 27(67%)were 5-10years and 9 (23%) were 10 to 15 years age group with the average age being 8.62 years and standard deviation 2.63.

Table 16: Showing Age/Sex Incidence

Study	Total Patients (N)	Sex (M/F)	Mean Age of Fixation
Yalcinkaya M *et al*	45	35M / 10F	10
Flynn JM *et al*	103	Not Mentioned	10.6
Richter D *et al*	30	18M / 12F	Not Mentioned
Shoemaker SD *et al*	32	22M / 10F	8.8
Parajuli NP *et al*	50	38M / 12F	10.4
Present Study	40	26M / 14F	8.62

Table 17: Showing Types of Implants Used in Pediatric BBF

Study	Implant Used
Yalcinkaya M *et al*	Rush Pins, Kirschner Wire
Flynn JM *et al*	Titanium Nails, Kirschner Wire
Richter D *et al*	Titanium Nails
Shoemaker SD *et al*	Kirschner Wire
Parajuli NP *et al*	Rush Pins
Present Study	Flexible Intramedullary Titanium Nails

Types of Implant Used: In the present study (see table.17) in all patients we used flexible titanium elastic nails in BBF. Flynn JM *et al* [5] and Richter D *et al* [9] also used titanium nail whereas under-mentioned literatures have used various other implants.

Table 18: Showing Average Time of Union (Weeks)

Study	Average Time of Union (weeks)
Yalcinkaya M *et al*	6-10 weeks
Flynn JM *et al*	6.9 -8.8 weeks
Richter D *et al*	13 weeks
Shoemaker SD *et al*	12 weeks
Parajuli NP *et al*	8 weeks
Present Study	7.95 weeks

Average Time of Union: In present study mean time of union was seen to be 7.95 weeks and this was comparable to other studies found in the literature of Yalcinkaya M *et al* & Flynn JM *et al* (Table 18).

Table 19: Showing Complications

Study	Complications
Yalcinkaya M *et al*	Major=2(4.44%) Minor=15(33.3%)
Flynn JM *et al*	Major=4(3.8%) Minor=11(10.6%)
Richter D *et al*	Minor=4(13.3%) Major=2(6.2%)
Shoemaker SD *et al*	Major=7(21.8%) Minor=8(16%)
Parajuli NP *et al*	Major=0 Minor=8(16%)
Present Study	Major=0 Minor=18(35%)

Complications: In present study (see table no.19) there were none major complications with reported 35% cases minor complications. The complications encountered in this study ranged from a dull aching pain (22.5%) to pin track infection (10%) along with hardware irritation (12.5%) which was comparable to the studies found in the literature
Yalcinkaya M *et al* and Parajuli NP *et al* have reported 4.4% and 0% cases major complications, 33.3% and 16% cases minor complications respectively.

Table 20: Showing Functional Outcome & Assessment Criteria

Study Author	Functional Outcome Assessment Criteria	Functional Outcome
Yalcinkaya M *et al*	Price Criteria	Excellent=82.2% Good=17.8%
Flynn JM *et al*	Children Hospital of Pheladephia Forearm	Excellent=77.75 Fair=14.6% Poor=7.8%
Richter D *et al*	Classification Tscherene Score	Excellent=80% Good=16.6% Fair=3.3%
Shoemaker SD *et al*	Price Criteria	Excellent=96.8% Good=3.2%
Parajuli NP *et al*	Price Criteria	Excellent=94% Good=6%
Present Study	Andersons *Et al*	Excellent=90% Good=10%

Functional Outcome Assessment: In the present study, the final outcome was excellent in 36(90%) cases whereas the remaining 4 (10%) cases showed good functional outcomes (see table no.20).

In Shoemaker SD *et al* [8] and Parajuli NP *et al* [6] study, the final outcome was excellent in 96.8% and 94% cases respectively, good in 3.2% and 6% cases and there were no cases showing poor outcome.

Summary

- Forty cases of pediatric forearm shaft fractures were treated with titanium elastic nailing in the period of January 2015 to December 2015 at National institute of medical science & hospital, Jaipur with a mean period of 6 month follow-up.
- Out of 40 children, aged between 5-15 years who were included in this study; 27 patients were 5-10 years(67%), 9 patients were 10-15 years (23%), 4 patients were of 5years(10%) with an average of 8.62 years.
- Predominance of male patients was 57.7% with mostly affected right extremity 57.7%. Fall on outstretched hand was most common accounts for 57.5% cases followed by sports injury 20% cases, fall from height 15% and remaining RTA.
- Commonly associated injuries with head injury (12.5% cases).Majority of cases were closed injury and open injury was excluded from the study.
- Most common level of fracture was middle shaft both bone fracture which accounts transverse (62.5%) and oblique pattern (37.5%) cases.
- All the patients were prepared and operated as early as possible once the general condition was stable and the patient was fit for surgery; with the Mean duration lag between time of injury and surgery was 1.5 days.
- Majority cases were of closed reduction (95%); fixed with 2 TENS nails.
- All cases were immobilized post-operatively for 4 weeks followed by physiotherapy.
- Time of union ranged from 6 to 10 weeks with a mean duration of 7.95 weeks.
- The majority of patients achieved full range of movements was within 6 months of follow-up.
- Restriction of moments was seen in 3 patients, in which 1 patient had pronation and supination restriction of 30 and 10 degrees respectively, second patient had pronation restriction of 15 degrees and last patient had 15 degrees of flexion restriction.
- The commonest complications encountered in this series were dull aching pain in 22.5%, hard-ware skin irritation in 12.5% and pin tract infection in 10% cases.

Conclusion

This study was conducted on 40 pediatric forearms both bone shaft fractures, treated by elastic intra-medullary nailing. The mean time of union was found to be 7.95 weeks. The majority of patients achieved full range of movements in 6 months.
The functional result evaluated by Andersons *et al* criteria showed 90% of patients had excellent results and remaining had good functional outcome. The common complications encountered in this series were pain, pin tract infection and hardware skin irritation.
In conclusion, TENs is an ideal device for the treatment of pediatric forearm fractures. It is a simple, safe, minimally invasive technique and has fewer complications. It also does not interfere with growth of the forearm and provides early union due to non-interference of fracture hematoma and minimal periosteal stripping. It is also associated with shorter hospital stay, rapid return to daily activity & school, avoids

long & uncomfortable immobilization & cosmetically it is acceptable as it only gives small scars at the sites of introduction of nails.

Reference

1. Nakamura T, Yabe Y, Horiuchi Y, Yamazaki N. *In vivo* motion analysis of forearm rotation utilizing magnetic resonance imaging. Clin Biomech (Bristol, Avon). 1999; 14(5):315-20.
2. Mayranpaa MK. Fractures in children: Epidemiology and associated bone health characteristics. Helsinki, University of Helsinki, 2012.
3. Mayranpaa MK, Makitie O, Kallio PE. Decreasing incidence and changing pattern of childhood fractures: A population-based study. J Bone Miner Res 2010; 25(12):2476-2483.
4. Wareham K, Johansen A, Stone MD, Saunders J, Jones S, Lyons RA. Seasonal variation in the incidence of wrist and forearm fractures, and its consequences. Injury 2003; 34(3):219-222.
5. Flynn JM, Waters PM. Single-bone fixation of both-bone forearm fractures. J Pediatr Orthop 1996; 16(5):655-659.
6. Parajuli NP, Shrestha D, Dhoju D, Dhakal GR, Shrestha R. Intramedullary nailing for paediatric diaphyseal forearm bone fracture. Kathmandu Univ Med J (KUMJ). 2011; 9(35):198-202.
7. Yalçinkaya M, Doğan A, Ozkaya U, Sökücü S, Uzümcügil O. Clinical results of intramedullary nailing following closed or mini open reduction in pediatric unstable diaphyseal forearm fractures. Acta Orthop Traumatol Turc 2010; 44(1):7-13.
8. Shoemaker SD, Comstock CP, Mubarak SJ, Wenger DR, Chambers HG. Intramedullary Kirschner wire fixation of open or unstable forearm fractures in children. J Pediatr Orthop. 1999; 19(3):329-337.
9. Richter D, Ostermann PA, Ekkernkamp A, Muhr G, Hahn MP. Elastic intra-medullary nailing: a minimally invasive concept in the treatment of unstable forearm fractures in children. J Pediatr Orthop. 1998; 18(4):457-461.