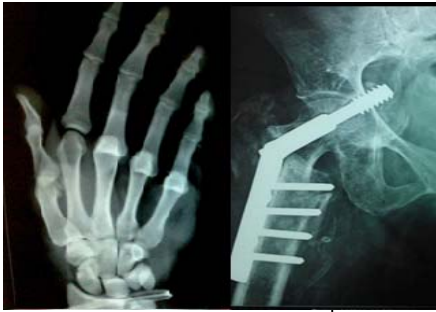



International Journal of Orthopaedics Sciences

ISSN: 2395-1958
IJOS 2017; 3(1): 356-359
© 2017 IJOS
www.orthopaper.com
Received: 23-11-2016
Accepted: 24-12-2016

Dr. Mathew Panackhottam
Research Scholar, Department
Of Orthopedics, Father Muller
Medical College, Mangalore,
Karnataka, India

Dr. Thomas Devasia
Senior Resident, Department of
Orthopedics, Father Muller
Medical College, Mangalore,
Karnataka, India

Dr. K Raghuvver Adiga
Head of Department and
Professor, Department of
Orthopedics, Father Muller
Medical College, Mangalore,
Karnataka, India

Dr. Vivian D'almeida
Assistant Professor, Department
of Orthopedics, Father Muller
Medical College, Mangalore,
Karnataka, India

Dr. Ashwin Kamath
Senior Resident, Department of
Orthopaedics, Father Muller
Medical College, Mangalore,
Karnataka, India

Correspondence

Dr. Mathew Panackhottam
Research Scholar, Department
Of Orthopedics, Father Muller
Medical College, Mangalore,
Karnataka, India

Comparative study on functional outcome of steroid injection vs conservative management in plantar Fasciitis

**Dr. Mathew Panackhottam, Dr. Thomas Devasia, Dr. K Raghuvver
Adiga, Dr. Vivian D'almeida and Dr. Ashwin Kamath**

DOI: <http://dx.doi.org/10.22271/ortho.2017.v3.i1f.53>

Abstract

Plantar fasciitis is the most commonly encountered cause of heel pain often presenting after periods of inactivity. Since its aetiology is obscure, there exist multiple modalities of treatment including both conservative and local injection of steroid. This study aims to evaluate the functional outcome following steroid injection versus conservative management of plantar fasciitis. Sixty two patients with heel pain with clinical diagnosis of plantar fasciitis in whom other causes of heel pain was ruled out were included. One group received plantar fascia stretching exercise, NSAID treatment and footwear modification while the other group received local steroid injection in addition to the exercises and footwear modification and NSAIDS. The VAS scores were re assessed on admission and after 2, 4 and 8 weeks. The conservative group showed a slow decline in VAS scores over 8 weeks whereas the steroid group showed a rapid fall in the first two weeks and a plateau at the end of 8 weeks with no major VAS score difference. There is a statistically significant drop in pain and VAS scores in the steroid group on comparing with the conservative group at 2 and 4 weeks follow up. However there was no significant difference in the VAS scores of steroid injection and stretching exercises by the 8th week. Since, local injection of steroid can sometimes causes unwarranted complications such as heel pad atrophy or Achilles tendon rupture, conservative management is preferred. However with good patient selection and adequate precaution steroid injection can be used for rapid pain relief and early return to activities.

Keywords: Plantar fasciitis, Heelpain, steroids, conservative

1. Introduction

Plantar fasciitis is the most common cause of inferior heel pain ^[1] accounting upto 15% of foot pain ^[2] It is synonymous with calcaneal spur which is the accumulation of calcium near the attachment of the plantar fascia on the calcaneum. Symptoms include insidious onset of pain particularly in the morning or after rest ^[3]. The pain is usually accompanied in situations of sudden weight gain, prolonged standing, change in activity, or incorrect training and is aggravated by increased activity like running, dancing, and playing basketball ^[4] Pathognomonic feature is pain on palpation of medial and lateral parts of the heel and on extending great toe ^[5].

The Pathology lies in the compression of the heel pad of fat and the calcaneal traction during the terminal stance phase of walking. This continually causes microtears and is associated with collagen degeneration and necrosis of plantar fascia ^[6].

In most persons it is a self-limiting condition, lasting from 6-18 months on an average and presenting commonly among women ages 40-60 years ^[7]. The diagnosis is usually clinical but in many patients the treatment can be refractory, often not responding to standard treatment protocols. In atypical cases the diagnosis can be augmented using high-resolution ultrasonography which shows increased thickness and hypoechoic fascia ^[8-10].

Treatment is primarily conservative which includes stretching exercises for the plantar fascia and Achilles tendon ^[11]. If these fail, corticosteroid injection into the heel to control painful symptoms is frequently used ^[12, 13]. The need for this study is to evaluate the functional outcome following steroid injection versus conservative management of plantar fasciitis.

2. Materials and Methods

The present study was carried out in Father Muller Medical College, Mangalore, on 65 patients from November 2015 to November 2016, 3 patients were lost to follow up. The patients who fulfilled the below mentioned criteria were included in the study (n= 62).

2.1 Inclusion Criteria

1. Patients with heel pain for more than 3 months
2. Patients above 20 years and below 70years

2.2 Exclusion Criteria

1. Calcaneal fractures, Hagelunds disease and pes planus
2. Systemic illnesses like diabetes, gout, rheumatoid arthritis
3. Patients below 20 years and above 70 years

After fulfilling the inclusion and exclusion criteria, informed consent was obtained from those included. A thorough clinical examination of all the patients presenting with heel pain was done and scored using the Visual Analog Score (VAS) (Figure 1) which is measured by means of a numerical range (0-10) on which 0 represented no pain and 10 the worst pain in each subject's experience.

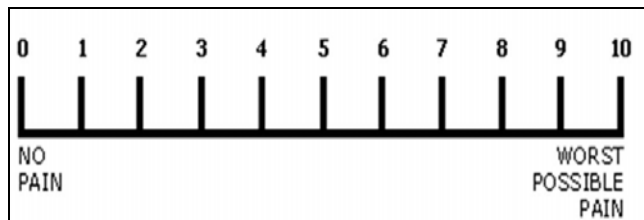
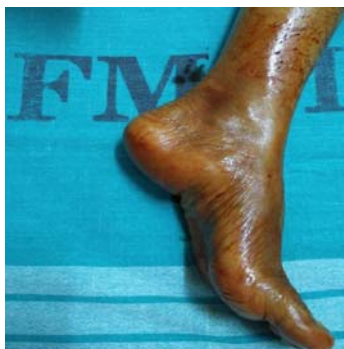
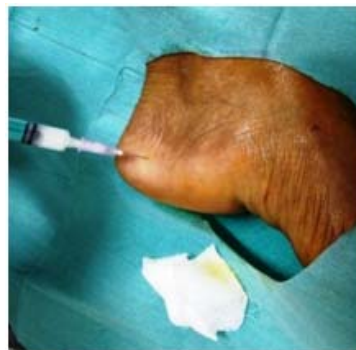
Fig 1: Visual Analog Score (VAS)

After assessing the initial score the patients were divided into two groups. In the conservative group, footwear modification, NSAIDS and physiotherapy like plantar fascia stretching exercises was done. The stretching exercise is done by making the patient sit on a chair and put his affected foot on the contralateral knee. The patient then pushes back the great toe and other toes with his hand while the contralateral hand is placed on the palm of the foot to feel for its stretching and stiffness during passive dorsiflexion of toes. The patient should hold this position for 10 seconds for adequate stretch. This exercise is done three times a day and with each set of 10 repetitions. In corticosteroid group, local injection of Triamcinolone (Kenacort) over the medial tubercle of calcaneum in a fan shaped manner in addition to conservative measures like footwear modification, NSAIDS and physiotherapy. The patient was reassessed in 2 weeks, 4 weeks and 8 weeks using VAS score.



A) Positioning



B) Infiltrating Kenacort

3. Results

Out of 62 cases taken for the study, 31 cases were treated conservatively with footwear modification, NSAIDS and physiotherapy while 31 patients received Triamcinolone injection in addition to the above mentioned.

Of the total 61 cases enrolled in this study 44.3% were male and 55.74% patients were female (Figure 2, Table 1). Most common age group was 41-50 year age group (42.62%). (Table 2) followed by 51-60 years (22.2%). Right side was predominantly symptomatic with 29 cases (47.5%) followed by left 21 cases (32.8%) and 12 cases were bilateral involvement (19.67%) (Figure 3, Table 3). Majority of the patients had severe pain on first consultation as depicted in the VAS analog score (Table 4). On first visit or week zero - the mean of the conservative treatment group was 7.58 and that of the corticosteroid group was 7.52 which was not statistically significant. By the follow up week 2, the mean dropped from 7.58 to 6.68 in the conservative group while the mean VAS scores dropped significantly in steroid group from 7.52 to 4.58. By the 4th week the mean VAS scores were 3.61 in conservative group while in the steroid group, the mean was at 2.68. By week 8 the conservative and steroid groups reached VAS scores of 1.42 and 1.45 respectively which was found to be statistically not significant. Thus the inference drawn is that steroid group shows a much faster decline in VAS scores as compared to the conservative group and hence earlier symptom free period.

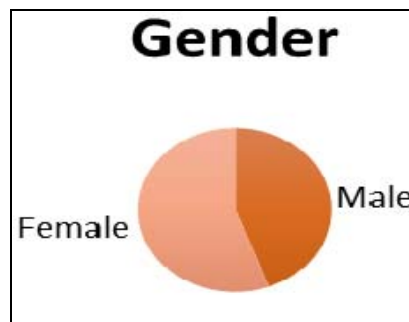


Fig 2: Gender Distribution

Table 1: Gender Distribution

		Group		Total
		CONSERVATIVE	STERIOD INJECTION	
SEX	F	17 54.8%	18 58.1%	35 56.5%
	M	14 45.2%	13 41.9%	27 43.5%
Total		31 100.0%	31 100.0%	62 100.0%

Table 2: Age distribution

Age distribution	Frequency	Percentage
21-30	2	3.3
31-40	11	16.39
41-50	26	42.62
51-60	16	26.23
61-70	7	11.48
	62	100

Table 3: Side of Involvement

	Frequency	Percent
Left	21	32.8
Right	29	47.5
Bilateral	12	19.67
Total	62	100.0

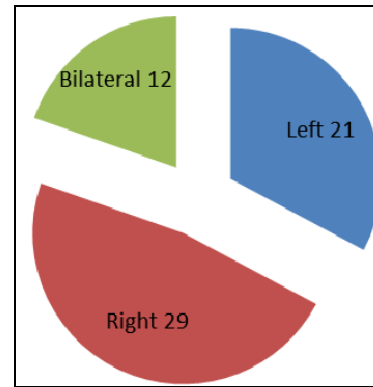


Fig 3: Side of Involvement

		N	Mean	Std. Deviation	t test p value	95% Confidence Interval for Mean		Minimum	Maximum
						Lower Bound	Upper Bound		
WK 0	CONSERVATIVE	31	7.58	.502	.617	7.40	7.76	7	8
	STERIOD INJECTION	31	7.52	.508	NS	7.33	7.70	7	8
WK 2	CONSERVATIVE	31	6.68	.475	.000	6.50	6.85	6	7
	STERIOD INJECTION	31	4.58	.620	HS	4.35	4.81	4	6
WK 4	CONSERVATIVE	31	3.61	.495	.000	3.43	3.79	3	4
	STERIOD INJECTION	31	2.68	.475	HS	2.50	2.85	2	3
WK 8	CONSERVATIVE	31	1.42	.502	.802	1.24	1.60	1	2
	STERIOD INJECTION	31	1.45	.506	NS	1.27	1.64	1	2

Table 4: VAS Score

4. Discussion

This study aimed to evaluate the functional outcome of two modalities of treatment of plantar fasciitis. The conservative group received NSAIDS, footwear modification like silicone heel pads or prefabricated insoles and stretching exercises to relieve stiffness of Achilles tendon and plantar fascia. However there have been no studies using only NSAIDS, hence no existence of their isolated use exists [14]. In footwear modification only embedded insoles have not been proven effective in alleviation of pain of plantar fasciitis, but when combined with stretching exercises have been significantly effective [15]. Crawford *et al.* evaluated the short-term effects of corticosteroid injection and it was compared with local anaesthetic in the treatment of heel pain in 106 patients and evaluated with VAS scores [16]. They concluded that heel steroid injection helped in pain alleviation in a short interval whereas local anaesthetic had no effect in treatment.

The demographics of this study showed female predominance, mostly ages 41-50 years with right side commonly affected, this is in concurrence with the study done by Frater *et al* [17]. One of the most common complications following steroid injection includes heel pad atrophy and Achilles tendon rupture [16], however the present study did not report any such complications even during 3 month follow up sessions.

The study had limitations like relatively small study group and shorter duration of follow up. Errors of measurement and patient adherence to exercise regimens could not be accounted for in this study. A randomized studies course will be needed in the future to validate the present study's findings.

5. Conclusion

There is a statistically significant drop in pain and VAS scores in the steroid group on comparing with the conservative group at 2 and 4 weeks follow up. However there was no significant difference in the VAS scores of steroid injection and stretching exercises by the 8th week. Complications such as weakness and sometimes rupture of plantar fascia and fat pad atrophy are documented to be common after corticosteroid injection. With

good patient selection and adequate precaution steroid injection can be used for rapid pain relief and early return to activities. So for long term outcome it is safer to carryout conservative management in form of foot wear modification and stretching exercises than steroid injection which is fraught with its share of complications. However, since there is rapid improvement in the symptoms following steroid injection it is suggested to use local steroid injection for patients requiring faster pain relief.

6. References

- Roxas M. Plantar fasciitis: diagnosis and therapeutic considerations. *Alter Med Rev.* 2005; 10:83-93.
- Cornwall MW, McPoil TG. Plantar fasciitis: etiology and treatment. *J Orthop Sports Phys Ther* 1999; 29:756-760.
- Solomon L, Warwick D, Nayagam S. *Apley's System of Orthopaedics and Fractures, 9th Edition.* London. Hodder Arnold the Ankle and Foot. 2010; 21:618-19.
- DeMaio M, Paine R, Mangine RE, Drez D. Plantar fasciitis. *Orthopedics.* 1993; 16:1153-63.
- Leach RE, Seavey MS, Salter DK. Results of surgery in athletes with plantar fasciitis. *Foot Ankle.* 1986; 7:156-61.
- Ozdemir H, Soyuncu Y, Ozgorgen M, Dabak K. Effects of changes in heel fat pad thickness and elasticity on heel pain. *Journal of the American Podiatric Medical Association.* 2004; 94(1):47-52.
- Wolgin M, Cook C, Graham C, Mauldin D. Conservative treatment of plantar heel pain: long term follow-up. *Fool Ankle Int* 1994; 15:97-102.
- Cardinal E, Chhem RK, Beauregard CG, Aubin B, Pelletier M. Plantar fasciitis: sonographic evaluation. *Radiology.* 1996; 201:257-9.
- Wall JR, Harkness MA, Crawford A. Ultrasound diagnosis of plantar fasciitis. *Foot Ankle* 1993; 14:465-70.
- Gibbon W, Long G. Plantar fasciitis: US evaluation. *Radiology,* 1997, 203-290.
- Tallia AF, Cardone DA. Diagnostic and therapeutic injections of the ankle and foot. *Am Fam Physician* 2003;

68:1356-1362.

12. Bordelon RL. Subcalcaneal pain: a method of evaluation and plan for treatment. *Clin Orthop*. 1993; 79:218-25.
13. Pfeffer GB, Baxter DE, Graves S, Michelson JD, Sammarco GJ. Symposium: the management of plantar heel pain. *Contemp Orthop*. 1996; 32:357-66.
14. Guijosa AF, Munoz IM, Fuente ME, Ituarte PC. Planter fasciitis: evidence based review of treatment. *Reumatol Clin*. 2007; 3(4):159-65.
15. Cole C, Seto C, Gazewood J. Planter fasciitis: Evidence Based Review of Diagnosis and Therapy. *American family Physician*. 2005; 72(11):2237- 42.
16. Crawford Ma, Davis PF, Severud E, Baxter DE. Painful heel syndrome: results of non-operative treatment. *Foot Ankle Int*. 1994; 15:531-535.
17. Frater C, Vu D, Van der Wall H, Perera C, Halasz P. Bone Scintigraphy Predicts Outcome of Steroid Injection for Planter Fasciitis. *J Nucl Med* 2006; 47:1577-1580.
18. Tatli YZ, Kapasi S. The real risks of steroid injection for planter fasciitis, with a review of conservative therapies. *Current Reviews in Musculoskeletal Medicine*. 2009; 2(1):3-9.