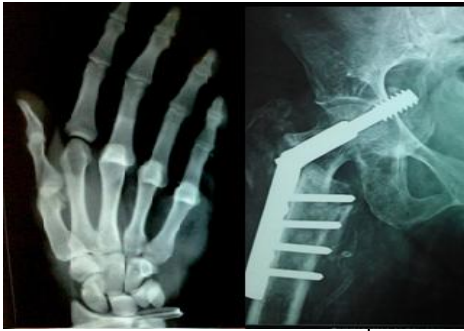

# International Journal of Orthopaedics Sciences

ISSN: 2395-1958  
IJOS 2017; 3(1): 220-224  
© 2017 IJOS  
www.orthopaper.com  
Received: 05-11-2016  
Accepted: 06-12-2016

**Dr. Mohammed Ashraf**  
Department Of Orthopaedics,  
Government T.D. Medical  
College, Alappuzha, Kerala,  
India

**Dr. Sumesh Shanker. V**  
Department Of Orthopaedics,  
Government T.D. Medical  
College, Alappuzha, Kerala,  
India

**Dr. Savad M.P**  
Department Of Orthopaedics,  
Government T.D. Medical  
College, Alappuzha, Kerala,  
India

**Dr. Jinumon Mathew**  
Department Of Orthopaedics,  
Government T.D. Medical  
College, Alappuzha, Kerala,  
India

**Dr. Nitheesh Chandran**  
Department Of Orthopaedics,  
Government T.D. Medical  
College, Alappuzha, Kerala,  
India

**Correspondence**  
**Dr. Mohammed Ashraf**  
Department Of Orthopaedics,  
Government T.D. Medical  
College, Alappuzha, Kerala,  
India

## The use of vacuum-assisted wound closure in musculoskeletal injuries

**Dr. Mohammed Ashraf, Dr. Sumesh Shanker. V, Dr. Savad M.P,  
Dr. Jinumon Mathew and Dr. Nitheesh Chandran**

DOI: <http://dx.doi.org/10.22271/ortho.2017.v3.i1d.35>

### Abstract

**Background:** This study was performed to evaluate the results of vacuum assisted wound therapy in patients with open musculoskeletal injuries or infected or exposed implant in situ (excluding arthroplasty) or traumatic wounds after debridement, infections after debridement at a tertiary care hospital, from 2013 to 2015.

**Materials and Methods:** 23 Patients were prospectively treated using NPWT {Negative Pressure Wound Therapy}. Mean Age of patient was 39±18yrs yrs (range, 18 to 76yrs). All patients had wounds with underlying tendon or bone exposure due to RTA OR CRUSH INJURY or ACUTE TRAUMA had to be debrided before applying NPWT.

The optimal level of negative pressure appears to be around 125mmhg and is more effective as evidenced if applied in a cyclical fashion at least three times a day for 15 mins either continuous or intermittent. In our study we use a sterile polyurethane sponge which is cut to suit the wound surface and placed to contact with entire wound surface. A romovac suction drain tube runs from the sponge to another tube, which is connected to suction apparatus. An adherent plastic sheet (cling drape or op sites) is used to adhere sponge to surrounding skin to form a closed system of wound.

**Results:** Exposed tendons, bones, raw area wounds and exposed implants were covered by granulation tissue successfully and was managed by either a skin graft or other definitive procedures. No major complication occurred that was directly attributable to treatment.

**Conclusion:** NPWT was found to facilitate rapid formation of granulation tissue on wounds with Exposed tendons, bones, raw area wounds and exposed implants hence shorten healing time and minimize secondary soft tissue defect coverage procedures. The technique we used is indigenous and modified as per our situation. This technique can be used in treatment of many of soft tissue injuries including degloving injuries, wounds and various soft tissue injuries prior to surgical closure, grafting or reconstructive surgeries. VAC is a cost effective and economical mode of treatment with suggestive evidence when compared with other conventional therapies with the added advantage of reduced hospital stay, no need for plastic surgery and better cosmetic acceptance.

**Keywords:** VAC, NPWT, NPWTi, negative pressure wound therapy, vacuum assisted closure

### Introduction

Delayed wound healing is a significant health problem, particularly in patients with compound joint injuries with exposed tendons ligaments and implants. It still remains a challenging task in orthopaedic surgery which in addition to the pain and suffering, failure of the wound to heal also imposes social and financial burdens. Vacuum-assisted closure (VAC) therapy has been developed as an alternative to the standard forms of wound management, which incorporates the use of negative pressure to optimise conditions for wound healing and requires fewer painful dressing changes. In 1993, Fleischmann *et al.* [1], described a more familiar version of NPWT using a polyurethane sponge. They noted that such a method had a positive effect on granulation tissue in the management of open fractures. The use of an open pore polyurethane dressing exposed to a subatmospheric pressure (125 mmHg below ambient pressure) was promoted by Argenta *et al.* [2] and forms the basis of today's contemporary dressings. [3,4,5,6]

**They subjected** 300 wounds of varying chronicity to their 'vacuum-assisted closure' technique until the wounds were either completely closed or covered by a split thickness skin Graft or local flap.

### Mechanism of Action

NPWT has evolved from the basic principles of wound healing [7]. The initial phase of wound healing involves both haemostasis and inflammation. During this period local vasoconstriction occurs and platelets collect at the damaged endothelium. Following a brief period of vasoconstriction the local vasculature dilates to allow an influx of polymorphonuclear leukocytes and other blood cells to the site of injury. This process is mediated by a host of growth factors and cytokines. The inflammatory phase lasts approximately 4-6 days and is followed by the proliferative phase lasting for around 21 days. This phase is dominated by fibroblast activity and is characterized by the formation of granulation tissue, neo-angiogenesis and re-epithelialisation. The final stage in wound healing is tissue remodeling and involves the renewal of collagen fibres and contraction of the wound through the activity of myofibroblasts. Local factors at the wound bed can have a negative effect on the wound healing process [7]. The presence of infection, oedema, high flowing exudates [7] and ischaemia can delay the healing process. Using negative pressure on the wound is thought to reduce these negative effects by promoting a lower bacterial count [4], increasing vascularity and cell proliferation [8] as well as promoting removal of exudate from the wound, promoting granulation tissue and encouraging the wound edges to come together [7]. Orgill *et al.* [9] described four primary effects of NPWT on wound healing: Macro-deformation - drawing the wound edges together leading to contraction. Stabilisation of the wound environment - ensuring it is protected from outside microorganisms in a warm and moist environment. Reduced oedema - with removal of soft tissue exudates. Micro-deformation- leading to cellular proliferation on the wound surface. Multiple secondary effects were noted to result from this including cell proliferation, increased blood flow and angiogenesis, reduction of inflammation, granulomatous tissue formation and the possibility of a decrease in bacterial load at the wound bed [7]. Two main theories prevail regarding the mechanism of action of NPWT used in conjunction with a reticulated open cell foam [10]. The first is based on the theory that tissue strain caused by NPWT has a stimulatory effect on cellular proliferation. This theory is supported by the fact that tissues have been shown to undergo a 5-20% strain when subjected to NPWT [11]. This level of strain is hypothesized to proactively cause cell division and angiogenesis in a process analogous to Ilizarovian distraction [8]. The second theory is focused on the effects of NPWT on the mechanical evacuation of excessive interstitial fluid and oedema [10]. By actively removing fluid at the wound bed it is felt that the local micro-circulation is improved and secondary necrosis is reduced. This hypothesis is supported by studies which have shown reduced need for debridement at the time of 'second look' for wounds treated with NPWT [12]. It is also supported by *in vivo* studies using a porcine model which have demonstrated acceleration in capillary formation and increase in luminal area in wounds treated with NPWT [13].

The purpose of this study is to evaluate the results of this therapy for the management of patients presenting with open musculoskeletal injuries.

### Materials and Methods

#### Aim of Study

To study the advantage of vacuum assisted closure in patients had wounds with underlying tendon or bone exposed or open

musculoskeletal injuries in extremities that required coverage procedures or exposed implants

### Design

#### Descriptive study

#### Setting

Study was conducted at Govt. T.D. Medical College, Alappuzha which is tertiary care centre

#### Period of study

The period of study was from June 2013 to May 2015

#### Sample size

23 Patients were prospectively treated using NPWT {Negative Pressure Wound Therapy}., mean patient age 27yrs (range 18 to 60yrs). Patients were selected from ortho wards (ward 4 & ward 12), TDMCH

#### Inclusion criteria

##### Age b/w 18 to 60 yrs.

Traumatic ulcers

Patients with open musculoskeletal injuries in extremities that required coverage procedures /

Acute traumatic soft tissue defects/ infected soft tissue defects

#### Exclusion criteria

Fistulas to organs /body cavities Exposed blood vessels/nerves

Gangrenous foot Patients undergoing anticoagulant therapy Malignancy Patients below 13yrs and above 70yrs untreated osteomyelitis Exposed anastomotic sites Participation in the study did not deviate from the standard care of the acute wound. All patients for wound management were subjected to -standard radiological assessment of the injured wound/limb - Routine haematological investigation eg. complete blood count, ESR, blood sugar, HbsAg, gram stain & culture All patients with wounds were given the standard care necessary for the acute wounds and managed according Materials used for study Transparent sterile material (OP-SITE) Transparent Adhesive plaster (cling drape) Sponge (pre sterilized) -which is obtained from the TKR /THR Prosthesis packing Suction drain (Romovac) and tubing's Suction Apparatus in the wards

#### Materials used

#### Sequence of Procedure

##### Wound preparation

Wound Preparation was done prior to application of VAC. All dressings were removed and discarded. A culture swab for microbiology was taken before wound irrigation with normal saline. Wound debridement was done and adequate haemostasis was achieved. At day zero and whenever dressings were subsequently changed the wound was photographed and measurements of wound made by Vernier Calliper. Any associated complications, measurements and findings were recorded on day zero and day seven. Placement of foam In our study we use a sterile polyurethane sponge which is cut to suite the wound surface and placed to contact with entire wound surface, polyurethane with 400-600 microns size having hydrophobic open cell structured network. Such sizes of pores are most effective at transmitting mechanical forces across the wound and provide an even distribution of negative pressure over the entire wound bed to aid in wound healing. A suction drain tube is placed between the foam or is passed through its centre.

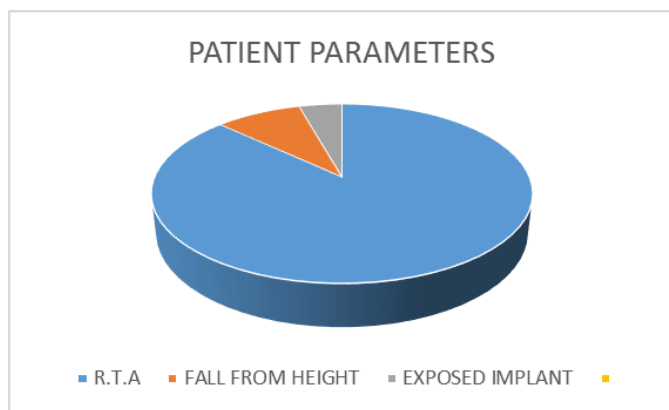
**Sealing the wound**

The site is sealed with an adherent plastic sheet (cling drape or op sites) is used to adhere sponge to surrounding skin to form a closed system of wound which includes three to five centimetres of surrounding healthy tissue to ensure a tight seal.

The Application of Negative Pressure Controlled pressure was uniformly applied to all tissues on the inner surface of the wound. Pressure was applied in a cyclical fashion at least three times a day for 15 mins either continuous or intermittent connecting to a suction apparatus available in the ward. The dressings were changed on the seventh day.

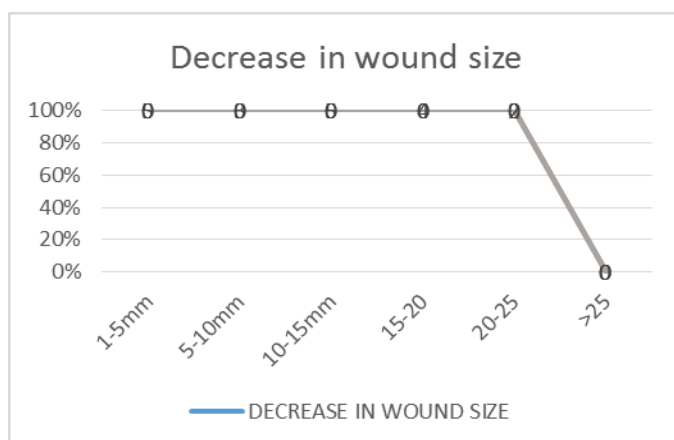
**Observations & Results**

All patients had suffered an acute trauma. Road traffic accident was found to be most common cause with 20 (86.95%) patients, 2 (8.69%) patients had a fall from height & 1(4.34%) had an exposed implant. According to Gustilo Anderson classification, out of 23 patients, 15 patients had grade IIIB injury, 3 had IIIa injury, and 5 had grade II injury.



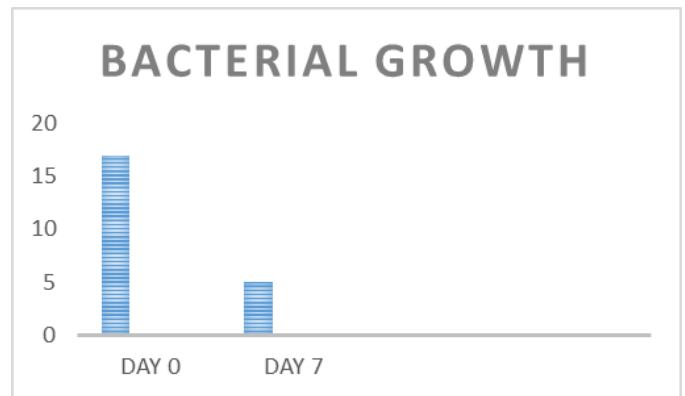
**Decrease in Wound Size.** There was significant decrease in wound size from day zero to day seven

Measurements (mm)	VAC(n=20)
1-5	5(25%)
5-10	3(15%)
10-15	5(25%)
15-20	4(20%)
20-25	2(10%)
>25	1(5%)



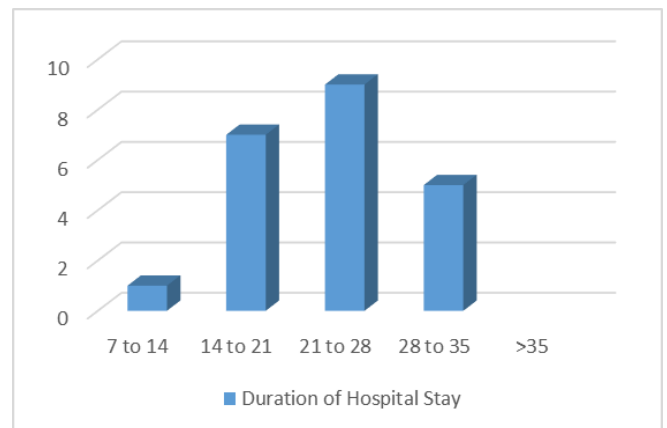
**Bacterial Growth:** There was significant decrease in the bacterial growth with VAC

Bacterial growth	Day 0	Day 7
Bacterial growth (n = 23).	17	5



**Duration of hospital stay**

Duration of hospital stay (days)	Cases
7-14	1
14-21	7
21-28	9
28-35	5
>35	1



Exposed tendons, bones, raw area wounds and exposed implants were covered by granulation tissue successfully and was managed by either a skin graft or other definitive procedures. No major complication occurred that was directly attributable to treatment.

**Discussion**

Negative pressure dressings are an attractive option for the interim management of open fracture wounds. The negative pressure dressing consists of a polyurethane ether foam sponge that is cut to fit the contours of the wound. Into the sponge is placed a noncollapsible evacuation tube, evacuation tube is in turn connected to a suction apparatus which collects the effluent. The dressing is sealed with an occlusive drape. The typical setting is 120 mm sub atmospheric pressure for the first 48 hours, then intermittent mode (5 minutes on, 2 minutes off) for the remaining duration of therapy. Clinical studies demonstrated that wound healing is accelerated using this cyclic mode [2, 8, 9, 10].

Dehiscid and infected surgical wounds have been treated with negative pressure dressings until a split thickness skin graft can be placed over the wound bed. It's of great use for patients who are poor candidates for traditional wound management strategies such as free microvascular tissue transfers. Acute wounds such as large soft tissue avulsions and gunshot wounds have been managed successfully with negative pressure dressings. It's very useful adjuvant in the management of wounds associated with limb threatening

injuries or either failed free flap coverage or wounds too large to adequately cover with free flaps, or infected wounds waiting for free flap coverage were treated with negative pressure dressings. Although some needed additional surgical procedures, no amputations occurred and adequate soft tissue coverage was obtained in all patients.

The wound healing is influenced by the available vascular supply and the rate of formation of new capillaries and matrix molecules. The changes are influenced by locally acting growth factors that affect the processes including proliferation, angiogenesis, chemotaxis and migration, gene expression, proteinases, and protein production. Disruption of any of these factors will definitely affect the healing process, resulting in a chronic or nonhealing wound.

A significant increase in blood flow and a decrease in bacterial colonization of wound is observed following the application of sub atmospheric pressure. An increase in circulation and oxygenation to compromised or damaged tissue enhances the resistance to infection, spontaneous healing and healing following surgical intervention are correlated with tissue bacterial counts of less than 10<sup>5</sup> organisms per gram of tissue. A Higher level interferes with wound healing. An increase in the local tissue oxygen levels reduce the growth of anaerobic organisms, which have been attributed to decreased healing rates. An increased flow also makes large quantity of oxygen available to neutrophils for the oxidative bursts that kill bacteria.

There are several advantages negative pressure dressings have for acute open fracture wounds. First, the occlusive dressing completely isolates the wound, decreasing the risk of secondary contamination from the environment. Second, the negative pressure dressing removes edema from the limb. Edema present in the wound bed increases the pressure in the tissue, slowing capillary inflow, and impeding venous and lymphatic drainage. Removal of edema by the negative pressure dressing improves capillary blood flow, which increases the delivery of oxygen and nutrients to the wound. Removal of edema fluid also removes compounds that are detrimental to wound healing. Factors removed from chronic wound fluid have been found to suppress the proliferation of keratinocytes, fibroblasts, and vascular endothelial cells. Elevated levels of proteases (e.g. collagenase, elastase) and their degradation products are also found in this fluid. Third, bacterial proliferation is limited Morykwas and Argenta [7], Banwell *et al.* [20], and Morykwas *et al.* [21] which showed clearance of bacteria from infected wounds using VAC therapy. On the other hand, Weed *et al.* [11] while quantifying bacterial bio burden during negative pressure wound therapy concluded with serial quantitative cultures that there is no consistent bacterial clearance with the VAC therapy, and the bacterial growth remained in the range of 10<sup>4</sup>–10<sup>6</sup>. Thomas first postulated that application of mechanical stress would result in angiogenesis and tissue growth. Unlike sutures or tension devices, the VAC can exert a uniform force at each individual point on the edge of the wound drawing it toward the centre of the defect by mechanically stretching the cells when negative pressure is applied [12,13]. This allows the VAC to move distensible soft tissue, similar to expanders, towards the centre of the wound, thereby decreasing the actual size of the wound DeFranzo *et al.* reported that NPWT, when used on exposed bone and tendon, resulted in the formation of granulation tissue over the exposed area and sometimes obviated the need for flap surgery. DeFranzo *et al.* also reported that the use of NPWT reduced tissue oedema, and diminished the circumference and surface area of the wound

[14, 15] Our study showed that in VAC on day 8 there were 60% of patients who had no bacterial growth.

Our study showed a decrease in size of 1 to 5 mm in 25% of patients and a decrease in size of 10 to 20 mm was seen in 45% of patients and a decrease in size of more than 25 mm was seen in 5% in VAC group.

Previous studies by Joseph *et al.*, Morykwas and Argenta, and Morykwas *et al.* have shown that VAC was effective in shrinking the widths of wound over time compared to standard wound dressings. Kaplan M, Daly D, Stenkowski S *et al.* [16] studies on Acute-care trauma wound patients receiving early NPWT/ROCF demonstrated significant reductions in length of stay, treatment days, and ICU stay, which resulted in significant reduced patient treatment costs.

Open musculoskeletal injuries are highly prone for nonunion and infection which require an urgent irrigation and debridement. Since majority of these wounds are left open and necessitate their repeated debridement, results in large soft tissue defects, early coverage of these exposed bone, tendons, and neurovascular structures is crucial. This will decrease the risk of infection, nonunion, and further tissue loss. In such scenario VAC therapy can be effective to overcome all these problems.

Complications of negative pressure dressing treatment can occur. Some patients complain about pain with initiation of negative pressure to the wound. This usually abates over time. A few problems due to improper dressing application. Erythema around wound edges can be seen with a dressing that extends to the intact skin. This erythema can be mistaken for cellulitis, but really represents hyperaemia, and will resolve quickly with discontinuation of therapy. Necrosis of the skin around the evacuation tube has been observed if the occlusive drape is applied too tightly in this region. Ingrowth of granulation tissue into the sponge has been observed, most commonly if the dressing has been in place over 72 hours.

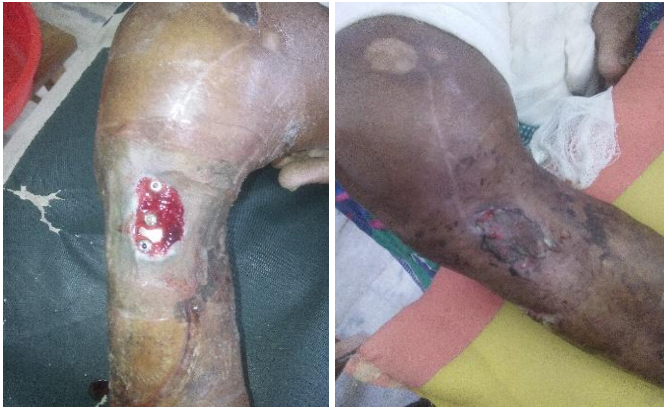VAC is most useful in difficult cavity or highly exudative wounds. VAC is a useful tool in moving a wound to a point where more traditional dressings or more simple surgical reconstructive methods can be used. Our modified technique of creating a vac is very cost effective and economical mode of treatment with suggestive evidence when compared with other conventional therapies with the added advantage of reduced hospital stay, no need for plastic surgery and better cosmetic acceptance. Wounds healed with good granulation tissue and decision of split thickness skin graft taken individually depending upon the case.

### Conclusion

NPWT was found to facilitate rapid formation of granulation tissue on wounds with Exposed tendons, bones, raw area wounds and exposed implants hence shorten healing time and minimize secondary soft tissue defect coverage procedures. It's safe and effective method of treatment of open musculoskeletal injuries it can be an adjunct for the treatment, although traditional soft tissue reconstruction may be required to obtain adequate coverage, NPWT device appears to decrease their overall need. Vac improves pus culture and sensitivity. It decreases the hospital stay.

### Conflict of Interests

The author confirms that there is no conflict of interests of any sort with this article content.



**Fig:** An exposed implant beginning to be covered after first vac application and follow up after skin grafting

## References

1. Fleischmann W, Strecker W, Bombelli M, Kinzl L. [Vacuum sealing as treatment of soft tissue damage in open fractures]. *Unfallchirurg.* 1993; 96(9):488-92. German. PubMed PMID: 8235687.
2. Argenta LC, Morykwas MJ. Vacuum-assisted closure: a new method for wound control and treatment: clinical experience. *Ann Plast Surg.* discussion 577. PubMed PMID: 9188971, 1997; 38(6):563-76;
3. Müllner T, Mrkonjic L, Kwasny O, Vécsei V. The use of negative pressure to promote the healing of tissue defects: a clinical trial using the vacuum sealing technique. *Br J Plast Surg.* PubMed PMID: 9176007. 1997; 50(3):194-9.
4. The Mechanism of Action of the Vacuum-Assisted Closure Device, *Plastic & Reconstructive Surgery*: 2008; 122(3):786-797
5. Bucalo B, Eaglstein WH, Falanga V. Inhibition of cell proliferation by chronic wound fluid. *Wound Repair Regen.* PubMed PMID: 17163887. 1993; 1(3):181-6.
6. Falanga V. Growth factors and chronic wounds: the need to understand the microenvironment. *J Dermatol.* 1992; 19(11):667-72. PubMed PMID: 1293152.
7. Singer AJ, Clark RA. Cutaneous wound healing. *N Engl J Med.* Review. PubMed PMID: 10471461, 1999; 341(10):738-46.
8. Singh S, Mackey S, Soldin M. VAC it - Some techniques on the application of VAC dressings. *Ann R Coll Surg Engl.* PubMed PMID: 18333292; PubMed Central PMCID: PMC2443317, 2008; 90(2):161-2.
9. The Evidence-Based Principles of Negative Pressure Wound Therapy in Trauma & Orthopedics *Open Orthop.* Published online 2014 un 27, 2014; 8:168-177.
10. Morykwas MJ, Simpson J, Pungler K, Argenta A, Kremers L, Argenta J. Vacuum-assisted closure: state of basic research and physiologic foundation. *Plast Reconstr Surg.* Review. PubMed PMID: 16799379, 2006; 117(7):121S-126S.
11. Weed T, Ratliff C, Drake DB. Quantifying bacterial bioburden during negative pressure wound therapy: does the wound VAC enhance bacterial clearance? *Ann Plast Surg.* discussion 279-80. PubMed PMID: 15156981, 2004; 52(3):276-9.
12. Virchow Archives for Pathological Anatomy and Physiology and Clinical Medicine About the Histomechanik the vascular system and the pathogenesis of angiosclerosis. 1911; 204(1):1-74
13. Ilizarov GA. The tension-stress effect on the genesis and growth of tissues. Part I. The influence of stability of fixation and soft-tissue preservation. *Clin Orthop Relat*

- Res. PubMed PMID: 2910611, 1989; (238):249-81.
14. DeFranzo AJ, Marks MW, Argenta LC, Genecov DG. Vacuum assisted closure for the treatment of degloving injuries. *Plast Reconstr Surg.* 1999; 104:2145-2148. 10.1097/00006534-199912000-00031
  15. DeFranzo AJ, Argenta LC, Marks MW, Molnar JA, David LR, Webb LX *et al.* Teasdall RG. The use of vacuum-assisted closure therapy for the treatment of lower-extremity wounds with exposed bone. *Plast Reconstr Surg.* 2001; 108(5):1184-91. PubMed PMID: 11604617.
  16. Kaplan M, Daly D, Stemkowski S. Early intervention of negative pressure wound therapy using Vacuum-Assisted Closure in trauma patients: impact on hospital length of stay and cost. *Adv Skin Wound Care.* 2009; 22(3):128-32. doi: 10.1097/01.ASW.0000305451.71811.d5. PubMed PMID: 19247014.