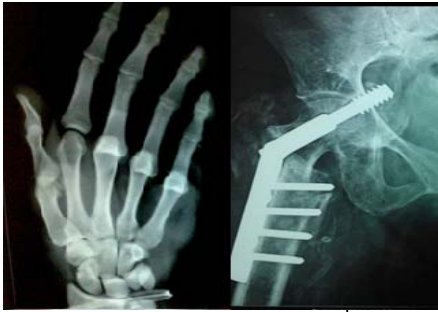



# International Journal of Orthopaedics Sciences

ISSN: 2395-1958  
IJOS 2017; 3(1): 216-219  
© 2017 IJOS  
www.orthopaper.com  
Received: 04-11-2016  
Accepted: 05-12-2016

**Dr. Amit Mishra**  
Assistant Professor, Department  
of Orthopaedics, BRD Medical  
College, Gorakhpur, Uttar  
Pradesh India

**Dr. Abhinit K Sinha**  
Senior Resident, Department of  
Orthopaedics, BRD Medical  
College, Gorakhpur, Uttar  
Pradesh India

**Dr. Ashok Yadav**  
Assistant Professor, Department  
of Orthopaedics, BRD Medical  
College, Gorakhpur, Uttar  
Pradesh India

**Dr. Deepak Pandey**  
Senior Resident, Department of  
Orthopaedics, BRD Medical  
College, Gorakhpur, Uttar  
Pradesh India

**Dr. Surendra K**  
Lecturer, Department of  
Orthopaedics, BRD Medical  
College, Gorakhpur, Uttar  
Pradesh, India

**Dr. Vivek Prakash**  
Post Graduate Trainee,  
Department of Orthopaedics,  
BRD Medical College,  
Gorakhpur, Uttar Pradesh India

## Correspondence

**Dr. Amit Mishra**  
Assistant Professor, Department  
of Orthopaedics, BRD Medical  
College, Gorakhpur, Uttar  
Pradesh India

## Original Article

### Clinical study of functional outcome of intertrochanteric fracture treated by Trochanteric fixation nail (TFN) in North Indian population: A prospective study

**Dr. Amit Mishra, Dr. Abhinit K Sinha, Dr. Ashok Yadav, Dr. Deepak Pandey, Dr. Surendra K and Dr. Vivek Prakash**

DOI: <http://dx.doi.org/10.22271/ortho.2017.v3.i1.d.34>

#### Abstract

**Background:** Trochanteric fixation nail (TFN) is a newer device used for the treatment of the intertrochanteric femoral fracture. This study reports the outcome in such fractures treated by using the TFN at northern part of India.

**Materials & Methods:** In a prospective study from October 2014 to September 2016, we included 64 patients (38 female, 36 male; mean age 59.25years; range 21 to 80 years) who were treated with the TFN for intertrochanteric hip fractures and followed up minimum of six months. According to the AO/OTA classification, there were 14 cases of type 31A1, 42 cases of type 31A2, and 08 cases of type 31A3 fractures. The patients were evaluated clinically (Harris hip score) and radiographically for a minimum period of six months with all complications were recorded.

**Results:** In our series, most of the patients sustained trauma after simple fall (87.5%) and 12.5% as a result of road traffic accident (RTA). Fractures were classified according to AO/OTA classification, 14 patients had 31-A1 type of fracture, 42 had 31-A2 type of fracture and rest 8 had 31-A3 type of fracture. Mean average delay for surgery was 11.56 days (range 3 to 27 days). Out of 64 patient post-operative radiograph showed near anatomic reduction in 60 patients. We found 6 cases of intraoperative complication in the form of 2 cases of fixation in varus and 4 cases of loss of reduction. We found 8 cases of post-operative complication in which 2 cases of superficial and deep wound infection and 6 cases of varus malunion. No fractures of the femoral shaft, Z-Effect and reverse Z-Effect were noticed. We did not encountered any case of implant failure or avascular necrosis of femoral head. All the patient shows radiological union in our study with mean time of union was 11.02 weeks (12-18 weeks). According to harris hip score, we had good to excellent results in 88%, fair to poor result in 12% of cases.

**Conclusions:** With proper patient selection, good instrumentation, image intensifier and surgical technique, TFN is a good choice in the management of intertrochanteric fractures leading to high rate of bone union and good functional result with minimal soft tissue damage.

**Keywords:** AO: Arbeitsgemeinschaft für Osteosynthesefragen, OTA: orthopaedic and trauma association, PFN: proximal femoral nail, TFN: trochanteric fixation nail, RTA: road traffic accident

#### 1. Introduction

Intertrochanteric fracture is one of the most common fractures of the hip especially in the elderly. The incidence of intertrochanteric fracture is rising because of the increasing life expectancy superadded with osteoporosis. These fractures are three to four times more common in women and the mechanism of injury is usually due to low-energy trauma like a simple fall [1]. The presence of osteoporosis in intertrochanteric fractures is important because fixation of the proximal fragment depends entirely on the quality of cancellous bone present [2]. The treatment of intertrochanteric fractures remains a challenge. The treatment of intertrochanteric fracture have been described by various operative procedures with different implants. Extramedullary fixation (dynamic hip screw) and intramedullary implants (TFN, PFN, Gamma Nail etc.) are two methods of fixations for intertrochanteric fractures. In various studies stable fractures can be treated very well with dynamic hip screw with good results but

unstable fracture showed variable results [3]. Intramedullary fixation have better biomechanics than extramedullary fixation [4-5]. The aim of our study on outcome of trochanteric fixation nail (TFN) in the management of intertrochanteric fractures which influence the postoperative mobility and fracture union.

## 2. Material and method

The prospective case series study was conducted in the department of orthopedics surgery, BRD medical college, Gorakhpur over a period of 24 months from October 2014 to September 2016 in patients having intertrochanteric fractures of femur. All cases of intertrochanteric fractures were included in the study except compound and pathological fractures. All patients were examined and investigated with radiographs of pelvis. Skeletal traction was applied to the affected limb in all cases. Preoperatively, radiographs were reviewed again and fractures classified according to Orthopaedic Trauma Association (AO/OTA) classification. Neck-shaft angle and medullary size were assessed. All patients were infused one dose of injection cefuroxime 1.5gm intravenously 6 hour before operation after negative skin test and 12 hourly for next 48 hour after operation.

**2.1 Trochanteric fixation nail:** The length of used trochanteric nail is 18mm, the proximal diameter of nail is 15 mm and diameter of distal part of nail is variable from 9mm to 12mm. In 12 cases we had used nail of diameter 9mm, in 48 cases nail of 10mm diameter while in 4 cases nail of 11 mm diameter was used.

**2.2 Operative procedure:** Patient were positioned supine on a standard fracture table. All the fractures were reduced by abduction of the femur with traction. The alignment of the medial cortex in AP view and reduction of the proximal fragment and shaft fragment in lateral view was checked. After preparation and incision was made five to six cm in size extending proximally from the tip of the greater trochanter. The entry point was made just medial to the tip of trochanter at the junction of its anterior 2/3<sup>rd</sup> and posterior 1/3<sup>rd</sup> with a curved bone awl. After that guide wire was inserted and the position of guide wire is checked under C-Arm in AP and lateral view. Distal reaming of the femoral canal is done with graded cannulated reamers and proximal femoral canal was reamed with 15mm cannulated reamer. Nail is inserted and position is checked under C-Arm. Cervical lag screw and derotation screw were passed into the head and neck over guide pin. Distal locking was done with the help of two 4.9mm locking boards after drilling with 4.0mm drill bit.

Quadriceps exercise started as early pain relieved dressing

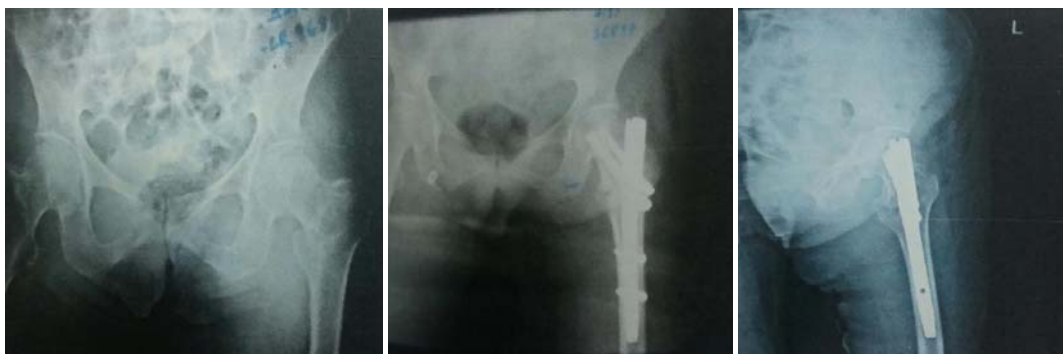changed on third post-operative day weight bearing allowed on third post-operative day or as early as pain relived when fixation is stable. Follow up done at two week, one month, 3 month and six month. Clinical, radiological examination and functional evaluation by Harris Hip Score done at each follow up.

## 3. Results

From 2014 to 2016, we treated 64 patients with intertrochanteric fractures with trochanteric fixation nail (TFN). In our study, out of 64 cases 36 patients were male and 28 were female. Mean age of the patients was 59.25 year (range 21-80). Most of the patients sustained trauma after simple fall (87.5%) and 12.5% as a result of road traffic accident (RTA). Fractures were classified according to AO/OTA classification, 14 patients had 31-A1 type of fracture, 42 had 31-A2 type of fracture and rest 8 had 31-A3 type of fracture. Mean average delay for surgery was 11.56 days (range 3 to 27 days). In most cases delay was due to optimisation of the patient for surgery. Average duration of surgery was 59.875 minutes (65 to 95 minutes). We achieved closed reduction in 56 patients and rest 8 patients were reduced by open reduction. Out of 64 patient, post-operative radiograph showed near anatomic reduction in 60 patients. The fracture consolidated in all 64 patients. 48 (75%) showed union at the end of 12 weeks and 16 (25%) showed union by end of 18 weeks. Complication were divided in to intra-operative and post-operative. We found 6 cases of intra-operative complication in the form of 2 cases of fixation in varus and 4 cases of loss of reduction. We found 8 cases of post-operative complication in which 2 cases were of superficial and deep wound infection and 6 cases were of varus malunion. No fractures of the femoral shaft, Z-Effect and reverse Z-Effect were noticed.

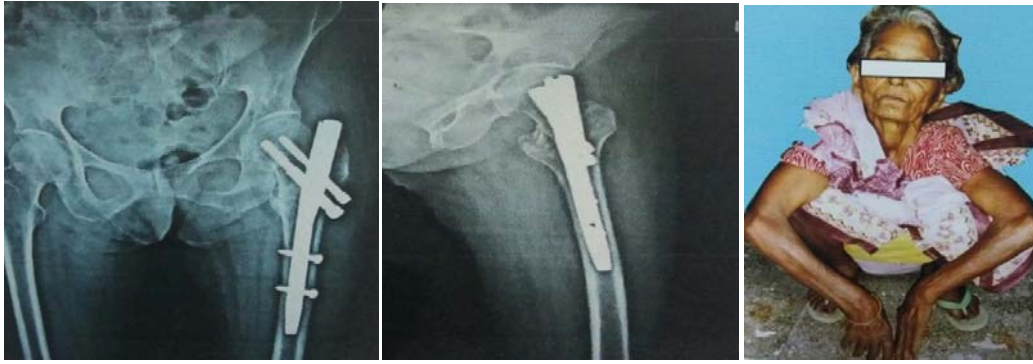Patient were functionally evaluated by Harris Hip Score at regular follow-ups. In our study 34 patients were having no post-operative pain at 12 weeks, 22 patients had slight post-operative pain and 8 patients had mild post-operative pain. There was significant improvement in pain with subsequent follow-ups. In our study 88.0% of cases showed good to excellent results (excellent=14, good=42). Rest 12% of cases showed fair to poor results (fair=4 and poor=4). No patients had fixed flexion deformity more than 30 degree, fixed abduction deformity more than 10 degree, fixed internal rotation in extension more than 10 degree and limb length discrepancy more than 2 cm. There was no significant difference in abductor function in which malreduction was occurred.

Case 1: 65 year old, Female



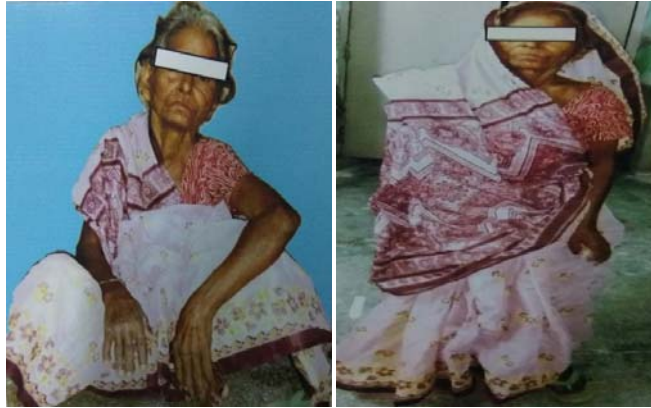Pre-Operative

Immediate post-operative xray



Post-Op 12 weeks

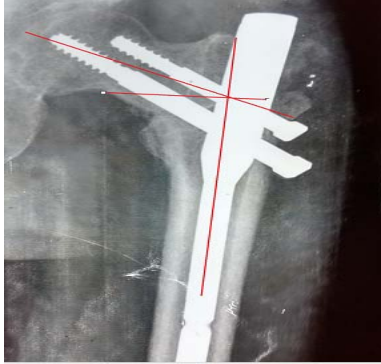Squatting at 3 month



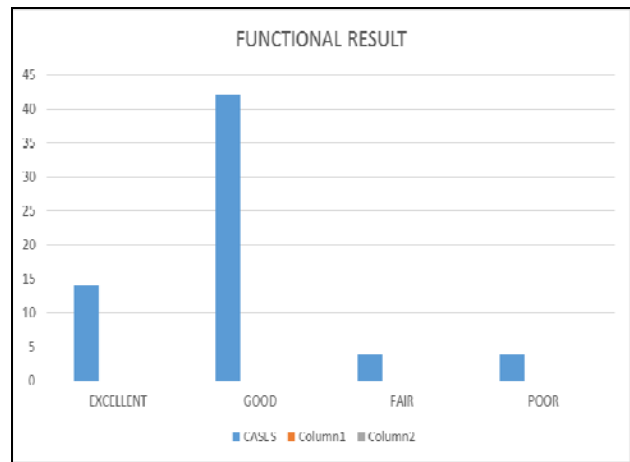
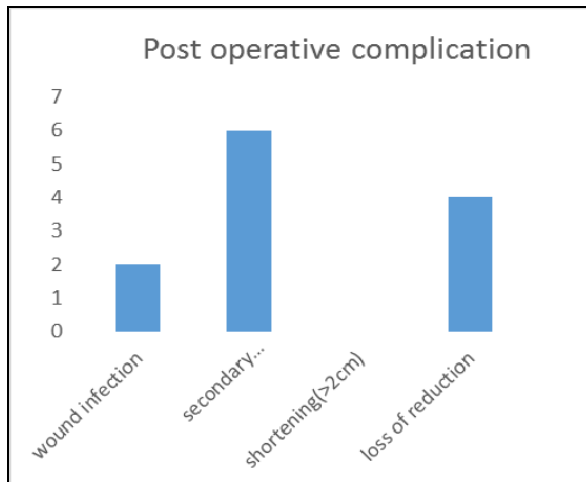
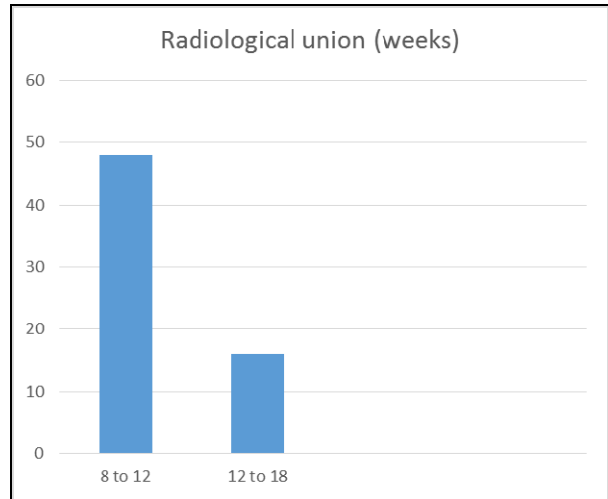
Crossed leg at 3 months

Standing without support at 3 months

Complication



Varus malunion



#### 4. Discussion

In our study, out of 64 patients 36 patients were male and 28 were female. The ratio of male to female was 1.3:1 for this group. This clearly reflected the more active life-style of male in Indian population. The result were opposite to the study done by David G. Lovelle<sup>[6]</sup>, who found trochanteric fractures more common in women and the ratio of female to male 3:1 but Gadgone and Salphale *et al*<sup>[7]</sup> found 62% male and 38% were female in their study. The distribution of the fracture types showed a large number of 31-A2 fractures 42 (65.6%) followed by 14 patients had type 31-A1 fracture and 8 patient had type 31-A3 fracture. In our study, right and left sides were nearly equally involved. Most common mode of injury is simple fall which is comparable to other studies in age above 50 years. In a study on unstable intertrochanteric fracture by Morihara *et al*<sup>[8]</sup>, 88.2% of patients had 31-A2 type of fracture and rest 11.7% had 31-A3 type of fracture. In our study average hospital stay was 10.96 days and average duration between injury and surgery was 11.56 days (ranging from 3 to 24 days) due to time taken to optimize the patient for surgery, while in a study by Rahul M Salunkhe *et al*<sup>[9]</sup> had average hospital stay of 12.5 days. In a study by Tyllianakis *et al*<sup>[10]</sup>, average duration between injury and surgery was 3 days (range 1-7 days).

In present study, the average duration of surgery was 59.875 minutes (ranging from 45 minutes to 85 minutes). Gadgone and Salphale<sup>[7]</sup> had similar findings in their study with average duration of surgery of 50 minutes (ranging from 45 to 65 minutes). The duration for surgery decreased as we gain experience of this new technique and being familiar with the instrumentation. In this study the average blood loss was 124.5 ml (ranging from 50-199 ml) Hardy *et al*<sup>[11]</sup> in their study showed that when operating with cephalo-medullary implant in unstable trochanteric fracture the average blood loss was 44ml (ranging from 24 to 144 ml). However average blood loss was 198 ml which is more in extra-medullary implant when compared with cephalo-medullary implant.

In the present study, the association of varus angulation of 1-4 degree was found in two patients (3.125%), varus angulation of 5 to 15 degree was found in 4 patients (6.25%). Russel *et al*<sup>[12-13]</sup> concluded that acceptable reduction is < 5 degree of angulation in any plain and they had similar findings with malreductions more than 5 degree in 10% cases and acceptable reduction in 90% cases which is comparable to our study. In our study 34 patients (53.125%) walked with partial weight bearing with support within 5 days post operatively. 6 patients (9.375%) walked with partial weight bearing after 1 week and 16 (25%) cases walked with support after two weeks. In 6 patients delayed weight bearing was allowed after 3 weeks due to malreduction. In present study post-operative patients were followed upto minimum of 12 weeks and maximum of 1 year and were assessed radiologically for union. Out of 64 patients 48 patients showed union at the end of 12 weeks and 16 patients showed union by the end of 18 weeks. Gadgone and Salphale<sup>[7]</sup> in their study had similar findings who had union in all cases between 15 weeks to 21 weeks.

Functional assessment was done by Harris Hip Score in which 14 patients had excellent score, 42 patients had good score, 4 patient had fair score and 4 patients had poor score. So 87.5% cases showed good to excellent result and rest 12.5% cases fair to poor result.

#### 5. Conclusion

We can conclude in our study that with proper patient selection, good instrumentation, image intensifier and surgical

technique, TFN is a good choice in the management of intertrochanteric fractures leading to high rate of bone union and good functional result with minimal soft tissue damage.

#### 6. References

1. Dimon JH, Hughston JC. Unstable intertrochanteric fractures of the hip. *J Bone Joint Surg Am.* 1967; 49(3):440-50.
2. Babhulkar SS. Management of trochanteric Fractures. *Indian J Orthop.* 2006; 40:210-8.
3. Schipper IB, Marti RK, Werken C, Van Der. Unstable trochanteric femoral fractures: extramedullary or intramedullary fixation Review of literature, 2004.
4. Friedl W, Clausen J. Experimental examination for optimized stabilisation of trochanteric femur fractures, intra- or extramedullary implant localisation and influence of femur neck component profile on cut-out risk. *Chirurg* 2001; 72:1344-52.
5. Curtis MJ, Jinnah RH, Wilson V, Cunningham BW. Proximal femoral fractures: a biomechanical study to compare intramedullary and extramedullary fixation. *Injury.* 1994; 25:99-104.
6. Dean GL, David S, Jason HN. Osteoporotic pertrochanteric; management and concurrent controversies. *J Bone Jt Surg (Am)* 72-B: 737-752.
7. Gadgone WM, Salphale YS. Proximal femoral nail – an analysis of 100 cases of proximal femoral fractures with an average follow up of 1 year. *International Orthopaedics* 2007; 31(3):403-8.
8. Morihara T Arai Y, Tokugawa S, Fujita S. Proximal femoral nail for treatment of trochanteric femoral fractures. *Journal of Orthopaedic Surgery.* 2007; 15(3):273-7.
9. Salunkhe RM, Limaye S, Biswas SK, Mehta RP. Cemented hemi-arthroplasty in proximal femoral fractures in elderly with severe osteoporosis: a case series. *Med J DY Patil Univ.* 2012; 5:36-42.
10. Tyllianakis M, Panagopoulos A, Papadopoulos A, Papisimos S, Mousafiris K. Treatment of extracapsular hip fractures with the proximal femoral nail (PFN): long term results in 45 patients. *Acta Orthop Belg.* 2004; 70:444-54.
11. Hardy DC, Descamps PY, Krallis P. Use of an intramedullary hip-screw compared with a compression hip-screw with a plate for intertrochanteric femoral fractures. A prospective, randomized study of one hundred patients. *J Bone Joint Surg Am.* 1998; 80:618-30.
12. Russel TA, Taylor JC, Technique manual. Memphis: Smith and Nephew Richards, Iric, 1984.
13. Russel TA, Taylor JC. Subtrochanteric fractures of the femur. In: Browner BD, Jupiter JB, and Levine AM. *Skeletal trauma* 2<sup>nd</sup> edition, Philadelphia, PA: WB Saunders; 1992, 1832-78.