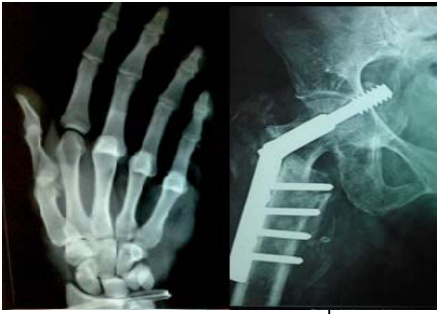



International Journal of Orthopaedics Sciences

ISSN: 2395-1958
IJOS 2017; 3(1): 233-236
© 2017 IJOS
www.orthopaper.com
Received: 08-11-2016
Accepted: 09-12-2016

S Subbiah
MS, MCh., Professor and Head,
Department of Surgical
Oncology Kilpauk Medical
College, Chennai, Tamil Nadu,
India

G Gopu
MS, MCh., Associate Professor,
Department of Surgical
Oncology Kilpauk Medical
College, Chennai, Tamil Nadu,
India

Dr. Syed Afroze Hussain
MCh., Assistant Professor,
Department of Surgical
Oncology Kilpauk Medical
College, Chennai, Tamil Nadu,
India

Dr. Bharanidharan,
Department of Surgical
Oncology Kilpauk Medical
College, Chennai, Tamil Nadu,
India

Correspondence:
S Subbiah
MS, MCh., Professor and Head,
Department of Surgical
Oncology Kilpauk Medical
College, Chennai, Tamil Nadu,
India

Distal tibial osteosarcoma: A technique of custom mega prostheses reconstruction

S Subbiah, G Gopu, Dr. Syed Afroze Hussain and Dr. Bharanidharan

DOI: <http://dx.doi.org/10.22271/ortho.2017.v3.i1d.38>

Abstract

Primary malignant bone tumours of the distal tibia are very rare. Amputation was the standard surgical treatment with satisfactory functional results obtained using an appropriate prosthesis^[1]. But in the era of limb salvage, tumours of distal tibia are being dealt with limb salvage surgery to provide patients with a better quality of life^[2].

We report a case of limb salvage for non-metastatic osteosarcoma of the distal tibia using resection and reconstruction with custom mega prostheses and ankle arthrodesis^[3]

Osteosarcomas of the distal tibia are rare. These tumours are usually treated with amputation^[2]. We report a case of osteosarcoma of distal tibia in a 13year old female. The patient presented with complaints of pain and limping gait of 6 months' duration. Imaging revealed a mixed lesion predominantly sclerotic with moth-eaten appearance, aggressive periosteal reaction in distal tibia. MRI revealed soft tissue involvement.

The patient received four cycles of neoadjuvant chemotherapy^[4] she had a good clinical response by clinical and imaging evaluation. A distal tibial resection with custom mega prostheses reconstruction was done. The post-operative histopathology revealed an osteoblastic variant of osteosarcoma with 60% of necrosis. The patient completed two more cycles of same chemotherapy^[4] the patient was on follow up since four months.

The post-treatment functional evaluation was done with "Revised Musculoskeletal Tumour Society Rating Scale^[5]. And patient had a score of 26 of 30. The patient was able to walk without crutches.

Keywords: Osteosarcoma, distal tibia, limb salvage, custom prostheses

1. Introduction

Primary malignant bone tumours of the distal tibia are very rare and amputation has been the standard surgical treatment for long with less satisfactory functional results obtained using an appropriate prosthesis^[1] But in era of limb salvage surgery, for tumours of distal tibia amputation can be avoided to provide patients better quality of life^[2] When ankle joint is involved it presents unique challenges in reconstruction in terms of biomechanics and soft tissue coverage^[6] Reconstruction of lower limb after resection of distal tibia remains a debate^[7] Casadei *et al.*, reported that arthrodesis is an option in whom limb salvage is planned^[8]. Other options include autografts, allografts and custom prostheses^[2].

Endo-prosthetic replacement of the distal tibia and ankle joint for a primary bone tumour is a rarely attempted and technically challenging procedure^[9]. We describe a case of osteosarcoma of the distal tibia which was treated with resection and reconstructed with custom-made prostheses with a better post-operative outcome.

2. Case report

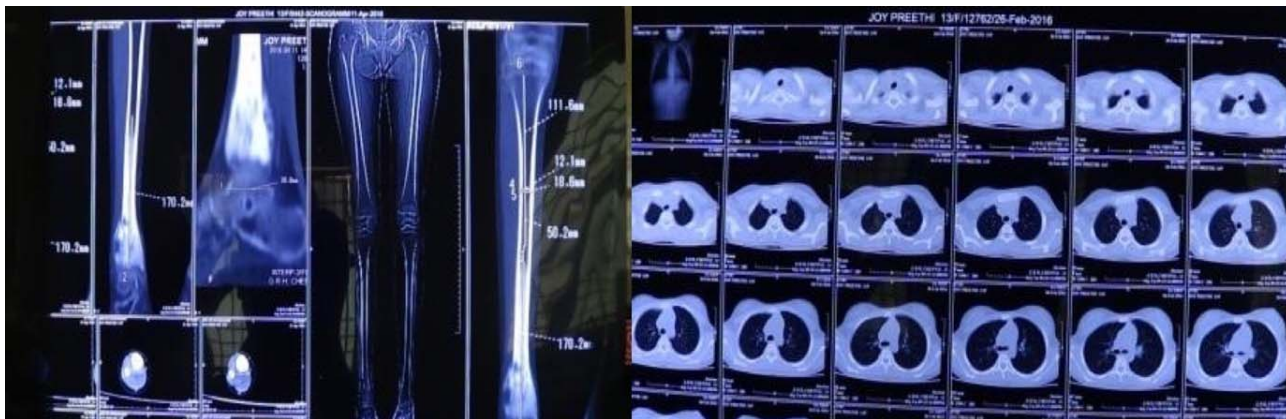
A 13-year-old female was referred to us, with complaints of pain in the right lower leg of six months' duration. The patient had limping gait of four months' duration. Symptoms progressively increased in severity.

On examination, the patient had diffuse swelling over the lower end tibia, without pathological fracture and distal neurovascular deficits. Ankle joint movement was restricted due to pain.

Radiograph of the right lower limb showed mixed predominantly sclerotic lesion over the distal tibia, with moth-eaten appearance, cortical breach aggressive sunburst periosteal reaction.

Magnetic resonance imaging was done which showed soft tissue involvement, and T1 and T2 hypo intense marrow signal abnormality. CT of the chest showed no evidence of

metastases (Figure 1). Bone biopsy was reported as an osteoblastic variant of osteosarcoma with sheets of hyperchromatic spindle cells and polyhedral cells [10].

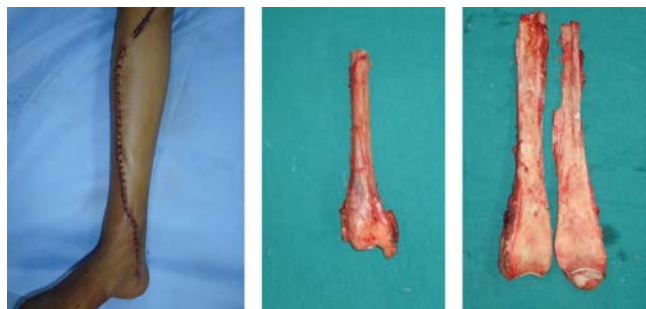
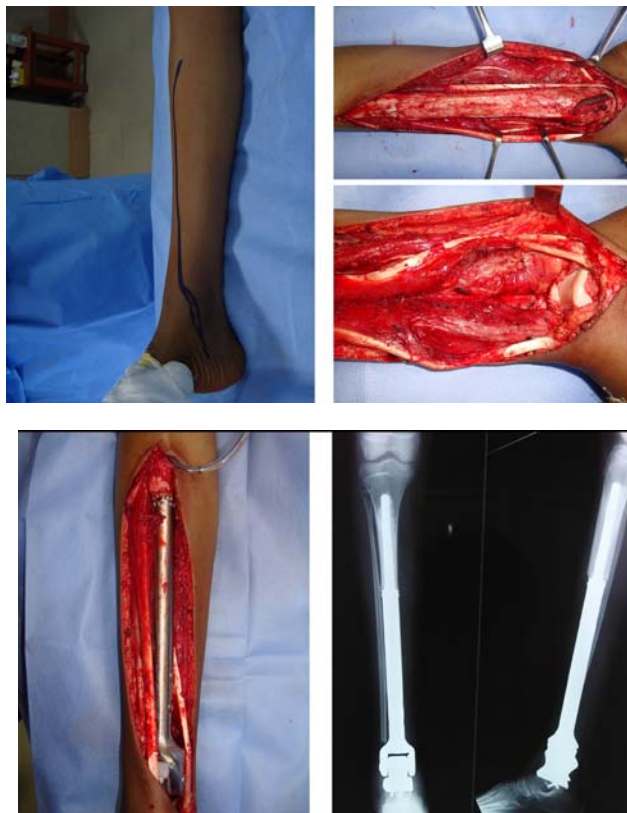
The patient was initiated on neoadjuvant chemotherapy with Adriamycin and Cisplatin [4]. The Patient was taken for surgery after four cycles of chemotherapy [4].

3. Prostheses

A custom prostheses was designed for the replacement of the resected distal tibial component [3] Due to availability and cost factor stainless steel prostheses was used. The segment resection was 22.5cm from the ankle joint and so base length of 22.5cm and width of 26mm is made with a stem length of 10cm with a proximal width of 10mm tapering to 8mm at the tip. The talus cup was hinged to the prostheses and prepared as one component.

extensor hallucis longus, extensor digitorum were preserved along with the anterior tibial artery. Then dissection continued posteriorly to preserve the tibialis posterior tendon flexor digitorum and the flexor hallucis longus. The tendo achilles and the posterior tibial artery was also preserved. Continuing the dissection laterally the peroneus longus and brevis is also preserved. Then joint capsule of the ankle was opened one centimetre below the joint line and capsule divided along with overlying ligaments all around the ankle. Tibia was cut giving a 5cm margin at 22.5cm from the lower end of the tibia. As the fibula was closer the tumour distal fourth of the fibula was also resected en bloc (Figure 2). Hemostasis was checked. The remaining tibia is reamed and prostheses trial assembly was done. The stem of the tibial component was inserted into the medulla of the remaining proximal portion of the tibia and fixed with bone cement. The distal component of the prostheses was secured with two cortical screws of 4.5mm and 28 mm one from medial side and the other from lateral side to the talus (Figure 3). The range of movement was checked and skin closed in layers with a suction drain. Plaster of Paris posterior slab was placed with the ankle in neutral position. Post procedure there was a limb lengthening of 1.0cm compared to the normal limb (Figure 4). Post-operative period was uneventful. The drain was removed on the 10th post-operative day (Figure 5). Non-weight bearing walking initiated on 10th postoperative day, and partial weight bearing was initiated from 3rd week onwards, with splint support (Figure 6).

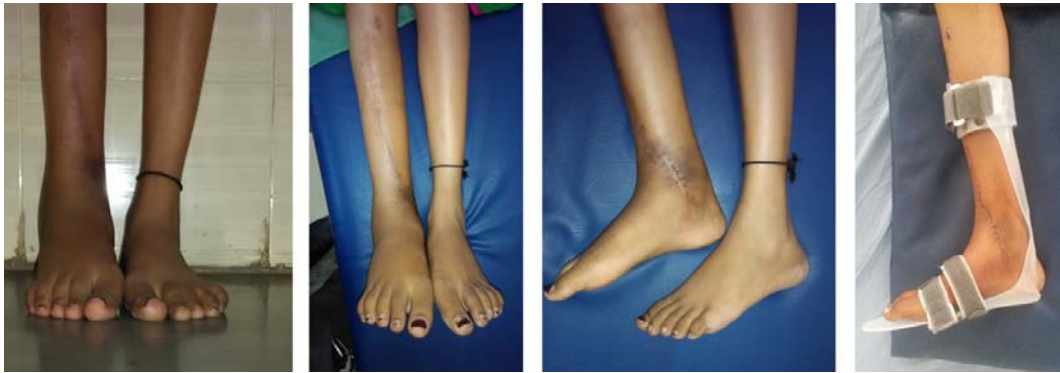

Through an anteromedial incision including the previous biopsy scar, skin flap raised deep to the deep fascia. Then tendons of the anterior compartment of leg, tibialis anterior,

Further cycles of chemotherapy were completed [4]. Postoperative histopathology revealed osteoblastic osteosarcoma with 60% necrosis and margin negative for malignancy [10]. Five months of follow-up the patient is presently able to stand on her legs walk independently. Patient has an active plantar

flexion of 15° degrees dorsiflexion of 10° degrees, and passive 30° planter flexion and passive 15° dorsiflexion, active inversion of 10° degrees and no eversion [11]. The patient is on regular physiotherapy training for further muscle

strengthening. Post-treatment functional evaluation with “Revised Musculoskeletal Tumour Society Rating Scale” had a score of 26 of 30. Patient is able to have pain free independent gait without much loss of function



4. Discussion

The most important factor in the treatment of malignant bone tumour of distal tibia is to achieve an adequate margin of resection [12]. Below-knee amputation has been the standard surgical procedure for malignant bone tumours involving the distal tibia and fibula. But amputation is associated with social and psychological stress. Advances in surgical techniques, chemotherapy and endoprosthesis have helped in limb salvage procedures. Among options of reconstruction, arthrodesis was considered initially the best option providing stability [13], and Casadei *et al*, reported 12 cases of malignant tumours of the distal tibia and treated with resection and arthrodesis by autogenous bone graft [8]. But had complications like infection, limb shortening, and fracture of grafted part. But the major problem is a loss of movement of the affected ankle joint, and the possibility of nonunion. Bishop *et al*, reported reconstruction with vascularized bone graft for malignant tumours of distal tibia [14].

Limb salvage procedures using custom prostheses have advantages in these considerations. The problems in limb salvage procedure are the extent of soft tissue involvement and blood vessel involvement. The distal tibia has few direct muscle attachments and if the posterior tibial artery or dorsalis pedis artery is not salvageable amputation is the only option. Likewise, posterior tibial nerve should also be preserved.

5. Conclusion

Custom-made endo-prosthetic reconstruction of the ankle following resection of a bone tumour is a viable treatment in carefully selected patients [15]. Pre-operative counselling is essential and should cover the associated risks, morbidity and the possibility of subsequent amputation. However, we believe that the complication rates are acceptable if amputation is the alternative in malignant distal tibial tumours [16].

6. Reference

- 1 Lee SH, Kim HS, Park YB, Rhie TY, Lee HK. Prosthetic reconstruction for tumours of the distal tibia and fibula. *J Bone Jt Surg Br.* 1999; 81(5):803-807. doi:10.1302/0301-620X.81B5.9588.
- 2 Shalaby S, Shalaby H, Bassiony a. Limb salvage for osteosarcoma of the distal tibia with resection arthrodesis, autogenous fibular graft and Ilizarov external fixator. *J Bone Joint Surg Br.* 2006; 88(12):1642-1646. doi:10.1302/0301-620X.88B12.17879.
- 3 Natarajan MV, Annamalai K, Williams S, Selvaraj R,

Rajagopal TS. Limb salvage in distal tibial osteosarcoma using a custom mega prosthesis. *Int Orthop.* 2000; 24(5):282-284. doi:10.1007/s002640000172.

- 4 Bacci G, Picci P, Ferrari S. Neoadjuvant chemotherapy for the treatment of osteosarcoma of the extremities: excellent response of the primary tumor to preoperative treatment with methotrexate, cisplatin, adriamycin, and ifosfamide. Preliminary results. *Chir Organi Mov.* 1995; 80(1):1-10.
- 5 Gerrand CH, Rankin K. A system for the functional evaluation of reconstructive procedures after surgical treatment of tumors of the musculoskeletal system. In: *Classic Papers in Orthopaedics.* 2014; 489-490. doi: 10.1007/978-1-4471-5451-8_128.
- 6 Kundu ZS, Gogna P, Gupta V. Ankle fusion with centralisation of the fibula after distal tibia bone tumour resection. *J Orthop Traumatol.* 2014; 15(2):95-101. doi:10.1007/s10195-013-0279-2.
- 7 Hamblen DL. Can the ankle joint be replaced? *J Bone Joint Surg Br.* 1985; 67(5):689-690.
- 8 Casadei R, Ruggieri P, Giuseppe T, Biagini R, Mercuri M. Ankle resection arthrodesis in patients with bone tumors. *Foot ankle Int.* 1994; 15(5):242-249. doi:10.1177/107110079401500503.
- 9 Grimer RJ, Carter SR, Tillman RM. Endoprosthetic replacement of the proximal tibia. *J Bone Jt Surgery-British.* 1999; 81B(3):488-494. doi:10.1302/0301-620X.81B3.13838.
- 10 Klein MJ, Siegal GP. Osteosarcoma. *Am J Clin Pathol.* 2006; 125(4):555-581. doi:10.1309/UC6KQHLD9LV2KENN.
- 11 Roaas A, Andersson GBJ. Normal Range of Motion of the Hip, Knee and Ankle Joints in Male Subjects, 30-40 Years of Age. *Acta Orthop Scand.* 1982; 53(2):205-208. doi:10.3109/17453678208992202.
- 12 Dürr HR, Bakhshai Y, Rechl H, Tunn PU. [Resection margins in bone tumors: what is adequate?]. *Unfallchirurg.* 2014; 117(7):593-599. doi:10.1007/s00113-013-2475-1.
- 13 Bolton-Maggs BG, Sudlow RA, Freeman MA. Total ankle arthroplasty. A long-term review of the London Hospital experience. *J Bone Joint Surg Br.* 1985; 67(5):785-790.
- 14 Bishop AT, Wood MB, Sheetz KK. Arthrodesis of the ankle with a free vascularized autogenous bone graft. Reconstruction of segmental loss of bone secondary to osteomyelitis, tumor, or trauma. *J Bone Joint Surg Am.*

- 1995; 77(12):1867-1875.
<http://jbjs.org/content/77/12/1867.abstract>. Accessed
November 15, 2016.
- 15 Nichter LS, Menendez LR. Reconstructive considerations
for limb salvage surgery. *Orthop Clin North Am.* 1993;
24(3):511-521.
- 16 Shekkeris S, Hanna S, Sewell MD. Endoprosthetic
reconstruction of the distal tibia and ankle joint after
resection of primary bone tumours. *J Bone Joint Surg Br.*
2009; 91(10):1378-1382. doi:10.1302/0301-
620X.91B10.22643.